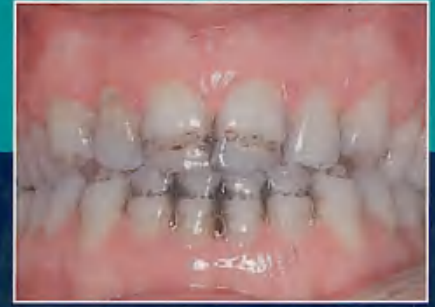
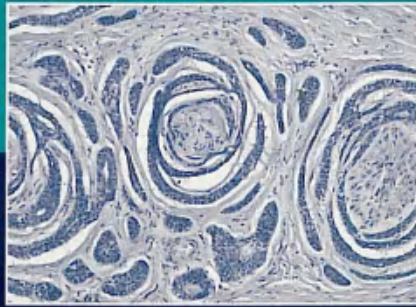
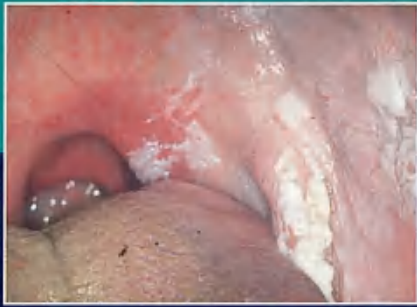
Oral Pathology

Fourth Edition

J. V. Soames and J. C. Southam

OXFORD



OXFORD MEDICAL PUBLICATIONS

Oral Pathology

Oxford University Press makes no representation, express or implied, that the drug dosages in this book are correct. Readers must therefore always check the product information and clinical procedures with the most up to date published product information and data sheets provided by the manufacturers and the most recent codes of conduct and safety regulations. The authors and the publishers do not accept responsibility or legal liability for any errors in the text or for the misuse or misapplication of material in this work.

Oral Pathology

Fourth Edition

J. V. Soames

Professor of Oral Pathology
University of Newcastle upon Tyne
UK

And

J. C. Southam

Emeritus Professor of Oral Medicine and Oral Pathology
University of Edinburgh
UK

OXFORD
UNIVERSITY PRESS

OXFORD

UNIVERSITY PRESS

Great Clarendon Street, Oxford OX2 6DP

Oxford New York

Auckland Bangkok Buenos Aires Cape Town Chennai
Dar es Salaam Delhi Hong Kong Istanbul Karachi Kolkata
Kuala Lumpur Madrid Melbourne Mexico City Mumbai Nairobi
São Paulo Shanghai Taipei Tokyo Toronto

Oxford is a registered trade mark of Oxford University Press
in the UK and in certain other countries

Published in the United States
by Oxford University Press Inc., New York

© J. V. Soames and J. C. Southam, 1985, 1993, 1998, 2005

The moral rights of the author have been asserted

Database right Oxford University Press (maker)

First edition published 1985

Reprinted 1988, 1989, 1990 (with corrections), 1991

Second edition 1993

Reprinted 1995, 1996

Third edition 1998

Reprinted 1999, 2001, 2002, 2003

Fourth edition 2005

Reprinted 2007, 2008

All rights reserved. No part of this publication may be reproduced,
stored in a retrieval system, or transmitted, in any form or by any means,
without the prior permission in writing of Oxford University Press,

Within the UK, exceptions are allowed in respect of any
or as expressly permitted by law, or under terms agreed with the appropriate
reprographic rights organization. Enquiries concerning reproduction
outside the scope of the above should be sent to the Rights Department,
Oxford University Press, at the address above.

You must not circulate this book in any other binding or cover
and you must impose this same condition on any acquirer

British Library Cataloguing in Publication Data

Data available

Library of Congress Cataloging in Publication Data

ISBN 978-0-19-852794-7

10 9 8 7 6 5 4

Typeset by EXPO Holdings Sdn Bhd., Malaysia

Printed in China

on acid-free paper by

Asia Pacific Offset

Preface to the fourth edition

The past seven years have seen major advances in molecular biology and genetics which have increased our understanding of several oral and maxillofacial diseases. In undertaking this edition we have included examples of these advances, even though in many cases enormous gaps in knowledge remain and some hypotheses must be considered as speculative. Nevertheless, it is likely these topics will impact on dentistry more and more in the future. Students and practitioners need to be aware of these developments, not least because they may be raised by an increasingly knowledgeable public. For example, recent advances in the understanding of the genetics of tooth formation were quickly followed by radio broadcasts and articles in the popular press discussing the possibility of developing a 'third set' after loss of a permanent tooth.

The Fourth Edition has been thoroughly updated and revised, where required, to encompass these developments. However, we have tried to avoid the trap of increasing the length and complexity of the text so as not to obscure the basic information necessary for students to gain knowledge and develop understanding of oral diseases. To this end, and to avoid disrupting the flow of the core information comprising the body of the text, we have condensed

much of the information relating to advances in molecular biology and genetics into additional information Boxes, supported by up-to-date references in Further Reading. Some of the rarer entities have also been incorporated into additional information Boxes, and the two previous chapters on disorders of bone have been edited and condensed into one. In response to feedback from students, both the number of Key Points, and the number of bullet points they contain, have been increased to aid learning. It is appreciated that curricula in oral pathology vary from country to country and from school to school but the text adequately covers the range of disorders comprising the minimum curriculum in oral pathology published recently by the British Society for Oral and Maxillofacial Pathology.¹

Finally, in addition to acknowledging the helpful comments received from colleagues and students, we are again indebted to Mrs Sylvia Bohan for her word processing skills, and to Joan, for unstinting support and the hours spent reading drafts and proofs.

Newcastle upon Tyne
Edinburgh
November 2004

J. V. S.
J. C. S.

¹ Odell, E.W., Farthing, P.M., High, A., Potts, J., Soames, J., Thakker, N., Toner, M., and Williams, H.K. (2004). British Society for Oral and Maxillofacial Pathology, UK: minimum curriculum in oral pathology. *European Journal of Dental Education*, 8, 177-84

Preface to the third edition

In undertaking the third edition our aim, as before, has been to provide a text primarily for undergraduate students, but with sufficient breadth and depth to be of value both to postgraduates studying for higher clinical qualifications, and to the continuing professional development of general dental practitioners. We have been aware of the impact of advances in molecular biology and genetics relevant to the understanding of basic disease processes, such as neoplasia, and of their application in oral pathology. We have also taken the opportunity to amend the classification and nomenclature of diseases, particularly the salivary gland tumours and odontogenic tumours, in line with current opinion.

To encompass these developments we have revised and updated the text, expanding some sections, editing others, and deleting concepts no longer generally accepted, so that the overall length of the book has not been significantly increased. One or two relatively new and rare entities, such as the glandular odontogenic cyst, have been included for completeness and the refer-

ences recommended for further reading have been extensively updated. We have retained the general format and chapter headings adopted for the second edition but the revised text is now considerably enhanced by being illustrated throughout in colour and by the inclusion of key points which, we hope, will help the reader identify important aspects of particular diseases.

As with the first two editions we are much indebted to the help and comments we have had from colleagues and students, and hope their criticisms have been addressed. We also wish to acknowledge the word processing and typing skills of Mrs Sylvia Bohan in preparing the revised text and owe special thanks to Joan for her patience, and for the many hours spent cutting, pasting, and proof reading.

Newcastle upon Tyne
Edinburgh
November 1997

J. V. S.
J. C. S.

Preface to the second edition

In the eight years that have passed since the publication of the First Edition of *Oral pathology* there have been many advances in our understanding of basic disease processes that particularly reflect the enormous progress in molecular biology. These have had their impact on research in oral pathology and on the day-to-day practice of diagnostic oral histopathology where, for example, immunohistochemical techniques are now routinely used. There have also been important changes in the patterns of oral and dental diseases associated, for example, with AIDS, the oral manifestations of which are important early diagnostic features, and the increasing numbers of elderly patients retaining their natural dentition. Several new clinicopathological entities have been described and others such as the odontogenic and salivary gland tumours have undergone changes in nomenclature and classification.

This Second Edition has been thoroughly revised and updated with several chapters being extensively rewritten. Diseases which are becoming increasingly important such as those associated with HIV infection are now fully described and illustrated. Our aim, as with the First Edition, has been to produce a compact and readable text aimed primarily at undergraduate students, but we hope that it will also be of value to postgraduates studying for higher clinical qualifications, more so now that we have included information on some of the less common oral diseases. In addition, we have been mindful of the needs of general dental prac-

tioners and of colleagues in other fields of medicine who wish to update their knowledge and understanding of oral diseases.

In response to criticism of the First Edition, this edition is extensively illustrated with over 400 photographs, some 190 of which are in colour, and we hope the book satisfies its purpose the better for this change. The illustrations have been drawn from our departmental collections but it is inevitable that over the years these have been enhanced by material 'collected' from elsewhere. Where this could be identified we have sought approval for its inclusion; we apologize for any that have escaped our notice but hope that colleagues will be pleased with the results.

Once again, we wish to acknowledge the advice and help we have had from our many colleagues. We particularly wish to express our gratitude for the assistance and skills of Mrs Diane Burgess for the typing and wordprocessing needed in the preparation and reorganization of the revised text; to David Sales for the line drawings and photomicrography; and to Brain Hill and Jan Howarth of the Department of Medical Illustration, Newcastle upon Tyne Dental Hospital, for most of the clinical photographs.

Newcastle upon Tyne
Edinburgh
November 1992

J. V. S.
J. C. S.

Preface to the first edition

Oral pathology is that part of pathology concerned with the scientific study of the causes and effects of oral disease, an understanding of which is essential for diagnosis and for the development of rational treatment and preventive programmes. The main purpose of this book is to provide the undergraduate dental student with sufficient information, as a foundation on which to build such as understanding, but it is also hoped that it will be of value to postgraduate students preparing for higher clinical qualifications.

Since this is essentially an undergraduate text we have consciously omitted or treated only briefly some of the rarer oral diseases. With regard to the commoner conditions we have endeavoured to interpret and incorporate recent advances in knowledge and in some cases even speculation. Where controversy exists we have attempted to provide an outline of the main arguments or at least a consensus view, but it is inevitable that in some cases we have had to be dogmatic.

Limitation of space and constraints imposed by costs have restricted the number of illustrations, but photographs are no substitute for practical experience and it is hoped that students will have the opportunity and be encouraged to study many of the

diseases covered in this book in clinical and laboratory classes. Similarly, the reference at the end of each chapter are in no sense comprehensive but either provide the reader with more detailed accounts of specific topics or are major review articles or specialized texts which themselves contain a more extensive bibliography.

We have much pleasure in acknowledging the help we have received from our many colleagues either directly or through their writings. The thoughts and ideas contained within the book partly reflect the authors' initial training in oral pathology in Manchester and Sheffield. The writing started when both authors worked together in Edinburgh and progress slowed when one of the authors moved to Newcastle. We would particularly wish to thank Yvonne Stables for her skill in deciphering and typing the drafts of the manuscripts, Gordon Bolas for much help with the indexing, Brian Conroy for his expertise in photomicrography, and David Sales for the line drawings.

Newcastle upon Tyne

Edinburgh

July 1985

J. V. S.

J. C. S.

Contents

1. Disorders of development of teeth and cranofacial anomalies	1
Disorders of development of teeth	3
Disturbances in number of teeth	3
Disturbances in size of teeth	5
Disturbances in form of teeth	6
Disturbances in structure of teeth	8
Craniofacial anomalies	16
Further reading	16
2. Dental caries	19
Aetiology of dental caries	21
Pathology of dental caries	24
Immunological aspects of dental caries	31
Further reading	31
3. Other disorders of teeth	33
Disorders of eruption and shedding of teeth	35
Non-bacterial loss of tooth substance	36
Discoloration of teeth	41
Transplantation and reimplantation of teeth	42
Root fracture	43
Age changes in teeth	43
Further reading	44
4. Disorders of the dental pulp	45
Pulpitis	47
Healing of pulp	51
Pulp calcification	52
Pulp necrosis	52
Age changes in the pulp	53
Further reading	53
5. Periapical periodontitis	55
Aetiology	57
Acute periapical periodontitis	58
Chronic periapical periodontitis (periapical or apical granuloma)	58
Acute periapical abscess and spread of inflammation	60
Further reading	63

6. Cysts of the jaws and oral soft tissues	65
Classification and incidence of cysts of the jaws	67
Odontogenic cysts: definition and origins	67
Non-odontogenic cysts	78
Non-epithelialized primary bone cysts	79
Cysts of the soft tissues	81
Further reading	84
7. Diseases of the periodontium	85
Chronic gingivitis and chronic periodontitis	87
Gingival enlargement	97
Desquamative gingivitis	98
Lateral periodontal abscess	98
Pericoronitis	98
Age changes in the periodontium	99
Further reading	99
8. Hyperplastic, neoplastic, and related disorders of oral mucosa	101
Hyperplasias of oral mucosa	103
Connective tissue neoplasms and allied conditions	107
Further reading	115
9. Keratoses and related disorders of oral mucosa	117
Classification	119
Definition of histopathological terms	120
Hereditary conditions	120
Traumatic keratoses	121
Leukoplakia	122
Dermatological causes of white patches	128
Further reading	131
10. Oral epithelial tumours, melanocytic naevi, and malignant melanoma	133
Squamous cell papilloma and other benign lesions associated with human papillomavirus (HPV)	135
Squamous cell carcinoma	136
Precancerous (or premalignant) lesions and conditions	147
Basal cell carcinoma (rodent ulcer)	147
Melanocytic naevi and malignant melanoma	148
Further reading	149
11. Infections of the oral mucosa	151
Viral infections	153
Bacterial infections	157
Fungal infections	161
Human immunodeficiency virus (HIV) infection and AIDS	166
Further reading	171
12. Oral ulceration and vesiculobullous diseases	173
Classification of oral ulceration	175
Traumatic ulceration	175
Recurrent aphthous stomatitis (RAS)	176
Vesiculobullous diseases	180
Further reading	186

13. Miscellaneous disorders of oral mucosa	189
Fordyce's granules	191
Sublingual varices	191
Lingual tonsil, foliate papillitis	191
Geographic tongue (benign migratory glossitis)	192
Orofacial granulomatosis	192
Crohn's disease	193
Sarcoidosis	194
Pyostomatitis vegetans	194
Wegener's granulomatosis	194
Progressive systemic sclerosis (scleroderma)	195
Verruciform xanthoma	196
Oral submucous fibrosis	197
Amyloidosis	197
Oral pigmentation	197
Age changes in the oral mucosa	201
Further reading	201
14. Diseases of salivary glands	203
Developmental anomalies	205
Sialadenitis	205
Obstructive and traumatic lesions	207
Sjögren syndrome	209
Sialadenosis	211
HIV-associated salivary gland disease	211
Salivary gland tumours	212
Age changes in salivary glands	218
Further reading	218
15. Odontomes and odontogenic tumours	221
Classification	223
Odontomes	223
Odontogenic tumours	228
Tumours of debatable origin	236
Further reading	236
16. Disorders of bone	239
Inherited and developmental disorders of bone	241
Healing of bone	247
Inflammatory diseases of bone	248
Metabolic and endocrine disorders of bone	251
Paget's disease of bone	252
Central giant cell granuloma	255
Torus palatinus, torus mandibularis, and other exostoses	256
Dense bone island	257
Tumours of bone	257
Langerhans cell histiocytosis	260
Haemangioma of bone	261
Metastatic tumours	261
Further reading	261
17. Diseases of the temporomandibular joint	263
Developmental disorders	265

Inflammatory disorders	265
Osteoarthrosis (osteoarthritis)	266
Functional disorders	267
Loose bodies	268
Neoplasms	268
Age changes in the jaws and temporomandibular joint	268
Trismus and dislocation	268
Further reading	268
Index	271

Disorders of development of teeth and craniofacial anomalies

DISORDERS OF DEVELOPMENT OF TEETH

DISTURBANCES IN NUMBER OF TEETH

- Hypodontia, anodontia, and associated syndromes
- Hypohidrotic ectodermal dysplasia
- Supernumerary teeth (hyperdontia)

DISTURBANCES IN SIZE OF TEETH

- Macrodontia and microdontia

DISTURBANCES IN FORM OF TEETH


- Dilaceration
- Taurodontism
- Double teeth
- Concrescence

DISTURBANCES IN STRUCTURE OF TEETH

- Disturbances in structure of enamel
 - Localized causes
 - Generalized causes
- Disturbances in structure of dentine
- Disturbances in structure of cementum

CRANIOFACIAL ANOMALIES

FURTHER READING



Disorders of development of teeth and craniofacial anomalies

The development of teeth and of the face is regulated by genes, but the genetic programme is very sensitive to disturbances in the environment such as exposure to infection or toxic chemicals, including drugs. The specific genetic abnormalities underlying some developmental disorders are now known, and for several others a strong genetic association has been established, even though the genes have yet to be identified. However, there remain many where the causes appear complex and multifactorial, involving the interaction of genetic and environmental factors.

Disorders of development of teeth

Disorders of development of teeth may be prenatal or postnatal in origin and may be inherited or acquired. Their recognition and evaluation require a thorough knowledge of the normal chronology of the human dentition and of the normal development and structure of the teeth.

Disorders of development of teeth may be due to abnormalities in the differentiation of the dental lamina and the tooth germs, causing anomalies in the number, size, and form of teeth (abnormalities of morphodifferentiation) or to abnormalities in the formation of the dental hard tissues resulting in disturbances in tooth structure (abnormalities of histodifferentiation). Abnormalities of histodifferentiation occur at a later stage in development than abnormalities of morphodifferentiation; in some disorders both stages of differentiation are abnormal.

Disturbances in number of teeth

Hypodontia, anodontia, and associated syndromes

The congenital absence of teeth may be referred to as hypodontia, when one or several teeth are missing, or anodontia when there is a complete absence of one or both dentitions.

Hypodontia is more common in the permanent dentition, occurring in about 2–10 per cent in different populations (excluding absent third molars) compared to the primary dentition where the prevalence is less than 1 per cent. It is more common in females and there are also racial differences. For example, the prevalence of missing mandibular permanent central incisors is much more common in Japanese and Swedish populations than in

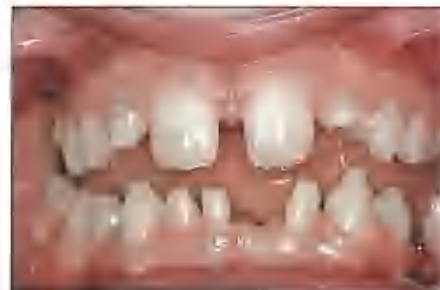

Fig. 1.1 Symmetrical hypodontia. (Note retention of deciduous teeth where permanent successional teeth are absent.)

other groups studied. Hypodontia may be symmetrical when particular teeth or groups of teeth are involved, or haphazard when no pattern is discernible (Fig. 1.1). Although it is very unusual for deciduous teeth to be congenitally absent, it is likely that in such cases the permanent successional tooth will also fail to form. Third molars, permanent maxillary lateral incisors, and mandibular second premolars are the teeth most frequently involved in symmetrical forms and a hereditary trait can sometimes be shown with missing maxillary lateral incisors.

Although the genetic basis of hypodontia is not yet understood, several regulatory genes involved in tooth development have been identified and it is likely that mutations in these result in tooth agenesis (see Box 1.1). These control or regulatory genes are not unique to tooth development but are the same genes that control the development of the face and of many other tissues and organs in the embryo. Thus, hypodontia may be associated with other craniofacial anomalies and developmental syndromes (see Table 1.1).

Hypohidrotic ectodermal dysplasia

Severe hypodontia and anodontia are rare and in most cases are associated with other defects, the most frequent being hereditary hypohidrotic ectodermal dysplasia which is characterized by the congenital absence of ectodermal structures. The disorder is rare and is usually inherited as an X-linked recessive trait, although a very rare autosomal recessive form has been described and sporadic cases have been reported. Affected patients have smooth, dry skin with fine, scanty hairs (Fig. 1.2) and partial or total absence

Box 1.1 Developmental control genes

- Control genes play key roles in organ formation and the patterning of structures throughout the embryo.
- The effects of control genes depend on the time of their activation during embryogenesis and the cells/tissues upon which they act.
- Control genes regulate the signalling pathways between cells and tissues.
- They act as transcription factors regulating gene expression in the nucleus; the control genes regulate expression of the structural genes.
- Two important examples of transcription factors in tooth formation are the *Pax9* and *Msx1* genes.
- *Msx1* is essential for tooth formation in mice; in the absence of *Msx1* tooth formation is arrested at the bud stage.
- *Msx1* mutations in humans cause hypodontia.
- *Pax9* mutations also cause hypodontia and the gene is also required for expression of *Msx1*.
- *Msx1* and *Pax9* are part of a complex genetic network involving several other transcription factors and signalling molecules involved in tooth development.

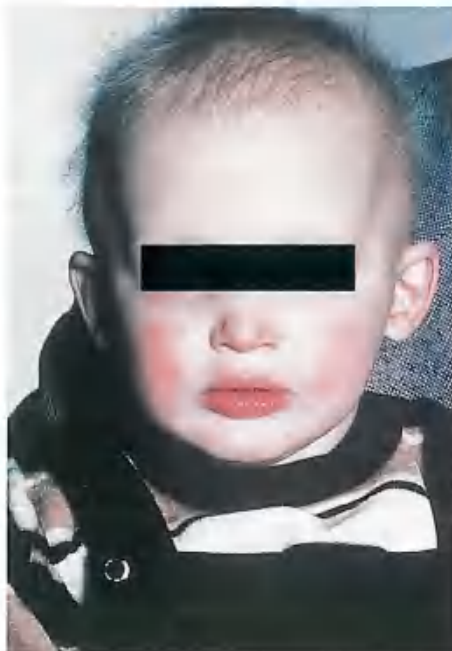

Fig. 1.2 Hypohidrotic ectodermal dysplasia.

Table 1.1 Examples of craniofacial anomalies and developmental syndromes associated with abnormalities in the number of teeth

Syndrome/anomaly	Associated features
A. Hypodontia	
Cleft lip/palate	Possible deafness and other cranial and skeletal abnormalities
Crouzon syndrome	Craniosynostosis, maxillary hypoplasia, hypertelorism
Down syndrome (trisomy 21)	Multiple, e.g. mental retardation, maxillary hypoplasia, macroglossia
Hypohidrotic ectodermal dysplasia	Hypotrichosis, hypohidrosis, saddle-nose
Ellis-van Creveld syndrome (chondroectodermal dysplasia)	Dwarfism, polydactyly, cardiac malformations
Oral-facial-digital syndrome	Cleft palate, hypoplasia of the nose, digital malformations
B. Hyperdontia	
Cleft lip/palate	Possible deafness and other cranial and skeletal abnormalities
Cleidocranial dysplasia	Aplasia of clavicles, delayed ossification of fontanelles, enlargement of cranium
Gardner syndrome	Multiple osteomas of jaws, skin cysts and fibromas, intestinal polyposis
Oral-facial-digital syndrome	Cleft palate, hypoplasia of the nose, digital malformations

of sweat glands which leads to hyperthermia. Some have a few teeth present, but these are often retarded in eruption, deformed, and frequently have conical crowns (Fig. 1.3) (see Box 1.2). Female carriers usually show only mild manifestations that may be restricted to minimal hypodontia, such as absent maxillary lateral incisors, but carriers may be detected by a reduced sweat pore count.

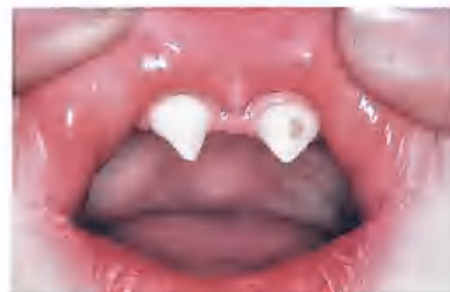


Fig. 1.3 Hypodontia associated with hypohidrotic ectodermal dysplasia.

Box 1.2 Hypohidrotic ectodermal dysplasia (HED)

- The formation of skin appendages and teeth depends on epithelial-mesenchymal interactions.
- Defective signalling between epithelium and mesenchyme is involved in HED.
- X-linked HED is caused by mutation in the EDA gene which codes for a signalling molecule.
- The rare autosomal form is caused by mutation of the gene which codes for the signal receptor.

Supernumerary teeth (hyperdontia)

These are teeth additional to those of the normal series. They may develop in any tooth-bearing area but occur most frequently in the anterior and molar regions of the maxilla followed by the premolar region of the mandible. Occasionally, they are associated with other defects, such as cleft palate or cleidocranial dysplasia (see Table 1.1). They may prevent the eruption, or cause malposition or resorption of adjacent teeth, and may develop dentigerous cysts if unerupted. Supernumerary teeth are more common in females, are usually single and occur in about 1–3 per cent of the population in the permanent dentition. They are unusual in the deciduous dentition.

Supernumerary teeth occurring at certain sites may be referred to by special terms. A mesiodens (Fig. 1.4) is a supernumerary tooth developing between the maxillary central incisors and is the most common of all supernumerary teeth. The majority have conical crowns and short roots. A paramolar (Fig. 1.5) arises alongside the maxillary molars and is usually buccally placed, and a distomolar develops distal to a third molar. Supernumerary teeth which morphologically resemble those of the normal series are called supplemental teeth but most are reduced in size.

Disturbances in size of teeth

Macrodontia and microdontia

The size of both the teeth and the jaws is influenced by genetic and environmental factors and considerable variation occurs.

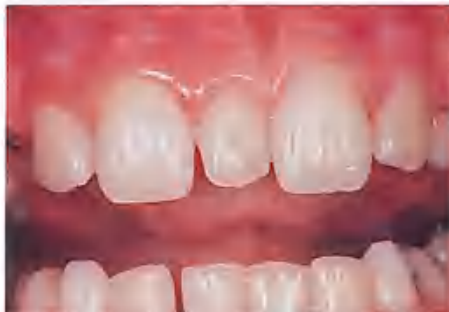

Fig. 1.4 Mesiodens.

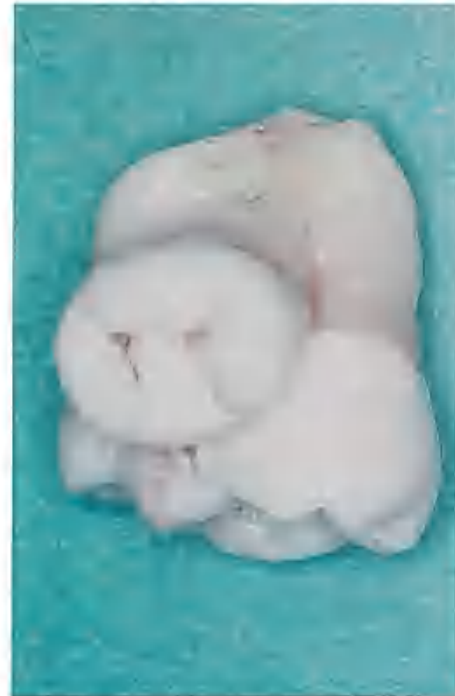

Fig. 1.5 Paramolar (with concrescence).

Studies of twins have shown that for the teeth, at least, genetic factors account for a large part of this variation. The terms 'macrodontia' and 'microdontia' are used to describe teeth which are larger or smaller than normal, respectively, but the limits of

Key points – Hypodontia and Hyperdontia

Hypodontia

- more common in permanent than primary dentition
- may be associated with mutations in developmental control genes
- absence of primary teeth associated with absence of permanent successors
- may be associated with other developmental abnormalities

Severe Hypodontia/Anodontia

- rare
- associated most frequently with hypohidrotic ectodermal dysplasia (HED)
- HED usually X-linked recessive

Hyperdontia (supernumerary teeth)

- more common in maxilla than mandible
- occasionally associated with other developmental defects
- more common in females than males
- relatively uncommon in primary dentition

normal variation have never been adequately defined. Both macrodontia and microdontia may involve the entire dentition, or only one or two teeth symmetrically distributed in the jaws. Microdontia of the whole dentition may be associated with other defects, for example Down syndrome and congenital heart disease.

Whilst it is convenient to consider abnormalities in the number and the size of teeth separately the anomalies often occur together. For example, hypodontia and microdontia may occur together in several of the conditions listed in Table 1.1. More common examples are seen in patients with one missing permanent maxillary lateral incisor, in which case the contralateral tooth is frequently peg-shaped.

Disturbances in form of teeth

Disturbances in tooth form may involve the crown, the root, or both. The most frequent variations of the crowns of teeth affect maxillary permanent lateral incisors, which may be peg-shaped or show an accentuated cingulum – either variation sometimes being associated with an invagination. Premolars or molars with an increased or decreased number of cusps are also frequently seen. Variations in the number, course, form, and size of roots are particularly common.

Dilaceration

The term dilaceration is used to describe a deformity in which the crown of the tooth is displaced from its normal alignment with the root, so that the tooth is severely bent along its long axis

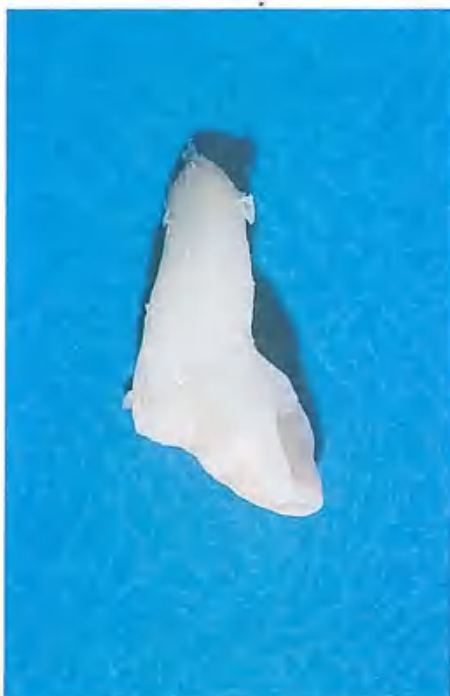

Fig. 1.6 Dilacerated permanent maxillary lateral incisor.



Fig. 1.7 Ground section of dilacerated tooth shown in Fig. 1.6.

(Figs 1.6, 1.7). Dilaceration is usually the result of acute mechanical trauma and most frequently involves the maxillary incisors.

Taurodontism

A taurodont tooth (bull-like tooth) is one in which the pulp chamber has a greater apico-occlusal height than in normal teeth, with no constriction at the level of the amelocemental junction.

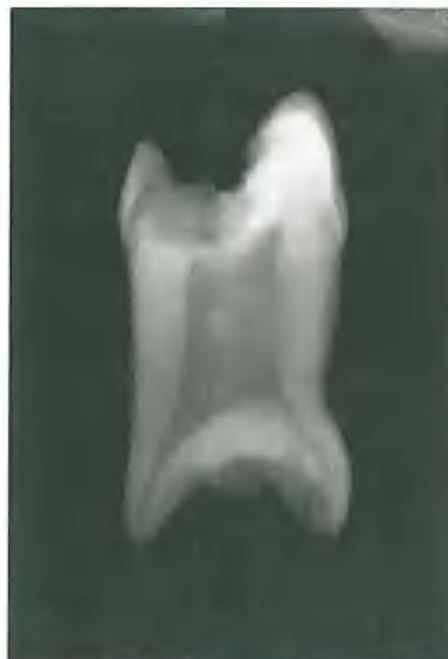

Fig. 1.8 Radiograph of taurodont tooth.

The result is that the chamber extends apically, well beyond the neck of the tooth (Fig. 1.8). The anomaly affects multirrooted teeth and is thought to be caused by the failure of Hertwig's sheath to invaginate at the proper horizontal level. It is rare in the primary dentition. Taurodont teeth may occur as incidental findings or be associated with other rare craniofacial or dental anomalies. There is also an association with abnormalities in the number of the sex chromosomes such as in Klinefelter and poly-X syndromes.

Double teeth

Double teeth is a descriptive term used to describe a developmental anomaly where two teeth appear joined together. The degree of union is variable and may involve the crown, the roots, or both. It is very unusual for teeth to be united by enamel only, joining of the dentine and also the pulp chamber being much more frequent (Figs 1.9, 1.10).

A variety of other terms have been applied to this anomaly based on its supposed aetiology, such as fusion and gemination. These have been defined as:

- Fusion** – the union between dentine and/or enamel of two or more separate developing teeth.
- Gemination** – the partial development of two teeth from a single tooth bud following incomplete division.

However, the aetiology remains unclear although a genetic basis has been suggested. For this reason the general term 'double teeth', which describes the appearance with no implication regarding aetiology, is preferred. The developmental anomaly of double teeth must be distinguished from concrescence which is an acquired condition where teeth are joined by cementum only (see below).

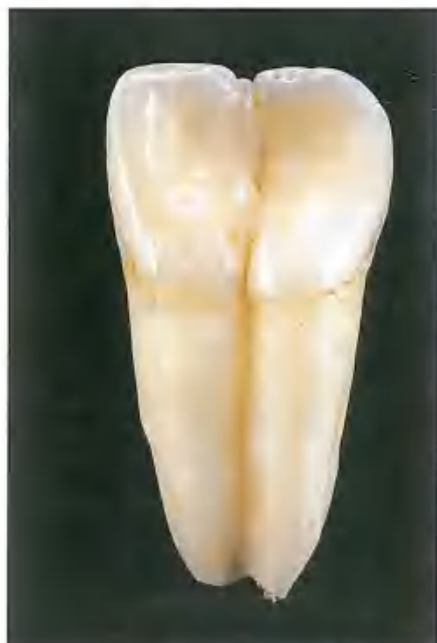

Fig. 1.9 Double (geminated) mandibular incisor tooth.

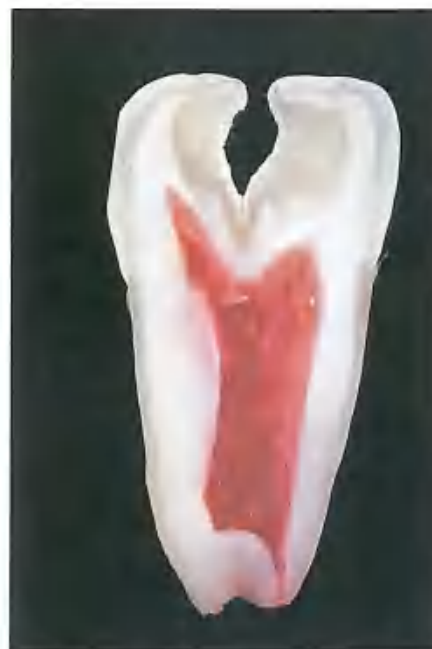

Fig. 1.10 Bisected double tooth shown in Fig. 1.9. There is union of enamel, dentine, and pulp.

Double teeth are more common in the primary than in the permanent dentition, the prevalence in different series ranging from 0.5–2.5 per cent for the primary and 0.1–0.2 per cent for the permanent dentitions. The incisors (and also the canines in the primary dentition) are most frequently affected and the condition may be bilaterally symmetrical (Fig. 1.11). In the primary dentition the majority of cases involve the anterior mandibular teeth.

Concrescence

Concrescence is an acquired disorder in which the roots of one or more teeth are united by cementum alone after formation of the crowns (Figs 1.5, 1.12). This is most frequently seen in the permanent dentition where the roots of teeth develop close together (for example, between maxillary second and third molars) or following hypercementosis associated with chronic inflammation.

Key points – Double teeth

- developmental anomaly
- teeth usually united by dentine (with or without pulp)
- more common in primary than permanent dentition
- anterior teeth mainly involved

Concrescence

- acquired anomaly
- union by cementum alone following hypercementosis
- more common in permanent than primary dentition

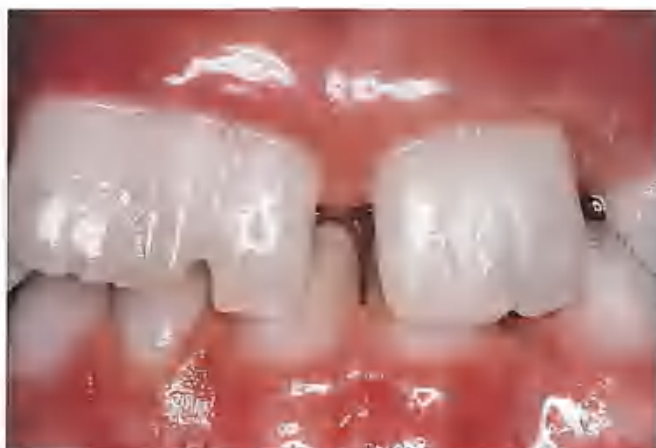

Fig. 1.11 Bilateral double teeth involving the maxillary incisors.



Fig. 1.12 Concrecence of maxillary molars.

Disturbances in structure of teeth

Disturbances in structure of enamel

Enamel normally develops in two stages. In the first, or secretory, stage, the ameloblasts perform the dual function of matrix production and initial mineralization. Matrix production involves the synthesis and secretion of the matrix proteins, amelogenin, enamelin, ameloblastin, and tuftelin, of which amelogenin accounts for about 90 per cent. Initial mineralization occurs immediately after secretion. In the second stage, the maturation stage, there is withdrawal of protein and water from the enamel accompanied by increase in mineral content before the tooth erupts. (see Box 1.3).

Most classifications of disturbances in enamel formation distinguish between those that affect the secretory stage, resulting in deficient matrix production and thin hypoplastic enamel, and those that affect the maturation stage, resulting in deficient mineral deposition and soft hypomineralized enamel. Although this distinction may at times be hard to sustain as some disturbances affect both matrix formation and mineralization, it remains a useful clinical division.

In enamel hypoplasia the ameloblasts fail to produce a normal volume of matrix but any matrix which is produced generally

Key points – Defective amelogenesis

- defective matrix production – enamel hypoplasia
- defective maturation/mineralization – hypomineralized enamel

becomes as fully mineralized as normal enamel. Enamel hypoplasia presents clinically as pits or grooves in the enamel surface, or as a general reduction in the thickness of the whole enamel. The defective enamel has fewer prisms than normal and they may run in abnormal directions. In some cases no prism structure can be seen.

Hypomineralized enamel results from a failure of the ameloblasts to fully calcify the previously formed matrix, and generally such enamel appears clinically as white and opaque. After eruption it may become pigmented buff, orange, or brown and be quickly chipped and worn away. Much of the organic matrix of hypomineralized enamel remains acid-insoluble and is often preserved in sections of decalcified specimens.

Hypoplastic and hypomineralized enamel may result from disturbances affecting a single tooth, a group of teeth, or all of the teeth, and the structure of the enamel formed depends on the severity and duration of the disturbance as well as its nature. Most disturbances of ameloblast function can produce both hypoplasia and hypomineralization, but clinically one type usually predominates in a particular patient.

The classification given in Table 1.2 is based on the aetiology of hypoplastic and hypomineralized enamel. It is not exhaustive but includes the common causes.

Box 1.3 Amelogenesis

In the secretory phase:

- enamel matrix proteins, amelogenin, enamelin, ameloblastin, and tuftelin, are secreted by ameloblast
- matrix proteins are important in the initiation of mineralization and control of crystal growth
- during this phase the crystallites grow mainly in length but little in width or thickness
- amount of matrix produced determines thickness of enamel and crown morphology.

In the maturation phase:

- secretion of matrix proteins ceases
- growth in length of crystallites is terminated
- proteolytic enzymes are secreted which degrade matrix proteins
- crystallites grow in width and thickness as the matrix is removed.

Table 1.2 Aetiology of developmental abnormalities of enamel

Local causes	
Infection	
Trauma	
Radiotherapy	
Idiopathic (enamel opacities)	
General causes	
(a) <i>Environmental/systemic</i>	
(chronological hypoplasias)	
(i) Prenatal	– infections, e.g. rubella, syphilis
	– maternal disease
	– excess fluoride ions
(ii) Neonatal	– haemolytic disease of the newborn
	– hypocalcaemia
	– premature birth/prolonged labour
(iii) Postnatal	– severe childhood infections, especially the viral exanthemata
	– chronic diseases in childhood, e.g. congenital heart disease, gastrointestinal and endocrine diseases
	– nutritional deficiencies, e.g. vitamin D
	– cancer chemotherapy
	– excess fluoride ions
(b) <i>Genetic</i>	
(i) Teeth only affected	– amelogenesis imperfecta
(ii) Teeth affected in association with generalized defects	– ectodermal dysplasia syndromes
	– Down syndrome (trisomy 21)

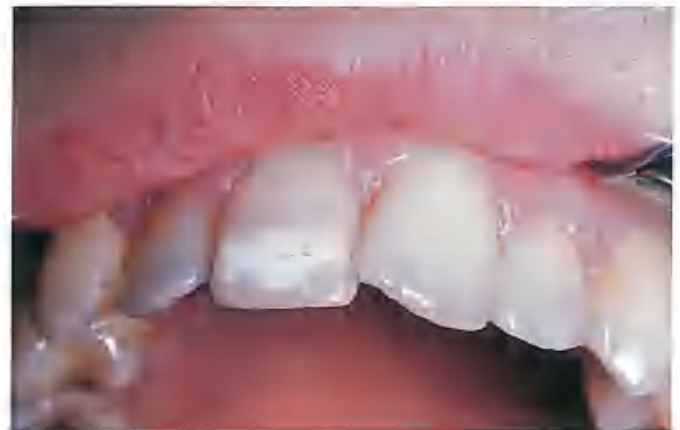Localized causes

Local infection or trauma

Enamel hypoplasia or hypomineralization involving a single tooth is most commonly seen in permanent maxillary incisors, or maxillary or mandibular premolars. The usual cause of these abnormalities is infection or trauma related to the deciduous predecessor resulting in damage to the ameloblasts of the permanent successor. Such teeth are often called Turner teeth. Clinically, the defects range from yellowish or brownish pigmentation of the enamel to extensive pitting and irregularity of the surface, the crowns often being smaller than normal. The yellowish colour is sometimes due to the deposition of cementum on the enamel surface.

Enamel opacities

These are white, opaque spots seen in smooth-surface enamel, some of which become brown-stained after eruption (Fig. 1.13). The opacities are common and are seen in as many as one in three children aged 12–14 years. They have a random distribution, and teeth in both the deciduous and the permanent dentition are affected. The maxillary permanent central incisor is most frequently involved. The cause is not known but the opacities are

**Fig. 1.13** Enamel opacity with early staining.

Key points – Developmental abnormalities of enamel – aetiology

- local causes
- generalized causes
 - environmental/systemic disturbances (chronological hypoplasia)
 - genetically determined

thought to be due to local rather than systemic factors. The prevalence is less in areas with one part per million of fluoride in the drinking water. Histological examination of the enamel shows the opaque spots to be hypomineralized.

Generalized causes

Chronological hypoplasias

Any serious nutritional deficiency or systemic disease occurring during the time of formation of the teeth can lead to enamel hypoplasia or hypomineralization, because ameloblasts are amongst the most sensitive cells in the body in terms of metabolic requirements. Such time-related disturbances are called chronological hypoplasia and most enamel hypoplasias due to environmental causes are of this type. A pitting type of hypoplasia usually results (Fig. 1.14), although ridging and grooving may also be seen, and the disturbance produces a horizontal band of hypoplasia, the distribution of which is related to that enamel which was forming at the time of the disturbance (Fig. 1.15). Thus a disturbance occurring at or soon after birth may affect the incisal edges of the permanent central incisors and the occlusal surfaces of the first permanent molars in addition to the deciduous teeth (Fig. 1.16).

Congenital syphilis

This disease produces characteristic hypoplastic changes in the enamel of permanent incisors and first molars due to infection of

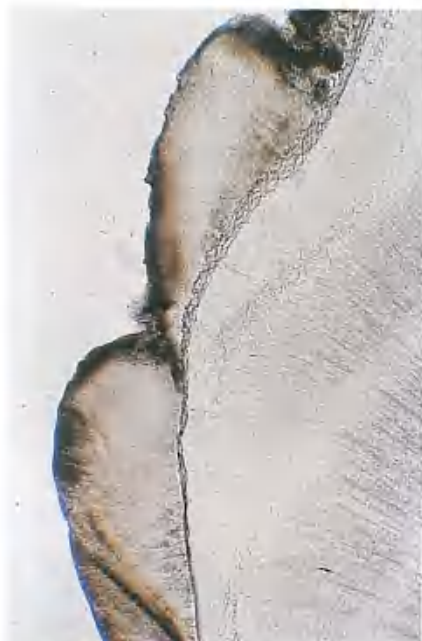

Fig. 1.14 Ground section of tooth with pitting of enamel due to chronological hypoplasia.

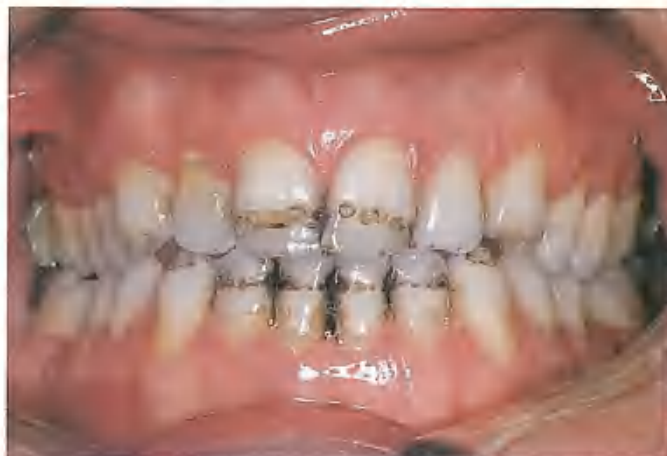

Fig. 1.15 Chronological hypoplasia of enamel associated with measles in early childhood.

the tooth germ by spirochaetes. The mesial and distal surfaces of the incisors taper towards the incisal edges rather than toward the cervical margin, giving a 'screw-driver' appearance, and the incisal edges usually have a central notch (Hutchinson's incisors) (see Chapter 11). These changes are most obvious in the maxillary central incisors. The occlusal surfaces and occlusal thirds of the crowns of the first molars are covered by small globular masses of enamel (Moon's molars or mulberry molars).

Fluoride ions

Ingestion of excess fluoride during the period of tooth formation may result in dental fluorosis, producing hypomineralized or

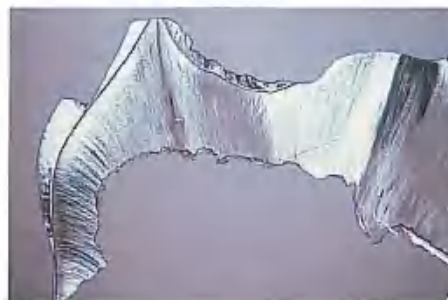

Fig. 1.16 Enamel hypoplasia associated with neonatal hypocalcaemia. A prominent step-like defect separates the thin prenatal enamel from the normal postnatal enamel following restoration of normal calcium levels. Ground section of a deciduous molar viewed with polarized light.

hypoplastic enamel. The development of fluorosis is dependent on the total amount of fluoride ingested from all sources and the duration and timing of exposure. The early maturation phase of enamel formation appears particularly sensitive whereas the secretory phase is the least sensitive. Clinically, dental fluorosis is characterized by faint white flecking of the enamel, white patches or

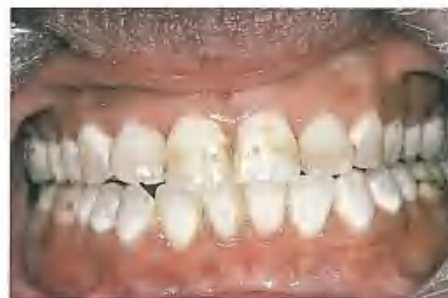

Fig. 1.17 Dental fluorosis.

Key points – Chronological hypoplasias; dental fluorosis

Chronological hypoplasias

- time related
- horizontal bands of pitting of enamel
- distribution of bands and tooth involvement reflect the chronology of tooth development

Dental fluorosis

- effects dependent on dose, duration, and timing of exposure
- mottled appearance of the teeth, usually widespread throughout the dentition
- hypomineralization of subsurface enamel; hypoplastic pitting in severe cases

striations, or in more severe cases by yellow or brownish-black discoloration, particularly in teeth most exposed to light. The term 'mottling' is often used to describe the appearances of dental fluorosis (Fig 1.17). Varying degrees of hypoplasia of the enamel may also be seen. The severity of the lesions varies from tooth to tooth and between different areas of an individual tooth, reflecting variations in exposure and in the susceptibility of different phases of enamel formation with time. They are found mainly in the permanent dentition but the deciduous teeth may be involved in severe cases and in areas of endemic fluorosis.

Amelogenesis imperfecta

Amelogenesis imperfecta is a group of hereditary conditions affecting enamel formation. It is usually classified into two major and clinically distinct types depending on whether the abnormality is related to defective matrix production (hypoplastic type) or defective mineralization (hypomineralized/hypomaturation type). Within this broad division many subtypes have been described based on the modes of inheritance and clinical manifestations. It can be inherited as autosomal dominant, autosomal recessive or X-linked forms. Most cases of amelogenesis imperfecta are inherited as autosomal dominant or, less frequently, X-linked traits.

The patterns of inheritance are not related to particular variations in the clinical manifestations (phenotype). However, as the molecular basis for enamel formation is becoming better understood (see Box 1.3) the corresponding genes are being identified. Mutations in these genes have been associated with amelogenesis imperfecta and in the future it may be possible to correlate specific genotypes with particular phenotypes. Amelogenin, the most abundant of the enamel matrix proteins, has been most extensively studied and is coded for by genes on both the X and the Y chromosomes. However, the gene on the X chromosome (AMELX gene) accounts for the great majority of the protein synthesized. The genes for ameloblastin, enamelin, and tuftelin have also been localized and mutations in these are linked to autosomal patterns of inheritance of amelogenesis imperfecta (see Box 1.4). All types of amelogenesis imperfecta affect the deciduous and permanent dentitions and most of the enamel on all of the teeth is involved.

Box 1.4 Genes encoding enamel proteins

- Amelogenin genes are found on both X and Y chromosomes but that on the X (AMELX gene) accounts for about 90 per cent of RNA transcripts.
- Ameloblastin and enamelin are located on the long arm of chromosome 4 (4q).
- Ameloblastin and enamelin are localized to a critical region on 4q where several dentine and bone extracellular matrix genes are also localized.
- Tuftelin is localized to the long arm of chromosome 1 (1q).

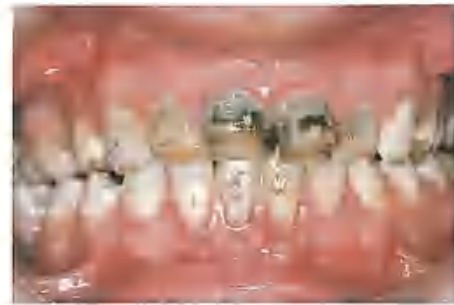

Fig. 1.18 Amelogenesis imperfecta, hypomineralized type.

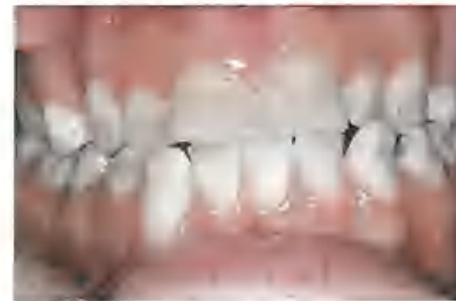

Fig. 1.19 Amelogenesis imperfecta, hypoplastic type with generalized roughening of the enamel.

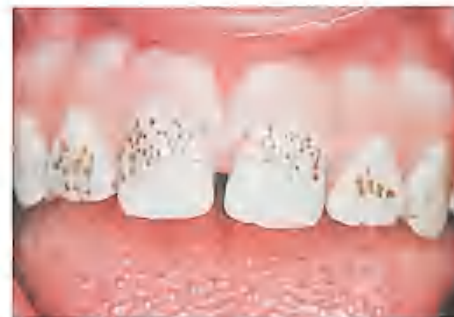

Fig. 1.20 Amelogenesis imperfecta, hypoplastic type with generalized pitting of the enamel.

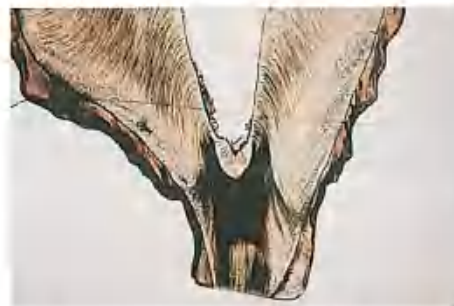

Fig. 1.21 Amelogenesis imperfecta, hypoplastic type. Ground section showing generalized pitting/roughness of the enamel.

The hypomineralized/hypomaturation type is the most common form. Newly erupted teeth appear normal in size and shape and have enamel of normal thickness. However, the enamel is of a soft chalky consistency (Fig. 1.18) and exhibits variable white, opaque to mottled brownish-yellow appearances. Because of the deficient mineralization the enamel has a similar density to dentine on radiographs. It is rapidly lost by abrasion and attrition exposing the dentine. Gross attrition may result in the teeth being worn down to gum level.

In the hypoplastic types of amelogenesis imperfecta the enamel does not reach normal thickness and there is considerable variation in clinical appearances. In some cases, localized areas of hypoplasia are randomly distributed over the surface of the

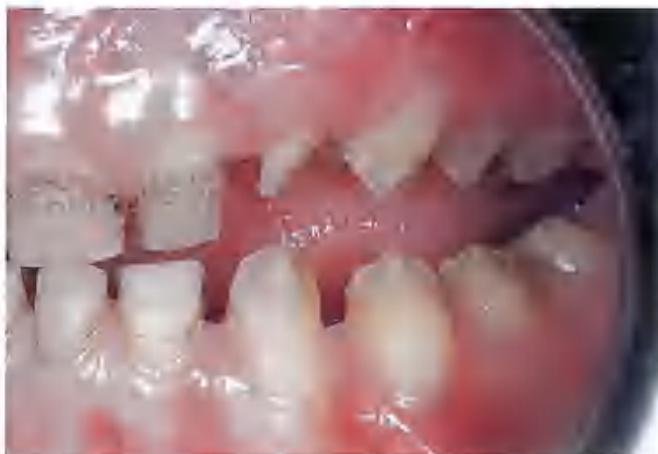

Fig. 1.22 Amelogenesis imperfecta, hypoplastic type, smooth form.

Key points – Amelogenesis imperfecta

- hypomineralized/hypomaturation and hypoplastic types
- autosomal dominant pattern of inheritance the most common for both types
- X-linked forms associated with mutations in the amelogenin (AMELX) gene
- mutations in genes coding for other enamel proteins linked to autosomal patterns of inheritance

Hypomineralized/hypomaturation type

- normal tooth morphology when first erupt
- soft chalky enamel easily lost, exposing dentine
- teeth prone to attrition, sometimes severe

Hypoplastic type

- enamel of normal hardness but of variable thickness
- considerable variation in clinical appearances
- variable pitting/vertical grooving/generalized thinning
- teeth may appear small/show abnormal cuspal morphology

enamel producing generalized roughness and pitting or irregular vertical grooving and wrinkling (Figs 1.19–1.21). In the smooth form, the enamel over the whole of the crown is affected and the teeth have sharp, needle-like cusps (Fig. 1.22). The enamel is very thin but hard and glassy. It lacks a normal prismatic structure and may be laid down in incremental bands parallel to the surface.

In the X-linked form, heterozygous females are less severely affected than males or homozygous females and tend to show alternating irregular vertical bands of normal and defective enamel, reflecting the random inactivation of one or other of the X chromosomes in different groups of ameloblasts (Lyonization effect).

Disturbances in structure of dentine

Dentine is the first-formed dental hard tissue, the cells of the internal enamel epithelium inducing the adjacent mesenchymal cells of the dental papilla to differentiate into odontoblasts. Both the odontoblasts and subodontoblastic cells influence the development of the first-formed or mantle dentine, the subodontoblastic cells forming part of the collagenous matrix which is embedded in a ground substance rich in glycosaminoglycans. As more matrix is formed the odontoblasts migrate centripetally and their processes remain in the matrix which begins to mineralize when it is about 5 μm thick. Calcification is initiated by small crystallites (which at first are probably budded from the odontoblasts) and completed by subsequent growth and fusion of discrete globules called calcospherites. Where fusion of calcospherites does not occur, hypomineralized areas of interglobular dentine remain. A layer of uncalcified matrix (predentine) is normally present at the pulpal surface. Peritubular dentine is formed along the internal surfaces of the dentinal tubules throughout life, the tubule diameter being progressively reduced or even obliterated.

Table 1.3 Developmental abnormalities of dentine

Local causes
Trauma, e.g. Turner teeth; radiotherapy
General causes
<i>Dentinogenesis imperfecta</i>
Type I – associated with osteogenesis imperfecta
Type II – teeth only affected (including 'shell-teeth')
Type III – Brandywine isolate
<i>Dentine dysplasia</i>
Type I – radicular dentine dysplasia (rootless teeth)
Type II – coronal dentine dysplasia
<i>Environmental/systemic</i>
Vitamin D-dependent rickets
Vitamin D-resistant rickets (hypophosphataemia)
Hypophosphatasia
Juvenile hypoparathyroidism
Other mineral deficiencies
Drugs, e.g. chemotherapeutic agents

Most of the clinically significant disturbances of dentinogenesis have a genetic aetiology, but some environmental or systemic disturbances affecting calcium metabolism or calcification may also produce abnormal dentine. The developmental abnormalities of dentine are listed in Table 1.3. Many are rare.

Dentinogenesis imperfecta (hereditary opalescent dentine)

Three types of dentinogenesis imperfecta are recognized: type I, which is associated with osteogenesis imperfecta; type II, where only the teeth are affected; and type III, which only occurs in a rare racial isolate in the USA. Type II is the commonest type.

Dentinogenesis imperfecta type II is an autosomal dominant disorder with variable expressivity and is the most common dental genetic disease, involving approximately 1 in 6000 to 1 in 8000 of the population. It has been mapped to the long arm of chromosome 4 (4q), as have some of the enamel matrix proteins (see Box 1.4), but the gene involved has not yet been isolated. Both the deciduous and permanent dentitions are affected. On eruption the teeth have a normal contour but an opalescent amber-like appearance (Fig. 1.23). Subsequently, they may have an almost normal colour, following which they become translucent, and finally grey or brownish with bluish reflections from the enamel. Although in most cases the enamel is structurally normal, it is rapidly lost and the teeth then show marked attrition (Fig. 1.24).

Radiological examination shows short, blunt roots with partial or even total obliteration of the pulp chambers and root canals by

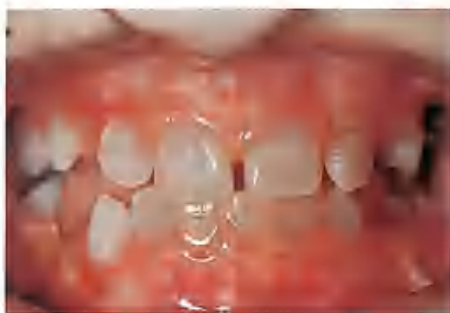

Fig. 1.23 Dentinogenesis imperfecta showing opalescent amber-like appearance of the teeth.

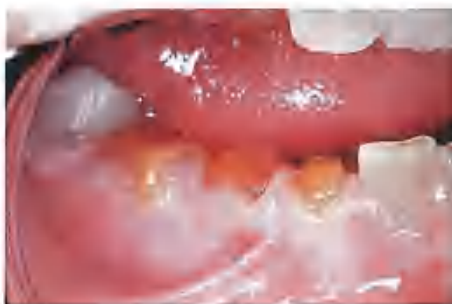


Fig. 1.24 Dentinogenesis imperfecta showing marked attrition of deciduous dentition.

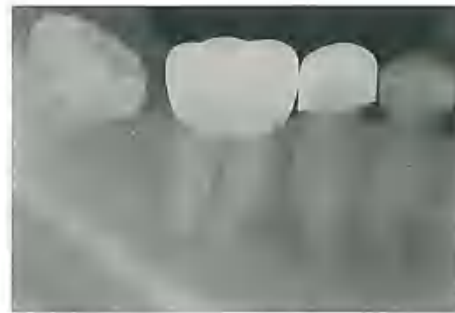

Fig. 1.25 Radiograph of teeth in dentinogenesis imperfecta showing obliteration of the pulp chambers and root canals and stunting of the roots.

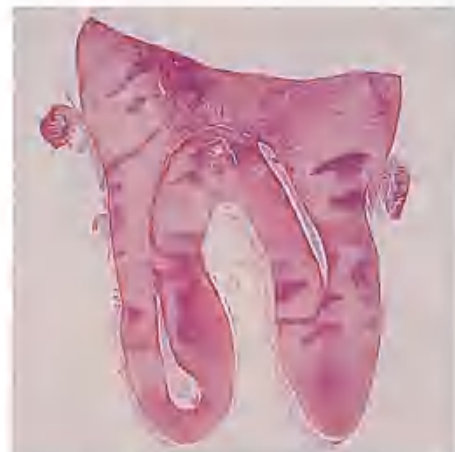

Fig. 1.26 Abnormal dentine in dentinogenesis imperfecta with partial obliteration of the pulp chamber.

dentine (Fig. 1.25). Histological examination shows that apart from a thin layer of normal tubular mantle dentine (i.e. the dentine immediately adjacent to the enamel or cementum), the dentine contains a reduced number of tubules, many of which are wide and irregular, and areas of atubular dentine may be present. This abnormal dentine partly or totally obliterates the pulp chamber and root canal (Fig. 1.26). Vascular inclusions are often found in the dentine, representing remnants of odontoblasts and pulp tissue.

Analysis of the dentine shows an increased water content and a decreased mineral content when compared with normal dentine. The microhardness of the dentine is low, explaining the rapid attrition of the teeth which occurs following loss of enamel. The latter may be due to the abnormal physical properties of the dentine which render it less able to withstand distortional forces. Caries is unusual in affected teeth, presumably due to the reduced number of invasion pathways in the dentine, with the caries being confined to the superficial layers which are quickly worn away. The pulp cavities in deciduous teeth may not be obliterated, the dentine may remain thin and the pulps may become exposed by attrition (see 'shell-teeth' below).

Key points – Dentinogenesis imperfecta

Type I

- associated with osteogenesis imperfecta
- genetically distinct from dentinogenesis type II
- primary dentition more severely affected than permanent
- appearances in the primary dentition as for type II

Type II

- autosomal dominant, affecting teeth only
- primary and permanent dentition affected
- discoloration of teeth, opalescent amber-like appearance
- marked attrition following loss of enamel
- pulp obliteration and stunted roots
- abnormal dentine structure and composition.

Type III

- rare racial isolate in USA
- closely related to type II

Dentinogenesis type I is associated with osteogenesis imperfecta (see Chapter 16 and Fig 16.2) and although the two conditions are closely related they are genetically distinct. In many patients with osteogenesis imperfecta the appearances of the teeth in the primary dentition are indistinguishable from those seen in dentinogenesis type II. However, the involvement of the permanent dentition in type I (associated with osteogenesis imperfecta) is very variable and tooth discoloration and attrition do not occur to the same extent.

A similar appearance is seen in dentinogenesis type III which occurs in a particular racial isolate group in southern Maryland, USA (the Brandywine isolate). Genetic studies have shown that type III overlaps with the same region on chromosome 4 as type I, but it is not yet known whether they are genetically distinct or represent variable expression of disease in different groups of patients.

Dental dysplasia

Two forms of this rare autosomal dominant disease are described. In type I (rootless teeth) the permanent teeth have normal crowns associated with roots composed of dysplastic dentine containing numerous calcified, spherical bodies. The pulp chamber and root canals are largely obliterated and the roots are usually very stunted. The abnormality is due to a defect in Hertwig's root sheath which fragments and is incorporated into the dental papilla where it induces formation of fused globular masses of abnormal dentine. The first sign may be premature exfoliation either spontaneously or with minor trauma.

Type II dental dysplasia (coronal dentine dysplasia) may not be a distinct entity. It has been linked to the same area on chro-

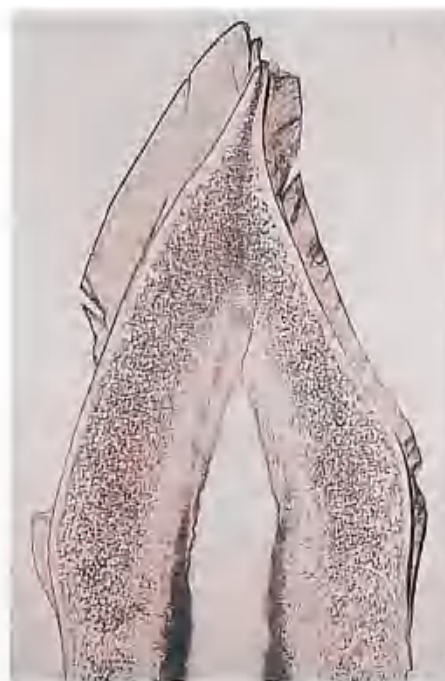

Fig. 1.27 Ground section of a tooth from a patient with hypophosphataemia showing prominent interglobular dentine.

somosome 4 as dentinogenesis imperfecta type II. The appearances in the primary dentition are the same but the permanent teeth are of normal colour and root length.

Metabolic disturbances affecting dentinogenesis

In the active phase of rickets the width of the predentine is increased and the recently formed dentine is incompletely calcified. Subsequently, bands and areas of interglobular dentine corresponding to the period of illness are seen in the dentine. Pronounced interglobular dentine is also a feature of vitamin D-resistant rickets (hypophosphataemia) (Fig. 1.27), but large pulp chambers and long pulp horns which may extend as clefts to the amelodentinal junction are also seen. The overlying enamel may also be cracked or defective allowing direct access of bacteria to the pulp, resulting in pulpitis and periapical sequelae without carious attack. Increased amounts of interglobular dentine and widening of the predentine may be seen in other environmental disorders affecting mineralization such as hypophosphatasia (see also hypocementosis) and nutritional deficiencies. The effects of drugs vary with the nature of the drug and period of administration. Cytotoxic agents often produce increased prominence of incremental lines coinciding with drug administration.

The teeth in juvenile hypoparathyroidism may be small with hypoplastic enamel. The roots may be stunted and there may be structural abnormalities in the radicular dentine.

Regional odontodysplasia (ghost teeth)

This is an uncommon developmental disorder of unknown aetiology associated with abnormalities of enamel, dentine, pulp, and

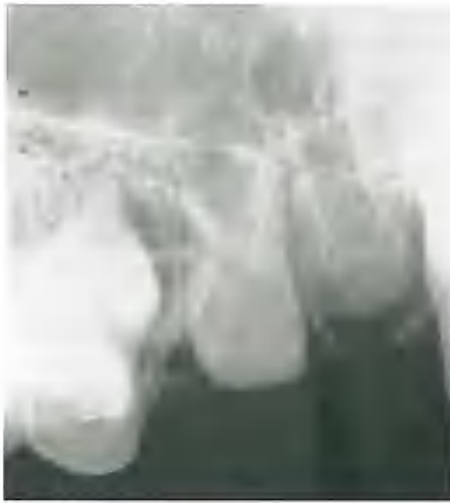

Fig. 1.28 Radiograph of anterior maxillary teeth in regional odontodysplasia showing their ghostly appearance.

the dental follicle. Both deciduous and permanent dentitions are affected and the number of teeth and number of quadrants involved varies. The defect occurs most frequently in the anterior part of the maxilla and is usually unilateral.

The teeth are delayed in eruption and generally have a very irregular shape with hypoplastic and irregularly mineralized enamel. The dentine is thinner than normal, hypomineralized, and contains large areas of interglobular dentine. Radiological examination shows reduced radiopacity of the teeth with loss of distinction between the enamel and dentine, described as a 'ghostly' appearance (Fig. 1.28).

Disturbances in structure of cementum

The coronal third of the root is normally covered only by a narrow layer of acellular (primary) cementum, whereas the apical two-thirds and furcation areas are covered by an additional thicker layer of cellular (secondary) cementum. Cellular cementum continues to be formed throughout the life of the tooth and typically shows incremental lines of growth. The thickness of the cementum varies considerably between individuals, but generally increases with age and to compensate for occlusal wear.

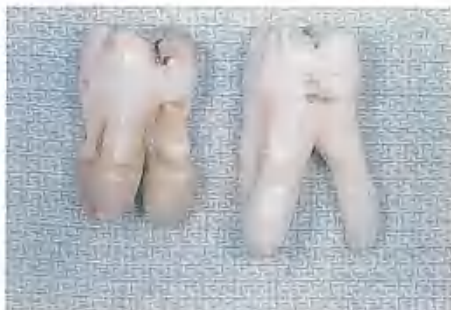

Fig. 1.29 Hypercementosis of maxillary molars.

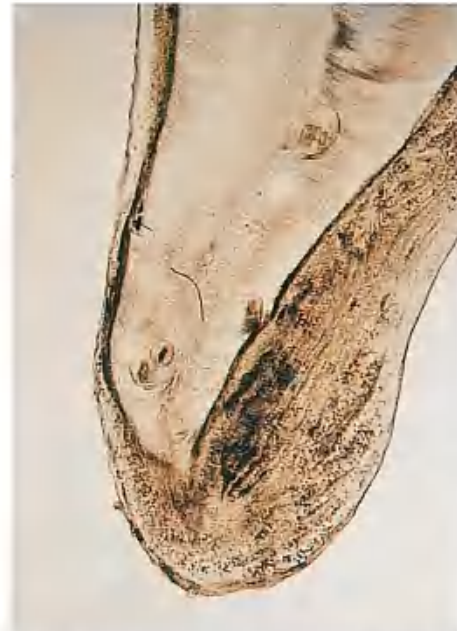

Fig. 1.30 Ground section of a tooth root showing hypercementosis.

Hypercementosis

Hypercementosis (Figs 1.29, 1.30) may be idiopathic or the result of local or general disorders. It may affect one or several teeth and may be associated with root ankylosis, when cementum is directly continuous with the alveolar bone, or with concrecence (see Fig. 1.12). Some causes are given below.

PERIAPICAL INFLAMMATION

Although resorption of cementum may occur close to the centre of the inflammatory focus, apposition of cementum may be stimulated a little further away. This produces a generalized thickening of the cementum or a localized knob-like enlargement.

MECHANICAL STIMULATION

Excessive forces applied to a tooth may produce resorption, but mechanical stimulation below a certain threshold may stimulate apposition of cementum (Fig. 1.31).

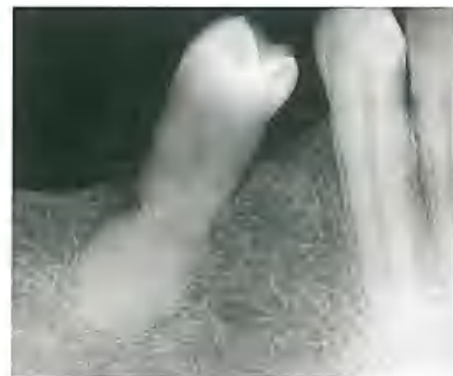

Fig. 1.31 Hypercementosis associated with mechanical stimulation.



Fig. 1.32 Decalcified section through a root showing aplasia of cementum associated with hypophosphatasia.

FUNCTIONLESS AND UNERUPTED TEETH

Such teeth may show areas of cementum resorption, but excessive apposition of cementum may also occur. In unerupted teeth the cementum may even extend over the surface of the enamel if the reduced enamel epithelium is lost:

PAGET'S DISEASE OF BONE

Hypercementosis is often seen in teeth of patients with Paget's disease, the thickened cementum showing a mosaic appearance analogous to that seen in the bone. The cementum forms irregular masses and ankylosis is common (see Fig. 16.35).

Hypocementosis

Hypoplasia and aplasia of cementum are uncommon. In cleidocranial dysplasia there is a lack of cellular cementum following the deposition of acellular cementum. Aplasia of cementum is seen in hypophosphatasia (Fig. 1.32); a recessive autosomal disease, characterized by a reduced serum alkaline phosphatase level and skeletal abnormalities. Premature loss of some or all deciduous and permanent teeth is seen. Dentine formation may also be abnormal.

Craniofacial anomalies

A bewildering array of craniofacial anomalies and associated syndromes have been, and continue to be, identified. The majority have a genetic basis and with the recent advances in molecular genetics the mechanisms underlying some of these conditions are being discovered. Many appear to be associated with abnormali-

ties in the developmental genes, their signalling molecules, receptors, and transcription factors, as discussed previously in relation to hypodontia (see Box 1.1). Examples include cleidocranial dysplasia (see Chapter 16) in which there is mutation of a master control gene of osteoblast function, and Crouzon syndrome (see Table 1.1) in which there is mutation of a fibroblast growth factor receptor gene. However, others, particularly orofacial clefts (clefts of the lip and/or palate), have a multifactorial aetiology involving the interplay of genetic and environmental factors.


Orofacial clefts are amongst the commonest of all congenital structural birth defects and may occur alone or in combination with over 300 syndromes, although about 70 per cent are non-syndromic in type. The prevalence varies in different parts of the world but ranges from about 1 in 500 to about 1 in 1000 births in most cases. There is a higher incidence of clefts of the lip and palate compared with clefts of the palate alone and there is a family history in about 30% of the former and 15% of the latter.

About 20 possible (or candidate) genes have been suggested from different studies and although some occur more frequently than others, those associated with increased risk have still to be confirmed. In addition, clefts have also been associated with environmental factors, for example smoking, alcohol, and folic acid deficiency, but study of the interplay of these with genetic factors is at an early stage.

Further reading

- Aldred, M. J. and Crawford, P. J. (1995). Amelogenesis imperfecta – towards a new classification. *Oral Diseases*, 1, 2–5.
- Crawford, P. J. M. and Aldred, M. J. (1989). Regional odontodysplasia: a bibliography. *Journal of Oral Pathology and Medicine*, 18, 251–63.
- Den Besten, P. K. (1999). Biological mechanisms of dental fluorosis relevant to the use of fluoride supplements. *Community Dentistry and Oral Epidemiology*, 27, 41–7.
- Derijcke, A., Eerens, A., and Carels, C. (1996). The incidence of oral clefts: a review. *British Journal of Oral and Maxillofacial Surgery*, 34, 488–94.
- Deutsch, D., Catalano-Sherman, J., Dafni, L., David, S., and Palmon, A. (1995). Enamel matrix proteins and ameloblast biology. *Connective Tissue Research*, 32, 97–107.
- Fearne, J. M., Bryan, E. M., and Brook, A. H. (1990). Enamel defects in the primary dentition of children born weighing less than 2000g. *British Dental Journal*, 168, 433–7.
- Forsman, K., Lind, L., Backman, B., Westermark, E., and Holmgren, G. (1994). Localization of a gene for autosomal dominant amelogenesis imperfecta (ADAI) to chromosome 4q. *Human Molecular Genetics*, 3, 1621–5.
- Hillman, G. and Guertzen, W. (1996). Pathohistology of undecalcified primary teeth in vitamin D-resistant rickets: review and report of two cases. *Oral Surgery, Oral Medicine, Oral Pathology, Oral Radiology, and Endodontics*, 82, 218–24.
- Irthagarun, A. and King, N. M. (1997). Ectodermal dysplasia: a review and case report. *Quintessence International*, 28, 595–602.

- Kupietzsky, A. and Houpt, M. (1995). Hypohidrotic ectodermal dysplasia: characteristics and treatment. *Quintessence International*, 26, 285–91.
- Kurisu, K. and Tabata, M. J. (1997). Human genes for dental anomalies. *Oral Diseases*, 3, 223–8.
- O'Connell, A. C. and Marini, J. C. (1999). Evaluation of oral problems in an osteogenesis imperfecta population. *Oral Surgery, Oral Medicine, Oral Pathology, Oral Radiology, and Endodontics*, 87, 189–96.
- Pirinen, S. (1998). Genetic craniofacial aberrations. *Acta Odontologica Scandinavica*, 56, 356–9.
- Robinson, C., Brookes, S. J., Shore, R. C., and Kirkham, J. (1998). The developing enamel matrix: nature and function. *European Journal of Oral Sciences*, 106 (Suppl 1.1), 282–91.
- Schutte, B. C. and Murray, J. C. (1999). The many faces and factors of orofacial clefts. *Human Molecular Genetics*, 8, 1853–9.
- Schuurs, A. H. and van Loveren, C. (2000). Double teeth: a review of the literature. *Journal of Dentistry for Children*, 67, 313–25.
- Simmer, J. P. (2001). Dental enamel formation and its impact on clinical dentistry. *Journal of Dental Education*, 65, 896–905.
- Slavkin, H. C. (1999). Entering the era of molecular dentistry. *Journal of the American Dental Association*, 130, 413–7.
- Thesleff, I. (1998). The genetic basis of normal and abnormal craniofacial development. *Acta Odontologica Scandinavica*, 56, 321–5.
- Thesleff, I. (2003). Developmental biology and building a tooth. *Quintessence International*, 34, 613–20.
- Townsend, G. C., Aldred, M. J., and Bartold, P. M. (1998). Genetic aspects of dental disorders. *Australia Dental Journal*, 43, 269–86.
- Vastardis, H. (2000). The genetics of human tooth agenesis: new discoveries for understanding dental anomalies. *American Journal of Orthodontics and Dentofacial Orthopedics*, 117, 650–6.
- Winter, G. B. (1997). Anomalies of tooth formation and eruption. In *Paediatric dentistry* (ed. R. R. Welbury), pp. 255–80. Oxford University Press. Oxford.
- Zhu, J. E., Marcushamer, M., King, D. L., and Henry, R. J. (1996). Supernumerary and congenitally absent teeth: a literature review. *Journal of Clinical Pediatric Dentistry*, 20, 87–95.



Dental caries

AETIOLOGY OF DENTAL CARIES

Role of bacteria and dental plaque

Microbiology of dental caries

Role of carbohydrates

Aetiological variables

PATHOLOGY OF DENTAL CARIES

Classification by site of attack

Classification by rate of attack

Enamel caries


Dentine caries

Root caries

Arrested caries

IMMUNOLOGICAL ASPECTS OF DENTAL CARIES

FURTHER READING



Dental caries

Loss of tooth substance may result from the action of oral microorganisms as in dental caries, or be due to non-bacterial causes. The latter include mechanical factors associated with attrition and abrasion, chemical erosion, and pathological resorption.

Dental caries may be defined as a bacterial disease of the calcified tissues of the teeth characterized by demineralization of the inorganic and destruction of the organic substance of the tooth. It is a complex and dynamic process involving, for example, physicochemical processes associated with the movements of ions across the interface between the tooth and the external environment, as well as biological processes associated with the interaction of bacteria in dental plaque with host defence mechanisms.

Dental caries has been recognized throughout history and exists around the world, although the prevalence and severity varies in different populations. In western industrialized countries there was a sharp increase in disease activity in the first half of the twentieth century, but during the 1970s and 1980s the prevalence of dental caries in children fell steadily, particularly following the widespread use of fluoride-containing toothpastes. The reduction was much greater for smooth surface as opposed to occlusal caries, which now accounts for most of the lesions seen in children. Epidemiological studies have shown that the decline in prevalence is continued into adult life and, as a result, more people are retaining more teeth for much longer than before. This reflects the increase in the prevalence of root surface caries as people grow older.

Despite the encouraging and sustained reduction in dental caries in industrialized countries, the prevalence is increasing in certain developing countries and is associated with urbanization and the increased availability of refined carbohydrates.

Aetiology of dental caries

Various theories for the aetiology of dental caries have been proposed, but there is now overwhelming support for the acidogenic theory. This theory, which has remained virtually unchanged since first postulated by W. D. Miller in 1889, proposes that acid formed from the fermentation of dietary carbohydrates by oral bacteria leads to a progressive decalcification of the tooth substance with a subsequent disintegration of the organic matrix (Fig. 2.1). Some of the evidence supporting the acidogenic theory is discussed below.

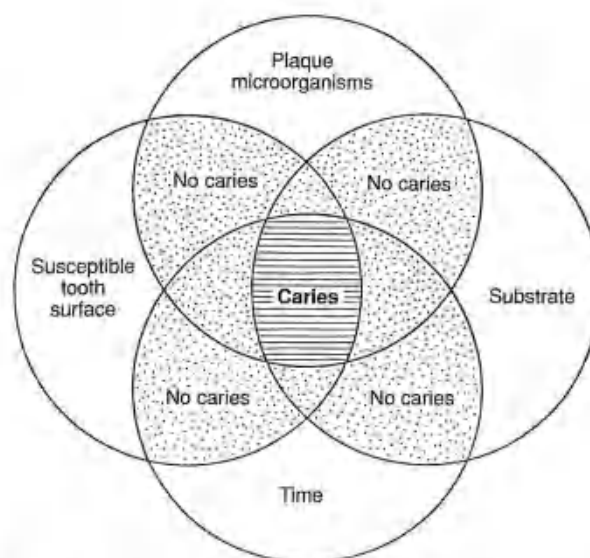


Fig. 2.1 Diagrammatic representation of the parameters involved in the aetiology of dental caries.

Role of bacteria and dental plaque

Experiments with germ-free animals have shown that bacteria are essential for the development of dental caries. Bacteria are present in dental plaque which is found on most tooth surfaces. Dental plaque is a biofilm consisting of a variety of different species of bacteria embedded in a matrix derived from salivary mucins and extracellular polysaccharide polymers (glucans and fructans) synthesized by the organisms.

A clean enamel surface is covered in a few seconds by an adsorbed layer of molecules comprising mainly glycoproteins from saliva, the acquired pellicle, to which microorganisms initially adhere. As they multiply and synthesize extracellular matrix polymers other bacteria may bind to them, rather than to the pellicle, resulting in a complex biofilm of spatially arranged species. The close proximity of different species allows for a variety of synergistic or antagonistic interactions. In a healthy mouth the bacterial composition of the plaque varies at different sites on the teeth, reflecting the different microenvironments available for colonization.

Dietary sugars diffuse rapidly through plaque where they are converted to acids (mainly lactic acid but also acetic and propionic

acids) by bacterial metabolism. The pH of the plaque may fall by as much as 2 units within 10 minutes after the ingestion of sugar, but over the next 30 to 60 minutes the pH slowly rises to its original figure, due to the diffusion of the sugar and some of the acid out of the plaque, and the diffusion into the plaque of buffered saliva which helps to dilute and neutralize the acid. At the critical pH of 5.5 mineral ions are liberated from the hydroxyapatite crystals of the enamel and diffuse into the plaque. The pH curves of plaque in response to sugar (Stephan's curves) are similar in shape in caries-free and caries-active individuals. However, since the starting pH may be lower in caries-active mouths, the reduction in pH will be greater and the pH will be depressed below the critical level for a greater period of time. At a neutral or slightly alkaline pH the plaque becomes supersaturated with mineral ions derived both from the saliva and from those released from the hydroxyapatite crystals. Ions may now diffuse back into enamel and be redeposited in the crystal structure and this reprecipitation of mineral is aided by fluoride ions.

There is, therefore, a see-sawing of ions across the plaque-enamel interface as the chemical environment within the plaque changes (Fig. 2.2). However, mineral ions may be lost from the system by diffusion out of the plaque and into the saliva during the acid phase, and repeated episodes lead to an overall demineralization and the initiation of enamel caries. Obviously the frequency and duration of the acid phase of plaque will affect the rate of development of caries, and this is why the reduction of carbohydrate intake between meals has such a beneficial effect in caries prevention. Once enamel caries has progressed to cavity formation, the plaque becomes progressively more removed from saliva and probably remains acidic for longer periods. Many plaque bacteria store carbohydrate as an intracellular glycogen-like polysaccharide which may be formed from a variety of sugars, and this may be broken down to acid when other sources of carbohydrate are absent, such as between meals. In addition, as mentioned

above, plaque organisms can synthesize extracellular glucans from dietary sugars which may also be metabolized to acid when other sources of carbohydrate are absent. However, abundant extracellular polysaccharides have other important consequences in that they markedly increase the bulk of the plaque, thereby interfering with the outward diffusion of acids and the inward diffusion of saliva and its buffering systems. Such plaques are likely to be more cariogenic because they favour retention of acid at the plaque-enamel interface.

Fluoride ions are present in relatively high concentration in plaque compared with saliva. Fluoride favours the precipitation of calcium and phosphate ions from solution, and so when present at the plaque-enamel interface the deposition of free mineral ions in the plaque as hydroxy- and fluorapatite on the remaining enamel crystals is encouraged. Fluorapatite crystals may also be formed during enamel development if fluorides have been administered systemically (for example by water fluoridation). Fluorapatite is less soluble in acid than hydroxyapatite. Systemic fluoride also promotes the formation of hydroxyapatite crystals with a more stable crystal lattice. Fluoride ions in plaque inhibit bacterial metabolism and this provides an additional mechanism for the preventive action of fluoride in enamel caries.

Microbiology of dental caries

Acid is a general product of bacterial metabolism and no single bacterial species is uniquely associated with the development of enamel caries. Members of the 'mutans streptococci' group are the most efficient cariogenic organisms in animal experiments, and epidemiological data in humans indicates an association between the presence of *S. mutans* and *S. sobrinus* in plaque and the prevalence of caries. Some of the factors supporting an aetiological role for *S. mutans* in dental caries are summarized in Table 2.1. However, caries of enamel may develop in the absence of *S. mutans* and in some individuals high levels of *S. mutans* may be present on a tooth surface without the subsequent development of caries. Nevertheless, there is now a wealth of evidence from animal and human studies that the mutans streptococci, especially *S. mutans*, play a key role in the initiation of caries. Other bacteria, for example lactobacilli, may be important in the further progression

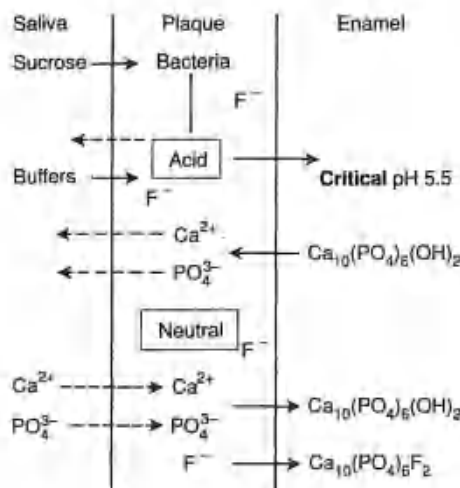


Fig. 2.2 Ionic exchanges at the saliva-plaque-enamel interface. Mineral ions are able to ebb and flow both from the enamel surface into the plaque and vice versa.

Key points – In dental plaque

- cariogenic bacteria ferment carbohydrate to acid
- cariogenic bacteria can store carbohydrate intra and extracellularly
- extracellular polysaccharides increase plaque bulk
- bulky plaques interfere with outward diffusion of acid and inward diffusion of salivary buffers
- frequent intakes of carbohydrate can depress the pH below the critical level for long periods

Key points – Ionic exchanges in enamel caries

- ions see-saw across the plaque–enamel interface depending on pH
- ions in plaque can be redeposited into the enamel at a neutral pH or lost into the saliva
- enamel caries progresses when the net rate of loss of ions due to acid attack is greater than the net rate of gain due to remineralization
- fluoride ions encourage reprecipitation of minerals into enamel
- fluoride ions can replace hydroxyl ions in hydroxyapatite to form less acid-soluble fluorapatite

Table 2.1 Factors supporting a role for *S. mutans* in the aetiology of dental caries

Rapid generation of acid from sucrose
Synthesis of extracellular polysaccharides
– adhesion to tooth
– increase in plaque bulk
Synthesis of intracellular polysaccharides
– acid production when sucrose absent from diet
Present in high numbers in plaque associated with developing lesions
High numbers at a particular tooth site predispose to subsequent caries
Highly cariogenic in animal models of experimental caries
Immunization against <i>S. mutans</i> reduces caries incidence in animal models

of the lesion. Lactobacilli are also the pioneer organisms in dentine caries (see later).

Since caries occurs occasionally in the absence of *S. mutans* other bacteria can contribute to its development. A range of organisms has been isolated from such sites including several types of non-mutans streptococci, for example those belonging to the mitis, salivarius, anginosus, and sanguinis groups, and lactobacilli and actinomycetes. Although these organisms can induce experimental caries in animals their relative significance in the development of caries in humans is less clear. However, some are moderately acidogenic and as such may contribute to the acid pool of plaque as well as creating an environment favouring colonization by aciduric species such as mutans streptococci and lactobacilli. Because of the strong evidence that *S. mutans* and lactobacilli are major organisms associated with dental caries, simple screening tests to estimate the salivary levels of these bacteria have been developed as predictors of caries activity. However, the results from such tests need to be interpreted in conjunction with the assessment of other risk factors for caries in an individual patient. Infants become colonized by mutans streptococci from

Key points – Microbiology of dental caries

- species strongly implicated
 - mutans streptococci, especially *S. mutans*
 - lactobacilli
- species that may be associated
 - non-mutans streptococci, e.g. mitis group
 - actinomycetes
- transmission of *S. mutans* occurs mainly from mother to child
- low plaque pH favours proliferation of mutans streptococci and lactobacilli
- level of mutans streptococci in plaque increased by sucrose consumption

their mothers, and there is evidence that children of high-risk mothers become colonized at an earlier age and develop more carious lesions than children of low-risk mothers.

Role of carbohydrates

Numerous epidemiological studies have demonstrated a direct relationship between fermentable carbohydrate in the diet and dental caries. The evidence includes:

1. The increasing prevalence of dental caries in developing countries and previously isolated ethnic groups associated with westernization, urbanization, and the increasing availability of sucrose in their diet. Examples include Inuit, native North and South Americans, African tribes, and the rural population in countries in the Far East.
2. The decrease in the prevalence of caries during World War II because of sugar restriction, followed by a rise to previous levels when sucrose became available in the post-war period.
3. The Hopewood House study – a children's home in Australia where sucrose and white bread were virtually excluded from the diet. The children had low caries rates which increased dramatically when they moved out of the home.

Different carbohydrates have different cariogenic properties. Sucrose is significantly more cariogenic than other sugars, partly because it is readily fermented by plaque bacteria and partly because of its conversion by bacterial glucosyl transferase into extracellular glucans. Sucrose is also readily converted into intracellular polymers. Glucose, fructose, maltose, galactose, and lactose are also highly cariogenic carbohydrates in experimental caries in animals, but the principal carbohydrates available in human diets are sucrose and starches. Dietary sugars can be divided into intrinsic (mainly fruit and vegetables) and extrinsic sources (added sugars, milk, fruit juices). Dietary advice recommends that consumption of extrinsic sugars (except milk) should be reduced. Much of the epidemiological data incriminates sucrose. Its relative importance is also well illustrated in patients

Key points – Diet and dental caries

- caries prevalence increases when populations become exposed to sucrose-rich diets
- extrinsic sugars are more damaging than intrinsic sugars
- sucrose is the most cariogenic sugar
- frequency of sugar intake is of more importance than total amount consumed

with hereditary fructose intolerance who cannot tolerate fructose or sucrose (ingestion may lead to coma and death) but who are able to consume starches. Such individuals have little or no caries. Starch solutions applied to bacterial plaque produce no significant depression in pH, due to the very slow diffusion of the polysaccharide into the plaque which must be hydrolysed by extracellular amylase before it can be assimilated and metabolized by plaque bacteria. However, cooked highly refined starches can cause caries, although much less than sucrose. The combination of cooked starch and sucrose together, such as in cakes and biscuits, is more cariogenic than sucrose alone. The main alternative non-sugar sweeteners, sorbitol and xylitol, are, to all intents and purposes, non-cariogenic. Xylitol is not fermented by oral bacteria and sorbitol is only fermented at a very slow rate.

Whilst there is no doubt that there is a direct relationship between dietary carbohydrates and caries, experimental evidence in humans has shown that the manner and form in which the carbohydrate is taken and the frequency of consumption are more important than the absolute amount of sugar consumed. The risk of caries is greatest if sugar is consumed between meals, thus supplying plaque bacteria with (in the case of habitual 'snackers') an almost constant supply of carbohydrate. It is also increased if the sugar is consumed in a sticky form likely to be retained on the surfaces of the teeth.

In children, prolonged sucking of a sweetened pacifier to about 2 years of age or beyond may be associated with rampant caries, involving particularly the smooth surfaces of the anterior maxillary teeth. A similar problem may also be seen in children given sweetened drinks in a nursing bottle, especially at night. Some studies have also shown an association between prolonged breast feeding beyond 2 years of age and extensive caries, but this is controversial as the results from different studies are conflicting.

Aetiological variables

Not all teeth or tooth surfaces are equally susceptible to caries, nor is the rate of progression of carious lesions constant. Factors influencing site attack and rates of progression in dental caries are largely unknown but may include:

Factors intrinsic to the tooth

Enamel composition – There is an inverse relationship between enamel solubility and enamel fluoride concentration. A graded

increase in enamel resistance with age might account for selectivity of site attack.

Enamel structure – Developmental enamel hypoplasia and hypomineralization may affect the rate of progression but not the initiation of caries.

Tooth morphology – Deep, narrow pits and fissures favour the retention of plaque and food.

Tooth position – Malaligned teeth may predispose to the retention of plaque and food.

Factors extrinsic to the tooth

Saliva – Flow rate, viscosity, buffering capacity, availability of calcium and phosphate ions for mineralization, and the presence of antimicrobial agents such as immunoglobulins, thiocyanate ion, lactoferrin, and lysozyme may affect caries pattern.

Diet – The most important factor is the frequency of intake of sugary foods and drinks. Chewing sugar-free gum or eating a small portion of cheese after meals helps protect against dental caries. Phosphates in the diet, either organically bound or inorganic, may also reduce the incidence of caries.

Use of fluoride – In addition to an intrinsic effect, fluoride readily enters bacterial cells and can inhibit enzymes involved in the metabolism of sugar.

Immunity – See later.

Pathology of dental caries

Clinically, dental caries may be classified according both to the location of the lesion on the tooth and to the rate of attack.

Classification by site of attack

Pit or fissure caries

This occurs on the occlusal surfaces of molars and premolars, on the buccal and lingual surfaces of molars, and the lingual surfaces of maxillary incisors. Early caries may be detected clinically by brown or black discoloration of a fissure in which a probe 'sticks'. The enamel directly bordering the pit or fissure may appear opaque, bluish-white as it becomes undermined by caries. Since the widespread use of fluoride-containing dentifrices early occlusal caries has become more difficult to diagnose. Apparently clinically sound enamel can overlay extensive dentine caries because of strengthening of the enamel by the formation of fluorapatite and the ability of fluoride to promote remineralization.

Smooth surface caries

This occurs on the approximal surfaces, and on the gingival third of the buccal and lingual surfaces. Approximal caries begins just below the contact point as a well-demarcated chalky-white opacity of the enamel (Fig. 2.3). At this stage there is no loss of continuity of the enamel surface and the lesion cannot be detected

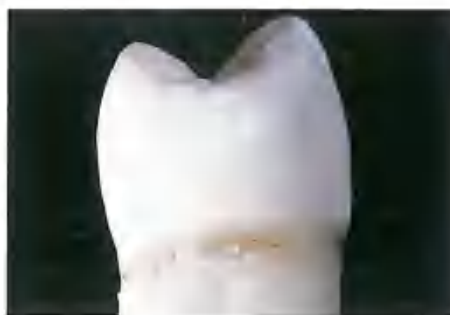

Fig. 2.3 White spot lesion of enamel caries involving an approximal surface of a premolar.

by a probe or on routine radiographs. The white spot lesion may become pigmented yellow or brown and may extend buccally and lingually into the embrasures. As the caries progresses, the surrounding enamel becomes bluish-white. The surface of the lesion becomes roughened before frank cavitation occurs. There are no consistent radiographic features which enable unequivocal identification of enamel lesions that have cavitated from lesions where the surface is still intact. However, lesions with an underlying radiolucency involving half or more of the dentine thickness are always cavitated. For a radiolucency limited to the outer half of the dentine the probability of cavitation ranges from about 40 to 80 per cent in different studies. For radiolucencies limited to the enamel the probability of cavitation in most studies is low and such lesions should be treated by preventive measures and reviewed. Cervical caries extends occlusally from opposite the gingival margin on buccal and lingual tooth surfaces. It has a similar appearance to approximal caries, but almost always produces a wide open cavity.

Cemental or root caries

This occurs when the root face is exposed to the oral environment as a result of periodontal disease. The root face is softened and the cavities, which may be extensive, are usually shallow, saucer-shaped, with ill-defined boundaries.

Recurrent caries

This occurs around the margin or at the base of a previously existing restoration.

Key points – Diagnosis of caries

- early occlusal caries may be difficult to detect
- radiolucencies in approximal enamel that do not reach the amelodentinal junction do not usually indicate enamel cavitation
- approximal lesions which on radiographs do not extend into dentine should be treated by preventive measures

Classification by rate of attack

Rampant or acute caries

This is rapidly progressing caries involving many or all of the erupted teeth, often on surfaces normally immune to caries. The rapid coronal destruction and limited time for the protective responses of the pulpodentinal complex to occur lead to early involvement of the pulp.

Slowly progressive or chronic caries

This is caries that progresses slowly and involves the pulp much later than in acute caries. It is most common in adults and the slow progress allows time for defence reactions of the pulpodentinal complex (sclerosis and reactionary dentine formation) to develop.

Arrested caries

This is caries of enamel or dentine, including root caries, that becomes static and shows no tendency for further progression.

Enamel caries

Ground sections of teeth have been used extensively in histopathological studies of enamel caries and have been examined by transmitted and polarized light, and by microradiography. Electron microscopy and biochemical analysis of microdissected pieces of carious enamel have also been carried out. Most research has concentrated on smooth surface caries to avoid the problems of interpretation of histological features imposed by the anatomy of pits and fissures. However, the pathological features are essentially similar in both sites. The established early lesion (white spot lesion) in smooth surface enamel caries is cone-shaped, with



Fig. 2.4 Ground section through an early carious lesion in enamel showing zonation of the lesion.

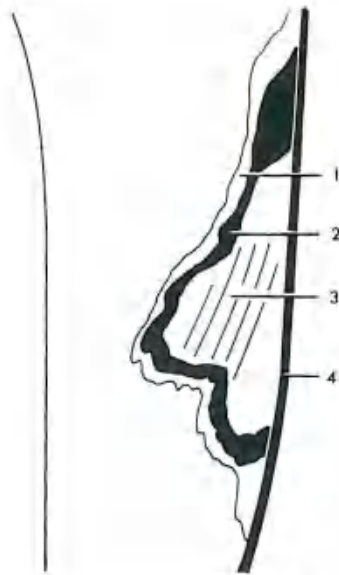

Fig. 2.5 Diagrammatic representation of the lesion in Fig. 2.4 showing: 1, translucent zone; 2, dark zone; 3, body of the lesion; 4, surface zone.

the base of the cone on the enamel surface and the apex pointing towards the amelodentinal junction. The shape is modified in pit and fissure caries (see later). In ground sections it consists of a series of zones, the optical properties of which reflect differing degrees of demineralization (Figs 2.4, 2.5). These zones are described below.

Translucent zone

This is the first recognizable histological change at the advancing edge of the lesion. It is more porous than normal enamel and contains 1 per cent by volume of spaces, the pore volume, compared with the 0.1 per cent pore volume in normal enamel. The pores are larger than the small pores in normal enamel which approximate to the size of a water molecule. Chemical analysis shows that there is a fall in magnesium and carbonate when compared with normal enamel, which suggests that a magnesium- and carbonate-rich mineral is preferentially dissolved in this zone. Dissolution of mineral occurs mainly from the junctional areas between the prismatic and interprismatic enamel. The prism boundaries, which are relatively rich in protein, allow ready ingress of hydrogen ions and the magnesium- and carbonate-rich mineral that is preferentially removed may represent the surface layers of crystallites at the prism boundaries. The translucent zone is sometimes missing, or present along only part of the lesion.

Dark zone

This zone contains 2–4 per cent by volume of pores. Some of the pores are large, but others are smaller than those in the translucent zone, suggesting that some remineralization has occurred due to reprecipitation of mineral lost from the translucent zone. It is thought that the dark zone is narrow in rapidly advancing

lesions and wider in more slowly advancing lesions when more remineralization may occur.

Body of the lesion

This zone (Fig. 2.6) has a pore volume of between 5 and 25 per cent, and also contains apatite crystals larger than those found in normal enamel. It is suggested that these large crystals result from the reprecipitation of mineral dissolved from deeper zones. However, with continuing acid attack there is further dissolution of mineral both from the periphery of the apatite crystals and from their cores. The lost mineral is replaced by unbound water and to a lesser extent by organic matter, presumably derived from saliva and microorganisms. There is increased prominence of the striae of Retzius in the body of the lesion, the explanation for which is unknown.

Surface zone

This is about 40 μm thick and shows surprisingly little change in early lesions (see Fig. 2.6). The surface of normal enamel differs in composition from the deeper layers, being more highly mineralized and having, for example, a higher fluoride level and a lower magnesium level, and so interpretation of possible chemical changes in this zone is difficult. The surface zone remains relatively normal despite subsurface loss of mineral, because it is an area of active reprecipitation of mineral derived both from the plaque and from that dissolved from deeper areas of the lesion as ions diffuse outwards (see Fig. 2.2).



Fig. 2.6 Microradiograph of an early carious lesion in enamel showing loss of mineral from the body of the lesion, prominence of the striae of Retzius, and intact surface zone.

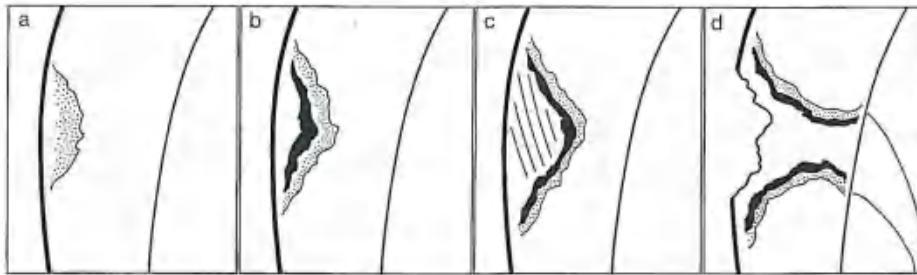


Fig. 2.7 Histopathogenesis of enamel caries: a, subsurface translucent zone; b, development of the dark zone; c, typical zoned structure of the early (white spot) lesion; d, cavitation of the surface, spread along the amelodentinal junction, reactive changes in dentine.

Histopathogenesis of the early lesion

The development of enamel caries can be traced through the following stages when ground sections are examined by transmitted light (Fig. 2.7).

1. Development of a subsurface translucent zone, which is unrecognizable clinically and radiologically.
2. The subsurface translucent zone enlarges and a dark zone develops in its centre.
3. As the lesion enlarges more mineral is lost and the centre of the dark zone becomes the body of the lesion. This is relatively translucent compared with sound enamel and shows enhancement of the striae of Retzius, interprismatic markings, and cross-striations of the prisms. The lesion is now clinically recognizable as a white spot.
4. The body of the lesion may become stained by exogenous pigments from food, tobacco, and bacteria. The lesion is now clinically recognizable as a brown spot.
5. When the caries reaches the amelodentinal junction it spreads laterally, undermining the adjacent enamel, giving the bluish-white appearance to the enamel as seen clinically. Although lateral spread can occur before cavitation (see stage 6), it is more common and more extensive in lesions with cavity formation.
6. With progressive loss of mineral a critical point is reached when the enamel is no longer able to withstand the loads placed upon it and the structure breaks down to form a cavity. This stage may precede stage 5. Caries progression is a slow process and it usually takes several years before cavitation occurs.

Caries in a fissure does not start at the base, but develops as a ring around the wall of the fissure, the histological features of the

lesion being similar to those seen on smooth surfaces. As the caries progresses it spreads outwards into the surrounding enamel and downwards towards the dentine, and eventually coalesces at the base of the fissure (Figs 2.8, 2.9). This produces a cone-shaped lesion, but the base of the cone is directed towards the amelodentinal junction and is not on the enamel surface as in smooth surface caries. The area of dentine ultimately involved is therefore larger than with smooth surface lesions.



Fig. 2.8 Ground section through an early lesion of fissure caries in enamel.

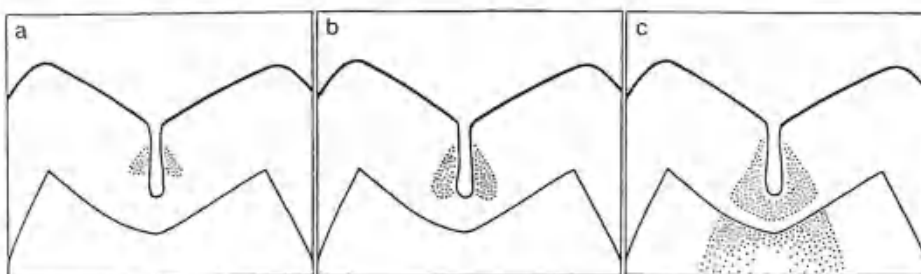


Fig. 2.9 Diagrammatic representation of the development of fissure caries.

Key points – Enamel caries

- a dynamic physicochemical process involving dissolution and reprecipitation of mineral
- caries progression is usually a slow process
- zonation of the early (white spot) lesion reflects different degrees of demineralization
- four zones usually seen: translucent zone (1 per cent loss), dark zone (2–4 per cent loss), body (5–25 per cent loss), surface zone (intact)
- surface zone is an area of active remineralization
- the morphology of the lesion differs in pits and fissures compared with approximal surfaces

Dentine caries

Dentine differs from enamel in that it is a living tissue and as such can respond to caries attack. It also has a relatively high organic content, approximately 20 per cent by weight, which consists predominantly of collagen. In dentine caries it is, therefore, necessary to consider both the defence reaction of the pulpodentinal complex and the carious destruction of the tissue which involves acid demineralization followed by proteolytic breakdown of the matrix. The defence reaction may begin before the carious process reaches the dentine, presumably because of irritation to the odontoblasts transmitted through the weakened enamel, and is represented by the formation of reactionary (or tertiary) dentine and dentinal sclerosis (see later). However, in progressive lesions the defence reaction is progressively overtaken by the carious process as it advances towards the pulp.

Caries of the dentine develops from enamel caries: when the lesion reaches the amelodentinal junction, lateral extension results in the involvement of great numbers of tubules (Fig. 2.10). The early lesion is cone-shaped, or convex, with the base at the amelodentinal junction. Larger lesions may show a broadening of the apex of the cone as it approaches the circumpulpal dentine. In caries of dentine, demineralization by acid is always in advance of the bacterial front, the subsequent bacterial invasion being followed by breakdown of the collagenous matrix.

Key points – Processes in dentine caries

- defence reaction of pulpodentinal complex:
 - sclerosis
 - reactionary dentine formation
 - sealing of dead tracts
- carious destruction:
 - demineralization
 - proteolysis

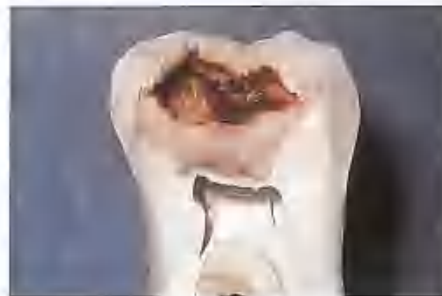

Fig. 2.10 Bisected grossly carious molar. Spread of caries along the amelodentinal junction has resulted in undermining of the enamel.

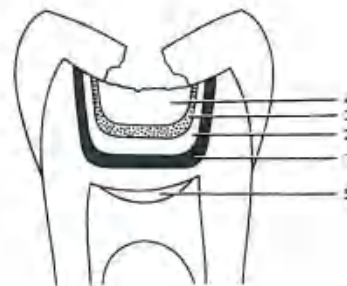


Fig. 2.11 Diagrammatic representation of the zones in established dentine caries: 1, sclerosis; 2, demineralization; 3, bacterial invasion; 4, destruction; 5, reactionary, tertiary dentine beneath the lesion.

Because of the sequential nature of the changes, studies of ground and decalcified sections show a zoned lesion in which four zones are characteristically present (Fig. 2.11).

Zone of sclerosis

The sclerotic or translucent zone is located beneath and at the sides of the carious lesion. It is almost invariably present, being broader beneath the lesion than at the sides, and is regarded as a vital reaction of odontoblasts to irritation. Two patterns of mineralization have been described. The first is the result of acceleration of the normal physiological process of centripetal deposition of peritubular dentine which eventually occludes the tubules. In the second, mineral first appears within the cytoplasmic process of the odontoblasts and the tubule is obliterated by calcification of the odontoblast process itself. Sclerosed dentine therefore has a higher mineral content.

Dead tracts may be seen running through the zone of sclerosis. They are the result of death of odontoblasts at an earlier stage in the carious process. The empty dentinal tubules contain air and the remains of the dead odontoblast process and such tubules can obviously not undergo sclerosis. However, they provide ready access of bacteria and their products to the pulp. To prevent this the pulpal end of a dead tract is occluded by a thin layer of hyaline calcified material, sometimes called eburnoid, which is derived from pulpal cells. Beyond this, further, often very irregular, reactionary dentine may form following differentiation of odontoblasts or odontoblast-like cells from the pulp.

Zone of demineralization

In the demineralized zone the intertubular matrix is mainly affected by a wave of acid produced by bacteria in the zone of bacterial invasion, which diffuses ahead of the bacterial front. The softened dentine in the base of a cavity is therefore sterile but, in clinical practice, it cannot be distinguished reliably from softened infected dentine (see later). It may be stained yellowish-brown as a result of the diffusion of other bacterial products interacting with proteins in dentine.

Zone of bacterial invasion

In this zone the bacteria extend down and multiply within the dentinal tubules (Fig. 2.12), some of which may become occluded by bacteria (Fig. 2.13). There are always, however, many empty tubules lying among tubules containing bacteria. The bacterial invasion probably occurs in two waves: the first wave consisting of acidogenic organisms, mainly lactobacilli, produce acid which diffuses ahead into the demineralized zone. A second wave of mixed acidogenic and proteolytic organisms then attack the demineralized matrix. The walls of the tubules are softened by the proteolytic activity and some may then be distended by the increasing mass of multiplying bacteria. The peritubular dentine is first compressed, followed by the intertubular dentine, resulting in elliptical areas of proteolysis-liquefaction foci. Liquefaction foci run parallel to the direction of the tubules and may be multiple, giving the tubule a beaded appearance (Fig. 2.14). These changes are enhanced in the zone of destruction. The bacteria may show varying degrees of degeneration.

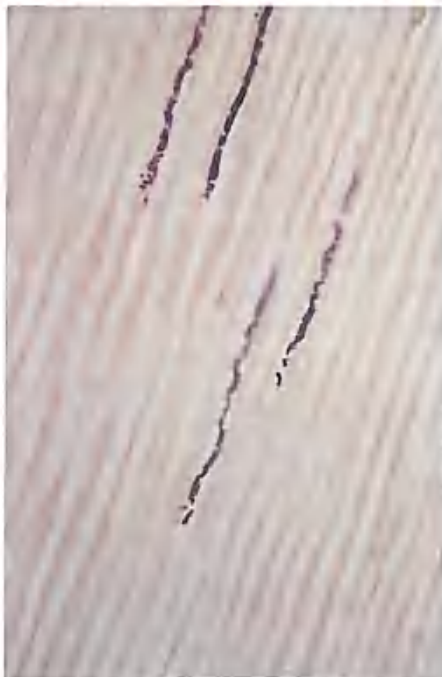

Fig. 2.12 Pioneer organisms at the advancing front of the zone of bacterial invasion in dentine caries.



Fig. 2.13 Packing of the dentinal tubules by bacteria in the zone of bacterial invasion (Gram stain).

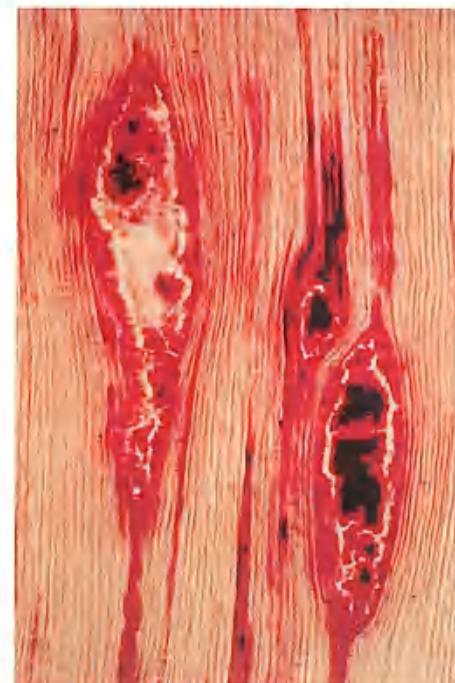


Fig. 2.14 Liquefaction foci in dentine caries.

Zone of destruction

In the zone of destruction the liquefaction foci enlarge and increase in number. Cracks or clefts containing bacteria and necrotic tissue also appear at right angles to the course of the

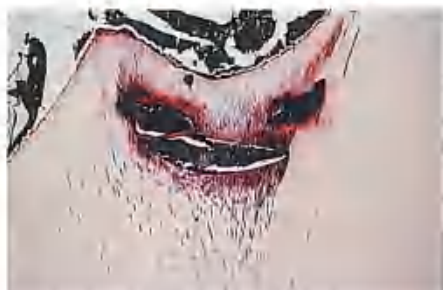

Fig. 2.15 Transverse clefts in dentine caries.

dentinal tubules forming transverse clefts (Fig. 2.15). The mechanism of formation of transverse clefts is uncertain. They may follow the course of incremental lines, or result from the coalescence of liquefaction foci on adjacent tubules, or arise by extension of proteolytic activity along interconnecting lateral branches of odontoblast tubules. Bacteria are no longer confined to the tubules and invade both the peritubular and intertubular dentine. Little of the normal dentine architecture now remains and cavitation commences from the amelodentinal junction. In acute, rapidly progressing caries the necrotic dentine is very soft and yellowish-white; in chronic caries it has a brownish-black colour and is of leathery consistency.

Reactionary (or tertiary) dentine

A layer of reactionary (or tertiary) dentine (Fig. 2.16) is often formed at the surface of the pulp chamber deep to the dentine caries, this dentine being localized to the irritated odontoblasts. It varies in structure but the tubules are generally irregular, tortuous, and fewer in number than in primary dentine, or may even be absent. Microradiography shows variations in mineralization, but areas of hypermineralization when compared with primary dentine may be present. Its formation effectively increases the depth of tissue between the carious dentine and the pulp, and in this way delays involvement of the pulp.

Key points – Dentine caries

- zoned lesion but zones not well demarcated
- demineralization precedes bacterial invasion
- bacterial invasion of tubules; acid produced by acidogenic organisms diffuses ahead
- proteolytic organisms in tubules break down demineralized dentine
- histological evidence of proteolysis – liquefaction foci, transverse clefts
- in the base of a cavity soft dentine must be removed; stained hard dentine can be retained

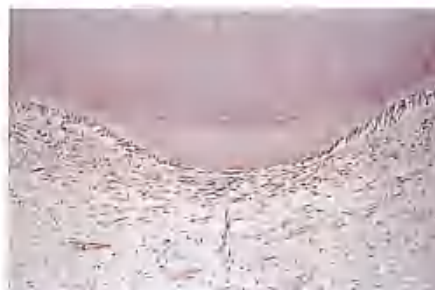

Fig. 2.16 Localised bead of reactionary dentine in response to dentine caries.

Reactionary dentine is a non-specific response to odontoblast irritation, also being formed in reaction to tooth wear and cavity and crown preparations.

Clinical aspects of dentine caries

The dentine at the base of a cavity may be soft, hard, stained, or unstained. Excavation of the softened dentine removes the great majority of cariogenic bacteria. Hard stained dentine may harbour small numbers of bacteria but these are of no consequence. There is no need to remove hard stained dentine. Follow-up studies have shown that lesions treated in this way and then sealed do not progress, providing the seal remains intact, even though some infected dentine may remain. Various caries-detector dyes have been developed with the aim of distinguishing between infected and sterile dentine but their validity and reliability require further study and, at present, they are not recommended for routine use.

The technique of stepwise excavation of a deep carious lesion takes advantage of the fact that progression of caries can be prevented even if some bacteria still remain. The aim of the technique is to remove as much infected dentine as is safely possible at the first excavation, without risking pulpal exposure, in order to reduce the rate of progression. The tooth is then sealed for an interval (from 4 to 6 months in different studies) to allow time for the defence reactions of the pulpodentinal complex to develop, before final excavation.

Chemomechanical methods of removal of carious dentine have also been developed. Although these reduce the amount of cavity preparation and removal of sound tooth tissue that would have been required for access using conventional excavation, the early techniques were time-consuming and relatively inefficient. However, the recently introduced reagent Carisolv (Medi Team) appears more promising. Essentially, chemomechanical techniques involve the application of reagents to carious dentine which chlorinate degraded collagen, disrupting and softening it, facilitating its removal.

Root caries

The primary tissue affected in root caries is usually the cementum. The development of cemental caries is preceded by exposure of the root to the oral environment as a result of periodontal

disease followed by bacterial colonization. Although *Actinomyces* species are present in large numbers and have been implicated in the disease, other organisms, including mutans streptococci and lactobacilli, are also associated with root caries.

Microradiographs of developing lesions show subsurface demineralization of the root which may extend into dentine. The surface layer is hypermineralized and is analogous to that seen in the early enamel lesion. It represents a zone of reprecipitation of mineral removed from the subsurface and of remineralization from minerals present in plaque/saliva. Fluoride is readily taken up by carious root surfaces and this enhances remineralization.

Despite the initial hypermineralization of the surface, progressive softening occurs with time in active lesions. Root caries is clinically diagnosed by a softening and brownish discoloration of the tissues. Demineralization is rapidly followed by bacterial invasion along the exposed collagen fibres and fracture and loss of successive layers of cementum. These fractures frequently occur parallel to the root surface and are associated with invasion of bacteria along the incremental bands in cementum which run as concentric layers around the root. This extension results in lesions that spread laterally around the root and often coalesce with other lesions so that eventually the carious process may encircle the root.

As the cementum is lost the peripheral dentine is exposed. The basic reactions and carious destruction of this tissue are the same as those described previously. Sclerosis may lead to arrested lesions and the surface of the exposed dentine may be covered by a hypermineralized layer.

Arrested caries

Enamel

Arrest of an approximal smooth surface lesion prior to cavity formation can occur when the adjacent tooth is lost so that the lesion becomes accessible to plaque control. Remineralization may then occur from saliva or from the topical application of calcifying solutions, but a normal crystalline structure is not necessarily reformed.

Dentine

Arrest of coronal dentinal caries may occur in lesions characterised by marked early dentinal sclerosis which limits the rate of inward spread of the caries. (In contrast, teeth involved by rampant caries

show a minimal protective response.) As a result, there is extensive lateral spread of caries along the zone of the amelodentinal junction, which undermines the surface enamel. Fracture and loss of this unsupported enamel exposes the superficially softened carious dentine to the oral environment and it is then removed by attrition and abrasion, leaving a hard, polished surface (Fig. 2.17). Such dentine is deeply pigmented brown-black in colour. Its surface is hypermineralized due to remineralization from oral fluids and has a high fluoride content.

Arrested lesions of root caries have a similar clinical appearance and develop in a similar manner following loss of the superficially softened cementum.

Immunological aspects of dental caries

Caries in man is associated with the development of serum and salivary antibodies against *S. mutans*, but in almost all individuals this natural active immunity appears to have little effect as caries is virtually universal in Western populations. This may be because *S. mutans* is only weakly antigenic.

However, artificial active immunity following experimental immunization in animal models has been shown to produce a significant reduction in caries. Early experiments used vaccines composed of whole cells of *S. mutans*, but these could induce antibodies in humans which cross-react with heart tissue. Subsequently, various subunits of the organism have been investigated, especially surface antigens involved in the attachment of the organism to tooth surfaces, which still confer protection against caries but without the risk of cross-reactivity.

Immunization evokes a humoral response and protection against *S. mutans* is provided largely by secretory IgA antibodies in saliva, although IgG and IgM class antibodies can also gain access to the mouth via the crevicular fluid. The salivary IgA antibodies act mainly by interfering with the attachment of the organism to tooth surfaces. In addition to active immunity, the development of genetically engineered antibodies (monoclonal antibodies) against specific mutans streptococcal antigens offer the prospect of passive immunization as a preventive strategy for the future.

Further reading

- Banerjee, A., Watson, T. F., and Kidd, E. A. (2000). Dentine caries: take it or leave it? *Dental Update*, 27, 272–6.
- Bjorndal, L., Larsen, T., and Thylstrup, A. (1997). A clinical and microbiological study of deep carious lesions during stepwise excavation using long treatment intervals. *Caries Research*, 31, 411–17.
- Bowen, W. H. (1994). Food components and caries. *Advances in Dental Research*, 8, 215–20.
- Brailsford S. R., Shah, B., Simons, D., Gilbert, S., Clark, D., Ines, I., et al. (2001). The predominant aciduric microflora of root-caries lesions. *Journal of Dental Research*, 80, 1828–33.

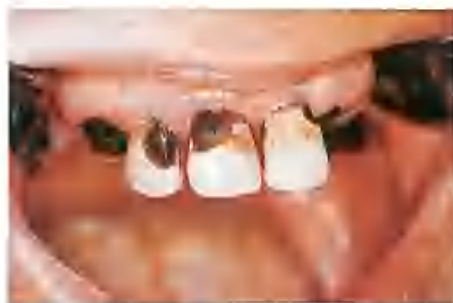

Fig. 2.17 Arrested dentine caries. Note sharply defined outline and brown-black polished surface.

- ten Cate, J. M. and van Loveren, C. (1999). Fluoride mechanisms. *Dental Clinics of North America*, 43, 713–42.
- Edgar, M. W. (1998). Sugar substitutes, chewing gum and dental caries – a review. *British Dental Journal*, 184, 29–32.
- Hardie, J. M. (1992). Oral microbiology: current concepts in the microbiology of dental caries and periodontal disease. *British Dental Journal*, 172, 271–8.
- Jensen, M. E. (1999). Diet and dental caries. *Dental Clinics of North America*, 43, 615–33.
- Kidd, E. A. (1998). Assessment of caries risk. *Dental Update*, 25, 385–90.
- Kidd, E. A. M. (1996). The carious lesion in enamel. In *The prevention of dental disease* (3rd edn) (ed. J. J. Murray), pp. 95–106. Oxford University Press, Oxford.
- Kidd, E. A. M., Ricketts, D. N. J., and Pitts, N. B. (1993). Occlusal caries diagnosis: a changing challenge for clinicians and epidemiologists. *Journal of Dentistry*, 21, 323–31.
- Kleter, G. A. (1998). Discoloration of dental caries lesions [a review]. *Archives of Oral Biology*, 43, 629–32.
- Krasse, B. (2001). The Vipeholm dental caries study: recollections and reflections 50 years later. *Journal of Dental Research*, 80, 1785–8.
- Lenander-Lumikari, M. and Loimaranta, V. (2000). Saliva and dental caries. *Advances in Dental Research*, 14, 40–7.
- Lingsstrom, P., van Houte, J., and Kashket, S. (2000). Food starches and dental caries. *Critical Reviews of Oral Biology and Medicine*, 11, 366–80.
- Maragakis, G. M., Hahn, P., and Hellwig, E. (2001). Chemomechanical caries removal: a comprehensive review of the literature. *International Dental Journal*, 51, 291–9.
- Maguire, A. and Rugg-Gunn, A. J. (2003). Xylitol and caries prevention – is it a magic bullet? *British Dental Journal*, 194, 429–36.
- Marsh, P. D. (1999). Microbiological aspects of dental plaque and dental caries. *Dental Clinics of North America*, 43, 599–614.
- Moynihan, P. J. (2002). Dietary advice in dental practice. *British Dental Journal*, 193, 563–7.
- Rugg-Gunn, A. J. (1996). Diet and dental caries. In *The prevention of dental disease* (3rd edn) (ed. J. J. Murray), pp. 3–31. Oxford University Press, Oxford.
- Russell, M. W., Hajishengallis, G., Childers, N. K., and Michalek, S. M. (1999). Secretory immunity in the defense against cariogenic mutans streptococci. *Caries Research*, 33, 4–15.
- Schupbach, P., Osterwalder, V., and Guggenheim, B. (1995). Human root caries: microbiota in plaque covering sound, carious and arrested carious root surfaces. *Caries Research*, 29, 382–95.
- Tanzer, J. M., Livingston, J., and Thompson, A. M. (2001). The microbiology of primary dental caries in humans. *Journal of Dental Education*, 65, 1028–37.
- Thorild, I., Lindau-Johnson, B., and Twetman, S. (2002). Prevalence of salivary *Streptococcus mutans* in mothers and their preschool children. *International Journal of Paediatric Dentistry*, 12, 2–7.
- Van Houte, J., Lopman, J., and Kent, R. (1994). The predominant cultivable flora of sound and carious human root surfaces. *Journal of Dental Research* 73, 1727–34.

Other disorders of teeth

DISORDERS OF ERUPTION AND SHEDDING OF TEETH

- Premature eruption, natal, and neonatal teeth
- Retarded eruption
- Premature loss
- Persistence of deciduous teeth
- Impaction of teeth
- Reimpaction of teeth

NON-BACTERIAL LOSS OF TOOTH SUBSTANCE

- Attrition
- Abrasion
- Erosion
- Resorption

DISCOLORATION OF TEETH

- Causes of discoloration


TRANSPLANTATION AND REIMPLANTATION OF TEETH

ROOT FRACTURE

AGE CHANGES IN TEETH

- Enamel
- Dentine
- Cementum

FURTHER READING



Other disorders of teeth

Disorders of eruption and shedding of teeth

Premature eruption, natal, and neonatal teeth

Teeth erupted at birth (natal teeth) or which erupt within the first 30 days of life (neonatal teeth) are uncommon, occurring in about 1 in 3000 live births in most reported series. In about 80 per cent of cases the mandibular incisors, usually one or both central incisors, are involved. They are thought to arise from normal tooth germs developing in a superficial position in the jaw with subsequent premature eruption. Coronal enamel and dentine formation is normal for the chronological age of the tooth, but because of the premature eruption the enamel may be hypoplastic. However, there is usually a virtual absence of root formation and any radicular dentine or cementum that forms is generally irregular in structure due to the mobility of the tooth in the jaw (Fig. 3.1). Such teeth may be lost spontaneously or have to be extracted if there is a risk of dislocation and inhalation, or if they interfere with feeding.

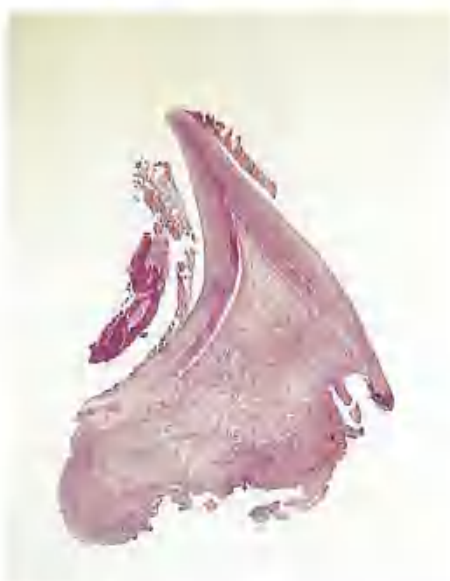

Fig. 3.1 Decalcified section through a neonatal incisor showing coronal dentine but absence of root formation.

Premature eruption of other deciduous or permanent teeth is rare and may be related to local factors such as a superficial location of a tooth germ or early shedding of deciduous teeth. Generalized early eruption of the permanent dentition may also be seen in children with endocrine abnormalities associated with an excess secretion of growth hormone or with hyperthyroidism.

Retarded eruption

Endocrinopathies (for example hypothyroidism), prematurity, nutritional deficiencies, and chromosome abnormalities, such as Down syndrome, may very occasionally be associated with retarded eruption of either the deciduous and/or permanent dentition. Idiopathic migration, traumatic displacement of tooth germs, or abnormally large crowns may also be associated with retarded eruption. Delayed eruption and multiple, impacted supernumerary teeth are also a feature of cleidocranial dysplasia (see Chapter 16).

Premature loss

This is usually the result of either dental caries and its sequelae, or chronic periodontal disease. Occasionally, premature loss of teeth is more specifically associated with diseases such as hypophosphatasia, hereditary palmar-plantar hyperkeratosis, and other causes of periodontitis in systemic disease (see Chapter 7).

Persistence of deciduous teeth

This occurs when deciduous teeth are not shed at the expected time, and is usually associated with the failure of eruption of the permanent successor because it is missing or displaced. Persistence of the entire deciduous dentition is uncommon and usually has a systemic background, such as cleidocranial dysplasia when eruption of permanent teeth is impeded.

Impaction of teeth

An impacted tooth is one which remains unerupted, or only partly erupted, in the jaw beyond the time when it should normally be fully erupted. One or several teeth may be affected and the condition may be symmetrical. It is rarely seen in the primary dentition. In the permanent dentition the teeth most frequently involved are third molars, mandibular premolars, and maxillary canines. Local causes for impaction include abnormal position of the tooth germ, lack of space for the teeth in the jaws, super-

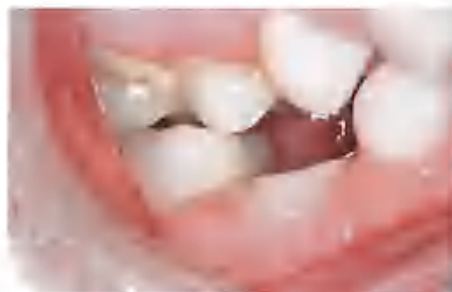

Fig. 3.2 Submerging mandibular deciduous second molar.

numerary teeth, cysts, and tumours. As previously mentioned, cleidocranial dysplasia is almost always associated with multiple impacted teeth. Possible complications of impaction include resorption of the impacted tooth or adjacent erupted teeth, and the development of dentigerous cysts and odontogenic tumours.

Reimpaction of teeth

This term describes the situation in which a previously erupted tooth becomes submerged in the tissues. Alternative terms for the disorder are infraocclusion and submerged teeth. The deciduous second molar is most commonly affected and reimpaction occurs twice as frequently in the mandible than in the maxilla (Fig. 3.2). The condition is associated with deficient development of the alveolar process around the reimpacted tooth which may, on rare occasions, become completely covered by oral mucosa. The roots of the tooth are usually partly resorbed and ankylosed to the bone. The cause is not known, but it is likely that the root first becomes ankylosed and that this is followed by lack of growth of the alveolar process. As the neighbouring teeth continue to move occlusally they tilt over the ankylosed tooth, causing reimpaction.

Non-bacterial loss of tooth substance

Although it is convenient to discuss attrition, abrasion, and erosion separately, in many patients tooth wear involves elements of all three. For this reason terms such as 'tooth wear with a major component of attrition' are usually preferred as clinical diagnoses.

Key points – Non-bacterial loss of tooth substance

- tooth wear
 - attrition
 - abrasion
 - erosion
- resorption
 - internal
 - external

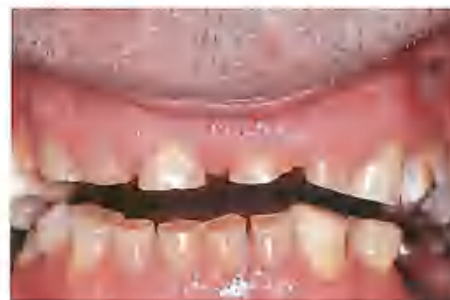

Fig. 3.3 Tooth wear with a large element of attrition.

Attrition

This is loss of tooth substance as a result of tooth-to-tooth contact (Fig. 3.3). It may be physiological or pathological in origin, although clinically the distinction is often unclear. The pattern of tooth loss in physiological attrition is fairly constant: the incisal edges of the incisors are worn first, followed by the occlusal surfaces of the molars, the palatal cusps of the maxillary teeth, and the buccal cusps of the mandibular teeth. When the dentine becomes exposed it generally becomes discoloured brown. Because dentine is softer than enamel it is attrited at a greater rate and the lesions may become cup-shaped, surrounded by a rim of enamel. Approximal attrition leads to the transformation of contact points to contact areas and to the mesial migration of teeth which throughout life may amount to as much as 1 cm from third molar to third molar. Men generally show more severe attrition than women. The abrasive property of food is important in determining the rate of physiological attrition.

Pathological attrition may result from:

- (1) abnormal occlusion – either developmental or following extractions;
- (2) bruxism and habits such as tobacco and betel chewing;
- (3) abnormal tooth structure, for example amelogenesis imperfecta, dentinogenesis imperfecta.

Exposure of dentinal tubules by attrition leads to the formation of reactionary dentine on the pulpal surface which protects the tooth against pulp exposure, and to the formation of translucent zones and dead tracts. The patient may complain of hypersensitive dentine.

Abrasion

This is the pathological wearing away of tooth substance by the friction of a foreign body independent of occlusion. Different foreign bodies produce different patterns of abrasion.

1. Toothbrush abrasion is common and is seen most frequently on exposed root surfaces of teeth. It is commonly associated with toothbrushing in a horizontal rather than a vertical direction and is made worse by an abrasive dentifrice. The maxillary teeth are more involved than the mandibular

teeth, and the abrasion is most pronounced in the cervical regions of the labial surfaces of incisors, canines, and premolars (Fig. 3.4). The abrasion produces wedge-shaped grooves with sharp angles and highly polished dentine surfaces (Fig. 3.5). Abrasion cavities may be accentuated as a result of flexing of the teeth due to excessive loading, such as in a traumatic occlusion. This can cause microcracks in the enamel, termed abfraction lesions.

2. Habitual abrasion may be seen in pipe-smokers.

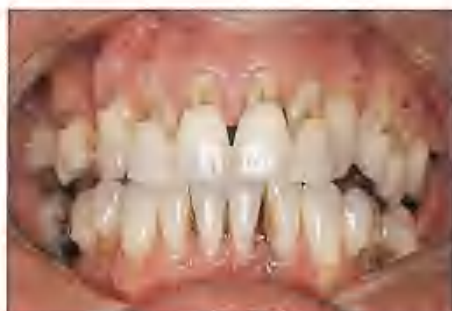

Fig. 3.4 Toothbrush abrasion.



Fig. 3.5 Ground section through a toothbrush abrasion cavity showing underlying reactive changes in dentine and reactionary dentine formation.

3. Occupational abrasion develops when objects are held between or against the teeth during work, for example hair-grips.
4. Ritual abrasion of the teeth is uncommon today and is confined mainly to Africa.

Erosion

This is the loss of tooth substance by a chemical process that does not involve known bacterial action. It may render the teeth more susceptible to attrition and abrasion.

1. Dietary erosion may follow the excessive intake of acidic beverages, such as fruit juices or carbonated soft drinks, or the habit of sucking citrus fruits. Although the cause of erosion cannot be reliably determined from the distribution of the lesions, dietary erosions tend to involve the palatal surfaces of the teeth and the labial surfaces of the maxillary incisors. It is a common problem, occurring to some extent in about 50 per cent of 5-year-old and about 30 per cent of 14-year-old children in the UK. Shallow, broad concavities with polished surfaces are produced.
2. Occupational (environmental) erosion is now relatively uncommon. It is seen in workers exposed to acids in their workplace and is usually due to atmospheric pollution. The labial surfaces of the maxillary and mandibular incisors are usually involved as these are the surfaces most exposed to the atmosphere.
3. Regurgitation of stomach contents or persistent vomiting causes erosion in which the palatal surfaces of the maxillary teeth are primarily affected – a condition referred to as perimolysis (Fig. 3.6). This may be associated with anorexia nervosa or bulimia nervosa. A similar pattern of erosion may also be seen in other patients with gastro-oesophageal reflux, for example chronic alcoholics, where gastric reflux is probably associated with chronic gastritis.

As in attrition, reactionary dentine, translucent zones, and dead tracts develop in relation to the exposed dentinal tubules and the patients may complain of hypersensitive dentine.

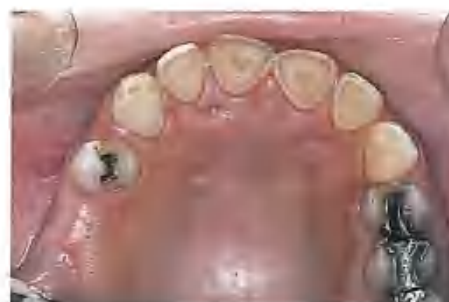

Fig. 3.6 Erosion of the palatal surfaces of the anterior maxillary teeth in a patient with anorexia nervosa. Almost all of the palatal enamel has been lost. The pulp chambers of the central incisors are visible.

Key points – Tooth wear

- embraces attrition, abrasion, and erosion alone and in combinations
- combined aetiologies modify clinical patterns of wear
- stimulates protective responses of pulpodentinal complex

Resorption

The natural shedding of deciduous teeth follows the progressive resorption of the roots by cells resembling osteoclasts. This physiological resorption may be an inherent developmental process or it may be related to pressure from the permanent successor against the overlying bone or tooth.

Microscopic areas of superficial (surface) resorption of the roots of permanent teeth are common but are transient and are repaired by the apposition of cementum or of a bone-like tissue. Such microscopic foci are of no clinical consequence. In contrast, resorption sufficient to be diagnosed radiologically is always pathological. Pathological resorption may start from the root surface (external resorption) or from the pulpal surface (internal resorption). In both cases osteoclast-like giant cells (sometimes called odontoclasts) sitting in resorption lacunae are seen on actively resorbing surfaces (Fig. 3.7). However, as resorption is not a continuous process the osteoclast-like cells are not always present and in this case some resorption lacunae may show attempts at repair.

External resorption

External resorption may be caused by inflammation and by pressure/mechanical stimulation or be of unknown (idiopathic) cause.

INFLAMMATORY RESORPTION

Inflammatory resorption typically involves the apical portion of the root, as a result of periapical inflammation following pulp necrosis or trauma, and is associated with a periapical radiolucency on a radiograph. However, following luxation injuries and reimplantation or transplantation of teeth, a replacement

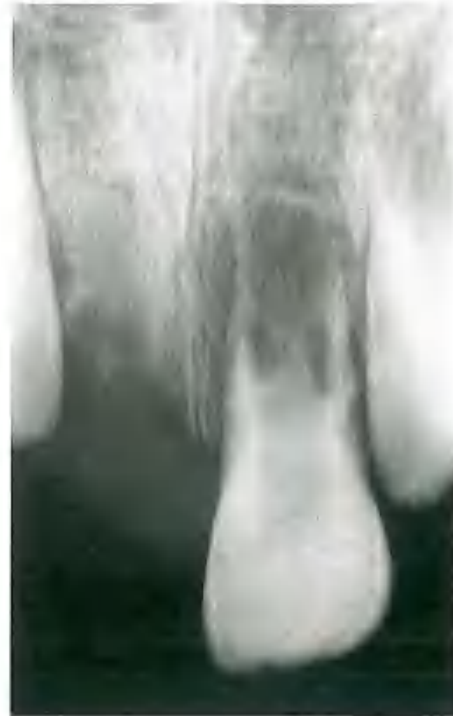

Fig. 3.8 Extensive resorption of a replanted maxillary permanent central incisor.

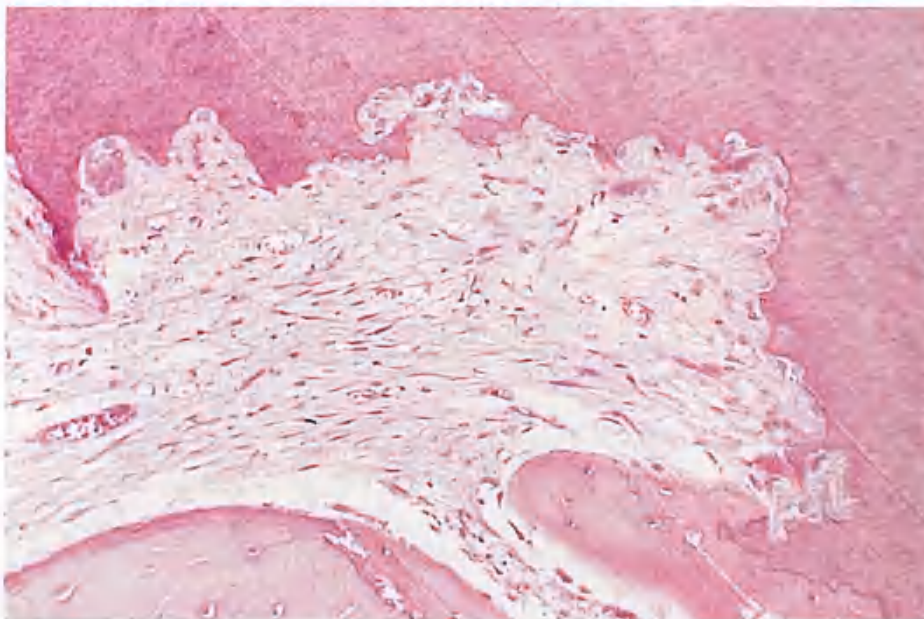


Fig. 3.7 Resorbing dentine surface with resorption lacunae and osteoclast-like cells.

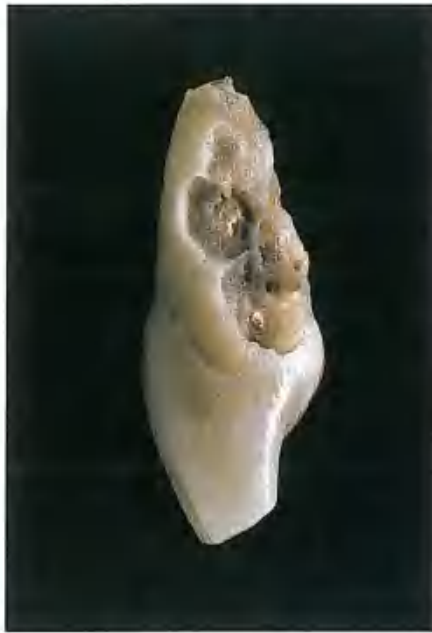

Fig. 3.9 Extensive resorption resulting in loss of most of the root of a transplanted maxillary canine.

pattern of resorption may be seen. This is characterized by progressive resorption of the root (Figs 3.8, 3.9) and replacement of the resorbed area by bone. However, there is no ankylosis and there is a zone of inflamed granulation or fibrous tissue of varying extent between the root and bone surfaces. Inflammation may also play a role in pressure/mechanical root resorption and in the burrowing type of external resorption involving the cervical areas of the teeth. These are considered below.

PRESSURE/MECHANICAL RESORPTION

Root resorption associated with pressure/mechanical stimulation may be seen in patients undergoing orthodontic treatment and can be caused by the application of excessive force. It occurs in the apical region and the resorbed area undergoes repair and remodelling when the cause is removed. It is possible that excess force could cause an aseptic necrosis of the periodontal ligament, followed by inflammation. Pressure may also be a factor in root resorption associated with tumours or, occasionally, cysts involving the roots of teeth. However, in both cases, it is likely that cytokines associated with bone resorption are also involved.

IDIOPATHIC RESORPTION

A burrowing type of resorption is most commonly seen. A localized area of the root surface is first resorbed, following which the resorption burrows deeply into and ramifies throughout the dentine, producing a labyrinthine network of lacunae and channels (Fig. 3.10). The resorbed tissue is replaced by granulation tissue in which varying amounts of calcified repair tissue and/or bone may form and ankylosis may result.

The circumpulpal dentine and predentine are generally spared and remain as a narrow shell as the resorption encircles the pulp

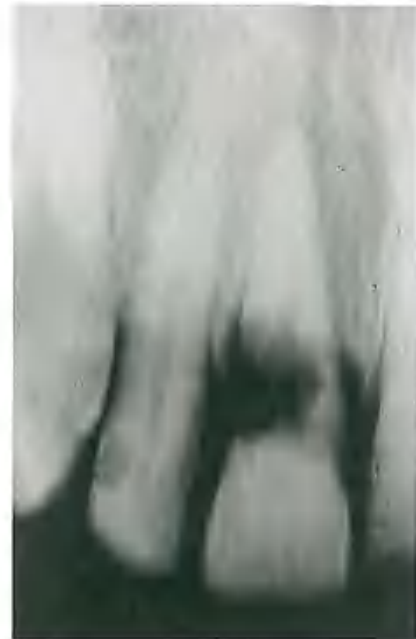

Fig. 3.10 Extensive burrowing idiopathic resorption involving the cervical region of a central incisor, resulting in root fracture.

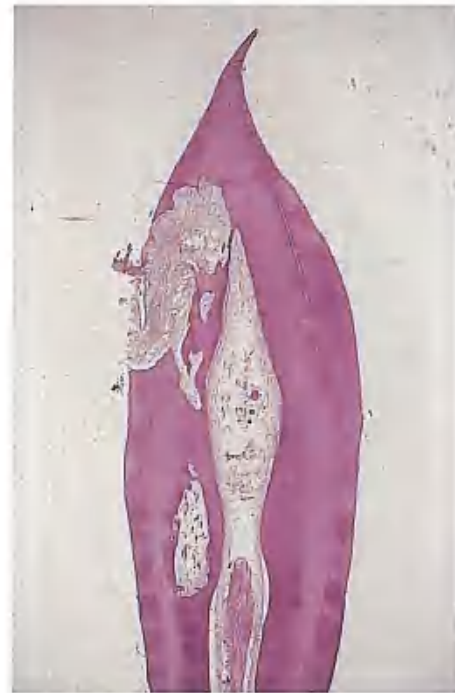

Fig. 3.11 Idiopathic resorption commencing in the cervical region and involving coronal and radicular dentine.

(Fig. 3.11). The pulp remains vital unless exposed by the resorptive process or by fracture of the residual dentine shell. This type of resorption usually starts in the cervical region of the tooth and it has been suggested that trauma to the cementum may trigger the process. As noted above, it is likely that inflammation plays a role.

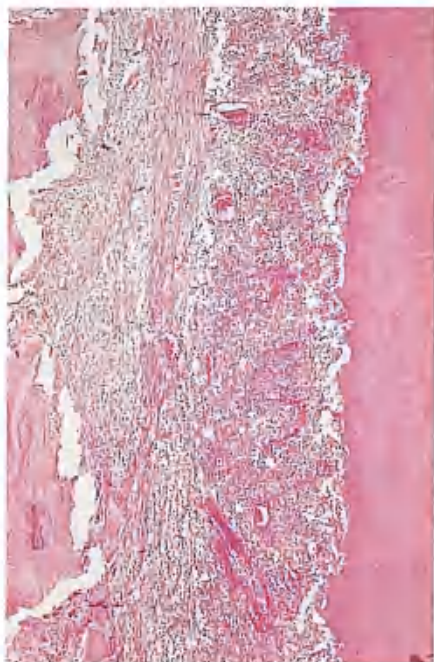

Fig. 3.12 Internal resorption of dentine associated with pulpitis.

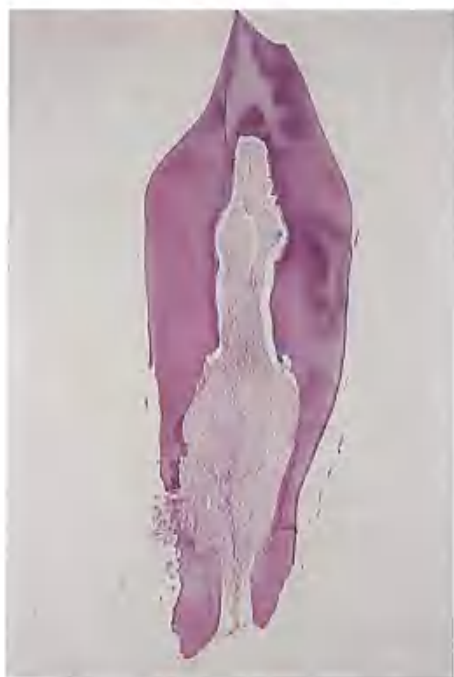

Fig. 3.13 Idiopathic internal resorption involving the root canal.

Internal resorption

Pathological resorption starting from the pulpal surface (internal resorption) is usually associated with pulpitis (Fig. 3.12) and follows the loss of odontoblasts and predentine, which might confer some degree of protection. An idiopathic type of internal resorption also occurs in which there is a well-defined, spherical

Key points – Resorption of teeth

External

- microscopic surface resorption (transient, reversible)
- inflammatory resorption – periapical inflammation, re-implanted/transplanted teeth
- pressure resorption – orthodontics, possibly tumours/cysts
- idiopathic resorption – burrowing (cervical) resorption

Internal

- most often associated with pulpitis
- may be idiopathic
- less common than external resorption
- can involve coronal or radicular pulp

radiolucent area in the dentine continuous with the pulp chamber or root canal (Fig. 3.13). When the coronal dentine is involved the resorption may present clinically as a pink spot due to the vascular pulp tissue being visible through the overlying enamel. Radiological distinction between idiopathic internal and external (burrowing) resorption may be impossible.

External resorption of the crowns of impacted teeth is uncommon. The enamel is normally separated from the surrounding connective tissues by the reduced enamel epithelium, which appears to confer protection. If the epithelium is lost, in total or in part, a burrowing type of external resorption may follow.

Table 3.1 Causes of discoloration of teeth

Extrinsic stains:

- substances in the diet
- habitual chewing, betel nut, tobacco
- tobacco smoking
- medicaments
- chromogenic bacteria

Changes in structure or thickness of dental tissues:

- enamel hypoplasias, fluorosis
- amelogenesis imperfecta, hypomaturation, and hypoplastic types
- enamel opacities
- enamel caries
- dentinogenesis imperfecta, dentinal dysplasia type II
- age changes in dental tissues

Diffusion of pigments into dental tissues after formation:

- extrinsic stains
- endodontic materials
- products of pulp necrosis

Pigments incorporated during formation of dental tissues:

- bile pigments
- porphyrins
- tetracycline

Again, calcified repair tissue resembling cementum and/or bone may be formed and ankylosis may result.

Discoloration of teeth

Normal variation in the colour of teeth must be distinguished from pathological discoloration.

Causes of discoloration

The colour of teeth may be affected by many factors, alone or in combination. The main groups of causes are listed below and examples of each are given in Table 3.1:

- (1) surface deposits (extrinsic staining);
- (2) changes in the structure or thickness of the dental hard tissues;
- (3) diffusion of pigments into the dental hard tissues after their formation;
- (4) incorporation of pigments into the dental hard tissues during their formation.

Extrinsic staining

Green, black, brown, or occasionally red or orange deposits may be adsorbed onto tooth surfaces within the salivary pellicle or dental plaque. The stain may be derived from food, drinks, tobacco, and other habits such as betel nut chewing, mouth-rinses and other topical medicaments, or from occupational exposure to metallic salts. Green and black stains are sometimes seen in children on the labial surfaces of upper anterior teeth (Fig. 3.14). It is thought that these are produced by chromogenic bacteria and such children usually have a low caries experience. However, whether or not this is related in some way to the cause of the staining or to other factors is unknown.

Changes in the structure or thickness of dental hard tissues

Abnormally coloured teeth are seen in amelogenesis and dentinogenesis imperfecta, other types of developmentally hypomineralized and hypoplastic enamel, and white spot enamel caries (see Chapters 1 and 2).

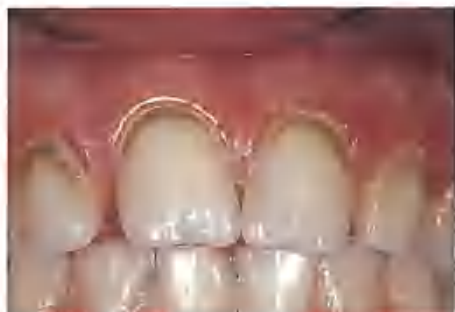

Fig. 3.14 Green extrinsic staining associated with chromogenic bacteria.

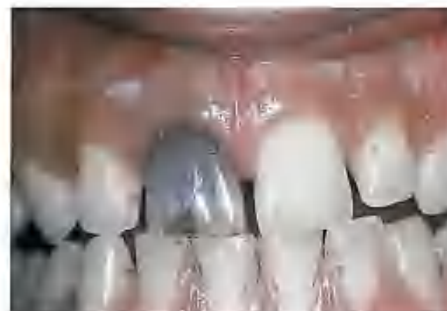

Fig. 3.15 Discoloration following pulp necrosis.

Diffusion of pigments into the dental hard tissues after their formation

In addition to discoloration due to intrinsic change in structure, developmentally hypomineralized enamel and carious enamel may take up stains from materials such as food and tobacco and acquire a dark brown colour. Similar stains may diffuse into dentine exposed by caries or tooth wear, and some restorative and root filling materials and their corrosion products may also stain dentine. Pulp necrosis is a common cause of a discoloured tooth. Lysis of necrotic tissue and of red blood cells from areas of haemorrhage leads to pigmented products which diffuse into the dentine (Fig. 3.15).

Incorporation of pigments into the dental hard tissues during their formation

This occurs in congenital disorders associated with hyperbilirubinaemia, congenital porphyria, and tetracycline pigmentation.

CONGENITAL HYPERBILIRUBINAEMIA (NEONATAL JAUNDICE)

Mild transient jaundice is common in neonates but in severe cases, most frequently associated with haemolytic disease of the newborn (rhesis incompatibility), bile pigments may be deposited in the calcifying enamel and dentine of developing teeth, particularly along the neonatal incremental line. The pigment is largely confined to the dentine, the affected teeth being discoloured green to yellowish-brown. Enamel hypoplasia may also occur (see Table 1.2).

CONGENITAL PORPHYRIA

This is a rare, recessive autosomal disease in which there is an inborn error of porphyrin metabolism. It is characterized by the excretion of red porphyrin pigments in the urine and circulating porphyrins in the blood which are deposited in many tissues, including bone and dental hard tissues. Affected teeth show a pinkish-brown discoloration and a red fluorescence under ultraviolet light.

TETRACYCLINE PIGMENTATION

Systemic administration of tetracyclines during the period of tooth development results in their deposition in the dental hard tissues as well as in bone. Dentine is more heavily stained than enamel and in ground sections of affected teeth yellow bands of pigmentation related to incremental lines in dentine can be seen.




Fig. 3.16 Fluorescent bands of tetracycline along incremental lines of coronal and radicular dentine in a molar tooth.

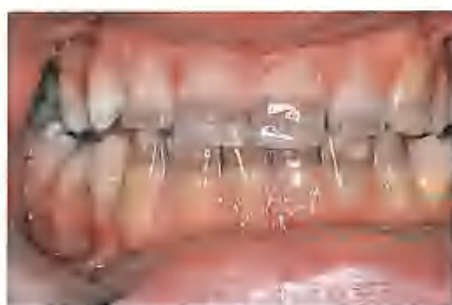

Fig. 3.17 Chronological discoloration of teeth associated with tetracycline.

The pigmented bands fluoresce a bright yellow under ultraviolet light (Fig. 3.16). Tetracyclines are also deposited in cementum.

Affected teeth generally are yellowish when they erupt and become darker and browner after exposure to light. The degree of clinical discoloration of the teeth is affected by which particular tetracycline preparation has been taken, the dosage, and the age of the patient at the time of administration of the drug (Fig. 3.17). If the drug is administered when crown formation is already complete, then the tetracycline is confined to the roots and the discoloration will not be clinically discernible. Tetracyclines cross the placenta and the deciduous teeth may be affected if the drug is given any time from 29 weeks to full term. It is particularly important to avoid tetracyclines from 4 months to about 7 years of age if severe clinical discoloration of the permanent dentition is to be prevented.

Transplantation and reimplantation of teeth

Transplantation of a tooth from one site to another in the same individual (autotransplantation), into an extraction site or a surgically prepared socket, has been carried out for many years with varying degrees of success. Reimplantation is when a tooth is returned to its own socket, usually following traumatic avulsion. Transplantation of teeth from one individual to another of the same species (allografting) has been studied experimentally in

Box 3.1 Allografting of teeth

- Allografts illicit an immune response leading to rejection.
- The host responds to histocompatibility antigens in donor tissues.
- The pulp and periodontal ligament are immunogenic.
- Demineralized dentine and soluble enamel protein are also immunogenic, but relevance of this to allograft rejection is not known.

animals but the results are very inconsistent because of graft rejection (see Box 3.1).

Autotransplants do not stimulate an immune response. Experimental studies in animals have shown that following transplantation or reimplantation the pulp and soft tissues attached to the root degenerate due to traumatic severance of the blood supply. In developing teeth with open apices, revascularization and repair of the dental papilla may occur and dentinogenesis may resume, although the dentine formed may be abnormal. However, continued root growth is rare. The reparative cells are probably derived from residual donor tissue which survives operative trauma. Reattachment of autotransplants may result from regeneration of the periodontal ligament, the formation of scar-like fibrous tissue running parallel to the root surface, or ankylosis. If ankylosis occurs the alveolar bone may be directly attached to the normal root surface or to resorption concavities (Fig. 3.18). It has been suggested that preservation of the vitality of the periodontal ligament is an important factor in deterring root resorption and ankylosis.

Clinical studies of autotransplants in humans have concentrated mainly on root resorption which is the most commonly encountered complication. Sometimes the resorption is rapid, but more often is slowly progressive and periods of 10–15 years may elapse before resorption causes exfoliation of the transplanted tooth. Root resorption may be extensive before marked tooth mobility occurs and pain is not a feature. Following transplantation and reimplantation there is an early acute traumatic inflammatory reaction which may initiate root resorption and this may be followed by a non-specific chronic



Fig. 3.18 Ankylosis of the root of a transplanted tooth. Note continuity between the surface of the root (left) and the alveolar bone (right).

inflammatory reaction. Chronic inflammatory resorption of the root is associated with an adjacent area of radiolucency in bone. Long-term replacement resorption may also occur in which the progressive loss of root substance is matched by bony infilling. Root resorption is minimized in transplants with fully developed roots if they are root filled within 4 weeks of transplantation. Resorption of reimplanted teeth is generally more common and extensive than that seen in transplanted teeth and is largely a function of the length of time the tooth has been out of the jaw.

For teeth with immature roots, further development is dependent on revascularization of the pulp. The diameter of the apical foramen is a critical factor; teeth with a foramen greater than 1 mm diameter are more likely to revascularize.

Root fracture

The outcome of an intra-alveolar fracture of a root depends on several factors, which include the presence or absence of infection, the vitality of the pulp, the position of the fragments, the degree of comminution, the location of the fracture, and the mobility of the coronal fragment. If the fracture is sterile, three main patterns of healing may occur similar to those seen in the healing of a fracture of bone:

1. The root fragments become united totally, or in part, by calcified repair tissue resembling bone and/or cementum.
2. The fractured surfaces of each fragment become rounded off and clothed by cementum but are not united by calcified tissue. Fibrous tissue continuous with the periodontal ligament fills the intervening space (analogous to fibrous healing of a bone fracture) (Fig. 3.19).
3. The fracture surfaces become rounded and clothed by cementum as above but the fragments are widely separated. Fibrous tissue continuous with the periodontal ligament covers the fractured ends of the separate fragments and the intervening space is filled by alveolar bone (analogous to non-union of a bone fracture).

Key points – Autotransplantation and reimplantation of teeth

- success rates for autotransplantation higher than for reimplantation
- 85–95 per cent of autotransplants survive 5 years
- main complications are:
 - root resorption – inflammatory/replacement types
 - loss of pulp vitality in teeth with immature roots
 - failure to complete root development in teeth with open apices
 - poor periodontal healing

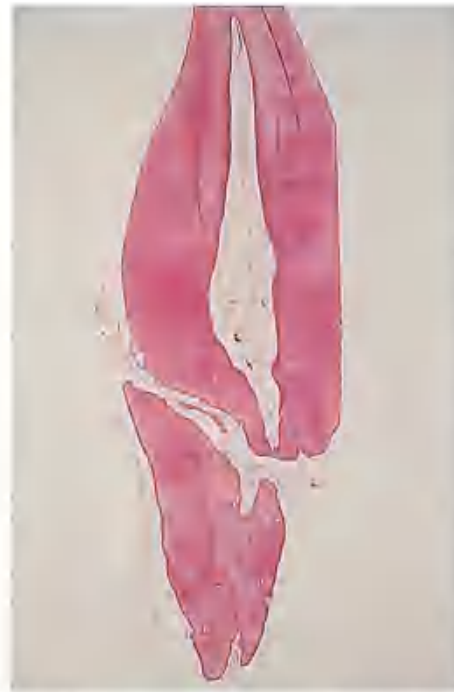

Fig. 3.19 Root fracture showing separation of the remodelled coronal and apical fracture surfaces by fibrous tissue.

The pulp chamber in either fragment may become obliterated by calcified tissue.

Age changes in teeth

Age changes in teeth include changes in morphology associated with wear, especially attrition, and changes in structure and composition of the dental hard tissues. Age changes in the dental pulp are discussed in Chapter 4.

Enamel

The enamel tends to become more brittle and less permeable with age, reflecting the ionic exchange which occurs between enamel and the oral environment throughout life. Darkening of the enamel has also been described and may be due to absorption of organic material.

Dentine

The two main age-related changes in dentine are continued formation of secondary dentine resulting in reduction in size and in some cases obliteration of the pulp chamber, and dentinal sclerosis associated with the continued production of peritubular dentine. Both of these processes are also associated with caries and tooth wear. Sclerosis of radicular dentine tends to make the roots brittle and they may fracture during extraction. It is also associated with increasing translucency of the root. This starts at the apex in the peripheral dentine just beneath the cementum and extends inwards and coronally with increasing age. The length of

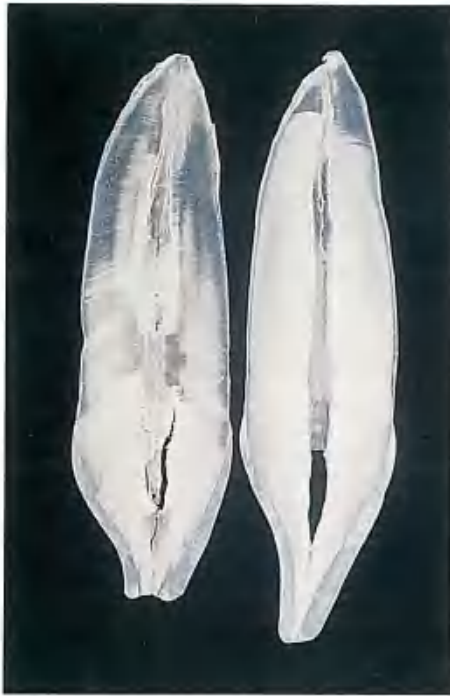

Fig. 3.20 Age changes in dentine. The tooth on the left is from an elderly patient and shows attrition, partial obliteration of the pulp chamber, and prominent sclerosis with increased translucency of radicular dentine compared with the younger tooth on the right.

root affected by translucency is used in forensic dentistry as one method of age estimation (Fig. 3.20).

Cementum

Cementum continues to be formed throughout life, especially in the apical half of the root, resulting in a gradual increase in thickness to compensate for interproximal and occlusal attrition. The amount of secondary cementum at the apex of a tooth is another factor that can be taken into account in forensic dentistry in age estimation, but it is important to distinguish between physiological apposition with age and other causes of hypercementosis.

Further reading

- Andreasen, J. O., Paulsen, H. U., Yu, Z., and Bayer, T. (1990). A long-term study of 370 autotransplanted premolars. Part IV. Root development subsequent to transplantation. *European Journal of Orthodontics*, 12, 38–50.
- Andreasen, J. O., Paulsen, H. U., Yu, Z., and Schwartz, O. (1990). A long-term study of 370 autotransplanted premolars. Part III. Periodontal healing subsequent to transplantation. *European Journal of Orthodontics*, 12, 25–37.
- Cunha, R. E., Boer, F. A., Torriani, D. D., and Frossard, W. T. (2001). Natal and neonatal teeth: review of the literature. *Pediatric Dentistry*, 23, 158–62.
- Gunraj, M. N. (1999). Dental root resorption. *Oral Surgery, Oral Medicine, Oral Pathology, Oral Radiology, and Endodontics*, 88, 647–53.
- Kardos, T. B. (1996). The mechanism of tooth eruption. *British Dental Journal*, 181, 91–5.
- Kelleher, M. and Bishop, K. (1999). Tooth surface loss: an overview. *British Dental Journal*, 186, 61–6.
- Leach, H. A., Ireland, A. J., and Whaites, E. J. (2001). Radiographic diagnosis of root resorption in relation to orthodontics. *British Dental Journal*, 190, 16–22.
- Milosevic, A. (1999). Eating disorders and the dentist. *British Dental Journal*, 186, 109–13.
- Moss, S. J. (1998). Dental erosion. *International Dental Journal*, 48, 529–39.
- Ne, R. E., Witherspoon, D. E., and Gutmann, J. L. (1999). Tooth resorption. *Quintessence International*, 30, 9–25.
- Nunn, J., Shaw, L., and Smith A. (1996). Tooth wear – dental erosion. *British Dental Journal*, 180, 349–52.
- Shaw, L. and Smith, A. J. (1998). Dental erosion – the problem and some practical solutions. *British Dental Journal*, 186, 115–18.
- Thomas, S., Turner, S. R., and Sandy, J. R. (1998). Autotransplantation of teeth: is there a role? *British Journal of Orthodontics*, 25, 275–82.
- Watts, A. and Addy, M. (2001). Tooth discolouration and staining: a review of the literature. *British Dental Journal*, 190, 309–16.

Disorders of the dental pulp

PULPITIS

Clinical features

Aetiology

Histopathology

Pulp polyp – chronic hyperplastic pulpitis

Effects of cavity preparation and restorative materials

HEALING OF PULP

PULP CALCIFICATION

PULP NECROSIS

AGE CHANGES IN THE PULP

FURTHER READING

Faint, illegible text in the upper left quadrant.

Faint, illegible text in the lower left quadrant.

Disorders of the dental pulp

Inflammation is the most important disease process affecting the dental pulp. It is a dynamic process and presents a spectrum of changes reflecting the interplay between its cause, the effectiveness of the host defences, and a variety of factors that may influence the latter.

Pulpitis

Clinical features

Pulpitis presents clinically as pain which the patient may have difficulty in localizing to a particular tooth, the pain often radiating to the adjacent jaw and on some occasions into the face, the ear, or the neck. The pain may be continuous for several days or may occur intermittently over a longer period. Pulpitis is often described clinically as either acute or chronic based on the duration and severity of the patient's symptoms. Although there is little correlation between the clinical features and the type and extent of inflammation seen in the pulp, patients with severe pain usually have more severe histopathological changes. A clinical diagnosis of acute pulpitis is usually made when the patient complains of a severe throbbing pain, at times lancinating in type, precipitated by hot or cold stimuli or on lying down, and which often keeps the patient awake. The pain generally lasts for about 10–15 minutes but may be more or less continuous. In contrast, a clinical diagnosis of chronic pulpitis is associated with spontaneous attacks of dull aching pain which can last for an hour or more. An absence of symptoms is not even evidence of a normal pulp as pulp death following pulpitis may occur with no previous history of pain. The critical decision which has to be made clinically is whether pulpitis is reversible or irreversible, as this will determine the management of the affected tooth. This decision is based on factors such as the age of the patient, the size of the carious lesion, the presence or absence of symptoms, pulp vitality tests, radiographic evidence, and direct observation during operative procedures. Patients with irreversible pulpitis usually have severe pain and often give a history of previous episodes of pain in the involved tooth.

Aetiology

Dental caries is the commonest cause of pulpitis, but it is also caused by microorganisms reaching the pulp via other routes, and

Key points – Pulpitis

- presents clinically as pain
- acute pulpitis and chronic pulpitis are clinical diagnoses
- clinical diagnosis based on the severity and duration of symptoms
- poor correlation between symptoms and pathology
- pulpitis may be reversible or irreversible

by traumatic injury to the pulp such as may occur in restorative procedures.

Microbial

Bacteria generally reach the pulp as a result of dental caries, including root caries and recurrent caries associated with marginal leakage of restorations. Inflammation of the pulp starts before the leading organisms in the carious dentine reach the pulp, showing that the initial pulp reactions follow the diffusion of soluble irritants through the dentine. Pulpitis is not usually seen histologically until the leading organisms in the carious dentine are within about 1 mm of the pulp in permanent teeth or twice this distance in deciduous teeth.

Bacteria can also reach the pulp if it is exposed by attrition, abrasion, traumatic restorative procedures, or by cracking or fracture of the tooth as a result of trauma. They can also gain access through the defective enamel and dentine lining an invaginated odontome. In addition, pulpitis may occasionally be a complication of advanced periodontal disease as a result of a periodontal pocket involving the periapical tissues or as a result of accessory root canals or exposed dentinal tubules communicating with a periodontal pocket, producing a combined periodontal–endodontic lesion.

The enormous importance of bacterial infection in the aetiology of pulpitis has been shown by experiments in germ-free rats in which surgical pulp exposures were not followed by progressive pulpitis even in the presence of gross food impaction.

Chemical and thermal injury

Chemical and thermal injury to the pulp may occur during restorative procedures (see later). Irritant substances may be

Key points – Pulpitis

- bacterial infection is the most important aetiological factor
- dental caries is the commonest cause
- bacteria can also reach the pulp by other local routes
- trauma to dentine and/or pulp may cause pulpitis and/or reactionary changes in the pulpo-dentinal complex

directly applied to an exposed pulp or may diffuse through dentine after insertion of a restorative material. Frictional heat generated during cavity preparation is a significant cause of pulp injury and the importance of an adequate supply of coolant to a bur cannot be overemphasized.

In many instances the pulp may respond to such agents by forming reactionary dentine, rather than the irritation leading to symptomatic pulpitis. Dentinal tubules may also become sclerosed or dead tracts may form which are sealed, as described in Chapter 3.

Barotrauma (aerodontalgia)

Dental pain has been described by air crew flying at high altitudes in unpressurized aircraft, and in divers subjected to too rapid decompression following deep-sea diving. This pain has been attributed to the formation of nitrogen bubbles in the pulp tissues or vessels, similar to the decompression syndrome elsewhere in the body. However, gas bubbles are seldom found in decompressed organs and the possibility of fat emboli from altered lipoproteins and platelet thrombi around the fat is suggested by some investigators. Aerodontalgia is really a marker of inadequate pulp protection from the atmosphere and this usually means caries. It is not a direct cause of pulpitis, rather an exacerbating factor.

Histopathology

The inflammatory process in the pulp is basically the same as elsewhere in the body, but the process may be modified by various factors, including the nature and severity of the insult, the efficiency of the host defence mechanisms, and its special anatomical location (Fig. 4.1). The pulp is almost totally surrounded by dentine which limits the ability of the pulp to tolerate oedema. Thus, the pressure rise in the pulp associated with an inflammatory exudate may cause local collapse of the venous part of the microcirculation (see Box 4.1). This leads to local tissue hypoxia and anoxia, which in turn may lead to localized necrosis. Chemical mediators released from the necrotic tissue lead to further inflammation and oedema, and total necrosis of the pulp may follow the continued spread of local inflammation. Reactionary dentine may continue to form after the onset of pulpitis, providing the odontoblasts and pulp have not been irreversibly damaged, and may in time protect the pulp from further injury by increasing the thickness of calcified tissue between the pulp and the irritant in the dentine.

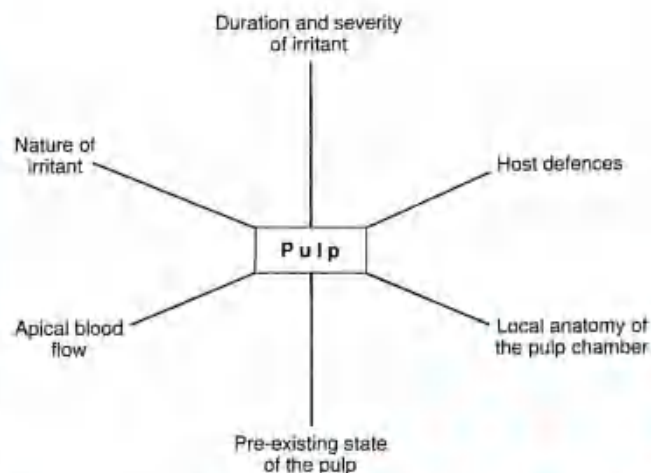


Fig. 4.1 Factors influencing the outcome of inflammation in the dental pulp.

Pulpitis caused by caries always starts as a localized area of inflammation directly related to the carious dentine, the inflammation eventually extending throughout the pulp if the caries is not treated. Carious lesions differ with respect to bacteriology, rates of progression, and pulpodentinal reactions, and so the rate of progression of the inflammation in the pulp will vary from individual to individual and from tooth to tooth. In multirooted teeth the inflammation may progress to the apex of one root even before the whole of the pulp chamber is involved.

The severity of the irritation to the pulp from dental caries increases as the caries advances pulpwards. The relatively low level of irritation initially leads to a mild inflammatory response in which there is diffuse infiltration beneath the odontoblasts by a few mononuclear inflammatory cells, principally lymphocytes and macrophages, responding to antigenic products from bacteria and the carious dentine (see Box 4.1). Acute exudative changes are not

Box 4.1 Pulpitis

- Normal interstitial fluid pressure in the pulp: 5–20 mm of mercury.
- In inflammation the interstitial pressure may rise to 60 mm of mercury.
- Pressures of 40–50 mm of mercury may cause local stasis, leading to localised necrosis.
- Local build-up of pressure is not inevitable because of drainage of the fluid exudate via the lymphatics.
- Antigenic stimuli can reach the pulp via the dentinal tubules ahead of the advancing organisms.
- Dendritic antigen-presenting cells are present within and around the odontoblast layer, in close proximity to the pulpal ends of the involved dentinal tubules.

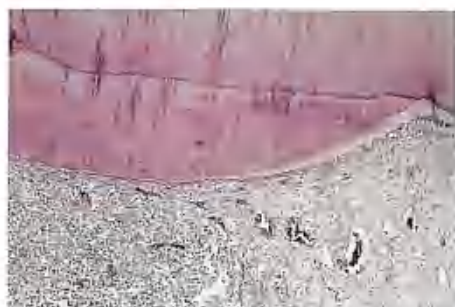

Fig. 4.2 Vasodilation and acute exudative changes in the dental pulp associated with bacterial invasion of reactionary dentine (purple-streaked tubules).

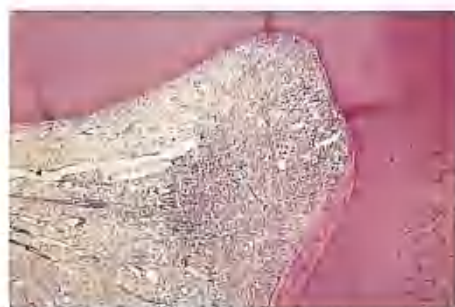

Fig. 4.3 Expansion of the area of inflammation in developing pulpitis.

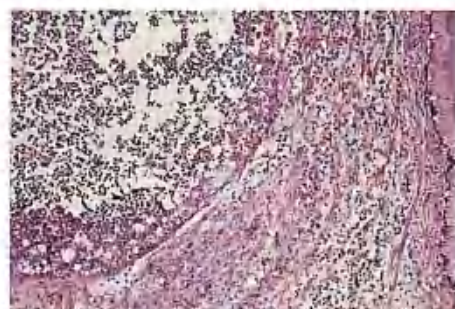


Fig. 4.4 Suppurative inflammation in the dental pulp progressing to abscess formation (top left of field).

prominent at this stage, but as the bacteria in the carious dentine reach the pulp, the vessels in the area become dilated and congested (Fig. 4.2). As the inflammatory exudate develops (Fig. 4.3) the local microcirculation may be compromised, leading to local death of tissue as previously described. This predisposes to suppuration due to the progressive accumulation of neutrophil leucocytes which release their lysosomal enzymes when they die. Suppuration may be local, forming a pulp abscess (Figs 4.4, 4.5), or may spread diffusely through the pulp depending on the interplay of the variables outlined in Fig. 4.1. Immune reactions in the inflamed tissue may also contribute to the tissue damage.

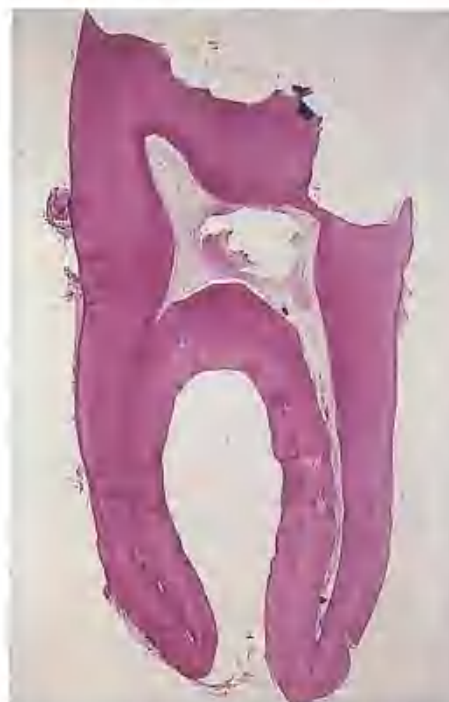

Fig. 4.5 Localized pulpitis with localized pulp abscess.

A pulp abscess may become static (or even reduce in size) if the pulp defences are sufficient to contain the level of bacterial challenge, in which case the area of suppuration is surrounded by a zone of proliferating granulation tissue (the so-called pyogenic membrane) as the damaged pulp undergoes organization and repair. In some cases the pus becomes walled off by fibrous tissue (Fig. 4.5), with temporary cessation of the spread of suppuration until such time as the level of bacterial challenge overcomes the host defences. In other cases the abscess may continue to expand due to continued tissue damage and massive emigration of neutrophils into the area of suppuration. As bacteria enter the inflamed tissue from the carious dentine most are destroyed by the neutrophil leucocytes and other host defence mechanisms; large numbers of bacteria are not generally seen in the pulp until the late stages of total irreversible pulpitis. If there is cavitation of the overlying carious dentine then the pus may drain into the mouth.

Although the rate of progression of pulpal inflammation is very variable, the end result of an untreated pulpitis is total pulp necrosis except in the case of pulp polyp formation (see below). However, in clinical practice, providing that the pulp is not cariously exposed and that the caries is successfully treated, healing of the pulp is the most likely outcome. In a grossly carious tooth where there is a risk of pulpal exposure then stepwise excavation of caries, over treatment intervals of 3 to 6 months, may reduce the bulk of the bacterial challenge sufficiently to allow the reactive defence mechanisms of the pulp to overcome the insult and for healing to take place.

Pulpitis resulting from irritants other than caries shows essentially similar histological changes, except that in some instances

Key points – Pulpitis

- Outcome depends on interplay between several factors:
 - nature/severity/duration of irritant
 - efficiency of pulpo-dentinal and general host defences
 - modifying factors that may compromise pulpal defences
- histopathological features and rates of progression variable but:
 - an immunological response in the subodontoblast zone can occur at an early stage
 - acute exudative changes occur in response to more severe irritation
 - the inflammatory exudate may increase tissue pressure and compromise local vascular supply
 - local ischaemia may lead to local necrosis and pulp abscess formation

the initial response is an acute exudative inflammation rather than a mononuclear inflammatory cell infiltration as the irritation to the pulp may be much more severe than that provided by caries.

Pulp polyp – chronic hyperplastic pulpitis

In deciduous or recently erupted permanent teeth with wide-open carious cavities and a good apical blood supply, pulpitis may be associated with a hyperplastic response characterised by the production of exuberant granulation tissue. This is seen most frequently in deciduous molars and first permanent molars. The wide-open pulpitis prevents build-up of tissue pressure compromising pulpal blood flow, and the good apical blood supply facilitates pulpal defence and repair. The hyperplastic granulation tissue protrudes beyond the boundaries of the pulp chamber to form a pulp polyp and such lesions are described as chronic hyperplastic pulpitis (Figs 4.6, 4.7). The polyp may become epithelialized by the spontaneous grafting of oral epithelial cells present in the saliva (Fig. 4.8). The origin of these epithelial cells is unknown. Most of the desquamated cells in saliva are degenerate superficial squames, incapable of further division. For the polyp to become epithelialized the grafted cells must be capable of division and subsequent differentiation into stratified squamous epithelium.

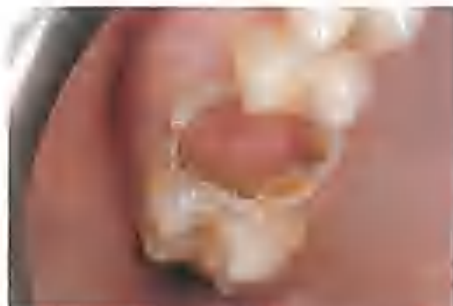

Fig. 4.6 Chronic hyperplastic pulpitis (pulp polyp).

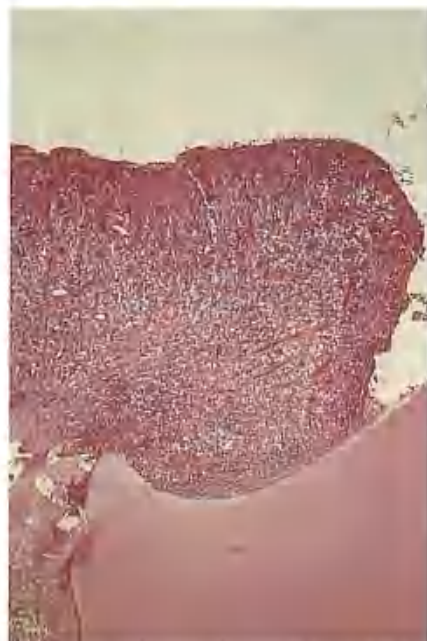


Fig. 4.7 Pulp polyp consisting of chronically inflamed, ulcerated, hyperplastic granulation tissue.

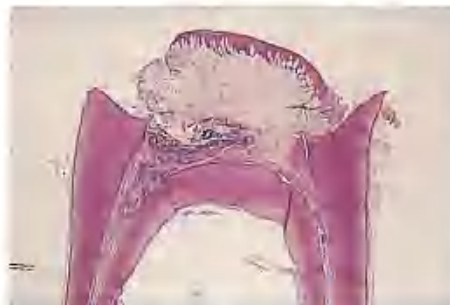

Fig. 4.8 Epithelialized pulp polyp.

Such cells must come from the region of the basal cell layer and might be released from trauma to the oral mucosa or from the gingival sulcus. Clinically, an ulcerated pulp polyp presents as a dark red, yellow-flecked (because of the fibrinous exudate) fleshy mass protruding from the pulp chamber, which bleeds readily on probing. In contrast, an epithelialized polyp is firmer, pinkish-white in colour, and does not bleed readily. They are both usually devoid of sensation on gentle probing.

Effects of cavity preparation and restorative materials

The speed of instrument rotation, heat, pressure, and coolants may all irritate the pulp tissue and cause pulpitis, particularly with increasing cavity depths. However, the main threat to the pulp is from frictional heat generated during the cutting process. Changes in the dental pulp in association with hard tissue ablation using lasers with water spray have been described as being

Key points – Restorative procedures and pulpal injury

- thermal injury is the main threat
- irreversible pulpal injury may occur with inadequate cooling
- in clinical practice most restorative materials appear to cause little/no irreversible pulpal injury
- variables that influence the potential for injury from a restorative material include:
 - residual dentine thickness
 - number of tubules opened – area of cavity floor
 - quality of the residual dentine – degree of sclerosis; extent of reactionary dentine formation
 - pre-existing state of the pulp

similar to those associated with a high-speed handpiece with water spray.

Additional histological changes often described in pulp reactions to restorative techniques and materials are aspiration or displacement of odontoblasts or their nuclei into the dentinal tubules and a reduction in the number of odontoblasts. Both these changes may be related to inflammatory oedema increasing local tissue pressure, the fluid displacing odontoblasts into dentinal tubules or collecting as vacuoles and compressing groups of odontoblasts together (so-called wheat-sheaving of odontoblasts) (Fig. 4.9). Aspiration of odontoblast nuclei may also be due to desiccation and the outward movement of the contents of the tubules during cavity preparation. It must be realized that early pulpitis following dentine caries may be further complicated by the effects of restorative techniques and materials, the response of the pulp being due to the combined effects of the different irritants.

Dental materials vary greatly in their ability to irritate the pulp, the dentine thickness between the pulp and the material often being critical in determining their effect. The nature of the dentine remaining may also affect the response, sclerosed dentine being less permeable than normal primary tubular dentine. A material which has little or no irritant effect when placed at the



Fig. 4.9 Wheat-sheaving of odontoblasts.

base of a cavity in the dentine may have a profound effect if it is directly applied to exposed pulp tissue, as in pulp capping.

Healing of pulp

Dentine trauma not directly involving the pulp may be followed by the displacement or aspiration of odontoblasts or their nuclei into the related dentinal tubules (for example during cavity preparation, see above). The clinical significance of these changes has not been established but such injuries could lead to the development of dead tracts (see Chapter 3).

Animal experiments have shown that it is possible for pulpitis to heal if the irritating agents are removed from the dentine. Localized pulp inflammation may resolve even when there is continuing dentinal caries, presumably due to a reduction in permeability of the dentine exposed to the bacterial products as a result of sclerosis and the formation of reactionary dentine.

In some cases where the pulp is exposed during cavity preparation, and following pulpotomy, it is possible to maintain pulp vitality by pulp-capping. Ideally, the capping agent should be non-irritant, should stimulate the formation of a calcific barrier, and have an antibacterial action as most pulp exposures are contaminated by saliva.

In clinical practice various preparations of calcium hydroxide are widely used as pulp-capping agents and have been shown to be effective, even though they are highly caustic, having a pH of about 12.5. Their application to an exposed pulp is followed rapidly by the formation of a necrotic zone next to the calcium hydroxide, and this is separated from the underlying normal tissue by a deeply basophilic zone probably consisting of calcium proteinates. Within 2 weeks (Fig. 4.10) a layer of coarse fibrous tissue develops next to the basophilic zone and beneath this a layer of odontoblast-like cells appears. After a further 2 weeks a calcified barrier with the characteristics of dentine starts to develop (Fig. 4.11).

This calcified barrier or dentine bridge is associated with a layer of odontoblast cells presumably derived from undifferentiated cells in the pulp. However, the quality of the barrier is very variable and about 90 per cent of dentine bridges contain multiple porosities which permit leakage of bacterial toxins into the

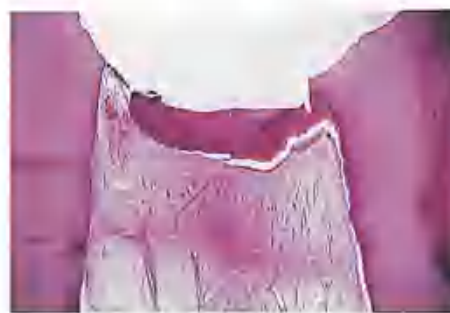

Fig. 4.10 Pulpotomy healing showing richly vascular zone of organization beneath the pulp-capping agent.

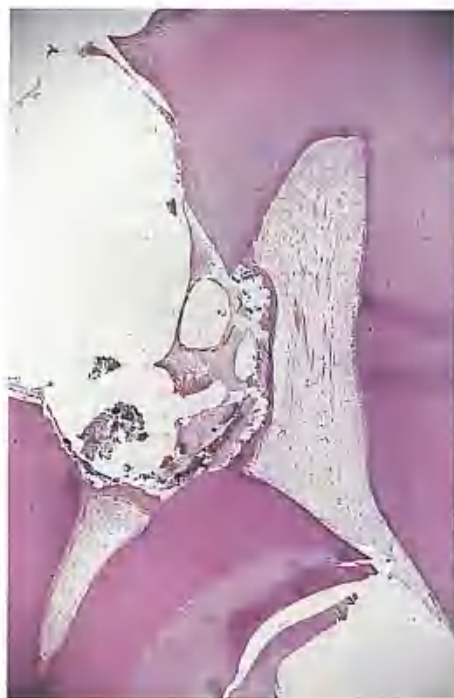

Fig. 4.11 Pulpotomy healing showing formation of calcified barriers bridging the pulpotomy wound.

pulp unless the cavity has been adequately sealed. Comparable healing to that obtained using calcium hydroxide has also been reported using a dentine adhesive system.

Pulp calcification

Pulp stones (or denticles) are calcified bodies with an organic matrix and occur most frequently in the coronal pulp. True pulp stones contain tubules (albeit scanty and irregular), and may have an outer layer of predentine and adjacent odontoblasts. False pulp stones (Fig. 4.12) are composed of concentric layers of calcified material with no tubular structure. According to their location in the pulp, stones may be described as free, adherent, or interstitial when they have become surrounded by reactionary or secondary dentine. Pulp stones increase in number and size with age and

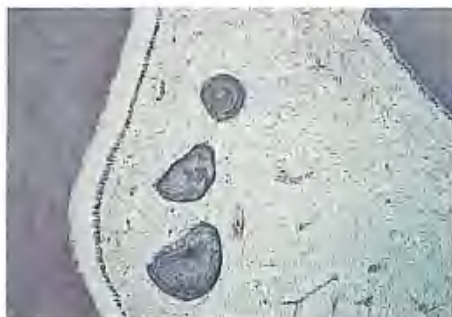

Fig. 4.12 Lamellated (false) pulp stones.



Fig. 4.13 Dystrophic calcifications in the radicular pulp.

are apparently more numerous after operative procedures on the tooth. When large they may be recognized on radiographs. They do not cause symptoms, although neuralgic pain has sometimes been attributed to their presence.

Dystrophic calcifications in the pulp consist of granules of amorphous calcific material which may be scattered along collagen fibres or aggregated into larger masses. They are most commonly found in the root canals (Fig. 4.13). Dystrophic calcifications and pulp stones may obstruct endodontic therapy.

Pulp obliteration may follow traumatic injury to the apical blood vessels which is not sufficient to cause pulp necrosis. Large quantities of irregular dentine form in the pulp chamber and root canals which become obliterated. Pulp obliteration is also seen in dentinogenesis imperfecta and dentinal dysplasia.

Pulp necrosis

Pulp necrosis may follow either pulpitis or a traumatic injury to the apical blood vessels cutting off the blood supply to the pulp. A coagulative type of necrosis is seen after ischaemia, but if the necrosis follows pulpitis then breakdown of inflammatory cells may lead to a liquefactive type of necrosis which may become infected by putrefactive bacteria from caries. This gangrenous necrosis of the pulp is usually associated with a foul odour when such infected pulps are opened for endodontic treatment.

Pulp necrosis has also been described in patients with sickle cell anaemia, following blockage of the pulp microcirculation by sickled erythrocytes.


Age changes in the pulp

The volume of the pulp gradually decreases with age due to the continued production of secondary dentine. Decreased vascularity, reduction in cellularity, and increase in collagen fibre content have also been reported, and these changes may impair the response of the tissue to injury and its healing potential. The reduction in pulp cell density is accompanied by reduction in the number of odontoblasts throughout adult life to about half their original number by age 70. The reduction is greater in the root than in the crown.

It is generally accepted that the prevalence of pulp stones and diffuse calcification increases with age but the evidence for this is inconclusive.

Further reading

- Baume, L. J. (1970). Dental pulp conditions in relation to carious lesions. *International Dental Journal*, 20, 309–37.
- Bender, I. B. (2000). Pulpal pain diagnosis – a review. *Journal of Endodontics*, 26, 175–9.
- Hafez, A. A., Kopel, H. M., and Cox, C. F. (2000). Pulpotomy reconsidered: application of an adhesive system to pulpotomised permanent primate pulps. *Quintessence International*, 31, 579–89.
- Heyeraas, K. J., Sveen, O. B., and Mjör, I. A. (2001). Pulp-dentin biology in restorative dentistry. Part 3: Pulpal inflammation and its sequelae. *Quintessence International*, 32, 611–25.
- Mjör, I. A. (2001). Pulp-dentin biology in restorative dentistry. Part 2: Initial reactions to preparation of teeth for restorative procedures. *Quintessence International*, 32, 537–51.
- Mjör, I. A. (2001). Pulp-dentin biology in restorative dentistry. Part 5: Clinical management and tissue changes associated with wear and trauma. *Quintessence International*, 32, 771–88.
- Mjör, I. A. and Ferrari, M. (2002). Pulp-dentin biology in restorative dentistry. Part 6: Reactions to restorative materials, tooth-restoration interfaces, and adhesive techniques. *Quintessence International*, 33, 35–63.
- Murray, P. E., Stanley, H. R., Matthews, J. B., Sloan, A. J., and Smith A. J. (2002). Age-related odontometric changes in human teeth. *Oral Surgery, Oral Medicine, Oral Pathology, and Endodontics*, 93, 474–82.
- Sheehy, E. C. and Roberts, G. J. (1997). Use of calcium hydroxide for apical barrier formation and healing in non-vital immature permanent teeth: a review. *British Dental Journal*, 183, 241–6.
- Trowbridge, H. O. (1981). Pathogenesis of pulpitis resulting from dental caries. *Journal of Endodontics*, 7, 52–60.



Periapical periodontitis

AETIOLOGY

Pulpitis and pulp necrosis

Trauma

Endodontic treatment

ACUTE PERIAPICAL PERIODONTITIS

CHRONIC PERIAPICAL PERIODONTITIS (PERIAPICAL OR APICAL GRANULOMA)

Sequelae

ACUTE PERIAPICAL ABSCESS AND SPREAD OF INFLAMMATION


Aetiology and microbiology

Routes of spread

Cellulitis

Ludwig's angina

FURTHER READING



Periapical periodontitis

Inflammation in the periapical area of the periodontal ligament is similar to that occurring elsewhere in the body. It is often accompanied by resorption of bone, and occasionally the root apex, sufficient to be detected radiographically. However, the periapical vascular network has a rich collateral circulation, greatly enhancing the ability of the tissue to heal if the cause of the inflammation is removed. This potential for complete periapical healing, providing the source of irritation is removed, is the basis of endodontic treatment.

Whether the response to irritation in the periodontal ligament is principally an acute or chronic inflammation depends on factors such as the number and virulence of any microorganisms involved, the type and severity of any mechanical or chemical irritant, and the efficiency of the host defences. While it is convenient to describe acute and chronic periapical periodontitis as separate conditions, it must be realized that the tissue reaction to irritation is a dynamic response, often vacillating with time between acute and chronic inflammation. The sequelae are deter-

mined by the balance between the nature, severity, and duration of the irritant and the integrity of the defence mechanisms of the patient.

Aetiology

The main causes of periapical periodontitis are detailed below.

Pulpitis and pulp necrosis

If pulpitis is untreated bacteria, bacterial toxins, or the products of inflammation will in time extend down the root canal and through the apical foramina to cause periodontitis. When pulp necrosis follows other causes, for example a blow to the tooth damaging the apical vessels, clinically significant periodontitis does not develop, unless bacteria gain access to the necrotic pulp or to the periapical tissues. The possible changes that may occur around the apex of an infected non-vital tooth and their inter-relationships are illustrated in Fig. 5.1.

Trauma

Occlusal trauma from, for example, a high restoration, undue pressure during orthodontic treatment, a direct blow on a tooth, and biting unexpectedly on a hard body in food may all cause minor damage to the periodontal ligament and localized inflammation. Traumatic periodontitis is often acute and transitory.

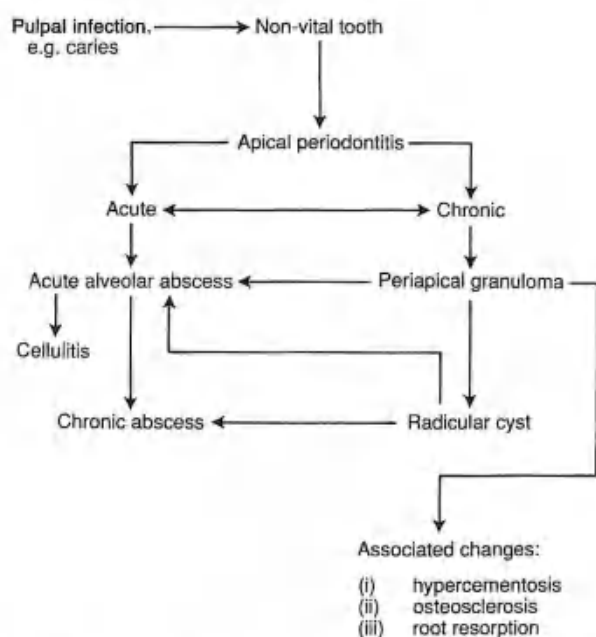


Fig. 5.1 Changes that may occur around the apex of an infected non-vital tooth.

Key points – Periapical periodontitis

- dynamic process; inflammation can vary with time
- outcome reflects the balance between the nature, duration, and severity of the irritant and the effectiveness of the host defences
- bacterial infection of the root canals is the major cause of clinically significant periodontitis
- can follow acute traumatic injury to periapical tissues without pulp necrosis; usually transient

1914
1915
1916
1917
1918
1919
1920
1921
1922
1923
1924
1925
1926
1927
1928
1929
1930
1931
1932
1933
1934
1935
1936
1937
1938
1939
1940
1941
1942
1943
1944
1945
1946
1947
1948
1949
1950
1951
1952
1953
1954
1955
1956
1957
1958
1959
1960
1961
1962
1963
1964
1965
1966
1967
1968
1969
1970
1971
1972
1973
1974
1975
1976
1977
1978
1979
1980
1981
1982
1983
1984
1985
1986
1987
1988
1989
1990
1991
1992
1993
1994
1995
1996
1997
1998
1999
2000
2001
2002
2003
2004
2005
2006
2007
2008
2009
2010
2011
2012
2013
2014
2015
2016
2017
2018
2019
2020
2021
2022
2023
2024
2025

Periapical periodontitis

Inflammation in the periapical area of the periodontal ligament is similar to that occurring elsewhere in the body. It is often accompanied by resorption of bone, and occasionally the root apex, sufficient to be detected radiographically. However, the periapical vascular network has a rich collateral circulation, greatly enhancing the ability of the tissue to heal if the cause of the inflammation is removed. This potential for complete periapical healing, providing the source of irritation is removed, is the basis of endodontic treatment.

Whether the response to irritation in the periodontal ligament is principally an acute or chronic inflammation depends on factors such as the number and virulence of any microorganisms involved, the type and severity of any mechanical or chemical irritant, and the efficiency of the host defences. While it is convenient to describe acute and chronic periapical periodontitis as separate conditions, it must be realized that the tissue reaction to irritation is a dynamic response, often vacillating with time between acute and chronic inflammation. The sequelae are deter-

mined by the balance between the nature, severity, and duration of the irritant and the integrity of the defence mechanisms of the patient.

Aetiology

The main causes of periapical periodontitis are detailed below.

Pulpitis and pulp necrosis

If pulpitis is untreated bacteria, bacterial toxins, or the products of inflammation will in time extend down the root canal and through the apical foramina to cause periodontitis. When pulp necrosis follows other causes, for example a blow to the tooth damaging the apical vessels, clinically significant periodontitis does not develop, unless bacteria gain access to the necrotic pulp or to the periapical tissues. The possible changes that may occur around the apex of an infected non-vital tooth and their interrelationships are illustrated in Fig. 5.1.

Trauma

Occlusal trauma from, for example, a high restoration, undue pressure during orthodontic treatment, a direct blow on a tooth, and biting unexpectedly on a hard body in food may all cause minor damage to the periodontal ligament and localized inflammation. Traumatic periodontitis is often acute and transitory.

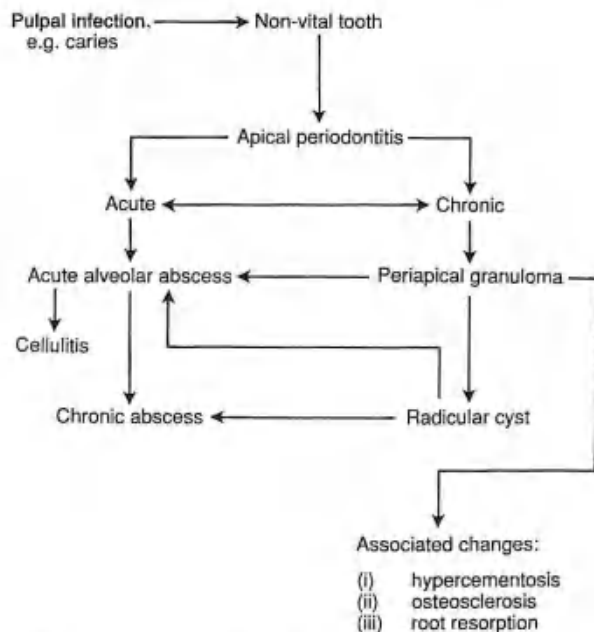


Fig. 5.1 Changes that may occur around the apex of an infected non-vital tooth.

Key points – Periapical periodontitis

- dynamic process; inflammation can vary with time
- outcome reflects the balance between the nature, duration, and severity of the irritant and the effectiveness of the host defences
- bacterial infection of the root canals is the major cause of clinically significant periodontitis
- can follow acute traumatic injury to periapical tissues without pulp necrosis; usually transient

Key points – Mnemonic for differential diagnosis of pain of pulpal and periapical origin – LOCATE

- Location
- Other symptoms
- Character
- Associations
- Timing
- Evaluation of other investigations, e.g. pulp vitality tests

Endodontic treatment

Mechanical instrumentation through the root apex during endodontic treatment, as well as chemical irritation from root-filling materials, may result in inflammation in the periapical periodontium. Instrumentation of an infected root canal may also be followed by periapical inflammation as a result of bacteria being forced inadvertently into the periapical tissues.

Acute periapical periodontitis

This is characterized by an acute inflammatory exudate in the periodontal ligament within the confined space between the root apex and the alveolar bone. Pain is elicited when external pressure is applied to the tooth because the pressure is transmitted through the fluid exudate to the sensory nerve endings. Even light touch may be sufficient to induce pain and, unlike pulpitis, this is generally well located by the patient to a particular tooth due to stimulation of proprioceptive nerve endings in the periodontal ligament. As the fluid is not compressible, the tooth feels elevated in its socket. Hot or cold stimulation of the tooth does not cause pain, as it would in pulpitis. The radiographic appearances are often normal as there is generally insufficient time for bone resorption to occur between the time of injury to the periodontal ligament and the onset of symptoms. If radiological changes are present, they consist of slight widening of the periodontal ligament and the lamina dura around the apex may be less well defined than normal.

The inflammation may be transient if it is due to acute trauma rather than infection and the condition soon resolves. If the irritant persists the inflammation becomes chronic and may be associated with resorption of the surrounding bone. Suppuration may occur if there is severe irritation and tissue necrosis associated with bacterial infection and the continued and massive exudation of neutrophil leucocytes leading to abscess formation. Such an abscess is called an acute periapical or alveolar abscess and, although such abscesses may develop directly from acute apical periodontitis (Fig. 5.1), most arise because of acute exacerbation within a pre-existing periapical granuloma (see below and Fig. 5.2).

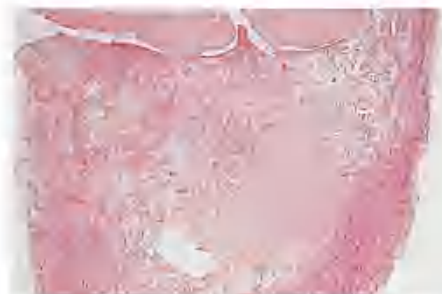


Fig. 5.2 Periapical granuloma with central zone of suppurative inflammation.

Chronic periapical periodontitis (periapical or apical granuloma)

Persistent irritation, usually derived from bacteria and their products in the pulp chamber and root canals, leads to chronic periapical periodontitis. This is characterized by resorption of the periapical alveolar bone and its replacement by chronically inflamed granulation tissue to form a periapical granuloma. Around the periphery of the lesion the chronic inflammatory stimuli may lead to the formation of dense bundles of collagen fibres that separate the chronically inflamed granulation tissue from the surrounding bone. These collagen fibres, forming a sort of capsule around the lesion, are attached to the root surface and in some cases the granuloma may be removed attached to the extracted tooth (Figs 5.3, 5.4).

Histologically the lesion consists mainly of granulation tissue infiltrated by lymphocytes, plasma cells, and macrophages and,

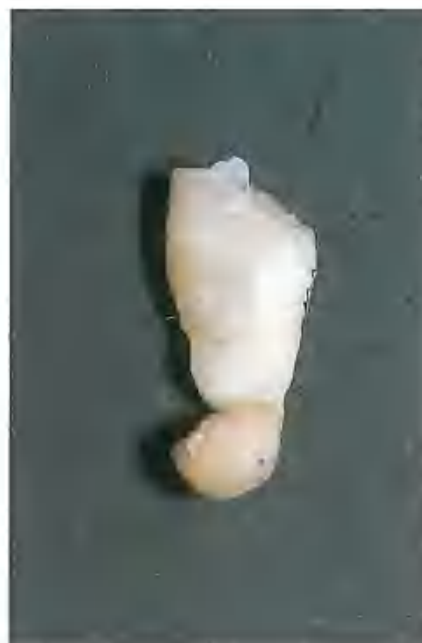

Fig. 5.3 Periapical granuloma attached to extracted root.

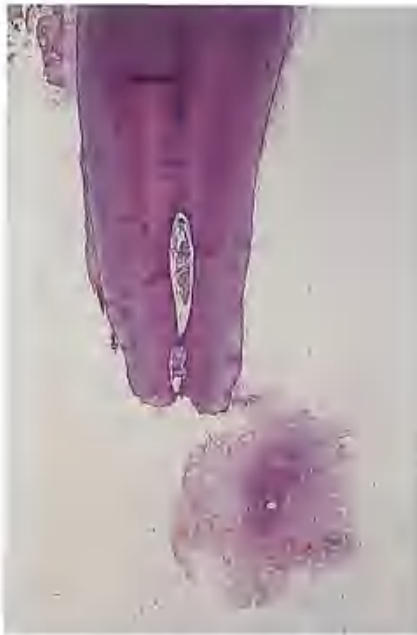


Fig. 5.4 Histological section of root and attached periapical granuloma from Fig. 5.3. Note the more heavily inflamed central area of the periapical granuloma (blue/purple stained), compared to the less inflamed, more collagenous peripheral zone.

although the composition of the inflammatory infiltrate varies considerably, T-lymphocytes predominate. Immunological reactions, in response to persistent antigenic stimulation derived from the pulp chamber and root canals, are key factors in the development of the lesion. In addition to the inflammatory infiltrate, deposits of cholesterol and haemosiderin are often present in a periapical granuloma and both are probably derived from the breakdown of extravasated red blood cells. Cholesterol crystals in the granulation tissue are represented in routine histological sections as empty needle-like spaces or clefts, the crystals having dissolved out in the reagents used in section preparation. Multinucleate foreign-body giant cells are grouped around the cholesterol clefts (Fig. 5.5). Foci of lipid-laden macrophages – foam cells – may also be seen (Fig. 5.6). Epithelial cell rests of Malassez incorporated within the granuloma may begin to proliferate, probably as a result of stimulation by growth factors released by a variety of cells within the granuloma (Fig. 5.7). The proliferated squamous epithelium forms anastomosing cords, often

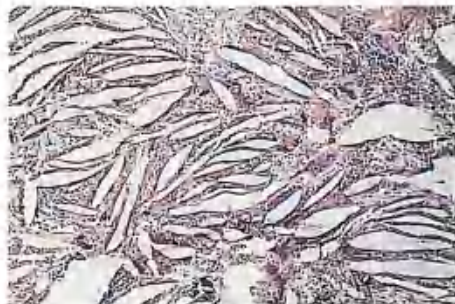

Fig. 5.5 Cholesterol clefts with associated foreign-body giant cells.

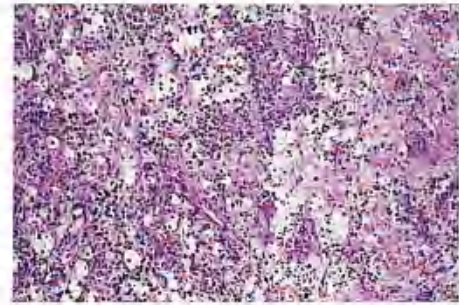


Fig. 5.6 Large, pale lipid-laden macrophages (foam cells) against a background of lymphocytes.

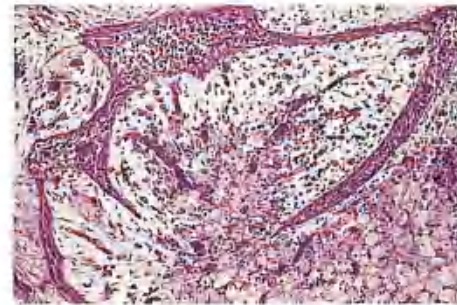

Fig. 5.7 Periapical granuloma containing proliferating strands of squamous epithelium.

arranged in loops or arcades, throughout the granulation tissue. Neutrophil leucocytes in varying stages of degeneration are often seen infiltrating the oedematous intercellular spaces of the epithelium.

Periapical granulomas tend to be asymptomatic, but may be associated with occasional tenderness of the tooth to palpation and percussion. Percussion may produce a dull note because of the lack of resonance caused by the granulation tissue around the



Fig. 5.8 Periapical radiolucency and apical resorption associated with a periapical granuloma.

apex. Radiological examination at first shows a widening of the periodontal ligament space around the apex and later a definite periapical radiolucency may develop. In some instances this radiolucency is well circumscribed and clearly demarcated from the surrounding bone by a corticated margin, while in others the border is poorly defined (Fig. 5.8). These appearances are related to differences in cellular activity around the margins of the lesion. Where there is active bone resorption and expansion of the lesion the margin is ill-defined. Where the lesion is static and a balance is established between the level of irritation and the host defences, the chronic inflammatory stimulus may lead to bone apposition and the formation of a zone of sclerosis around the lesion (see osteosclerosis (point 5) below). Histological evidence of external resorption of the apical cementum and dentine is frequent and is occasionally sufficient to be detected radiographically.

The importance of the root canal as a continued source of infection and antigenic challenge in an apical granuloma is shown by the fact that most periapical lesions heal once the canal is sealed by satisfactory endodontic treatment. The predominant organisms are obligate anaerobes (70 per cent or more) with smaller numbers of facultative anaerobes. Microorganisms surviving in the root canals or dentinal tubules after endodontic treatment may be important in teeth with persistent apical radiolucencies.

Sequelae (see Fig. 5.1)

1. If the level of antigenic challenge is in equilibrium with the host's immunological response, the granuloma can remain quiescent for long periods. However, if the equilibrium is disturbed in favour of the microbial flora in the root canal, the granuloma will continue to enlarge and be associated with continued resorption of bone, the process being symptomless, until equilibrium is restored.
2. When organisms invade the granuloma from the root canal acute exacerbation is likely and the patient may present with acute symptoms. Acute exacerbation can cause rapid enlargement of the lesion and may progress to abscess formation (see below). Alternatively, the inflammatory response may overcome the infection and a new equilibrium can be established.
3. Suppuration may occur in the granuloma (see Fig. 5.2). This may continue to enlarge to form an acute periapical (alveolar) abscess. Clinically this may present with rapid onset of pain, followed by redness and swelling of the adjacent soft tissues as the abscess tracks and points. The affected tooth is tender to percussion, and there may be slight mobility on palpation. Alternatively, the area of suppuration may be contained by the host's defences to form a chronic abscess that shows little tendency to enlarge or spread and which causes few, if any, clinical signs or symptoms until a further acute exacerbation.
4. Proliferation of the epithelial cell rests of Malassez associated with the inflammation may lead to the development of an inflammatory radicular cyst.

Key points – Periapical granuloma

- chronically inflamed granulation tissue around apex of a non-vital tooth
- infection and antigenic challenge from endodontic flora
- apical radiolucency; margins reflect dynamics of the lesion
- host response may be in equilibrium with level of irritation
- may be symptomless and remain quiescent for long periods
- stimulation and proliferation of rests of Malassez within the lesion



Fig. 5.9 Osteosclerosis around the roots of a mandibular molar.

5. Low-grade irritation to the apical tissues may result in bone apposition (osteosclerosis) rather than resorption, histologically a mild chronic inflammatory infiltrate being seen in the rather scanty, fibrous marrow. The process is clinically asymptomatic and shows as an opaque area of bone on radiographs (Fig. 5.9). On occasions, the opacity is well circumscribed while on others it shows no clear line of demarcation from the normal surrounding bone.
6. Low-grade irritation to the apical tissues may also result in the apposition of cementum on the adjacent root surface to produce hypercementosis.

Acute periapical abscess and spread of inflammation

Aetiology and microbiology

An acute periapical abscess may develop either directly from acute periapical periodontitis or more usually from a chronic periapical granuloma. It is generally the result of a mixed bacterial infection, culture of pus yielding a wide range of different species. Strict anaerobes are usually the predominant organisms, but micro-aerophilic (facultative) streptococci are frequently isolated (see Box 5.1). The relative pathogenicities of the bacteria isolated are not known and all isolates have to be regarded as of importance. Synergistic interactions between organisms will increase the severity of the infection.

Box 5.1 Frequently detected bacterial species in periapical abscesses

Microaerophilic streptococci	<i>'S milleri'</i> group, e.g. <i>S. anginosus</i>
Anaerobic streptococci	<i>Peptostreptococcus</i> species, e.g. <i>P. anaerobius</i>
Gram-positive anaerobic rods	<i>Actinomyces</i> species, e.g. <i>A. israelii</i> <i>Eubacterium</i> species, e.g. <i>E. lentum</i>
Gram-negative anaerobic rods (black-pigmented species important)	<i>Porphyromonas</i> species, e.g. <i>P. gingivalis</i> <i>Prevotella</i> species, e.g. <i>P. intermedia</i> <i>Bacteroides</i> species <i>Campylobacter</i> species <i>Fusobacterium</i> species, e.g. <i>F. nucleatum</i>

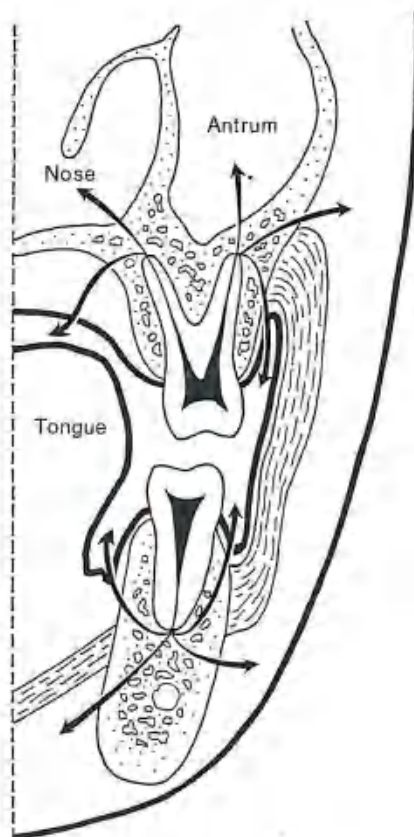


Fig. 5.10 Potential pathways of spread of pus from a periapical abscess.

Routes of spread

If the cause of the abscess is not removed, for example by extraction of the tooth, endodontic treatment, or antibiotic therapy, suppuration will continue and the abscess continues to enlarge. The increase in hydrostatic pressure within the abscess associated with progressive suppuration causes the pus to track in one of a number of directions (Fig. 5.10). It may drain through the root canal if this is open to the mouth or occasionally it may track through the periodontal ligament to discharge into the gingival sulcus. More commonly, the pus tends to track through the cancellous bone and eventually perforates the cortex. Most abscesses point buccally (Fig. 5.11) as the root apices lie closer to the buccal than to the lingual or palatal cortical plates. However, abscesses related to the apices of the maxillary teeth, particularly lateral incisors and the palatal roots of the molars and premolars, often track towards and point on the palate. Once the cortical plate is perforated the pus strips up the periosteum and may result in the formation of a subperiosteal abscess. More frequently, it penetrates the periosteum after which it may track in various directions. Although the apices of the roots of the mandibular second and third molars lie close to the lingual cortical plate, the bone in this area is very dense and is rarely penetrated.

After the pus has perforated the cortical plate its subsequent routes of spread are dictated largely by anatomical factors. The relationship of the cortical perforation (which itself is related to the position of the apex of the abscessed root) to the origins of muscles, for example buccinator and mylohyoid, and the strength of the overlying periosteum are important factors.

Possible outcomes are described below.

1. The pus may discharge directly into the oral cavity through a sinus following local penetration of the overlying periosteum and mucosa. This may occur with little or no pain and only a small swelling may develop on the oral mucosa before the pus breaks through. On other occasions the pus may accumulate beneath the mucosa and the patient may complain of a 'gumboil' before a sinus develops (see Fig. 5.11). A nodule of granulation tissue often forms in response to the irritation by pus and marks the opening of the sinus (Fig. 5.12).

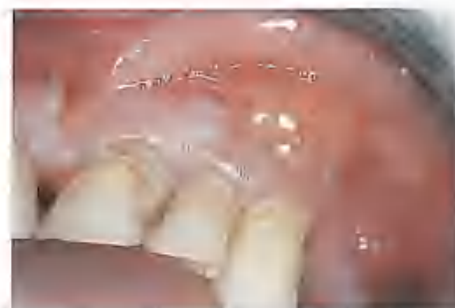

Fig. 5.11 Abscess related to maxillary canine pointing buccally.

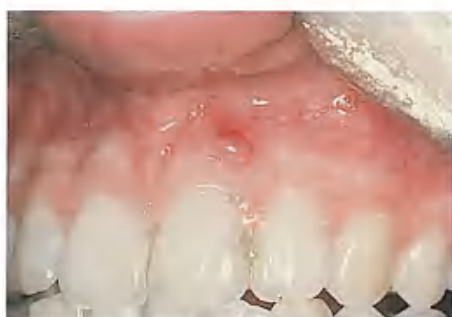

Fig. 5.12 Sinus opening related to abscess associated with maxillary central incisor.

2. The dense palatal mucoperiosteum is resistant to penetration by pus. Pus tracking palatally may spread under the mucoperiosteum posteriorly to the junction of the hard and soft palate and present as a palatal abscess (Fig. 5.13).

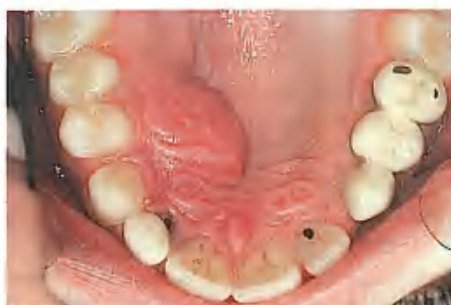

Fig. 5.13 Palatal abscess related to lateral incisor.

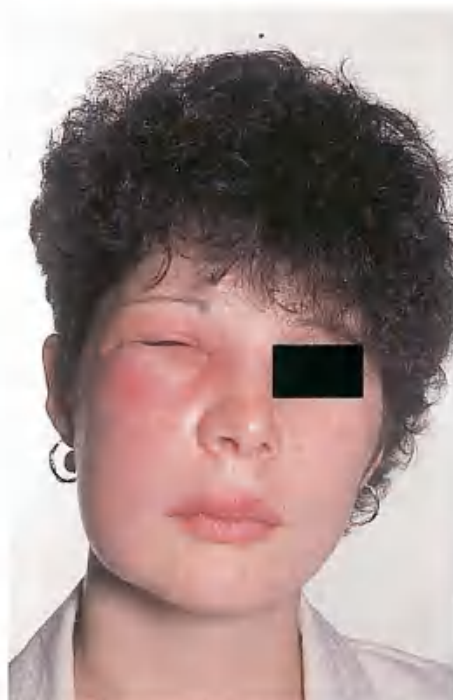

Fig. 5.14 Cellulitis associated with spread of inflammation from abscess related to a maxillary molar.

3. Abscesses in the molar region of either jaw may penetrate the buccal cortical plate above (in the maxilla) or below (in the mandible) the attachments of the buccinator muscle. In such cases acute inflammatory oedema and suppuration spread into the soft tissues of the face or neck. This may present as a cellulitis (Fig. 5.14) (see later) or less frequently as a localized soft-tissue abscess (Fig. 5.15) depending on the nature of the infection. Such an abscess may track towards the overlying skin to discharge through a sinus on the skin surface. The abscess may then become chronic with the sinus discharging pus periodically, associated with increasing fibrosis, scarring, and disfigurement (Fig. 5.16).
4. Abscesses related to anterior maxillary teeth may perforate the labial bone above the attachment of the levator anguli oris muscle. The infection may then pass medially and upwards towards the inner canthus of the eye, obliterating

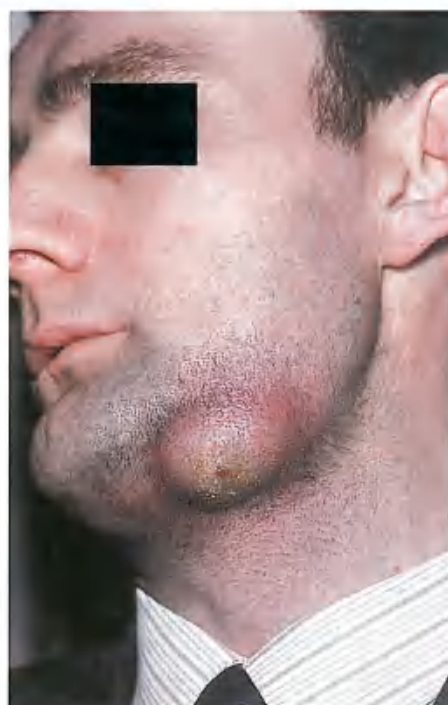

Fig. 5.15 Localized extraoral spread of abscess related to a mandibular molar.

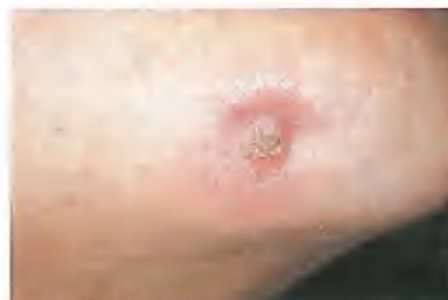

Fig. 5.16 Scarring associated with chronic extraoral sinus.

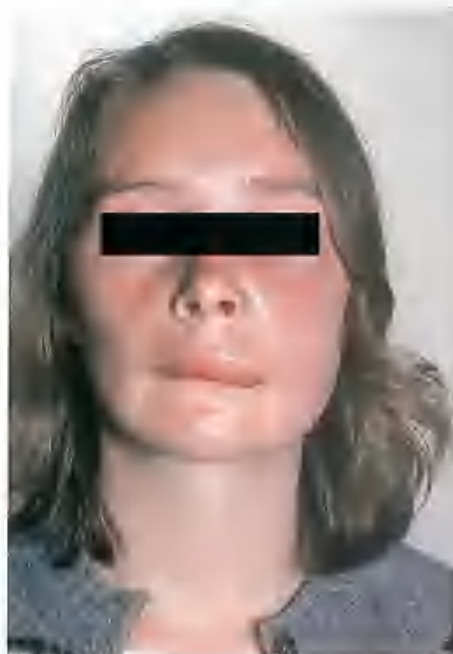

Fig. 5.17 Cellulitis associated with spread of inflammation from abscess related to an anterior maxillary tooth.

the nasolabial fold, and into the loose connective tissue of the lower eyelid. Alternatively, the infection may pass into the upper lip (Fig. 5.17).

5. Abscesses developing at the root apices of maxillary molars and premolars are very close to the floor of the maxillary sinus and consequently may discharge into the sinus.
6. An abscess related to a mandibular premolar or molar tooth may perforate the lingual plate of the mandible below the attachment of the mylohyoid muscle to involve the submandibular space. This causes a marked swelling at the lower border of the mandible spreading towards the neck. The submandibular space has communications with the

Key point – Acute periapical abscess

- usually arises as acute exacerbation in a periapical granuloma
- polymicrobial infection; anaerobic organisms predominate
- increase in hydrostatic pressure causes pus to track along lines of least resistance
- most periapical abscesses point buccally
- spread into soft tissues of face determined by relationship of abscess to muscle insertions
- cellulitis associated with streptococcal infections; organisms release 'spreading' enzymes, e.g. hyaluronidase, streptokinase

sublingual and lateral pharyngeal spaces, into which the infection may subsequently spread. An abscess in the submandibular region is separated from the skin by the deep fascia of the neck and so tends to track anteroposteriorly under the skin surface.

7. Pus from an abscess associated with a mandibular incisor or canine may track labially and perforate the bone below the insertion of the mentalis muscle and pass downwards to present as a subcutaneous abscess, most often in the midline between the points of attachment of the two mentalis muscles.

Cellulitis

Cellulitis is a rapidly spreading inflammation of the soft tissues particularly associated with streptococcal infections. It is not well-localized, in contrast to a circumscribed abscess, and the rapid spread is most likely related to release of large amounts of streptokinase and hyaluronidase which are produced by most strains of streptococci. Clinically, there is diffuse, tense, painful swelling of the involved soft tissues (see Figs 5.14, 5.17) usually associated with malaise and an elevated temperature. Much of the swelling is due to inflammatory oedema; suppuration and abscess formation occur later if treatment is neglected or delayed. Cellulitis associated with maxillary teeth initially involves the upper half of the face. Extension towards the eye is a potentially serious complication because of the risk of cavernous sinus thrombosis as a result of infection involving veins at the inner canthus of the eye which communicate with the cavernous sinus. Cellulitis associated with mandibular teeth initially involves the lower half of the face; extension into the submandibular and cervical tissues may cause respiratory embarrassment. Cellulitis spreading into the deeper surgical spaces usually presents clinically as pain and trismus rather than facial swelling.

Ludwig's angina

Ludwig's angina is severe cellulitis involving the submandibular, sublingual, and submental spaces, usually as a result of initial involvement of the submandibular space. Since the advent of antibiotics it is now rare. The diffuse cellulitis produces a board-like swelling of the floor of the mouth, the tongue being elevated and displaced posteriorly. As a result there is difficulty in eating, swallowing, and breathing. The latter is exacerbated as infection tracks backwards to involve the pharynx and larynx. Oedema of the glottis may occur with risk of death by suffocation.

Further reading

- Brauner, A. W. and Conrads, G. (1995). Studies into the microbial spectrum of apical periodontitis. *International Endodontic Journal*, 28, 244–8.
- Dahlen, G. (2002). Microbiology and treatment of dental abscesses and periodontal-endodontic lesions. *Periodontology* 2000, 28, 206–39.

- Marton, I. J. and Kiss, C. (2000). Protective and destructive immune reactions in apical periodontitis. *Oral Microbiology and Immunology*, 15, 139-50.
- Nair, P. N. R. (1997). Apical periodontitis: a dynamic encounter between root canal infection and host response. *Periodontology 2000*, 13, 121-48.
- Natkin, E., Oswald, R. J., and Carnes, L. I. (1984). The relationship of lesion size to diagnosis, incidence and treatment of periapical cysts and granulomas. *Oral Surgery, Oral Medicine, Oral Pathology*, 57, 82-94.
- Seltzer, S. and Farber, P. A. (1994). Microbiologic factors in endodontology. *Oral Surgery, Oral Medicine, Oral Pathology*, 78, 634-45.
- Stashenko, P., Teles, R., and D'Souza, R. (1998). Periapical inflammatory responses and their modulation. *Critical Reviews in Oral Biology and Medicine*, 9, 498-521.

Cysts of the jaws and oral soft tissues

CLASSIFICATION AND INCIDENCE OF CYSTS OF THE JAWS

ODONTOGENIC CYSTS: DEFINITION AND ORIGINS

Radicular cysts

Dentigerous and eruption cysts

Odontogenic keratocyst

Gingival cyst

Developmental lateral periodontal cyst

Paradental cyst

Glandular odontogenic cyst

NON-ODONTOGENIC CYSTS

Nasopalatine duct (incisive canal) cyst

Nasolabial cyst

Median cysts

NON-EPITHELIALIZED PRIMARY BONE CYSTS

Solitary bone cyst

Aneurysmal bone cyst

Stafne's idiopathic bone cavity

CYSTS OF THE SOFT TISSUES


Salivary mucoceles

Dermoid and epidermoid cysts

Lymphoepithelial cyst

Thyroglossal cyst

FURTHER READING



Cysts of the jaws and oral soft tissues

Classification and incidence of cysts of the jaws

Traditionally, a cyst is defined as a pathological cavity lined wholly or in part by epithelium, having fluid or semi-fluid contents. However, as there are a few cysts which do not have an epithelial lining an alternative and broader definition is that a cyst is a pathological cavity having fluid or semi-fluid contents, which has not been created by the accumulation of pus. Cysts of the jaws are more common than in any other bone, and the majority are lined wholly or in part by epithelium. Although the pathogenesis of many of these cysts is poorly understood, they are divided into two main groups depending on the origin of the lining epithelium.

1. *Odontogenic cysts*. The epithelial lining is derived from the epithelial residues of the tooth-forming organ. They can be

Table 6.1 Classification of cysts of the jaws

Epithelial cysts
<i>Odontogenic cysts</i>
Developmental
– Odontogenic keratocyst
– Dentigerous (follicular) cyst
– Eruption cyst
– Lateral periodontal cyst
– Gingival cyst
– Glandular odontogenic cyst
Inflammatory
– Radicular cyst (dental cyst)
(a) apical
(b) lateral
(c) residual
– Parodontal cyst
<i>Non-odontogenic cysts</i>
– Nasopalatine duct (incisive canal) cyst
– Nasolabial (nasolabial) cyst
– Median cysts
Non-epithelialized primary bone cysts
– Solitary bone cyst (simple, traumatic, haemorrhagic bone cyst)
– Aneurysmal bone cyst
– Stafne's idiopathic bone cavity

Table 6.2 Incidence of cysts of the jaws

Odontogenic cysts (90 %)		Non-odontogenic cysts (10 %)	
Radicular cysts	60–75 %	Nasopalatine cyst	5–10 %
Dentigerous cyst	10–15 %	Other non-odontogenic	
Keratocyst	5–10 %	and primary bone cysts	1 %
Paradental cyst	3–5 %		
Gingival cyst	} <1 %		
Lateral periodontal cyst			

subdivided into developmental and inflammatory types depending on their aetiology.

2. *Non-odontogenic cysts*. The epithelial lining is derived from sources other than the tooth-forming organ.

The classification of jaw cysts used in this chapter is given in Table 6.1. It is based on that recommended by the World Health Organization: the non-epithelialized, primary cysts of bone are appended. Stafne's idiopathic bone cavity is discussed in this chapter since, while it is not a cyst, it may be mistaken for such on a radiograph.

The incidence of each type of jaw cyst varies slightly from series to series and the figures given in Table 6.2 are approximations based on several reports. At least 90 per cent of all jaw cysts are of odontogenic origin.

Odontogenic cysts: definition and origins

By definition, the epithelial lining of these cysts originates from residues of the tooth-forming organ. There are three kinds of residue, each primarily responsible for the origin of a particular type of lesion.

1. The epithelial rests or glands of Serres persisting after dissolution of the dental lamina. These give rise to the odontogenic keratocyst. They may also be the origin of some developmental lateral periodontal and gingival cysts.
2. The reduced enamel epithelium which is derived from the enamel organ and covers the fully formed crown of the unerupted tooth. The dentigerous (follicular) and eruption cysts

Key points – Origins of odontogenic cysts

- derived from epithelial residues of the tooth-forming organ
- the main cyst types derived from each residue are:
 - dental lamina rests/glands of Serres
 - (i) odontogenic keratocyst
 - reduced enamel epithelium
 - (i) dentigerous cysts
 - (ii) paradental cyst
 - rests of Malassez
 - (i) radicular cysts

are derived from this tissue, as is the relatively uncommon inflammatory paradental cyst.

3. The rests of Malassez formed by fragmentation of the epithelial root sheath of Hertwig. All radicular cysts originate from these residues.

Radicular cysts

Clinical and radiographic features

Radicular cysts are subdivided into apical, lateral, and residual types depending on the anatomical relationship of the cyst to the root of the tooth.

Apical radicular cysts are the most common cystic lesions in the jaws and are always associated with the apices of non-vital teeth. They account for about 75 per cent of all radicular cysts. When small they are frequently symptomless and are usually discovered during routine radiological examination. As they enlarge they produce expansion of the alveolar bone and ultimately may discharge through a sinus. However, the majority of radicular cysts do not grow to large dimensions. The expansion of the alveolar bone is due to deposition of successive layers of new bone by the overlying periosteum. As the cyst enlarges and causes bone resorption centrally, increments of new subperiosteal bone are laid down to maintain integrity of the cortex, producing a bony-hard expansion. However, the rate of expansion tends to outstrip the rate of subperiosteal deposition, leading to progressive thinning of the cortex which can be deformed on palpation producing

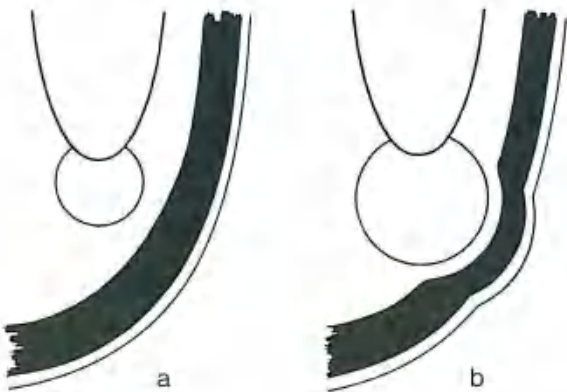


Fig. 6.1 Enlargement of a radicular cyst, a; producing bony expansion, b; and cortical thinning/egg-shell crackling, c.

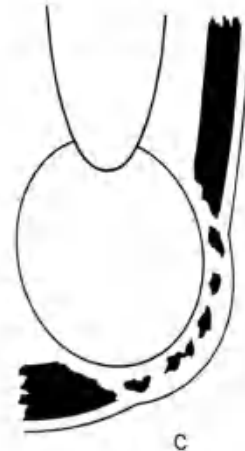the clinical signs of 'oil-can borboming' and 'egg-shell crackling' (Fig. 6.1). Eventually, the cyst may perforate the cortex and present as a bluish, fluctuant, submucosal swelling. The rate of expansion of radicular cysts has been estimated at approximately 5 mm in diameter per year.

Pain is seldom a feature unless there is an acute exacerbation which may rapidly progress to abscess formation.

The cysts can arise at any age after tooth eruption but are rare in the deciduous dentition. They are most common between 20 and 60 years of age and can occur in relation to any tooth in the arch. Radiographically, the apical radicular cyst presents as a round or ovoid radiolucency at the root apex (Fig. 6.2). The lesion is often well circumscribed and may be surrounded by a peripheral radiopaque margin continuous with the lamina dura of the involved tooth. The cyst develops within an apical granuloma and



Fig. 6.2 Radicular cyst presenting as a diffuse periapical radiolucency.



• male & female
 * 50% air found in maxilla
 * anterior teeth of maxilla / high incidence
 * pulp death from trauma
 - irritant RM is more likely in the anterior teeth rather than other sites.

Key points – Radicular cysts

- apical, residual, or lateral sub-types
- apical is commonest type
- associated with non-vital tooth
- apical radiolucency indistinguishable from a periapical granuloma
- may be symptomless
- enlargement of cyst leads to bone expansion



Fig. 6.3 Radiographic appearances of a residual cyst.

whether or not an apical radiolucency represents a granuloma or a cyst cannot reliably be determined from the radiographic features. On average, 40 per cent or more of apical radiolucencies are cystic.

The other varieties of radicular cyst are less common. The residual cyst is a radicular cyst that has remained in the jaw and failed to resolve following extraction of the involved tooth (Fig. 6.3). About 20 per cent of radicular cysts are of this type. However, it should be noted that most periapical inflammation will resolve after removal of the causative agent. The reasons why some lesions persist as residual cysts are unknown. The lateral type is very uncommon and arises as a result of extension of inflammation from the pulp into the lateral periodontium along a lateral root canal.

Pathogenesis

Radicular cysts arise from proliferation of the rests of Malassez within chronic periapical granulomas (Fig. 6.4), but not all granulomas progress to cysts. The factors which determine why cystic transformation occurs in some, and the mechanisms involved in the formation of the cyst are controversial. Persistence of chronic inflammatory stimuli derived from the necrotic pulp, particularly bacterial endotoxin, appears essential since, as mentioned above, most periapical inflammation will resolve spontaneously once the causative agent has been removed. It is assumed that the environment within the chronically inflamed granuloma, which is likely to be rich in cytokines including growth factors, stimulates the rests of Malassez to proliferate. Strands and sheets of squamous

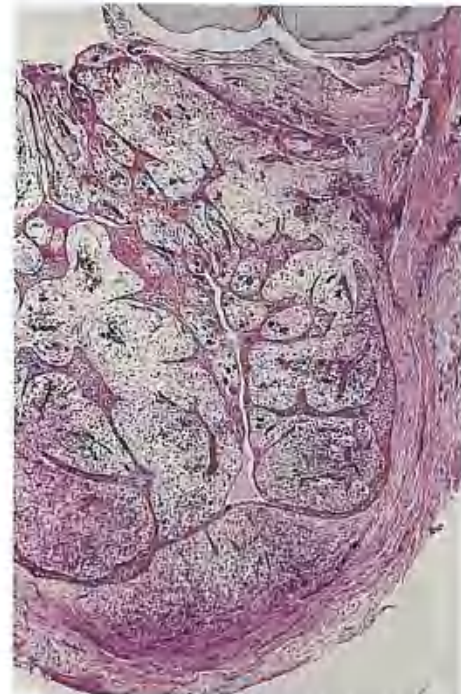

Fig. 6.4 Periapical granuloma containing proliferating arcs of squamous epithelium derived from the rests of Malassez showing early cystic breakdown.

epithelium derived from proliferation of the rests are common findings in periapical granulomas.

The mechanism of formation of an epithelial-lined cyst cavity within the granuloma is unclear. Two main mechanisms have been proposed:

1. Degeneration and death of central cells within a proliferating mass of epithelium. Epithelium is avascular and transport of metabolites and gaseous exchange occur by diffusion. It is argued that when the mass of proliferating epithelium within a granuloma reaches a critical size the central cells (furthest away from the surrounding vascular bed) degenerate and die. The microcyst so formed (Fig. 6.5) then continues to expand.

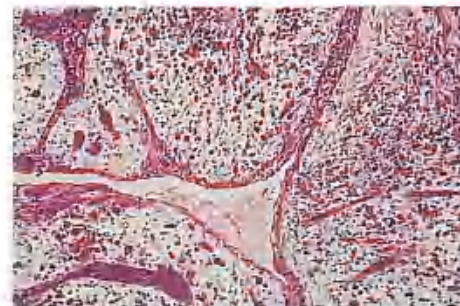


Fig. 6.5 Early (microcyst) formation associated with epithelial breakdown within the lesion shown in Fig. 6.4.

2. Degeneration and liquefactive necrosis of granulation tissue. It is suggested that areas of granulation tissue within the granuloma may undergo necrosis due to enclavement by proliferating strands of epithelium or to release of toxic products from the dead pulp or from infecting organisms. Epithelial proliferation to surround such an area of necrosis results in the formation of a cyst.

Histopathology

Radicular cysts are lined wholly or in part by non-keratinized stratified squamous epithelium supported by a chronically inflamed fibrous tissue capsule. In some cases the cyst may surround the root apex and such lesions have been referred to as 'pocket cysts' (Fig. 6.6). It has also been suggested that this type is more likely to heal after endodontic treatment. However, most radicular cyst cavities are separated from the apex by the chronically inflamed capsule.

In newly formed cysts the epithelial lining is irregular and may vary considerably in thickness (Fig. 6.7). Hyperplasia is a promi-

nent feature resulting in long anastomosing cords of epithelium (see Fig. 6.4) forming complex arcades extending into the surrounding capsule. The latter is richly vascular and diffusely infiltrated by inflammatory cells.

In established cysts the epithelial lining is more regular in appearance and of fairly even thickness (Fig. 6.8). Breaks in the lining – epithelial discontinuities – are common (Fig. 6.9). Metaplasia of the epithelial lining may give rise to mucous cells, found in about 40 per cent of radicular cyst linings and, more rarely, ciliated cells and areas of respiratory-type epithelium. In approximately 10 per cent of cases the lining contains hyaline eosinophilic bodies – Rushton bodies – of varying size and shape (Fig. 6.10). They appear to have no clinical or diagnostic significance and their origin is unknown, but they may represent some type of epithelial product.

With time, the connective tissue capsule tends to become more fibrous and less vascular and there is a reduction in the density of the inflammatory cell infiltration.



Fig. 6.6 Decalcified section showing cyst cavity and chronically inflamed cyst wall associated with a grossly carious root.

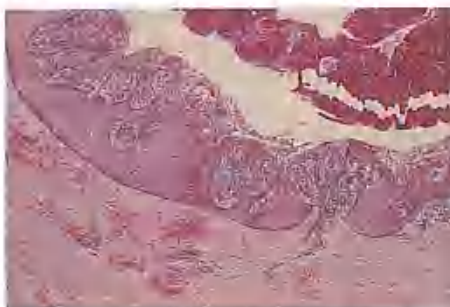

Fig. 6.7 Early radicular cyst showing variation in thickness of the epithelial lining.




Fig. 6.8 Epithelial lining of an established radicular cyst.

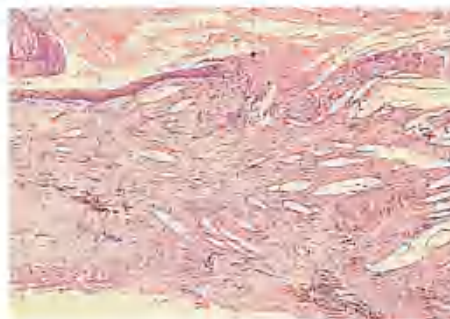


Fig. 6.9 Epithelial discontinuity in a radicular cyst associated with a mural cholesterol deposit.

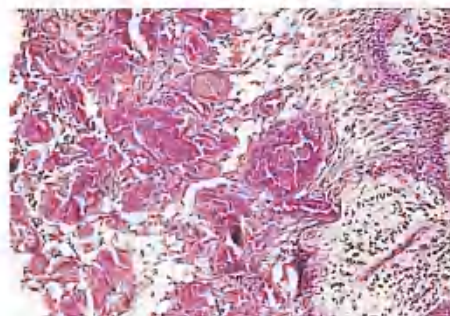


Fig. 6.10 Radicular cyst with numerous Rushton bodies.

Deposits of cholesterol crystals are common within the capsules of many radicular cysts. In histological sections cholesterol clefts may be few in number or form large mural nodules, in which case they are often associated with epithelial discontinuities and project into the cyst lumen (see Fig. 6.9). They are the probable origin of cholesterol crystals found in the cyst fluid. Mural cholesterol clefts are associated with foreign-body giant cells. As in periapical granulomas the cholesterol is probably derived from the breakdown of red blood cells as a result of haemorrhage into the cyst capsule, and deposits of haemosiderin are commonly associated with the clefts (Fig. 6.11).

Cyst contents

The cyst contents vary from a watery, straw-coloured fluid through to semi-solid, brownish material of paste-like consistency (Fig. 6.12). Cholesterol crystals impart a shimmering appearance.

The composition of cyst fluid is complex and variable. It is hypertonic compared with serum and contains:

1. Breakdown products of degenerating epithelial and inflammatory cells, and connective tissue components.
2. Serum proteins. All groups of serum proteins are present in cyst fluid and the soluble protein level is 5–11 g/dl. Most are derived as an inflammatory exudate. Compared with serum the fluid contains higher levels of immunoglobulin which probably reflects local production by plasma cells in the capsule.
3. Water and electrolytes.
4. Cholesterol crystals.



Fig. 6.11 Cholesterol clefts and haemosiderin deposit (blue). Perl's reaction.



Fig. 6.12 Bisected radicular cyst showing greyish-yellow cyst fluid.

Key points – Radicular cysts

- develop within apical granulomas
- lining derived from rests of Malassez
- lined by non-keratinizing squamous epithelium
- supported by a chronically inflamed capsule
- capsule may contain collections of cholesterol (appears as clefts histologically)
- contents variable but hypertonic

Cyst expansion

Once formed, radicular cysts tend to continue to expand equally in all directions, rather like a balloon. The rate of expansion is governed by the rate of local bone resorption and, as bone is resorbed, the hydrostatic pressure of the contents causes the cyst to enlarge. Bone resorption is associated with activation of osteoclasts by prostaglandins and cytokines released by inflammatory and other cells within the capsule. The hydrostatic pressure of the cyst fluid is increased because the contents are hypertonic compared with serum and water is drawn into the cyst cavity along this osmotic gradient (see Box 6.1 and Figs 6.13, 6.14)

It has been demonstrated *in vitro* that explants of cyst lining release bone resorbing factors which stimulate osteoclastic activity, amongst which prostaglandins, especially PGE₂, PGF₂, and PGI₂, may be particularly important. They are probably derived mainly from fibroblasts in the cyst capsule. Degradation of the bone matrix following demineralization by osteoclasts involves the action of various proteinases, particularly collagenase which may also be synthesized by capsular fibroblasts. Both prostaglandin and collagenase production by fibroblasts are increased by the action of various cytokines which are known to stimulate osteolytic activity and which may be generated locally. Interleukin-1 and interleukin-6 may be particularly important and may be synthesized by the epithelial lining itself as well as by macrophages and other cells within the capsule (Fig. 6.13). (For further discussion of mechanisms involved in pathological resorption of bone see Chapter 7.)

Because of the large number of osmotically active molecules in cyst fluid, the cyst contents are hypertonic compared with serum. The cyst wall acts as a semipermeable membrane, freely allowing the passage of water and crystalloids but restraining

Key points – Cyst expansion

- bone resorption allows –
- cyst expansion due to –
- hydrostatic pressure created by –
- osmotic gradient

Box 6.1 Cyst expansion

- Cyst expansion is dependent on osteoclastic resorption of surrounding bone. Osteoclasts are derived from haematopoietic precursors and are transported via the blood.
- Osteoclasts are recruited to and activated at sites of resorption by mediators. The cytokines interleukin-1 and interleukin-6 (IL-1, IL-6), tumour necrosis factor, and prostaglandin E₂ are key mediators in cyst expansion.
- Mediators are generated locally by a variety of cells, e.g. macrophages, lymphocytes, epithelial cells, fibroblasts.
- Activated osteoclasts attach to the bone surface and release acid resulting in demineralization. The organic matrix is then degraded by matrix metalloproteinases (MMPs), collagenases, and lysosomal proteases.
- MMPs synthesized by other cells in the cyst wall, e.g. fibroblasts, epithelial and inflammatory cells, may contribute to matrix degradation.
- Bone resorption is followed by cyst expansion which may involve hydrostatic pressure.
- Cyst contents are hypertonic. The wall acts as a semi-permeable membrane and retains the osmotically active molecules in the lumen, creating an osmotic gradient. Water moves into the lumen, along the gradient, increasing the hydrostatic pressure in the cyst, leading to enlargement.
- Enlargement is accompanied by growth of the lining and capsule. IL-1 and IL-6 stimulate epithelial proliferation. Other epithelial and fibroblast growth factors are also synthesized.

the passage of colloids. In addition, the cyst contents are virtually separated from the lymphatic drainage system. As a result, osmotically active molecules are retained within the cyst lumen. The high osmolality of the cyst contents and the semipermeable nature of the wall results in the movement of fluid from the tissues into the lumen along the osmotic gradient. This movement of fluid increases the hydrostatic pressure within the cyst causing it to expand in a unicentric ballooning pattern (Fig. 6.14).

Dentigerous and eruption cysts

A dentigerous cyst is one which encloses part or all of the crown of an unerupted tooth. It is attached to the amelocemental junction and arises in the follicular tissues covering the fully formed crown of the unerupted tooth (Fig. 6.15). Radiographically, other cysts may present in apparent dentigerous relationship. For example, an odontogenic keratocyst may envelop the crown of an impacted third molar and these extrafollicular lesions may be difficult to distinguish from true dentigerous cysts.

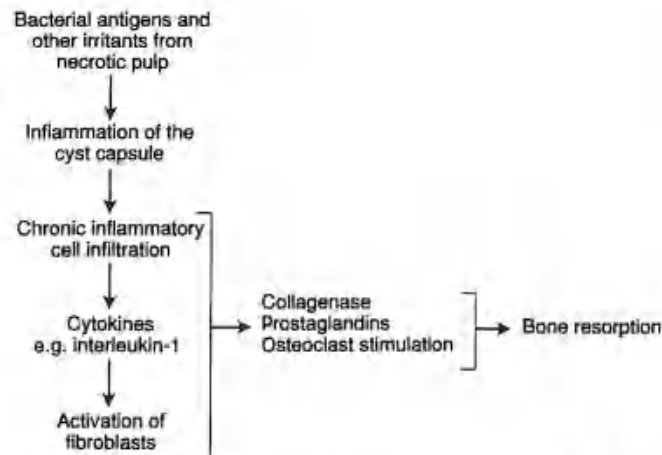


Fig. 6.13 Potential mechanisms of bone resorption in radicular cysts.

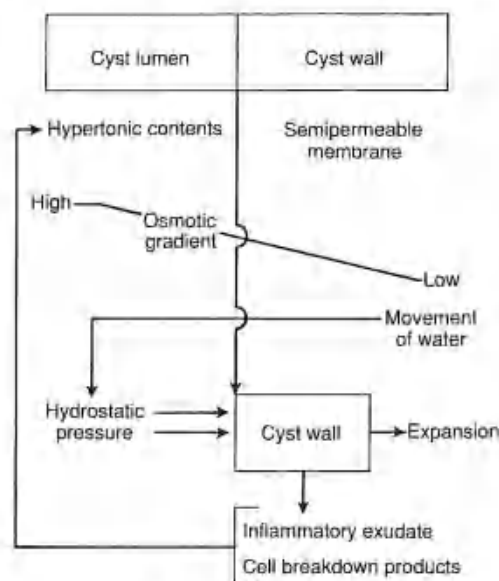


Fig. 6.14 Possible mechanisms involved in cyst expansion.

An eruption cyst is a true dentigerous cyst which arises in an extra-alveolar location.

Clinical and radiographic features

Dentigerous cysts occur over a wide age range and although many are detected in adolescents and young adults there is an increasing prevalence up to the fifth decade. They are about twice as common in males than in females and twice as common in the mandible than in the maxilla. The cysts most frequently involve teeth which are commonly impacted or erupt late. The majority are associated with the mandibular third molar and then, in order of decreasing frequency, the maxillary permanent canines, maxillary third molars, and mandibular premolars. Uncommonly, they are associated with supernumerary teeth or with complex and compound odontomes.

Although a tooth of the permanent series will be missing from the arch (with possible exceptions where a supernumerary or cystic odontome is responsible), a cyst may go undetected until

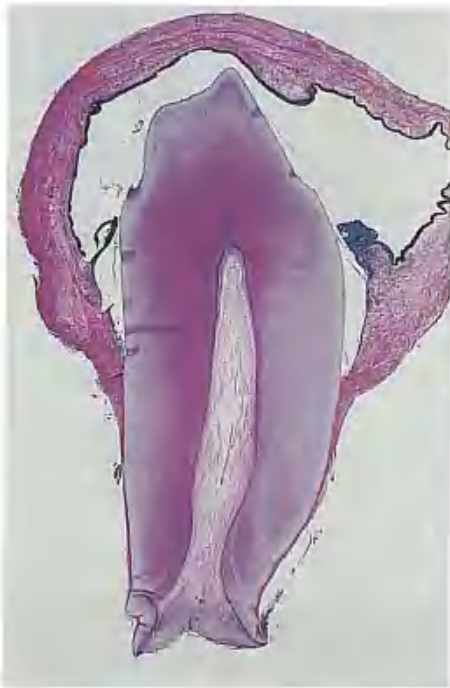

Fig. 6.15 Dentigerous cyst.

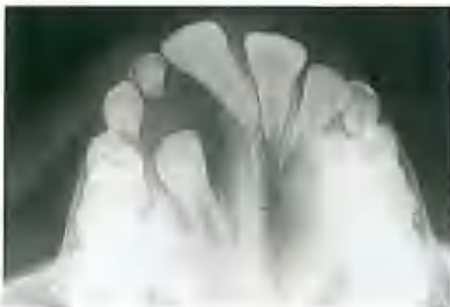

Fig. 6.16 Radiographic appearances of a dentigerous cyst.

it has enlarged sufficiently to produce expansion of the jaw. Alternatively, a cyst may be detected on routine radiographic examination or on seeking a cause for a retained deciduous tooth. Pain is not a feature unless there is secondary inflammation.

Radiographically, a dentigerous cyst presents as a well-defined unilocular, radiolucency associated in some way with the crown of an unerupted tooth (Fig. 6.16). The latter may be displaced for a considerable distance.

Eruption cysts involve both the deciduous and permanent dentitions. Because they arise in an extra-alveolar location they present as fluctuant swellings on the alveolar mucosa and are often bluish in colour (Fig. 6.17). Haemorrhage into the cyst cavity is common as a result of trauma (Fig. 6.18).

Pathogenesis and expansion

Dentigerous cysts develop from the follicular tissues, but the stimulus is unknown and the mechanism of cyst formation unclear. Although they are associated with unerupted teeth it has

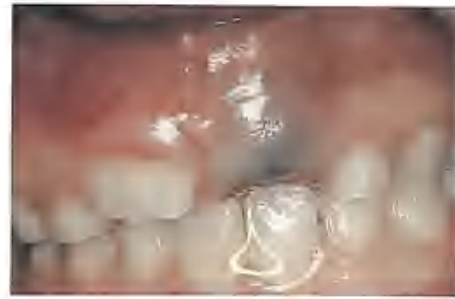

Fig. 6.17 Eruption cyst.

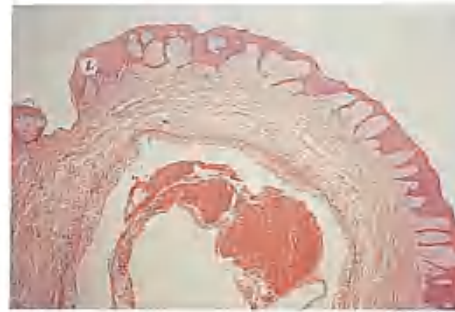


Fig. 6.18 Part of an eruption cyst (removed to expose underlying tooth) showing epithelial-lined cyst cavity beneath the mucosa.

been estimated that only about 1 per cent of such teeth develop cysts and other unidentified factors must, therefore, be involved.

The cyst develops between the crown of the unerupted tooth and the reduced enamel epithelium, but the mechanisms of cyst formation are unknown. One hypothesis suggests that compression of the follicle by a potentially erupting but impacted tooth increases the venous pressure in the follicle, leading to increased transudation of fluid. Pooling of this transudate separates the follicle from the crown, resulting in cyst formation. Another hypothesis suggests that the cysts arise as a result of proliferation of the outer layers of the reduced enamel epithelium, as would normally occur in tooth eruption, followed by breakdown of cells within the epithelial islands, leading to cyst formation.

In a few cases a cyst may arise as a result of spread of periapical inflammation from a deciduous predecessor to involve the follicle of the permanent successor, accumulation of inflammatory exudate leading to cyst formation. These inflammatory dentigerous cysts most often involve premolar teeth and are much more common in the mandible than in the maxilla.

The mechanism of expansion of dentigerous cysts is probably similar to that of radicular cysts. Bone resorbing factors, including prostaglandin E_2 and interleukin-1, are produced by the cysts and the contents are hypertonic compared with serum.

The rate of cyst expansion in children may be rapid but enlargement is much slower in adults.

Macroscopic features and histopathology

Macroscopic examination of intact specimens reveals a cyst attached to the amelocemental junction. In most cases the cyst

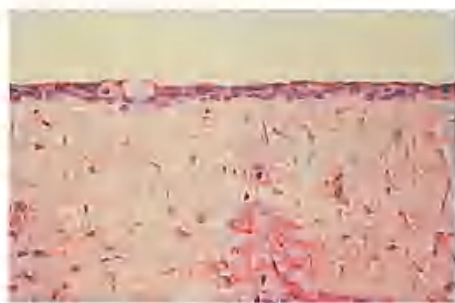


Fig. 6.19 Lining of dentigerous cyst.

completely surrounds the crown of the associated tooth (central type). Less frequently the cyst projects laterally from the side of the tooth and does not completely enclose the crown (lateral type).

The lining of dentigerous cysts is typically a thin, regular layer, some two to five cells thick, of non-keratinized stratified squamous or flattened/low cuboidal epithelium (Fig. 6.19). It resembles the reduced enamel epithelium from which it is derived. Mucous cell metaplasia is common and increases with age, and epithelial discontinuities are frequently observed. The lining is supported by a fibrous connective tissue capsule free from inflammatory cell infiltration, unless there has been secondary inflammation. Cholesterol clefts may be present and islands of odontogenic epithelium are occasionally observed. Occasionally, a cyst which clinically and radiographically appears to be a typical dentigerous cyst is lined by ameloblastomatous epithelium which proliferates into the cyst lumen. Such lesions are classified as unicystic ameloblastomas and are discussed in Chapter 15.

The cyst contains a proteinaceous, yellowish fluid, and cholesterol crystals are common. The soluble protein content is around 5–7 g/dl.

The lining of eruption cysts may be similar to that described above but is usually modified by chronic inflammation, possibly as a result of trauma. The latter also explains why many contain blood (see Fig. 6.18).

Key points – Dentigerous cysts

- most frequently involve impacted/late-erupting teeth
- develop between reduced enamel epithelium and crown
- surround part or all of the involved crown
- cyst attached to amelocemental junction
- lined by thin, non-keratinizing squamous epithelium; often shows mucous cell metaplasia
- non-inflamed capsule; may contain odontogenic epithelial rests
- eruption cyst is an extra-alveolar dentigerous cyst

Odontogenic keratocyst

The odontogenic keratocyst is a relatively uncommon lesion which has aroused much interest because of its unusual growth pattern and tendency to recur.

Clinical and radiographic features

Odontogenic keratocysts occur over a wide age range, but there is a pronounced peak incidence in the second and third decades with a second smaller peak in the fifth decade. The cysts are more common in males than females, and 70–80 per cent occur in the mandible. The most common site, accounting for at least 50 per cent of all cases, is the third molar region and ascending ramus of the mandible. In both the mandible and maxilla the majority of cysts occur in the region posterior to the first premolar.

Keratocysts give rise to remarkably few symptoms, unless they become secondarily inflamed, and this probably accounts for why some do not present until the fifth decade. Unlike radicular and dentigerous cysts which tend to expand in a unicentric ballooning pattern, keratocysts enlarge predominantly in an anteroposterior direction and can reach large sizes without causing gross bony expansion (Fig. 6.20). They are often discovered fortuitously on routine radiographic examination.

The majority of keratocysts arise sporadically and present as solitary lesions, although in a few patients two or more cysts may develop. Multiple cysts are associated with the naevoid basal cell carcinoma syndrome (Gorlin syndrome), inherited as an autosomal dominant trait with variable expressivity. It has numerous manifestations including:

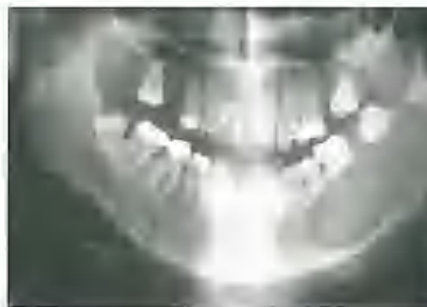

Fig. 6.20 Radiographic appearances of an odontogenic keratocyst.

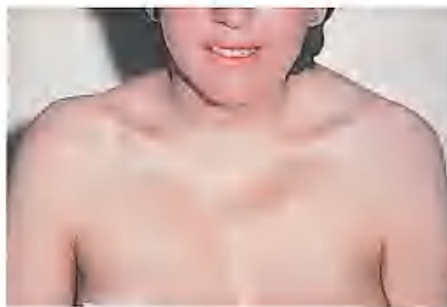


Fig. 6.21 Abnormal neck line associated with cervical ribs in a patient with naevoid basal cell carcinoma syndrome.

1. Skin: multiple naevoid basal cell carcinomas (about 90 per cent of cases). Unlike typical basal cell carcinomas which occur on sun-exposed skin in adults (see Chapter 10), naevoid basal cell carcinomas occur anywhere and commonly appear around the age of puberty.
2. Oral: multiple odontogenic keratocysts (about 90 per cent of cases). The cysts may arise at varying intervals throughout the lifetime of the patient but tend to appear earlier than single sporadic cases.
3. Skeletal: e.g. rib anomalies (Fig. 6.21), vertebral deformities, polydactyly, cleft lip/palate.
4. CNS: e.g. calcified falx cerebri (Fig 6.22), brain tumours.

The syndrome is caused by mutation of a tumour suppressor gene on chromosome 9q which plays an important role in the normal growth and development of tissues and organs (see Box 6.2)

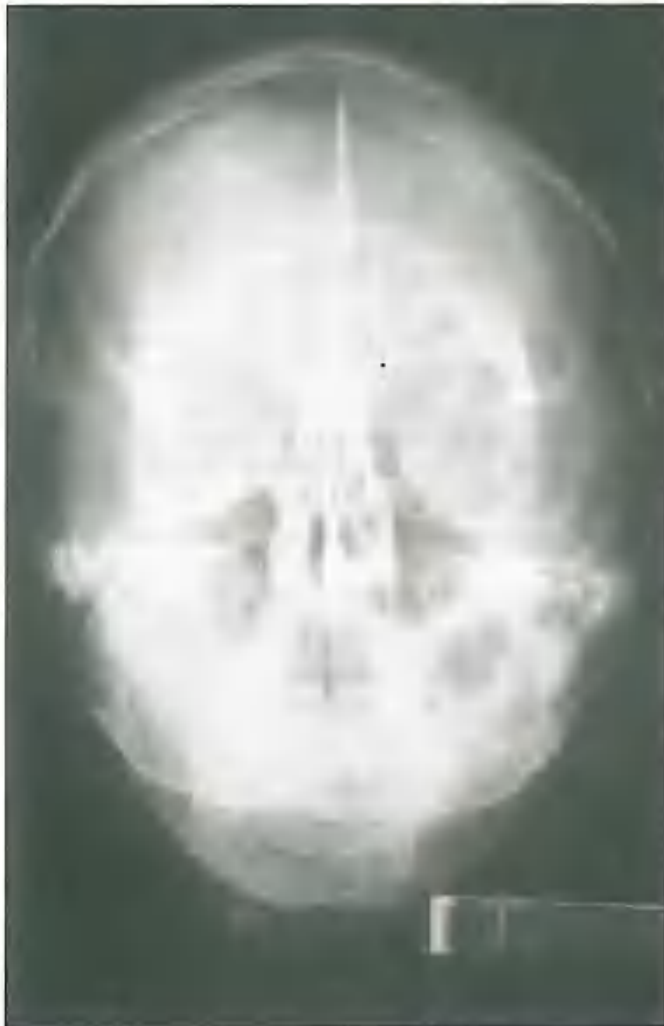

Fig. 6.22 Calcification of falx cerebri in a patient with naevoid basal cell carcinoma syndrome.

Key points – Odontogenic keratocysts

- bimodal age distribution – 2nd–3rd decades and 5th decade
- few symptoms; cause little expansion; may reach large size
- unilocular/multilocular radiolucency; may mimic dentigerous cyst
- more common in mandible than maxilla
- tendency to recur
- may be multiple; associated with naevoid basal cell carcinoma syndrome

The syndrome is uncommon, but patients with multiple keratocysts alone may be suffering from it in one of its least expressed forms.

An important clinical feature of keratocysts is their tendency to recur after surgical treatment. Recurrence rates vary in different reported series from around 3 per cent to about 60 per cent. It is likely that the rate is decreasing with improved management following recognition of this problem. Possible factors related to recurrence are discussed later.

Radiographically, keratocysts appear as well-defined radiolucencies that may be unilocular (Fig. 6.20) or multilocular. Many present in apparent dentigerous relationship associated with unerupted third molars but the crowns of such teeth are usually separated from the cyst cavity, the pericoronal tissues being continuous with the cyst capsule. Keratocysts may also present as developmental lateral periodontal cysts.

Box 6.2 Naevoid basal cell carcinoma syndrome (NBCCS)

- NBCCS is caused by mutation of a tumour suppressor gene on chromosome 9q termed the patched (PTCH) gene.
- PTCH encodes for a protein which represses transcription of the *Hedgehog* signalling network.
- The *Hedgehog* signalling network controls transcription of key genes involved in the development, patterning, and growth of numerous tissues and organs.
- Mutations in PTCH affect the normal function of the *Hedgehog* signalling network, which could account for the wide variety of manifestations of NBCCS.
- The range of features seen in an individual patient might be due to different mutations in the PTCH gene and to variations in their penetrance and expression.
- Mutations in PTCH have also been reported in sporadic odontogenic keratocysts.

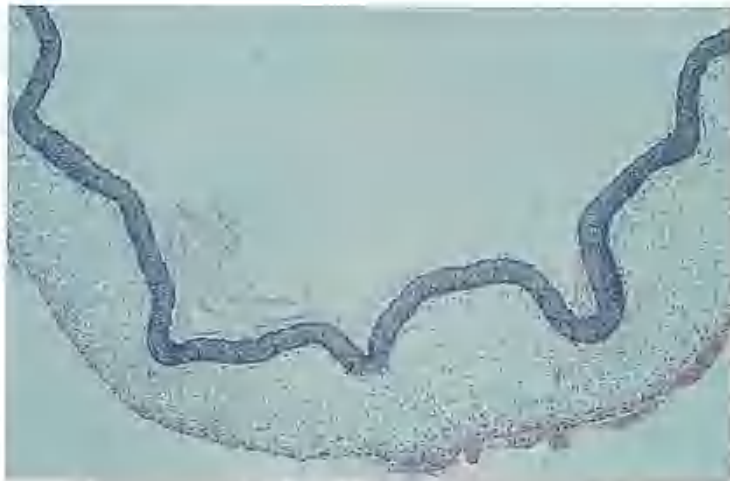

Fig. 6.23 Wall of an odontogenic keratocyst showing regular epithelial lining and thin capsule.

Histopathology

The cyst wall is usually thin and often folded and is lined by a regular continuous layer of stratified squamous epithelium some five to ten cells thick (Fig. 6.23). The basal cell layer is well defined and consists of palisaded columnar or occasionally cuboidal cells. The suprabasal cells resemble those of the stratum spinosum of oral epithelium and there is an abrupt transition between these and the surface layers which differentiate towards keratin production (Fig. 6.24). Parakeratosis predominates but areas of orthokeratinization are occasionally seen. The cells desquamate into the cyst lumen. Mitotic activity is higher than in other types of odontogenic cysts and mitotic figures are found in basal and suprabasal cells.

The fibrous capsule of the cyst is usually thin and generally free from inflammatory cell infiltration. If the cyst becomes secondarily inflamed the epithelial lining loses its characteristic histology and comes to resemble that of a radicular cyst. Small groups of

epithelial cells resembling dental lamina rests are often found in the capsule and these can give rise to independent satellite cysts around the main lesion (Fig. 6.25). Satellite cysts are usually small and often microscopic in size. Epithelial residues and satellite cysts are more common in cysts associated with the naevoid basal cell carcinoma syndrome. Retention of epithelial residues or satellite cysts when the main lesion is enucleated is one of the factors associated with the high recurrence rate of keratocysts. The thinness of the cyst wall and its low tensile and rupture strength compared with radicular cysts make enucleation more difficult and recurrence may thus follow retention of fragments of torn lining.

Keratocysts contain thick, grey/white cheesy material consisting of keratinous debris. There is little free fluid and the contents have a low soluble protein level, less than 4 g/dl, composed predominantly of albumin.

The term odontogenic keratocyst must not be used to describe any odontogenic cyst producing keratin, it refers to a specific clinicopathological entity. Other jaw cysts such as radicular and

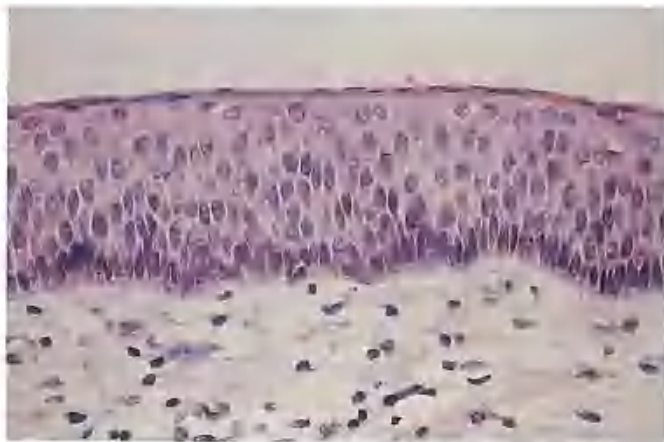


Fig. 6.24 Epithelial lining of odontogenic keratocyst showing palisaded basal cells and parakeratinization.

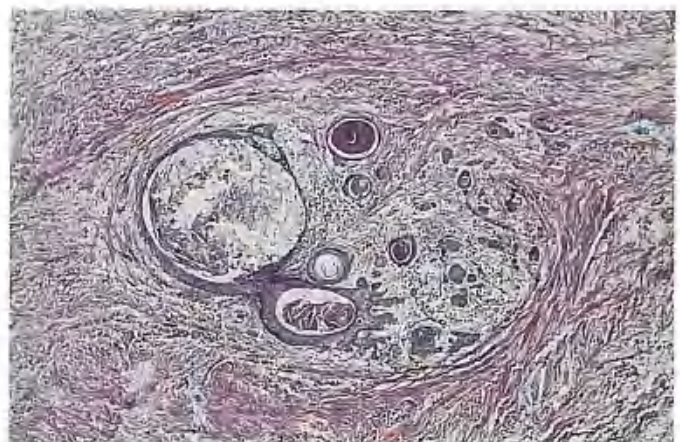

Fig. 6.25 Epithelial residues and satellite cysts associated with odontogenic keratocyst.

Key points – Odontogenic keratocyst

- thin, easily torn wall
- lined by an even layer of parakeratinized squamous epithelium
- palisaded basal cell layer
- contains keratinous debris
- satellite cysts in capsule

dentigerous cysts may, rarely, produce keratin by metaplasia, but the epithelial linings of such cysts are usually orthokeratinized and do not show the regular and ordered epithelial differentiation that characterize the odontogenic keratocyst.

Growth of the odontogenic keratocyst

The odontogenic keratocyst has an aggressive pattern of growth, burrowing through cancellous bone in a predominantly antero-posterior direction. (It has been proposed that this lesion be redesignated the 'keratinizing cystic odontogenic tumours' (see page 223).) As noted previously, this distinguishes it from the other odontogenic cysts which tend to expand equally in all directions, that is, in a unicentric ballooning pattern. The unique pattern of growth of the odontogenic keratocyst, in comparison to the other cysts, suggests that different mechanisms of enlargement are involved. The major factors are:

1. *Active epithelial growth.* The epithelial lining of keratocysts shows a higher rate of mitotic activity than other odontogenic cysts. The proliferation is not uniform but tends to occur in clusters, which may account for foldings in the cyst lining and projections of the cyst into cancellous spaces resulting in a multicentric pattern of growth. Abnormalities in expression of some of the key proteins controlling the cell proliferation cycle have also been reported, similar to those seen in neoplasia. The proliferative activity and altered expression of cell-cycle related proteins of the epithelial lining is higher in keratocysts associated with the naevoid basal cell carcinoma syndrome than in sporadic cysts.
2. *Cellular activity in the connective tissue capsule.* Active growth of the capsule occurs in association with the proliferating areas of the epithelium. Osteoclasts tend to be located around the tips of the projections of the lining which are proliferating into the cancellous spaces.
3. *Production of bone resorbing factors.* Like the radicular cysts the odontogenic keratocyst releases bone resorbing factors, including prostaglandins, collagenase, and interleukins -1 and -6. Some studies have shown that, in comparison to radicular cysts, keratocysts have less bone resorbing activity per unit surface area. However, it is likely that this is the result of the focal rather than uniform pattern of growth activity of the cyst wall, described above. The aggressive behaviour of keratocysts indicates that they are effective

Key points – Odontogenic keratocyst

- tendency to recur related to difficulty of surgical removal
 - thin, easily ruptured wall
 - projections into cancellous spaces easily torn
 - satellite cysts in capsule
- cyst enlargement involves
 - focal areas of active growth of the cyst wall
 - extension of proliferating areas along cancellous spaces
 - production of bone resorbing factors

resorbers of bone; recent studies have shown that fragments of keratocysts grown in culture secrete considerably more interleukin-1 than radicular or dentigerous cysts.

Increase in intracystic pressure, due to the hypertonic nature of the contents of keratocysts or to the accumulation of squamous debris within the lumen, is unlikely to be a significant factor in cyst expansion, and would not account for the biological behaviour of the lesion.

Gingival cyst

Gingival cysts (Fig. 6.26) are of little clinical significance. They are common in neonates when they are often referred to as Bohn's nodules or Epstein's pearls. Most disappear spontaneously by 3 months of age. They arise from remnants of the dental lamina which proliferate to form small keratinizing cysts.

Gingival cysts in adults are rare. It is likely that most represent developmental lateral periodontal cysts (see below) that have arisen in an extra-alveolar location. They occur most frequently in females and in the interpremolar region of the mandible.

Developmental lateral periodontal cyst

The developmental lateral periodontal cyst is an uncommon lesion that must be distinguished from a lateral radicular cyst associated with a non-vital tooth and from an odontogenic keratocyst arising alongside the root of a tooth.

Clinically, the lateral periodontal cyst occurs mainly in the canine and premolar region of the mandible in middle-aged

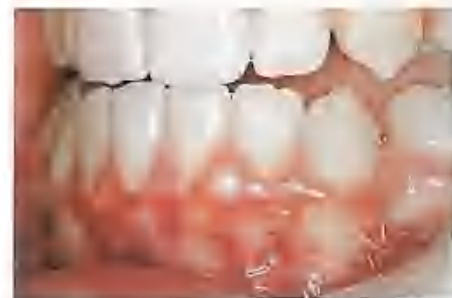

Fig. 6.26 Gingival cyst presenting as a pearly-white lesion between the central and lateral mandibular incisors.

patients. It may present with expansion or be discovered on routine radiographic examination as a well-defined radiolucent area with sclerotic margins.

Histologically, the cyst is lined by thin non-keratinized squamous or cuboidal epithelium resembling reduced enamel epithelium, with focal, plaque-like thickenings. Its pathogenesis is uncertain but it is probably derived from either the reduced enamel epithelium or rests of the dental lamina.

Occasionally, developmental lateral periodontal cysts are multilocular and may be described by the adjective 'botryoid' because of their resemblance to a bunch of grapes (botryoid odontogenic cyst).

Paradental cyst

This type of cyst arises alongside a partly erupted third molar involved by pericoronitis. Almost all occur in the mandible and most are buccally or distobuccally located (Figs 6.27, 6.28). The teeth associated with these cysts may show an enamel spur extending from the buccal cervical margin to the root furcation.

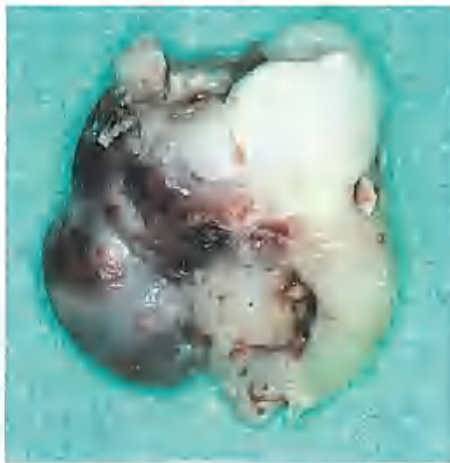

Fig. 6.27 Paradental cyst.

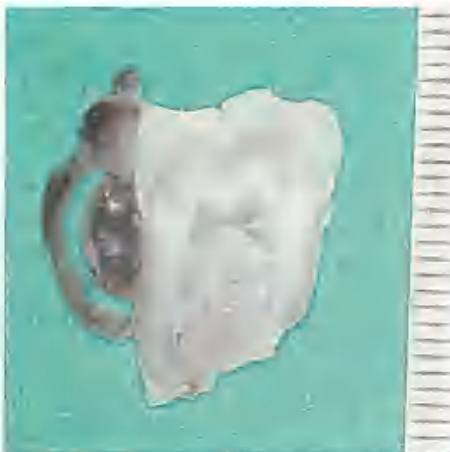


Fig. 6.28 Macroscopic section through cyst shown in Fig. 6.27.

Radiographically, they appear as well-defined radiolucencies related to the neck of the tooth and the coronal third of the root.

The cysts are of inflammatory origin and probably arise as a result of extension of inflammation stimulating proliferation and cystic change in the reduced enamel epithelium covering the unerupted part of the crown.

Histologically, paradental cysts resemble inflammatory radicular cysts.

Glandular odontogenic cyst

The glandular odontogenic cyst is a rare, developmental odontogenic cyst. Most have occurred in the anterior part of the mandible where they present as a slow-growing, painless unilocular or multilocular radiolucency.

Histologically, the cyst is lined by epithelium of varying thickness with a superficial layer of columnar or cuboidal cells and occasional mucous cells. Crypts or small cyst-like spaces are present within the thickness of the epithelium and the lining has a distinctly glandular structure. The cyst has a potentially aggressive, locally invasive nature and a tendency to recur.

Non-odontogenic cysts

Nasopalatine duct (incisive canal) cyst

The nasopalatine duct cyst is a distinct clinicopathological entity and is the commonest of the non-odontogenic cysts. It is a developmental lesion thought to arise from epithelial remnants of the nasopalatine duct which connects the oral and nasal cavities in the embryo. The stimulus for cystic change is unknown.

Clinical and radiographic features

The cyst presents most commonly in the fifth and sixth decades and occurs more frequently in males than in females. It may be asymptomatic and be discovered on routine radiographic examination, or present as a slowly enlarging swelling in the anterior region of the midline of the palate. Occasionally, it discharges into the mouth when the patient may complain of a salty taste. Pain may occur if the cyst becomes secondarily inflamed. Although cysts may arise at any point along the nasopalatine canal, most originate in the lower part and some arise entirely within the soft

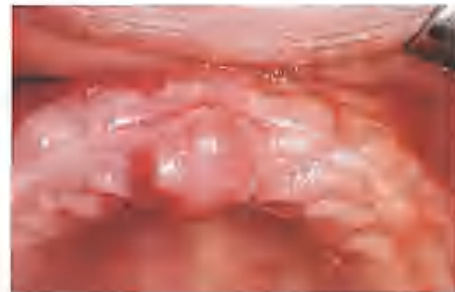

Fig. 6.29 Nasopalatine duct cyst presenting as a cyst of the papilla palatina.

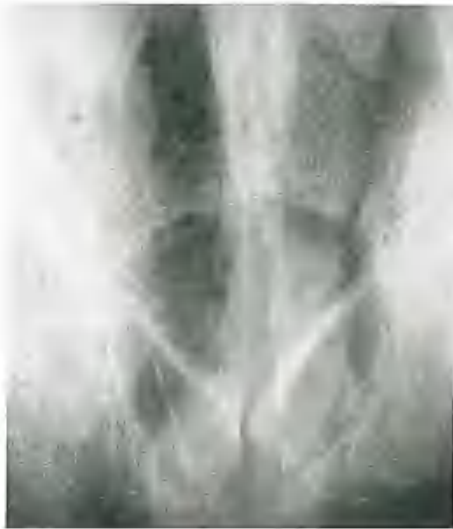

Fig. 6.30 Radiograph of nasopalatine duct cyst.

tissue of the incisive papilla. Such lesions are often designated cysts of the papilla palatina (Fig. 6.29).

Radiographically, nasopalatine duct cysts present as well-defined round, ovoid, or heart-shaped radiolucencies, often with a sclerotic rim (Fig. 6.30). They are usually symmetrical about the midline but some are displaced to one side. The cyst must be distinguished from the normal incisive fossa and although precise limits cannot be placed on the maximum size of the latter, it is generally accepted that a radiolucency not greater than 6 mm wide may be considered within normal limits. Where there are standing teeth, the lesion must also be differentiated from a radicular cyst.

Histopathology

The cysts may be lined by a variety of different types of epithelium. Stratified squamous epithelium, pseudostratified ciliated columnar (respiratory) epithelium often containing mucous cells, cuboidal epithelium, or columnar epithelium may be seen alone or in any combination (Fig. 6.31). The epithelium is supported by a connective tissue capsule which usually includes prominent neurovascular bundles from the terminal branches of the long sphenopalatine nerve and vessels. Collections of mucous glands and a scattered chronic inflammatory cell infiltrate are frequently present.

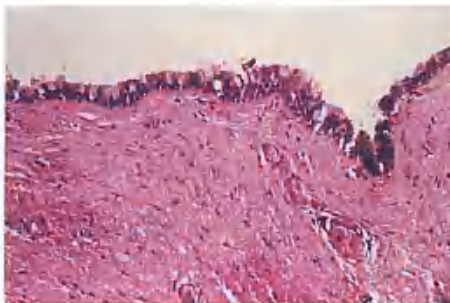


Fig. 6.31 Lining of nasopalatine duct cyst.

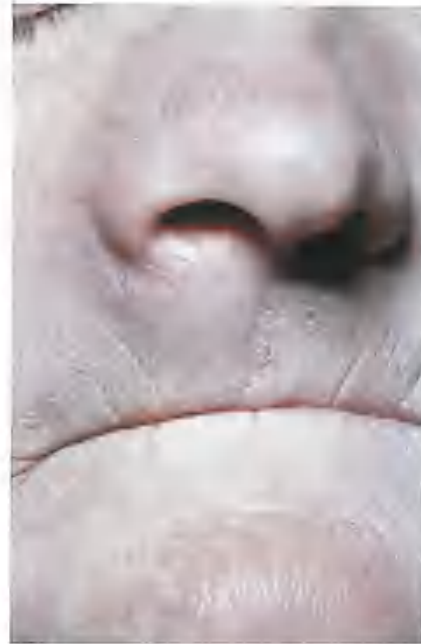

Fig. 6.32 Nasolabial cyst involving the right nostril and upper lip.

Nasolabial cyst

The nasolabial cyst is a rare lesion which arises in the soft tissue of the upper lip just below the ala of the nose. Although arising in soft tissue, it is traditionally grouped with the jaw cysts previously regarded as fissural lesions.

Clinically, it presents as a slowly enlarging soft-tissue swelling obliterating the nasolabial fold and distorting the nostril (Fig. 6.32). The cyst may arise bilaterally. The majority of cases present in the fourth decade and over 75 per cent occur in women.

The cysts are usually lined by pseudostratified columnar epithelium but stratified squamous epithelium, mucous cells, and ciliated cells may also be present.

The aetiology of the cyst is unknown but it has been suggested that it arises from remnants of the lower part of the embryonic nasolacrimal duct.

Median cysts

The status of the rare, median cysts that occur in the palate or mandible is uncertain. Some median cysts of the palate may represent displaced nasopalatine duct cysts. It is very likely that median cysts of the mandible are of odontogenic origin.

Non-epithelialized primary bone cysts

Non-epithelialized bone cysts occur most often in long bones but are occasionally seen in the jaws, almost exclusively in the mandible.

Solitary bone cyst

A variety of terms have been used to designate this lesion, including simple bone cyst, traumatic bone cyst, haemorrhagic bone cyst, and unicameral bone cyst.

Clinical and radiographic features

The solitary bone cyst occurs predominantly in children and adolescents with a peak incidence in the second decade. There is no definite sex predilection although some series have shown a slightly higher incidence in males. The cyst arises most frequently in the premolar and molar regions of the mandible. Maxillary lesions are rare. The majority of solitary bone cysts are asymptomatic and are chance radiographic findings; some degree of bony expansion occurs in about 25 per cent of cases.

Radiographically, the lesion presents as a radiolucency of variable size and irregular outline. Scalloping is a prominent feature particularly around and between the roots of standing teeth (Fig. 6.33). The margins of the lesion are usually well defined.

Pathological features and pathogenesis

Surgical exploration is undertaken to confirm the clinical diagnosis and characteristically reveals a rough bony-walled cavity devoid of any detectable soft-tissue lining. In many cases the cavity appears empty, but in others there is a little clear or blood-stained fluid. Rapid healing follows surgical exploration but even without surgical intervention the cyst will resolve spontaneously with time.

Microscopic examination of curettings from the lesion shows that the bony walls are covered by a delicate layer of loose, vascular fibrous tissue (Fig. 6.34) containing extravasated red blood

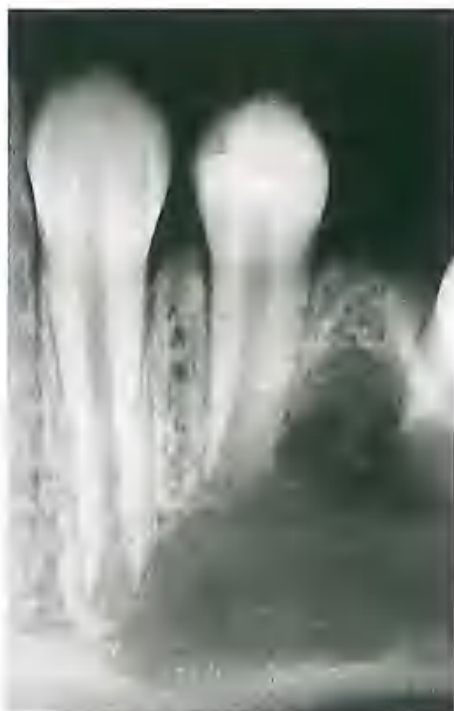

Fig. 6.33 Radiographic appearances of solitary bone cyst.

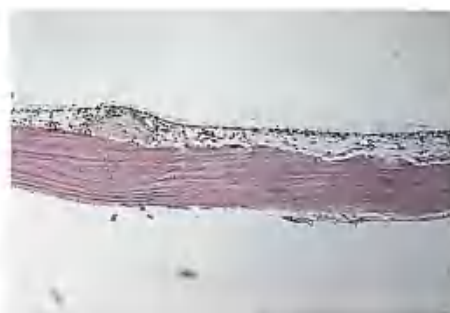

Fig. 6.34 Wall of solitary bone cyst. Loose fibrous tissue covers the bone.

cells and deposits of haemosiderin pigment. There is no epithelial lining.

The pathogenesis of the solitary bone cyst is unknown. It is commonly believed that there is a relationship to trauma, but the evidence is not convincing. Although a history of trauma can be elicited in about 50 per cent of cases, the interval between trauma and discovery of the lesion can range from months to years and the apparent relationship may be purely fortuitous. It has been suggested that the solitary bone cyst, aneurysmal bone cyst, and central giant cell granuloma of bone are related lesions reflecting some haemodynamic disturbance in medullary bone. In the case of the solitary bone cyst it has been argued that trauma produces intramedullary haemorrhage which, for unknown reasons, fails to organize and that cavitation occurs by subsequent haemolysis and resorption of the clot.

Aneurysmal bone cyst

The aneurysmal bone cyst is rare in the jaws. It arises either as a primary lesion, or as a secondary change in some other pre-existing disorder of bone. Most of the reported cases of primary aneurysmal bone cysts have arisen in the mandible, usually the posterior part of the body or angle, and have occurred in children or young adults. It presents as a firm expansile swelling causing facial deformity and may be associated with pain. Radiographs show a uni- or multilocular radiolucency which may have a ballooned-out appearance due to gross cortical expansion (Fig. 6.35). Secondary aneurysmal bone cysts in the jaws have



Fig. 6.35 Radiographic appearances of an aneurysmal bone cyst showing ballooned-out ascending ramus and multilocular radiolucencies.

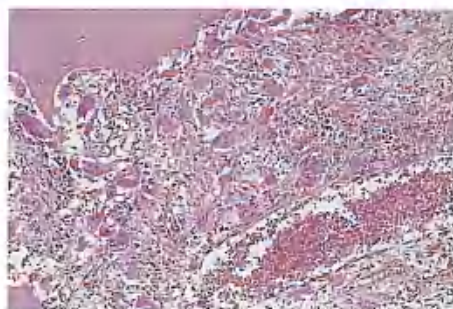


Fig. 6.36 Aneurysmal bone cyst with collections of giant cells.

been reported mainly in association with fibro-osseous lesions and central giant cell granuloma (see Chapter 16).

Microscopically, the lesion consists of numerous, non-endothelial-lined, blood-filled spaces of varying size separated by cellular fibrous tissue. Multinucleated giant cells and evidence of old and recent haemorrhage are common in the fibrous septa (Fig. 6.36).

The pathogenesis of aneurysmal bone cysts is unknown but it has been suggested that, like the solitary bone cyst, they may be associated with a haemodynamic disturbance in medullary bone.

Stafne's idiopathic bone cavity

This is an uncommon developmental anomaly of the mandible that is included here for convenience since it may be mistaken for a cyst on a radiograph. It is a symptomless chance finding which appears as a round or oval, well-demarcated radiolucency between the premolar region and angle of the jaw, and is usually located beneath the inferior dental canal (Fig. 6.37). Occasionally, the anomaly is bilateral.

The radiographic appearances are due to a saucer-shaped depression or concavity of varying depth on the lingual aspect of the mandible, which, in the great majority of cases, contains ectopic salivary tissue in continuity with the submandibular salivary gland. Sialography may be useful in identifying such salivary inclusions.

Cysts of the soft tissues

With the exception of the salivary mucoceles, cysts of the oral soft tissues are uncommon. Although strictly speaking gingival



Fig. 6.37 Radiographic appearances of Stafne's idiopathic bone cavity.

Key points – Other cysts of the jaws

developmental lateral periodontal cyst

- associated teeth are vital
- lined by non-keratinising squamous epithelium with focal thickenings

paradental cyst

- almost all associated with partly erupted mandibular third molar
- inflammatory origin; lining derived from reduced enamed epithelium

glandular odontogenic cyst

- rare developmental cyst with glandular structures in lining
- predominantly anterior mandible and locally aggressive

nasopalatine duct cyst

- commonest of the non-odontogenic cysts
- derived from nasopalatine duct residues; midline anterior palate

solitary bone cyst

- mainly molar region mandible; second decade
- empty cavity, no epithelial lining

aneurysmal bone cyst

- rare in jaws
- may occur alone or be associated with other disorders of bone

and nasolabial cysts are soft-tissue lesions they are traditionally grouped with cysts of the jaws. The main types of soft-tissue cysts, including those occurring in the neck, are listed in Table 6.3.

Salivary mucoceles

Cysts arising in connection with minor salivary glands are common. About 90 per cent of cases are of the mucous extravasation type.

Table 6.3 Cysts of the oral soft tissues

Salivary mucoceles
mucous extravasation cyst
mucous retention cyst
Dermoid and epidermoid cysts
Lymphoepithelial cyst
Thyroglossal cyst

Extravasation mucoceles

Over 70 per cent of all mucous extravasation cysts arise in the lower lip, followed by the cheek and floor of mouth. They are extremely uncommon in the upper lip. (In contrast, salivary tumours occur much more frequently in the upper lip than in the lower lip.) The cyst occurs over a wide age range but most patients are under 30 years of age and there is a peak incidence in the second decade.

Clinically, the lesion presents as a bluish or translucent sub-mucosal swelling (Fig. 6.38) and there may be a history of rupture, collapse, and refilling which may be repeated. It arises as a result of extravasation of mucus from a ruptured duct and a history of trauma can often be elicited from the patient.

Microscopically, the lesion typically consists of a mucin-filled cystic cavity or cavities lined by inflamed granulation tissue (Fig. 6.39). There is no epithelial lining. The extravasated mucus

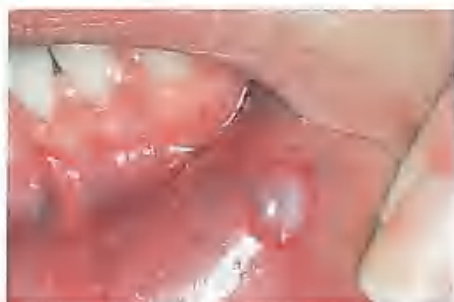

Fig. 6.38 Extravasation mucocele in superficial tissues.

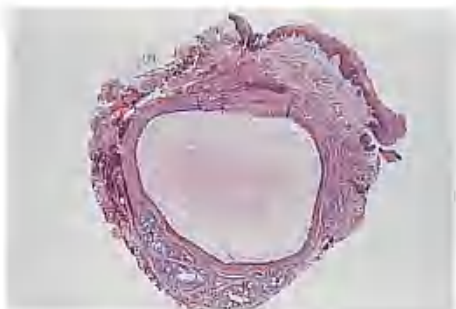

Fig. 6.39 Extravasation mucocele.




Fig. 6.40 Lining of an extravasation mucocele rich in macrophages (histiocytes).

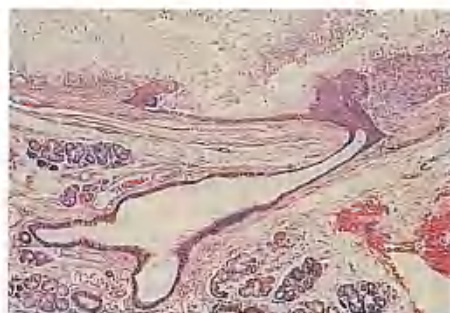

Fig. 6.41 Ruptured duct running into extravasation mucocele.

evokes a chronic inflammatory reaction and the wall of the cyst is infiltrated by large numbers of macrophages with vacuolated cytoplasm containing phagocytosed mucin (Fig. 6.40). Similar cells are seen within the cyst lumen. The torn duct may be seen running into the lesion (Fig. 6.41). In some cases the mucus is present as diffuse pools rather than being contained within a more or less discrete cyst-like space.

Retention mucoceles

In contrast to extravasation mucoceles, retention mucoceles occur most frequently in patients over 50 years of age and are almost never found in the lower lip.

They are derived from cystic dilatation of a duct and are lined by epithelium of ductal type (Figs 6.42, 6.43). Because the mucus is still contained within the duct there is no surrounding chronic inflammatory reaction. Their pathogenesis is unknown but progressive ballooning of a partially obstructed duct or even spontaneous cystic change have been suggested.

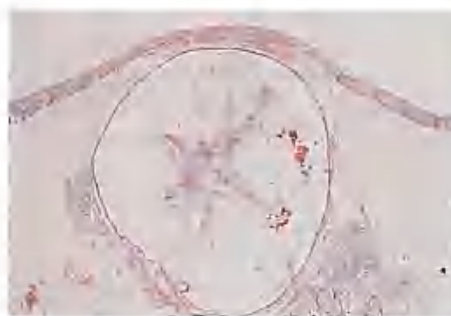

Fig. 6.42 Retention mucocele.




Fig. 6.43 Epithelial lining of a retention mucocele.

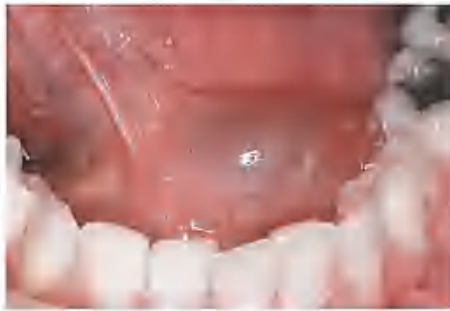

Fig. 6.44 Ranula.

Ranula

Ranula is a clinical term used to describe a swelling of the floor of the mouth which is said to resemble a frog's belly (Fig. 6.44). It is not a pathological diagnosis. Histologically, most ranulae are mucous extravasation cysts. Occasionally, a ranula may extend through the mylohyoid muscle and present in the submandibular area or neck, referred to clinically as a plunging ranula.

Dermoid and epidermoid cysts

Dermoid cysts are developmental lesions which occur at a variety of sites in the head and neck including, occasionally, the floor of the mouth. They may present as intraoral or submental swellings (Fig. 6.45). The cyst is presumed to arise from enclavement of epithelium in the midline as a result of deranged fusion of the mandibular and hyoid branchial arches.

Histologically, the cyst is lined by a regular layer of orthokeratinized stratified squamous epithelium resembling epidermis. The lumen contains keratinous debris. To be designated as dermoid, skin appendages, such as hair follicles, sebaceous and sweat glands, and erector pili muscles, must be identified in the

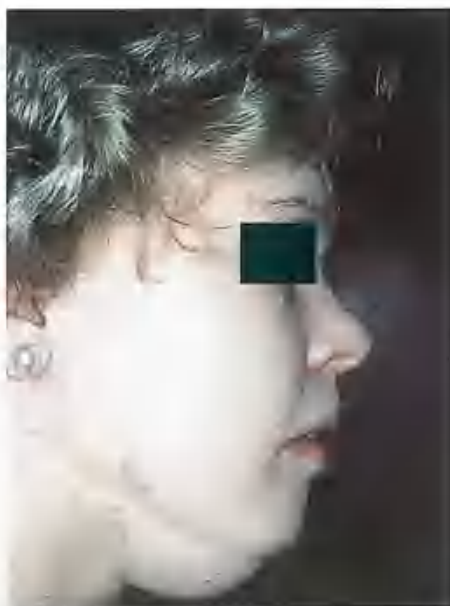

Fig. 6.45 Dermoid cyst presenting as submental swelling.

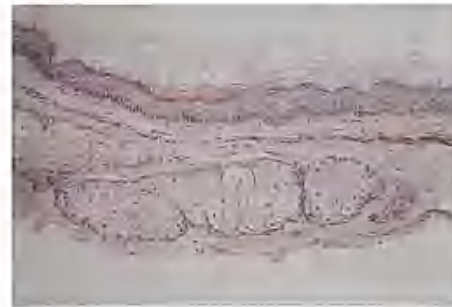

Fig. 6.46 Lining of dermoid cyst showing sebaceous glands.

wall of the cyst (Fig. 6.46). In the absence of skin appendages the cysts are designated as epidermoid. Epidermoid cysts occurring elsewhere in the oral soft tissues are acquired rather than developmental lesions. They arise as a result of traumatic implantation of epithelium into the deeper tissues, with subsequent cystic change and expansion.

Lymphoepithelial cyst

Lymphoepithelial cyst is the term now used to describe lesions previously classified as branchial cysts. The majority occur deep to sternomastoid or along its anterior border at the level of the angle of the mandible. It is an unusual lesion in the oral cavity, generally arising in the floor of the mouth. Histologically, the cyst is lined by stratified squamous epithelium and its wall contains well-organized lymphoid tissue (Fig. 6.47).

The cysts are of developmental origin but their pathogenesis is uncertain. Although they may be derived from remnants of the branchial arches or pharyngeal pouches it is likely that most arise from epithelium, probably of salivary origin, that becomes entrapped by lymphoid tissue. An origin from tonsillar tissue has also been suggested.

Thyroglossal cyst

The thyroglossal cyst is a developmental lesion derived from residues of the embryonic thyroglossal duct, the vestigial remains of which are represented by the foramen caecum on the tongue. Intraoral cysts, in the midline of the tongue or floor of the mouth, are very rare. Most thyroglossal cysts arise in the region of the hyoid bone.

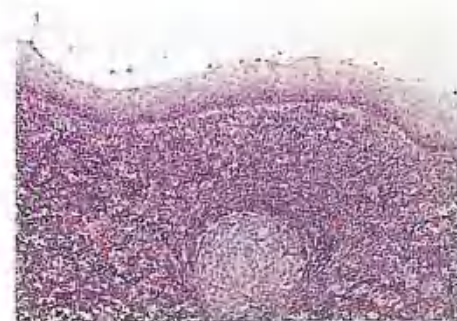


Fig. 6.47 Lining of lymphoepithelial cyst with lymphoid tissue and germinal centre in the wall.

It is convenient here to mention that functioning thyroid tissue may also occur in the tongue, although examples are rare. Before excision of ectopic lingual thyroid it is important to establish that the patient has functioning thyroid tissue present in the neck.

Further reading

- Ackerman, G., Cohen, M. A., and Altini, M. (1987). The paradental cyst: a clinicopathologic study of 50 cases. *Oral Surgery, Oral Medicine, Oral Pathology*, 64, 308–12.
- Barreto, D. C., Gomez, R. S., Bale, A. E., Boson, W. L., and De Marco, L. (2000). PTCH gene mutations in odontogenic keratocysts. *Journal of Dental Research*, 79, 1418–22.
- Benn, A. and Altini, M. (1996). Dentigerous cysts of inflammatory origin. A clinicopathological study. *Oral Surgery, Oral Medicine, Oral Pathology, Oral Radiology, and Endodontics*, 81, 203–9.
- Colgan, C. M., Henry, J., Napier, S. S., and Cowan, G. C. (2002). Paradental cysts: a role for food impaction in their pathogenesis? A review of cases from Northern Ireland. *British Journal of Oral and Maxillofacial Surgery*, 40, 163–8.
- Copete, M. A., Kawamata, A., and Langlais, R. P. (1998). Solitary bone cyst of the jaws: radiographic review of 44 cases. *Oral Surgery, Oral Medicine, Oral Pathology, Oral Radiology, and Endodontics*, 85, 221–5.
- Harvey, W., Foo, G.-C., Gordon, D., Meghji, S., Evans, A., and Harris, M. (1984). Evidence for fibroblasts as the major source of prostacyclin and prostaglandin synthesis in dental cyst in man. *Archives of Oral Biology*, 29, 223–9.
- King, R. C., Smith, B. R., and Burk, J. L. (1994). Dermoid cyst in the floor of the mouth. Review of literature and case reports. *Oral Surgery, Oral Medicine, Oral Pathology*, 78, 567–76.
- Koppang, H. S., Johannessen, S., Haugen, L. K., Haanaes, H. R., Solheim, T., and Donath, K. (1998). Glandular odontogenic cyst (sialo-odontogenic cyst): report of two cases and literature review of 45 previously reported cases. *Journal of Oral Pathology and Medicine*, 27, 455–62.
- Meghji, S., Henderson, B., Bando, Y. and Harris, M. (1992). Interleukin-1: the principal osteolytic cytokine produced by keratocysts. *Archives of Oral Biology*, 37, 935–43.
- Meghji, S., Qureshi, W., Henderson, B., and Harris, M. (1996). The role of endotoxin and cytokines in the pathogenesis of odontogenic cysts. *Archives of Oral Biology*, 41, 523–31.
- Ramachandran Nair, P. N. (1997). Apical periodontitis: a dynamic encounter between root canal infection and host response. *Periodontology 2000*, 13, 121–48.
- Ramachandran Nair, P. N., Pajarola, G., and Schroeder, H. E. (1996). Types and incidence of human periapical lesions obtained with extracted teeth. *Oral Surgery, Oral Medicine, Oral Pathology, Oral Radiology, and Endodontics*, 81, 93–102.
- Saito, Y., Hoshina, Y., Nagamine, T., Nakajima, T., Suzuki, M., and Hayashi, T. (1992). Simple bone cyst. A clinical and histopathologic study of fifteen cases. *Oral Surgery, Oral Medicine, Oral Pathology*, 74, 487–91.
- Shear, M. (1994). Developmental odontogenic cysts. An update. *Journal of Oral Pathology and Medicine*, 23, 1–11.
- Shear, M. (2002). The aggressive nature of the odontogenic keratocyst: is it a benign cystic neoplasm? Part 1. Clinical and early experimental evidence of aggressive behaviour. *Oral Oncology*, 38, 219–26.
- Shear, M. (2002). The aggressive nature of the odontogenic keratocyst: is it a benign cystic neoplasm? Part 2. Proliferation and genetic studies. *Oral Oncology*, 38, 323–31.
- Shear, M. (2002). The aggressive nature of the odontogenic keratocyst: is it a benign cystic neoplasm? Part 3. Immunocytochemistry of cytokeratin and other epithelial cell markers. *Oral Oncology*, 38, 407–15.
- Woolgar, J. A., Rippin, J. W., and Browne, R. M. (1987). A comparative study of the clinical and histological features of recurrent and non-recurrent odontogenic keratocysts. *Journal of Oral Pathology*, 16, 124–8.

Diseases of the periodontium

CHRONIC GINGIVITIS AND CHRONIC PERIODONTITIS

Epidemiology

Aetiology

Risk factors for periodontal disease

Pathogenesis of periodontal disease

Degradation of the extracellular matrix in
periodontal disease

Pathogenic mechanisms in chronic periodontal
disease

Clinical forms of periodontitis

GINGIVAL ENLARGEMENT

Chronic hyperplastic gingivitis and drug-associated
hyperplasias

Gingival fibromatosis

Other causes of gingival enlargement


DESQUAMATIVE GINGIVITIS

LATERAL PERIODONTAL ABSCESS

PERICORONITIS

AGE CHANGES IN THE PERIODONTIUM

FURTHER READING



Diseases of the periodontium

Chronic gingivitis and chronic periodontitis

Epidemiology

Chronic plaque-associated gingivitis and periodontitis are destructive inflammatory diseases sometimes referred to together simply as chronic periodontal disease, although there is evidence that, at least clinically, several distinct types of chronic destructive periodontal diseases may exist. The term gingivitis is used to designate inflammatory lesions that are confined to the marginal gingiva. Once the lesions extend to include destruction of the connective tissue attachment of the tooth and loss of alveolar bone the disease is designated periodontitis.

Chronic inflammatory periodontal disease of varying severity affects practically all dentate individuals. Gingivitis is common in children, even by the age of 3 years, and early periodontitis may be detected in teenagers; in general, the extent and severity of disease increase with age. This does not imply that all gingivitis progresses unrelentingly to periodontitis and indeed there appears to be a level of inflammation, loosely called 'contained gingivitis', which may remain stable for long periods of time. Nor does it imply that periodontitis is a relentlessly progressive disease. For example, in the United Kingdom, just over 50 per cent of adults have some shallow pocketing (less than 6 mm) whilst only about 5 per cent have deep pocketing (greater than 6 mm). However, the prevalence and depth of pocketing increases with age. Epidemiological data from other countries are similar and show

Key points – Epidemiology of periodontal disease

- early periodontitis involves some of the teeth in the majority of adults
- the prevalence of pocketing/loss of attachment increases with age
- the proportion of teeth affected by periodontitis increases with age
- advanced periodontal disease affects only a small percentage of the population

that whilst evidence of early periodontitis is very common in adults, advanced disease affects only about 10–15 per cent of the population. The data for loss of attachment show a similar pattern.

Tooth loss as a result of periodontal destruction is uncommon before the age of 50 years.

Most forms of periodontitis in adults are considered to be manifestations of the same disease, but other rarer types occur in younger patients. A classification of periodontal diseases associated with the accumulation of dental plaque is given in Table 7.1.

Aetiology

There is now overwhelming evidence that dental plaque is the essential aetiological agent in chronic periodontal disease. Detailed discussion of the evidence is outside the scope of this book, but the main points are summarized below.

1. Epidemiological studies in many parts of the world have demonstrated a strong positive association between dental plaque and the prevalence and severity of periodontal disease.
2. Clinical experiments in man and other animals have demonstrated that withdrawal of oral hygiene in healthy

Table 7.1 Classification of plaque-associated periodontal diseases (based on that of the International Workshop for a Classification of Periodontal Diseases and Conditions, 1999)

1. Gingivitis
 - (a) associated with dental plaque only
 - (b) modified by systemic factors
 - (c) modified by medication
 - (d) modified by malnutrition
2. Chronic periodontitis
 - (a) localised
 - (b) generalised
3. Aggressive periodontitis
 - (a) localised
 - (b) generalised
4. Periodontitis in systemic diseases
 - (a) immunocompromised patients
 - (b) genetic disorders

mouths results in the accumulation of dental plaque and that this is paralleled by the onset of gingivitis. Institution of plaque control rapidly restores the tissues to health.

3. A number of topically applied antimicrobial agents have been shown to inhibit plaque formation and prevent the onset of gingivitis.
4. Bacteria isolated from human dental plaque are capable of inducing periodontal disease when introduced into the mouths of gnotobiotic animals.
5. Several species of pathogenic bacteria have been isolated from periodontal pockets that have the capacity to invade tissues and evoke destructive inflammatory changes.

Although there is ample evidence that bacteria in dental plaque play a major role in the aetiology of periodontal disease, it is by no means clear whether their effect is non-specific and dependent primarily on the number of organisms or whether specific bacteria or groups of bacteria are responsible. However, there is increasing evidence that there are differences in the bacterial flora associated with healthy gingival crevices and various stages of disease. A brief summary of some of the differences between so-called pathogenic and non-pathogenic flora is given below.

1. Healthy periodontal tissues of humans are associated with a scanty flora located almost entirely supragingivally on the tooth surface. The microbial accumulations are 1–20 cells in thickness and comprise mainly Gram-positive bacteria. *Streptococcus* and *Actinomyces* species predominate.
2. In developing gingivitis the total mass of plaque is increased and the microbial cell layers often extend to 100–300 cells in thickness. *Actinomyces* species predominate but the proportion of spirochaetes and capnophilic organisms increases. As gingivitis becomes established there is a substantial increase in the proportion of obligate anaerobic Gram-negative bacteria, for example *Porphyromonas gingivalis* and *Prevotella intermedia*, most of which are located subgingivally.
3. Microbial examination of subgingival plaque in periodontitis has revealed a complex flora rich in Gram-negative rods, motile forms, and spirochaetes. *Actinobacillus actinomycetem-*

Table 7.2 Main differences in plaque microorganisms in health, gingivitis, and periodontitis

Main species	% Aerobic/ anaerobic (facultative anaerobes)	% Gram +ve/ Gram -ve	Motile/ non-motile
Healthy gingiva <i>Streptococcus</i> <i>Actinomyces</i>	75/25	90/10	Very few motile forms; motile: non-motile, 1:40
Chronic gingivitis <i>Actinomyces</i> <i>Streptococcus</i> <i>Porphyromonas</i> <i>Prevotella</i>	60/40	65/35	Number of motile rods and spirochaetes increases with disease
Chronic periodontitis <i>Actinobacillus</i> <i>Porphyromonas</i> <i>Bacteroides</i> <i>Prevotella</i> <i>Fusobacterium</i>	20/80	25/75	Abundant motile rods and spirochaetes; motile: non-motile, 1:1

comitans, *Porphyromonas gingivalis*, and *Bacteroides forsythus* are prevalent and consistently isolated. Other species include *Prevotella intermedia*, *Prevotella nigrescens*, and *Fusobacterium nucleatum*.

4. The development of gingivitis and periodontitis is associated with sequential colonization and a progressively more complex flora, characterized by an increase in anaerobic, Gram-negative, and motile forms rather than a mere increase in the amount of plaque present (see Table 7.2). *A. actinomycetemcomitans*, *P. gingivalis*, and *B. forsythus* are considered as important pathogens in periodontitis. As the disease progresses, changes in the environment within the pocket may also favour the overgrowth of other potentially pathogenic bacteria, resulting in a complex, polymicrobial infection.

Key points – Microbiology of periodontal disease

- Gram-positive cocci decrease as gingivitis progresses to periodontitis
- Gram-negative anaerobic bacilli increase as disease progresses
- motile forms increase as disease progresses
- periodontal disease involves interactions of mixtures of bacteria forming complexes in plaque
- certain species (periodontal pathogens) are prevalent in destructive lesions

Risk factors for periodontal disease

Although dental plaque is the essential aetiological agent in periodontal disease, various local and systemic factors (risk factors) can modify the host's response to plaque accumulation and influence the development and progression of gingivitis and/or periodontitis. However, epidemiological studies have shown that over 90 per cent of the variance observed in populations can be accounted for by age and oral hygiene variables alone.

Local factors include the pre-existing anatomy of the teeth, gingiva, and alveolar bone, alignment and occlusal relationships of teeth, and factors such as approximal restorations that may affect the accumulation and growth of plaque or interfere with its removal.

Systemic factors that may be associated with an increased incidence or severity of periodontal disease or with modifying the course of that disease include the following.

Diabetes mellitus

The relationship between diabetes and periodontal disease is unclear. Although it is commonly held that periodontal disease is more severe and progresses faster in both type I and II diabetics than in non-diabetics, the evidence is inconclusive. Several studies have failed to show significant differences between diabetic and non-diabetic patients. Vascular changes and defects in cellular defence mechanisms have been suggested as possible ways in which diabetes could increase susceptibility to periodontal disease.

Pregnancy and sex hormones

Several studies have shown that the severity of a pre-existing gingivitis increases in pregnancy from the second to the eighth month of gestation and then decreases. Healthy gingiva are not affected. Hormonal changes modify the tissue response to dental plaque and increased levels of sex hormones or their metabolites are found in inflamed gingiva. Experimental evidence suggests that the aggravation of gingivitis during pregnancy is related mainly to progesterone which affects the function and permeability of the gingival microvasculature.

Localized gingival hyperplasia also occurs during pregnancy (pregnancy epulis). Increased levels of gingivitis occurring around puberty and in some women taking oral contraceptives may also be related to the concentration of circulating sex hormones.

Pregnancy and sex hormones are not risk factors for periodontitis.

Nutrition

The relationship between nutrition and periodontal disease is controversial except in rare cases of gross deficiency states.

Advanced periodontal disease has been reported in rural Nigerians who eat a protein-deficient diet and in such children this is a factor predisposing to cancrum oris.

Severe and prolonged deficiency of vitamin C causes scurvy which may be associated with haemorrhagic gingivitis and oedematous enlargement of the gums, but these are not constant features.

Blood diseases

Acute leukaemia may be accompanied by a generalized enlargement of the gingiva due mainly to infiltration and packing of the tissues by leukaemic cells. Other oral signs of the disease can be related to the associated pancytopenia and include mucosal pallor, necrotizing ulceration (particularly of the oropharynx) petechial haemorrhages, gingival bleeding, and gingival ulceration. Candidosis and recrudescence of herpetic infections are also common. Alveolar bone loss and severe periodontal destruction have also been reported which, in some patients, are caused by leukaemic infiltration.

Severe gingival inflammation, ulceration, and advanced bone destruction may be seen in certain chronic types of neutropenia,

Table 7.3 Drugs that can affect periodontal tissues and the activity of periodontal disease

Anti-epileptics	Phenytoin	Gingival hyperplasia
Immunosuppressants	Azathioprine	Equivocal reduction in disease activity
	Corticosteroids	
	Cyclosporin	Gingival hyperplasia
Non-steroidal anti-inflammatory drugs	Indomethacin	Equivocal reduction in disease activity
	Ibuprofen	
Calcium channel blockers	Nifedipine	Gingival hyperplasia
	Verapamil	
Sex hormones	Oestrogen	Exacerbation of pre-existing gingivitis
	Progesterone	

such as cyclic neutropenia, and functional disorders of neutrophils have also been implicated in juvenile periodontitis.

Drugs

With the exception of phenytoin, cyclosporin, and nifedipine, which are associated with generalized gingival hyperplasia and are discussed later in this chapter, the evidence that systemic drug therapy can modify the course of periodontal disease is inconclusive. The main drugs which have been reported to affect the periodontium are listed in Table 7.3.

Drugs which affect inflammatory and immune responses, such as immunosuppressants and non-steroidal anti-inflammatory agents, might be expected to influence the course of periodontal disease by modifying the response of the host to products from microbial plaque. However, the evidence is inconclusive, and sometimes contradictory.

Acquired immunodeficiency syndrome (AIDS)

Recent epidemiological studies suggest that the periodontal status of many HIV-positive patients is similar to that of the general population. However, severe and atypical forms of periodontal disease may be seen in some patients, particularly those with AIDS (see Chapter 11).

Smoking

There is a considerable body of evidence that tobacco smoking is an important risk factor for the development and progression of periodontal disease. The mechanism is not fully understood but smoking impairs the phagocytic function of polymorphonuclear neutrophils and impairs healing. The composition of subgingival plaque may also be affected and favour the overgrowth of potential periodontal pathogens.

Pathogenesis of periodontal disease

In health a balance exists between the challenge to the tissues from microorganisms in dental plaque and the host defence mechanisms (Fig. 7.1). Disturbances in this host-parasite relationship lead to the development of periodontal disease, but the transition from health to gingivitis is not precisely identifiable. The host




Fig. 7.1 Factors involved in maintaining the host-parasite equilibrium at the plaque-gingival interface.

Key point – Chronic periodontal disease

- a dynamic process reflecting changes in the balance of the host–parasite relationship with time

may be able to adapt to the imbalance in the relationship so that a new equilibrium is established and the disease may become arrested and remain stable over long periods of time. Healing may also occur. Transient imbalances in the host–parasite relationship are likely to occur frequently and yet the natural history of periodontal disease in humans usually spans decades, suggesting that equilibrium is rapidly restored and that for most of the time destruction is not continuous but is episodic in nature.

Chronic gingivitis

In healthy, non-inflamed gingiva there is continuous migration of polymorphonuclear neutrophil leucocytes (PMN) through the junctional epithelium into the gingival sulcus. This migration of PMN is part of the normal host defences to the low level of bacterial challenge to the gingiva which is likely to occur even in healthy mouths. In the absence of adequate oral hygiene the level

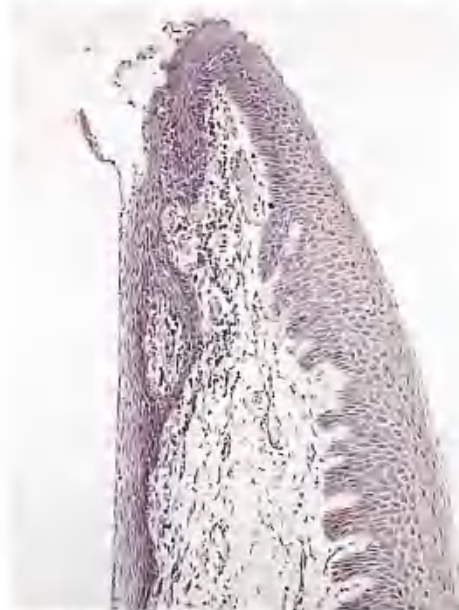


Fig. 7.2 Gingivitis developing around the base of the histological sulcus.

of challenge increases as dental plaque accumulates and gingivitis is initiated.

The initial lesion of gingivitis involves a microscopic area of tissue around the base of the gingival sulcus (Fig. 7.2) and cannot be detected clinically. It is essentially an acute inflammatory response characterized by dilatation of small blood vessels, enhanced PMN migration, and increased vascular permeability

Key points – Initial gingivitis

- microscopic area around base of gingival sulcus
- acute inflammatory changes
 - cellular exudate: enhanced migration of PMN
 - fluid exudate: increased crevicular fluid flow

Box 7.1 Pathogenesis of gingivitis

- Bacterial products activate junctional epithelium and endothelial cells to release cytokines, e.g. interleukin-1 (IL-1) and IL-8, that enhance recruitment and migration of PMN.
- PMN recruitment and migration are enhanced by activation of serum proteins released as a result of increased vascular permeability.
- Enhanced expression of adhesion molecules by endothelial cells mediated by cytokine activity recruits macrophages and lymphocytes into the area.
- Activation of macrophages and lymphocytes leads to production of complex arrays of pro- and anti-inflammatory cytokines.
- Cytokine activity induces B cells to differentiate into antibody-producing plasma cells.
- Pro-inflammatory cytokines, e.g. IL-1 and IL-6, enhance production and activation of metalloproteinases (see Box 7.2) leading to tissue destruction.
- Progression, stabilization, or regression of gingivitis reflects the changing balances between plaque products, their interaction with host cells, and the production of pro- and anti-inflammatory cytokines.

which manifests as an increase in the flow of crevicular fluid. The fluid contains all classes of plasma proteins, notably immunoglobulins and complement, which, in addition to the activity of the PMNs, may play a role in controlling the initial bacterial challenge. These changes are mediated by enhanced production and activity of a variety of chemical mediators (see Box 7.1), and persist throughout the subsequent stages of gingivitis and periodontitis.

If this initial reaction does not contain the microbial challenge, continuing ingress of bacterial antigens and other plaque products into the tissues potentiates the inflammation. The increasing level of bacterial challenge impairs the function of the junctional epithelium to maintain its attachment to enamel, and as the attachment is lost there is progressive deepening of the gingival sulcus resulting in the formation of a gingival pocket. This permits the development of subgingival plaque and the altered environment favours the growth of Gram-negative anaerobes. Impairment of the barrier function of the junctional epithelium allows ready ingress of antigens from the subgingival plaque, leading to the development of an immune response. The early lesion of gingivitis is characterized by a lymphocytic infiltrate which develops around the site of the initial lesion, but as it evolves it expands laterally and apically beneath the junctional epithelium, extending towards the amelocemental junction (Fig. 7.3).

The infiltrate consists of a mixture of T and B lymphocytes and macrophages, although at this stage T cells predominate. It leads to the development of a complex network of cytokines within the tissues (see Box 7.1) which can have both protective and destructive properties. In particular, a variety of mediators may be

Key points – Early gingivitis

- lymphocytic infiltration
- impairment of barrier function of junctional epithelium
- gingival pocket formation; growth of subgingival plaque

released that trigger connective tissue breakdown, leading to destruction of gingival collagen fibres as the infiltrate expands.

Early gingivitis may remain stable, especially in children, but, if the bacterial challenge persists, will progress with time to established gingivitis. The area of inflamed gingival tissue continues to expand apically and laterally, accompanied by continuing destruction of gingival collagen (Fig. 7.4). There is also a characteristic shift in the inflammatory cell population from predominantly lymphocytic, as seen in early gingivitis, to one in which plasma cells predominate. B lymphocytes are stimulated to differentiate into specific antibody-producing plasma cells against plaque bacterial antigens by cytokines from T-helper cells within

Key points – Established gingivitis

- expansion of area of inflammation and destruction of gingival connective tissue
- predominance of plasma cells in inflammatory infiltrate
- deepening of gingival pocket; thinning/ulceration of pocket epithelium

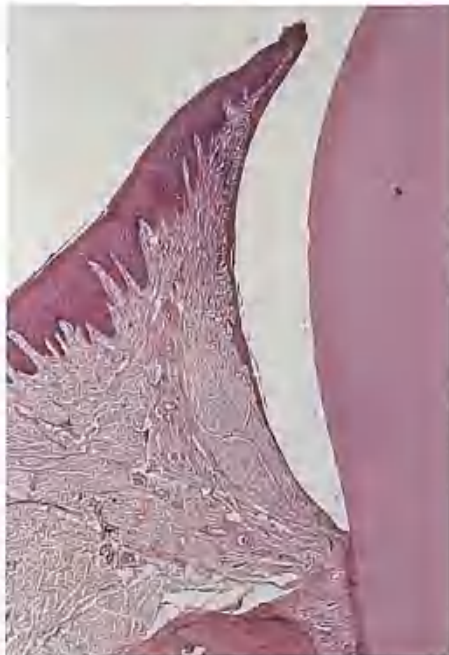


Fig. 7.3 The early lesion of gingivitis.



Fig. 7.4 Established gingivitis.

the infiltrate. Huge amounts of immunoglobulin are present throughout the connective and epithelial tissues. The exacerbation of the inflammation results in further impairment of the barrier function of the junctional epithelium and deepening of the gingival pocket. The appearance of the pocket epithelium is variable. It may be hyperplastic, with long anastomosing rete processes extending into the gingival connective tissue; it may be thinned with only one or two layers of cells separating the underlying engorged vascular bed from the external environment; or it may show frank ulceration (Fig. 7.4). The engorged vascular bed and thinning or ulceration of the pocket epithelium are related to the clinical signs of redness and bleeding.

In areas away from the zone of destruction there may be varying attempts at repair characterized by the formation of fibrous tissue. However, the newly-formed collagen bundles do not simulate the architecture of the previously existing gingival fibres. In some instances, exuberant fibrous tissue formation results in gingival hyperplasia and false pocketing. The destruction of the specifically orientated gingival fibres, fibrosis, and hyperplasia contribute to the loss of normal gingival form seen clinically in chronic gingivitis. Oedematous enlargement, resulting from increased vascular permeability associated with inflammation, is another factor.

Chronic periodontitis

Chronic periodontitis is characterized by destruction of the connective tissue attachment of the root of the tooth, loss of alveolar bone, and pocket formation. Although periodontitis is the result of extension of inflammation from the gingiva into the deeper tissues, the natural history of the untreated lesion of established gingivitis is not well understood. Gingivitis in some patients may

remain stable for years, in others it either progresses slowly to periodontitis or, in a minority of patients, there may be rapid progression and advanced bone-loss occurring at an early age. Factors governing the rate of progression remain largely unknown.

The earliest histological evidence of the progression of gingivitis to periodontitis is the extension of inflammation beneath the base of the junctional epithelium into the supra-alveolar connective tissue. The inflammatory infiltrate is rich in plasma cells but there are also numerous T lymphocytes and macrophages. As the area and density of the infiltrate increase there is destruction of collagen in the supra-alveolar connective tissue and the fibres lose their attachment to cementum (Fig. 7.5). This is accompanied by apical migration of the junctional epithelium to cover the denuded root surface, resulting in early true pocket formation (Fig. 7.6). As the disease extends into the supporting tissues there is progressive destruction of the fibres of the periodontal ligament accompanied by osteoclastic resorption of the alveolar bone. The junctional epithelium continues to migrate apically, resulting in progressive deepening of the pockets. As the junctional epithelium migrates apically the more coronal and inflamed tissue loses its specialized attachment and is converted into pocket epithelium. The width of the zone of attachment of the junctional epithelium at the base of the pocket remains fairly constant throughout the course of the disease.

The pathway of spread of inflammation into the supporting tissues influences the pattern of bone destruction and morphology of the pockets. In general, the spread of inflammation follows the

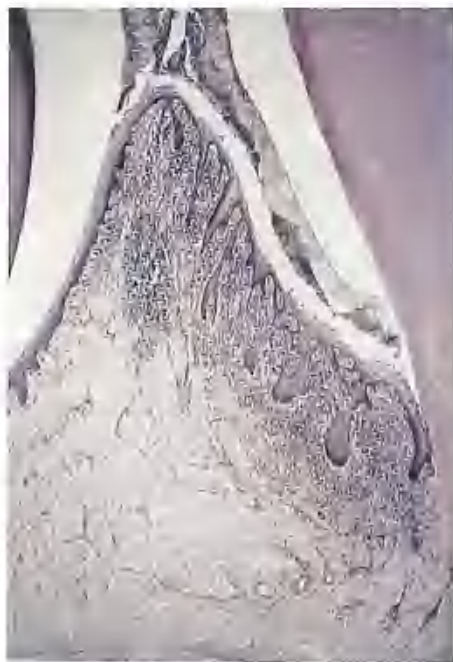


Fig. 7.5 Early periodontitis showing extension of inflammation into supra-alveolar tissues and early loss of attachment.

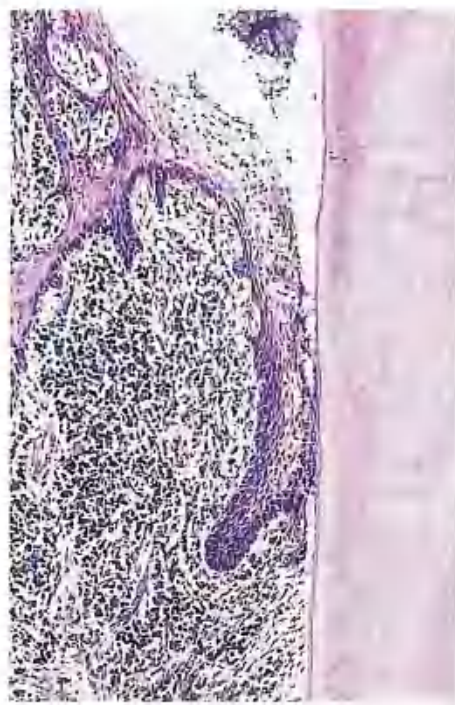


Fig. 7.6 High-power view of Fig. 7.5 showing apical migration of the junctional epithelium over the denuded root surface at the base of the developing pocket.

course of blood vessels. In the interdental areas the infiltrate extends mainly along the rich anastomotic supply running from beneath the interdental col towards the midpoint of the crest of the interdental septa and into underlying marrow spaces (Fig. 7.7). Osteoclastic resorption results in interdental cratering. In marginal areas, inflammation follows the course of supra-periosteal vessels towards the crest of the marginal alveolar bone. These pathways of spread, which follow the main vascular supplies, tend to result in a horizontal pattern of bone loss and suprabony pockets. However, various factors can modify these pathways and may divert the spread of inflammation towards and directly into the periodontal ligament, resulting in vertical patterns of bone loss and infrabony pockets (Figs 7.8, 7.9). These factors include the previously existing bone morphology, the morphology and alignment of teeth, occlusal trauma, and plaque retentive factors such as overhanging restorations. Thus, in any one patient the pattern of bone loss can be affected by many factors. Both horizontal and vertical defects may occur in different areas of the same mouth and in different areas around a single tooth.

Although chronic periodontal disease is characterized by destruction of the connective tissue attachment of the teeth, the rate of progression of the lesions is not constant and phases of tissue destruction and bone resorption may alternate with periods of remission. Current hypotheses suggest that loss of attachment occurs as brief bursts of destructive activity at random time intervals throughout an individual's life. During periods of remission there may be attempts at healing.



Fig. 7.7 Spread of inflammation towards the midpoint of the interdental septum.

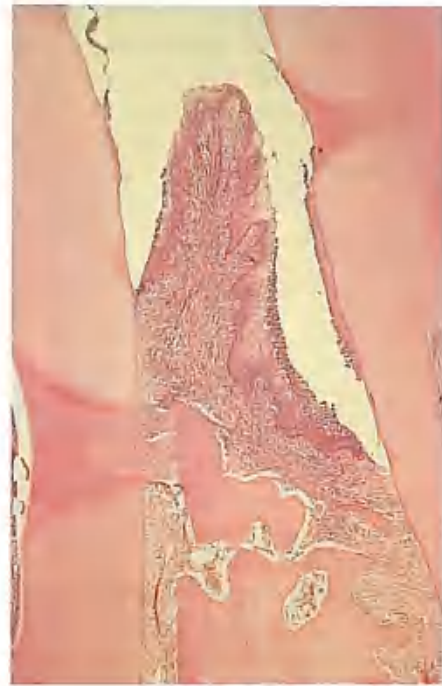


Fig. 7.8 Chronic periodontitis with infrabony pocket.

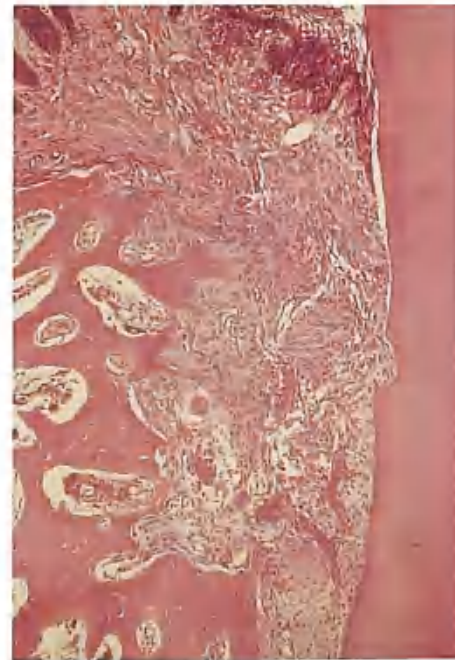


Fig. 7.9 Spread of inflammation into periodontal ligament associated with resorption of bone at the base of an infrabony pocket.

Histological examination of an established periodontal pocket (Fig. 7.10) shows the following features. The pocket is bounded on one side by denuded root surface and on the other by pocket

Key points – Chronic periodontitis

- apical extension of destructive inflammation
 - into supra-alveolar connective tissues
 - into alveolar bone
 - into periodontal ligament
- loss of connective tissue attachment and destruction of alveolar bone
- apical migration of junctional epithelium and pocket formation
- periods of quiescence/stability; random bursts of destructive activity

epithelium. At the base of the pocket a narrow zone of junctional epithelium mediates the soft-tissue attachment to the root. The pocket contains subgingival calculus and plaque and inflammatory exudate comprising fluid and cells, mainly PMN. The pocket epithelium varies in quality and thickness. Areas of irregular hyperplasia and rete ridge formation alternate with areas of thinning and even frank ulceration. The vessels in the subjacent connective tissue are markedly dilated and there is emigration of large numbers of PMN which transmigrate the pocket epithelium. The underlying connective tissue is densely infiltrated by inflammatory cells; plasma cells predominate. The inflammatory infiltrate may extend into adjacent marrow spaces. In actively progressing disease, osteoclasts may be seen along the bone front and within marrow spaces, but they are infrequent in relatively stable lesions.

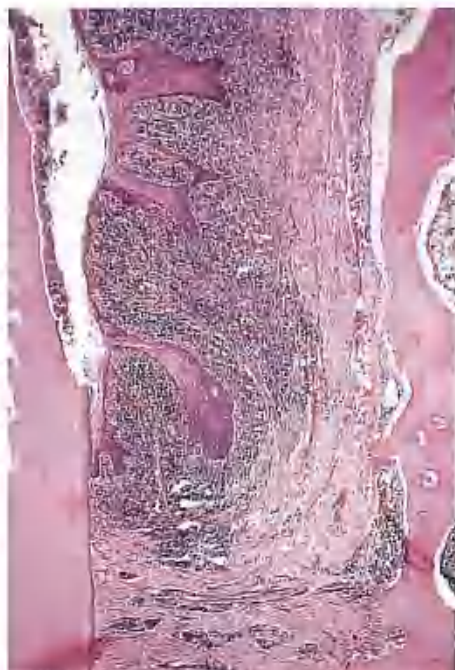


Fig. 7.10 Deep, established infrabony pocket.

Degradation of the extracellular matrix in periodontal disease

The mechanisms involved in the degradation of the extracellular matrix of the gingiva and periodontal ligament, especially collagen, and in the destruction of the alveolar bone are of major importance in periodontal disease since they can result, ultimately, in tooth loss.

The destruction of the extracellular matrix involves the activity of a family of proteolytic enzymes, the matrix metalloproteinases (MMPs), of which the collagenases are the best known. These enzymes are produced mainly by connective tissue cells, principally fibroblasts, but are also synthesized by other cell types, for example macrophages and neutrophils. They are secreted in a latent form and require activation before they can degrade matrix proteins.

In health, the normal remodelling of connective tissues is tightly controlled, resulting in a balance between the rates of synthesis and degradation which reflects the balance between the activity of the MMPs and their inhibitors. The main group of inhibitors present in the tissues are known as the tissue inhibitors of metalloproteinases (TIMPs) and they are also produced mainly by fibroblasts and macrophages, probably at the same time as the cells are releasing their MMPs. In periodontal disease, the destruction of connective tissue reflects an imbalance between the levels of MMPs and TIMPs in the tissues, resulting in a relative increase in the level of MMPs. This could be due to either an increase in MMP synthesis or a reduction in the synthesis of TIMPs. The production of both MMPs and TIMPs is influenced by a variety of factors, particularly cytokines. Thus, fluctuations in cytokine activity in response to plaque antigens is reflected in changes in the balance between production of MMPs and TIMPs. In particular, the activity of interleukin-1, which induces MMP production by host cells, probably plays a key role.

Bone resorption in periodontal disease

Mechanisms involved in bone loss in periodontitis are still unclear, but involve factors which stimulate the proliferation, differentiation, and activation of osteoclasts. In normal remodelling of bone, osteoblastic and osteoclastic activity are tightly coupled, after a wave of osteoclastic resorption osteoblastic deposition

Key points – Degradation of the extracellular matrix (ECM)

- MMPs degrade the ECM, TIMPs inhibit MMPs
- activity of MMPs and TIMPs is in balance in health
- imbalance in disease leads to increased MMP activity
- imbalance reflects fluctuations in cytokine activity in inflammation
- the activity of interleukin-1 probably plays a key role

occurs. The control of this process involves the activities of a number of cytokines which stimulate or inhibit either osteoclastic or osteoblastic activity. In pathological processes associated with bone destruction this coupling is disturbed and the balance is shifted, resulting in loss of bone.

Several local mediators capable of stimulating osteoclastic activity have now been identified. They fall into three main categories: cytokines, prostaglandins, and growth factors influencing osteoblastic and osteoclastic interactions (Table 7.4). Interleukin-1, interleukin-6, and tumour necrosis factor (TNF) are the main cytokines which stimulate bone resorption and they probably mediate their activity through prostaglandin synthesis, especially PGE₂, which enhances osteoclastic activity. Interleukin-1 is probably the most potent stimulator of bone resorption known and many pathways exist for its generation, and that of other cytokines, in periodontal inflammation.

During bone resorption osteoclasts adhere tightly to the bone matrix and secrete hydrochloric acid, creating an acidic micro-environment beneath them which demineralises the matrix. MMPs and other proteases produced by the osteoclast then degrade the organic matrix. The process is comparable to that described for cyst expansion (see Box 6.1).

Pathogenic mechanisms in chronic periodontal disease

Substances from plaque initiate an inflammatory and immune response which is designed to resist the challenge to the integrity of the tissues posed by infection by periodontopathic bacteria. In meeting this challenge a complex array of inflammatory and immune mediators are generated which, whilst being essential for defence, are capable of activating host mechanisms of connective tissue breakdown. Most of the tissue destruction in periodontal disease is thought to be due to inappropriate activation of tissue degradation systems triggered by the host response to microbial plaque. The outcome of the challenge from the plaque depends, therefore, on the balance between the protective and destructive aspects of the host response. This will vary from individual to individual and from site to site, as well as with time and with plaque composition.

Fluctuations in the host-parasite relationship upset the balance between the protective and destructive aspects of the host response, and in most patients periodontal destruction occurs as random bursts of activity separated by periods of stability. Thus,

Table 7.4 Local mediators affecting bone resorption

Cytokines:	interleukin-1 interleukin-6 tumour necrosis factors
Prostaglandins:	especially PGE ₂
Growth factors:	e.g. factors from osteoblasts which regulate osteoclast recruitment

following infection by periodontopathic bacteria there may be a period of active destruction before the host response is sufficiently protective to restore equilibrium to the host-parasite relationship. This new equilibrium will remain stable until at some unpredictable time in the future either the sudden overgrowth of a pathogen or some change in immunoregulation of the host response triggers another burst of tissue destruction. This will continue until balance is restored and a new equilibrium is established, and so on, at random intervals throughout life.

Some of the inflammatory and immune mediators have been discussed previously and interleukin-1 has been highlighted because of its potential to stimulate degradation of the extracellular matrix and bone resorption. Many of these mediators can be detected in crevicular fluid, along with products of tissue degradation and catabolic enzymes released by inflammatory and host tissue cells. Differences exist between disease active and inactive sites and it is likely that as understanding of the mechanisms of periodontal breakdown increases, diagnostic markers will be defined in crevicular fluid which identify patients and sites at risk of progressive disease.

Clinical forms of periodontitis

Three main categories of periodontitis have been described which can be distinguished by their clinical and, to some extent, pathological features (see Table 7.1). The main features of each type are described below, but for more detailed discussion the reader should consult texts in periodontology.

Chronic periodontitis

This is by the most common form of chronic periodontal disease and is characterized by its chronicity. The onset of disease is in early adult life (or even before), but in the majority of patients does not progress to tooth loss until after 50 years of age. It is also referred to as adult-type periodontitis. A generally regular pattern of predominantly horizontal bone loss is seen with suprabony pocketing. The entire dentition is usually involved, with the lower incisors and molars tending to show the most advanced bone loss.

Key points – Pathogenesis of periodontal disease

- disturbance in host-parasite relationship, leading to:
- activation of host inflammatory and immune response, leading to:
- enhanced synthesis of inflammatory mediators/cytokines, leading to:
- burst of breakdown of connective tissue/bone resorption leading to:
- new equilibrium in host-parasite relationship as host response contains the challenge from plaque bacteria

Aggressive periodontitis

The localized form of aggressive periodontitis is typified by the condition commonly referred to as juvenile periodontitis, although not all patients with this type of periodontal disease are juveniles.

Juvenile periodontitis is a rare form of periodontitis which usually commences around puberty. There is a higher incidence in females. The disease is characterized by rapid destruction of alveolar bone with vertical bone loss resulting in deep infrabony pockets. Initially, the permanent first molars and/or maxillary incisor teeth are affected, usually symmetrically, but the number of teeth involved increases with age. The pattern of involvement tends to follow the sequence of eruption.

The aetiology and pathogenesis of the condition remain obscure. The lesions are inflammatory and bacterial plaque is the prime aetiological factor, but the degree of destruction is not commensurate with the generally small amounts of plaque present. However, the subgingival flora in juvenile periodontitis differs significantly from that in adult periodontitis and is dominated by Gram-negative anaerobic rods, particularly *Actinobacillus actinomycetemcomitans*. Host factors have also been implicated, for example a familial pattern has been found in several cases, suggesting that genetic factors are involved. Abnormalities in cell-mediated immunity and in PMN function have also been demonstrated.

The generalized form of aggressive periodontitis includes patients previously classified as having rapidly progressive periodontitis. This form usually has an onset in early adult life but lacks well-defined criteria.

The periodontal lesions are severe and generalized with evidence of rapid bone destruction. Almost the entire dentition is usually affected and the disease may either progress without remission to tooth loss or subside and become quiescent. Again, the aetiology and pathogenesis are ill understood.

Periodontitis in systemic disease

This category comprises mainly the rare forms of periodontitis, previously classified as prepubertal periodontitis, which present in childhood and involve the deciduous and subsequently the permanent dentition. They are characterized by extensive destruction of alveolar bone and are associated with a variety of uncommon systemic diseases (Table 7.5). Several involve abnormalities in number and/or function of PMN. The Papillon-Lefèvre syndrome is characterized by skin lesions of palmar-plantar hyperkeratosis and severe periodontal destruction involving both the deciduous and permanent dentitions. It is transmitted as an autosomal recessive and is due to mutations in the gene encoding for the lysosomal enzyme cathepsin C.

Gingival enlargement

Chronic hyperplastic gingivitis and drug-associated hyperplasias

Chronic hyperplastic gingivitis represents a variation in host tissue response to the accumulation of dental plaque. In most

Table 7.5 Diseases associated with severe periodontitis in children

Diseases associated with major abnormalities of neutrophils:
– agranulocytosis
– cyclic neutropenia
– Chediak-Higashi syndrome
– Job syndrome
Diseases in which there may be associated neutrophil dysfunction:
– Papillon-Lefèvre syndrome
– Down syndrome
– juvenile-onset diabetes mellitus
Other systemic diseases:
– hypophosphatasia
– Langerhans cell histiocytosis (histiocytosis-X group)
– Ehlers-Daalos syndrome (Type VIII)

cases the factors predisposing to the hyperplastic reaction are unknown, but it is well established that some degree of gingival enlargement can occur in epileptics and other patients taking the anticonvulsant drug phenytoin (Fig. 7.11). The percentage of patients affected varies from less than 10 per cent to over 60 per cent in different series. Dental plaque is an essential aetiological factor; the drug modifies a previously existing chronic gingivitis and good oral hygiene can prevent the gingival hyperplasia. The mechanisms by which the drug or its metabolites induce the hyperplasia are unknown, but certain gingival fibroblasts can metabolize phenytoin and this may be accompanied by an increased production of collagen. The distribution and activity of such a subpopulation of fibroblasts could be a factor determining the different susceptibilities of patients to gingival hyperplasia.

Clinically, the hyperplasia may be more or less generalized but primarily involves the interdental tissues, particularly around the labial surfaces of anterior teeth. The enlargement manifests as firm, pink, often lobulated fibrous masses that may obscure the crowns of the teeth. In patients where the marginal gingiva is relatively uninvolved, deep clefts separate adjacent bulbous interdental papillae. Histologically, the overgrowth consists mainly of bundles of collagen fibres but fibroblasts are common and there is a scattered chronic

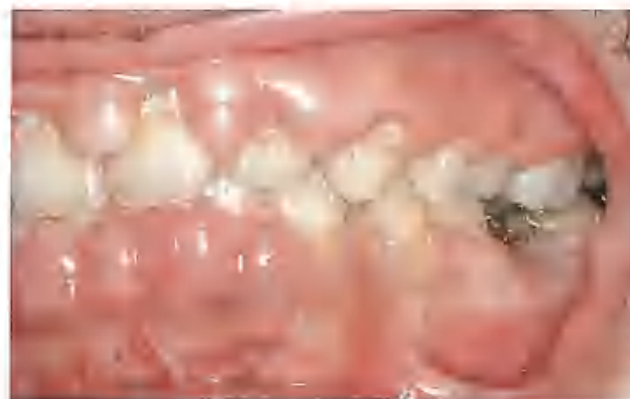

Fig. 7.11 Phenytoin-associated hyperplastic gingivitis.

inflammatory cell infiltration. The surface epithelium is also often markedly hyperplastic and shows long slender rete processes extending into the underlying connective tissue.

A similar hyperplastic gingivitis may also occur in patients taking the immunosuppressive drug cyclosporin, following transplant procedures, and in those taking calcium channel blocking agents or calcium antagonists, such as nifedipine (Fig. 7.12) and verapamil, for cardiovascular disorders. The mechanisms are unclear but genetic predisposition, related to fibroblast susceptibility, and variations in the pharmacokinetics of drug metabolism are possible factors in addition to pre-existing gingivitis.

Gingival fibromatosis

Gingival fibromatosis is a rare hereditary condition most frequently transmitted as an autosomal dominant trait, although autosomal recessive inheritance has been reported. The autosomal dominant type can be caused by mutations in at least two distinct genetic loci. The condition presents as a generalized, or occasionally localized, fibrous enlargement of the gingiva which usually begins with the eruption of the permanent, or occasionally the deciduous, teeth (Fig. 7.13). It is rarely present at birth. Occasionally, the condition is associated with hypertrichosis, epilepsy, and mental retardation. Microscopically, the fibrous tissue consists mainly of coarse bundles of collagen fibres, but mucoid change, due to the accumulation of ground substance, is common. The covering epithelium is often hyperplastic. Recurrence is likely following surgical excision.

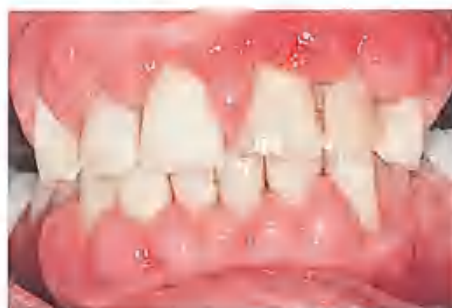

Fig. 7.12 Nifedipine-associated hyperplastic gingivitis.

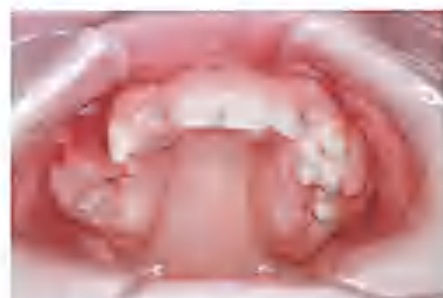

Fig. 7.13 Gingival enlargement in gingival fibromatosis. The mandibular gingivae were similarly affected.

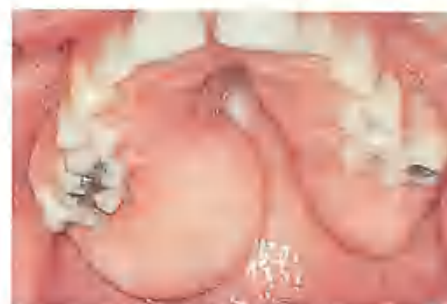

Fig. 7.14 Fibrous enlargement of the maxillary tuberosities.

Key points – Desquamative gingivitis

- the common clinical manifestation of a variety of different diseases
- involves full width of attached gingiva

Symmetrical fibrous enlargements may also occur in the maxillary tuberosity region (Fig. 7.14) and it is possible that some cases are related to gingival fibromatosis.

Other causes of gingival enlargement

In addition to fibrous overgrowth, generalized enlargement of the gingiva may be caused by oedema, by leukaemic infiltration in acute leukaemia, and may be a feature of other systemic diseases (Table 7.6). Localized enlargements (epulides) are discussed in Chapter 8.

Desquamative gingivitis

Desquamative gingivitis is not a disease entity but a clinical term applied to the gingival manifestation of several different diseases.

Clinically, the gingiva are red, oedematous, and glazed, and show areas of superficial ulceration or desquamation of varying extent. Vesicles, bullae, white flecks, or striae may also be seen depending on the underlying aetiology. The involvement is patchy but the buccal

Table 7.6 Causes of generalized enlargement of the gingiva

Fibrous overgrowths:	Gingival fibromatosis Chronic hyperplastic gingivitis Drug-associated hyperplasias – epanutin – cyclosporin – nifedipine and verapamil
Oedematous enlargement:	Oedematous gingivitis – puberty – pregnancy – oral contraceptives – scurvy
Systemic disease:	Acute leukaemias Wegener's granulomatosis

and labial gingiva are more commonly affected than lingual or palatal tissues. The condition is more common in females than males and most cases occur after 30 years of age.

Correct identification of the underlying aetiology is important and the dermatoses, particularly mucous membrane pemphigoid and lichen planus (Fig. 7.15), account for most cases (see Chapters 12 and 9 respectively). Other cases may represent local hypersensitivity reactions to various substances, for example toothpastes, cosmetics (Fig. 7.16), chewing-gum, and cinnamon, used as a flavouring in some of the previous examples, and may occur alone or as part of an orofacial granulomatosis (see Chapter 13). The gingival reaction associated with chewing-gum hypersensitivity has also been referred to as 'plasma-cell gingivitis' because of the widespread distribution of large numbers of plasma cells throughout the gingiva. Several other uncommon aetiological factors have also been suggested, which include hormonal disturbances in menopausal females, unusual manifestations of chronic infections, and abnormal responses to dental plaque. Dental plaque will exacerbate the inflammation from whatever cause and maintenance of adequate oral hygiene is important in management, but may be difficult because of soreness and bleeding associated with erosions.

Lateral periodontal abscess

The lateral periodontal abscess is a localized area of suppurative inflammation arising within the periodontal tissues alongside a tooth and is distinct from the more common periapical abscess. Most arise in patients with pre-existing advanced periodontitis, and may occur either as a direct result of an increase in virulence

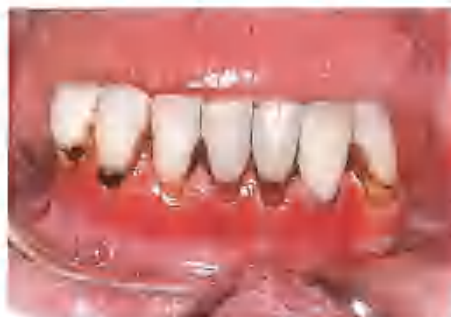

Fig. 7.15 Desquamative gingivitis associated with lichen planus.

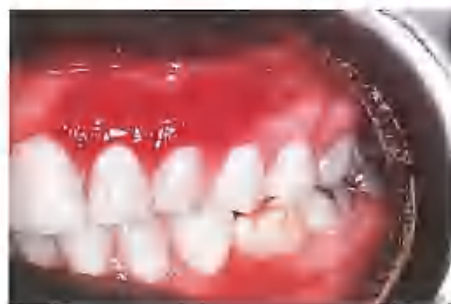

Fig. 7.16 Desquamative gingivitis associated with hypersensitivity to lipstick localized to where the cosmetic contacted the gingiva.

and toxic factors released by plaque organisms or secondary to reduction in host resistance. Obstruction to the drainage of exudate from a pocket predisposes to abscess formation. This may occur particularly in infrabony pockets pursuing a tortuous course around the root, or where fibrosis or oedema in the superficial parts of the pocket cause tight approximation of the soft-tissue wall to the neck of the tooth. Impaction of foreign material, such as food debris, into a pocket may also lead to abscess formation. In the absence of pocketing, periodontal abscesses may follow traumatic injury to a tooth, lateral perforation of the root in endodontic therapy, or stab infections. The latter arise when a foreign object, such as a toothbrush bristle or fish bone, penetrates the tissue introducing infection into the periodontal ligament. If there is only superficial penetration the abscess will be located in the gingiva.

Clinically, periodontal abscesses may be acute or chronic. An acute abscess develops rapidly and is accompanied by throbbing pain and redness, swelling, and tenderness of the overlying mucosa. The affected tooth is usually tender to percussion but most are vital. The abscess may discharge spontaneously through the mouth of a pocket, but in deep-seated lesions or where drainage is obstructed, it may track and present with a sinus opening on the mucosa somewhere along the length of the root (Fig. 7.17). Discharge of pus relieves the acute symptoms and the lesion may heal or become chronic with intermittent discharge. The chronic abscess may be asymptomatic or give rise to episodes of dull pain. Acute exacerbations are common.

Radiographic appearances are very variable and are influenced by the extent of previously existing bone destruction, the stage of the abscess, and its location. There is often extensive pocketing and abscess formation may be accompanied by rapid deepening of such defects, but in the early stages of an acute lesion there may be no associated radiographic changes. In deep-seated lesions there may be a discrete radiolucent area along the lateral aspect of the root.

Pericoronitis

Pericoronitis is inflammation of the soft tissues around the crown of a partially erupted tooth and is seen commonly in association with mandibular third molars. The space between the crown of the tooth and the overlying gum flap is an ideal area for the

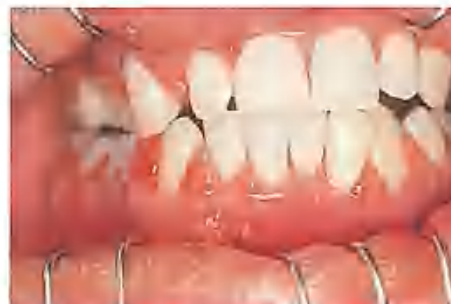

Fig. 7.17 Pointing lateral periodontal abscesses.

accumulation of bacterial plaque and food debris, leading to inflammation. Inflammatory oedema leads to swelling of the flap which predisposes to trauma from the opposing teeth and exacerbation of the inflammation. The usual symptoms are pain, tenderness in the gum flap, and a bad taste which is associated with persistent oozing of pus from beneath the flap. Limitation of opening and discomfort on swallowing may also be present. In severe cases, an acute pericoronal abscess may develop which can remain localized or be associated with cellulitis and extension of infection into adjacent surgical spaces.


Age changes in the periodontium

Although epidemiological studies have shown that the prevalence and severity of periodontal disease increases with age, this is most likely the result of repeated attacks of active destruction occurring with time rather than an intrinsic change associated with the ageing process itself. Gingival recession has been considered as an age change, but is now thought to be part of the clinical spectrum of periodontitis in which plaque and mechanical trauma are aetiological factors. There is no evidence that the elderly are particularly susceptible to periodontal disease, although this might be expected because of the decreased efficiency of both host defence systems and healing which are associated with ageing.

Several histological changes associated with ageing have been reported but it is likely that they are of little clinical significance. They include increased apposition of cementum, decreased cellularity of periodontal tissues, and disordered insertions of periodontal ligament fibres into bone and cementum.

Further reading

- Armitage, G. C. (1999). Development of a classification system for periodontal diseases and conditions. *Annals of Periodontology*, 4, 1–6.
- Beck, J. D. and Slade, G. D. (1996). Epidemiology of periodontal diseases. *Current Opinion in Periodontology*, 3, 3–9.
- Dahlen, G. (1993). Role of suspected periodontopathogens in microbiological monitoring of periodontitis. *Advances in Dental Research*, 7, 163–74.
- Embery, G. and Waddington, R. (1994). Gingival crevicular fluid: biomarkers of periodontal tissue activity. *Advances in Dental Research*, 8, 329–36.
- Hardie, J. M. (1992). Oral microbiology: current concepts in the microbiology of dental caries and periodontal disease. *British Dental Journal*, 172, 271–8.
- Herrera, D., Roldan, S., and Sanz, M. (2000). The periodontal abscess: a review. *Journal of Clinical Periodontology*, 27, 377–86.
- Jenkinson, H. F. and Dymock, D. (1999). The microbiology of periodontal disease. *Dental Update*, 26, 191–7.
- McCauley, L. K. and Nohutcu, R. M. (2002). Mediators of periodontal osseous destruction and remodelling: principles and implications for diagnosis and therapy. *Journal of Periodontology*, 73, 1377–91.
- Oh, T. J., Eber, T., and Wang, H. L. (2002). Periodontal diseases in the child and adolescent. *Journal of Clinical Periodontology*, 29, 400–10.
- Ong, G. (1998). Periodontal disease and tooth loss. *International Dental Journal*, 48 (Suppl.1), 33–8.
- Page, R. C. and Beck, J. D. (1997). Risk assessment for periodontal diseases. *International Dental Journal*, 47, 61–87.
- Page, R. C., Offenbacher, S., Schroeder, H. E., Seymour, G. J., and Kornan, K. S. (1997). Advances in the pathogenesis of periodontitis: summary of developments, clinical implications, and future directions. *Periodontology 2000*, 14, 216–48.
- Page, R. C. (1998). Periodontal diseases: a new paradigm. *Journal of Dental Education*, 62, 812–21.
- Reynolds, J. J. and Meikle, M. C. (1997). Mechanisms of connective tissue matrix destruction in periodontitis. *Periodontology 2000*, 14, 144–57.
- Seymour, R. A., Thomason, J. M., and Ellis, J. E. (1996). The pathogenesis of drug-induced gingival overgrowth. *Journal of Clinical Periodontology*, 23, 165–75.
- Socransky, S. S. and Haffajee, A. D. (1992). The bacterial etiology of destructive periodontal disease: current concepts. *Journal of Periodontology*, 63, 322–31.



Hyperplastic, neoplastic, and related disorders of oral mucosa


HYPERPLASIAS OF ORAL MUCOSA

- Epulides
- Pyogenic granuloma
- Fibroepithelial polyp
- Denture irritation hyperplasia
- Papillary hyperplasia of the palate

CONNECTIVE TISSUE NEOPLASMS AND ALLIED CONDITIONS

- Tumours of fibrous tissue
- Tumours of adipose tissue
- Tumours of vascular tissue
- Tumours of peripheral nerves
- The granular cell tumour
- Tumours of muscle
- Malignant lymphomas

FURTHER READING



Hyperplastic, neoplastic, and related disorders of oral mucosa

Hyperplasias of oral mucosa

Hyperplasia of gingival tissue resulting in generalized gingival enlargement has been discussed in Chapter 7. Localised hyperplastic lesions of the oral mucosa, which are common and are usually responses to chronic inflammation, are described in this chapter.

An essential feature of chronic inflammation is that the processes of inflammation and repair occur simultaneously and the production of granulation tissue is one of the hallmarks of the disease process. Most hyperplasias of the oral mucosa represent exuberant production of granulation tissue in chronic inflammatory reactions. Although several named lesions are distinguished either on clinical or histological grounds, it is important to appreciate that many are variations of the same basic disease process. Histologically, there is a spectrum of change varying from chronically inflamed, richly cellular granulation tissue to relatively non-inflamed and avascular masses of dense collagen.

Localized hyperplasias of oral mucosa can arise anywhere in the mouth, but those arising from the gingiva usually receive the designation 'epulis'. Although the term is non-specific and literally means 'on the gum', by common usage it implies a localized chronic inflammatory hyperplasia of the gingiva. The exception is the rare congenital epulis of the newborn (see Chapter 10).

The common, localized hyperplasias of oral mucosa are listed in Table 8.1.

Epulides

Epulides are common. They present as localized tumour-like gingival enlargements but are hyperplastic and not neoplastic

lesions. Most arise from the interdental tissues. Trauma and chronic irritation, particularly from subgingival plaque and calculus, are considered to be the main aetiological factors.

Many terms have been applied to these lesions, which makes analysis of their incidence difficult. However, the fibrous epulis is the commonest, accounting for over half the cases, followed by the vascular types. The peripheral giant cell granuloma is relatively uncommon and accounts for about only 10 per cent of epulides. The lesions share several common clinical features. They are all more common in females than males, particularly so in the case of vascular lesions, and about 80 per cent occur anterior to the molar teeth. Over half of the lesions present in the intercanine area and they are slightly more common in the maxilla than the mandible. They may recur if local precipitating factors are not identified and removed or, particularly in the case of the peripheral giant cell granuloma, if the lesion has not been completely excised in the first instance. Reported recurrence rates differ considerably between series, and are probably falling following recognition of the importance of removal of local irritants. However, the peripheral giant cell granuloma has the highest rate (from 5 per cent to over 70 per cent in different series) followed by the vascular epulides. Recurrence of the fibrous epulis is relatively uncommon.

Fibrous epulis

The fibrous epulis presents as a pedunculated or sessile mass which is usually of firm consistency and of similar colour to the adjacent gingiva (Fig. 8.1), although this will depend on the degree of vascularity and inflammation within the lesion. The surface may be ulcerated, in which case it will be covered by a yellowish fibrinous exudate. The epulis occurs over a wide age range but most arise between 11 and 40 years of age.

Histologically, the lesion usually comprises varying amounts of richly cellular fibroblastic granulation tissue and interlacing bundles of mature collagen fibres (see Box 8.1). There is a variable inflammatory cell infiltration, predominantly of plasma cells. Amorphous deposits of calcification and/or trabeculae of metaplastic bone are found within the fibroblastic tissue in about one-third of cases (Fig. 8.2), particularly if there is ulceration of the covering stratified squamous epithelium. However, there is no reason for regarding such epulides as a distinct entity and the presence or absence of calcification does not affect their clinical

Table 8.1 Localized hyperplastic lesions of the oral mucosa

Epulides	
- fibrous epulis	
- pyogenic granuloma	} Vascular epulides
- pregnancy epulis	
- peripheral giant cell granuloma (giant cell epulis)	
Pyogenic granuloma	
Fibroepithelial polyp	
Denture irritation hyperplasia	
Papillary hyperplasia of the palate	

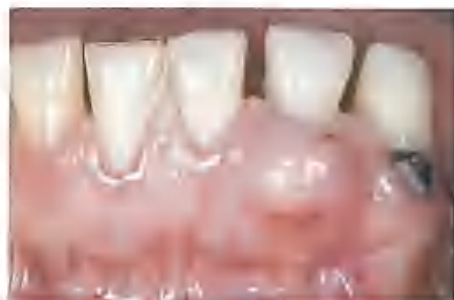

Fig. 8.1 Fibrous epulis.

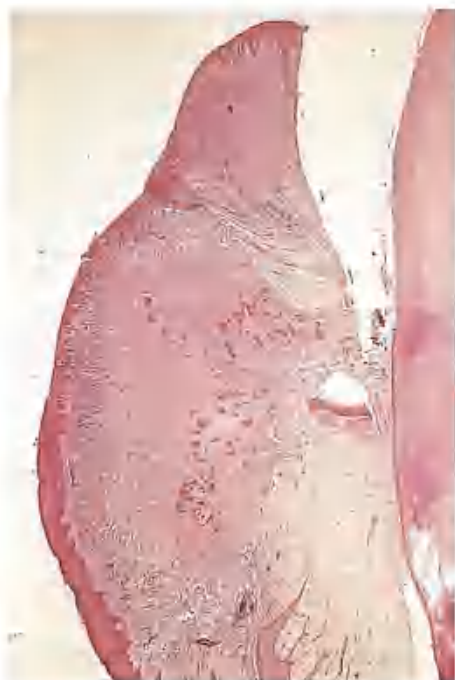


Fig. 8.2 Fibrous epulis with foci of calcification.

behaviour. Less commonly the lesion consists of dense, relatively avascular fibrous tissue identical to the fibroepithelial polyp (see later).

Vascular epulides

The pyogenic granuloma and pregnancy epulis present as rather soft, deep reddish-purple swellings (Fig. 8.3) which are often extensively ulcerated. Haemorrhage may occur either spontaneously or on minor trauma. The distinction between the lesions is purely clinical. Histologically, they are identical and the pregnancy epulis is regarded as a pyogenic granuloma occurring in a pregnant female. The lesions occur over a wide age range but, as might be expected, there is a peak incidence in females of child-bearing age. Lesions occurring in pregnancy can arise at any time from the first to the ninth month, although onset is usually around the end of the first trimester. They gradually increase in size, but after delivery may regress spontaneously or decrease in

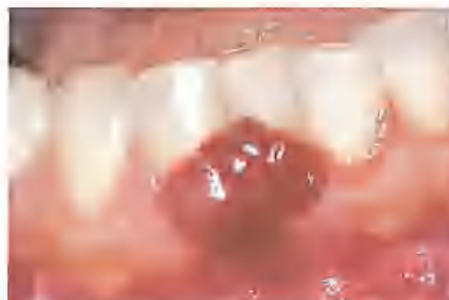

Fig. 8.3 Pyogenic granuloma (vascular epulis).

size and assume the clinical and histological features of a fibrous epulis. Control of haemorrhage may be difficult after excision of a pregnancy epulis but fibrosis of the lesion, following birth of the child, reduces the problem. Lesions excised during pregnancy also frequently recur and for these reasons it may be preferred to delay surgical treatment until after the birth of the child.

Histologically, the pyogenic granuloma and pregnancy epulis are characterized by vascular proliferation, which may take the form of rather solid sheets of endothelial cells with little evidence of canalization (Fig. 8.4) or of numerous small vessels and large, dilated, thin-walled vascular spaces (Fig. 8.5). Both patterns may coexist in different parts of the same lesion. The vascular element is supported by a delicate and often oedematous cellular fibrous stroma (see Box 8.1). Inflammatory cell infiltration is variable but seldom prominent except beneath areas of ulceration.

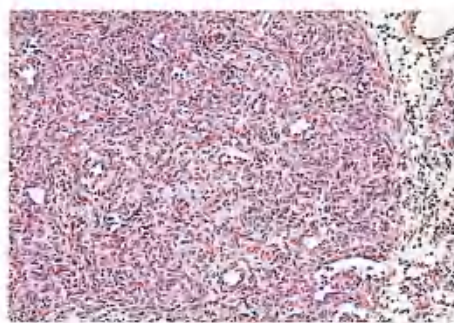


Fig. 8.4 Pyogenic granuloma showing sheets of endothelial cells.

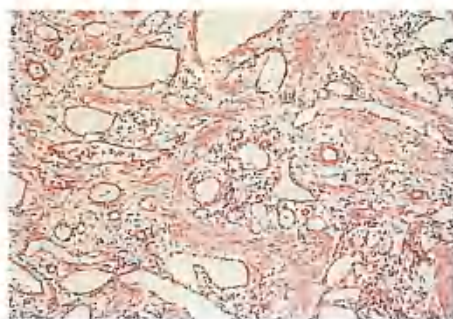


Fig. 8.5 Pyogenic granuloma showing numerous dilated capillary vessels.

Box 8.1 Epulides

Fibrous/vascular types

- Exuberant granulation/fibrous tissue production is associated with synthesis and release of growth factors.
- Fibroblast growth factors and angiogenic factors are particularly important.
- Macrophages within the chronic inflammatory cell infiltrate are potent sources of growth factors.

Giant cell epulis

- Multiple synchronous lesions are rare but may be associated with hyperparathyroidism or, more rarely, with neurofibromatosis type I.

The term 'pyogenic granuloma' is historical. It was originally applied because the identical lesion on skin was thought to be a reaction to infection by pyogenic organisms. Although this is no longer accepted, the term is now firmly entrenched in the dermatological and dental literature.

Peripheral giant cell granuloma (giant cell epulis)

The peripheral giant cell granuloma has characteristics which separate it from the fibrous and vascular epulides. It occurs over a wide age range but the peak incidence in males is in the second decade compared to the fifth decade for females. The lesion can arise anywhere on the gingival or alveolar mucosa in dentate or edentate patients but most occur anterior to the molar teeth. Females are affected about twice as frequently as males, and slightly more occur in the mandible than in the maxilla. It presents as a pedunculated or sessile swelling of varying size which is typically dark red in colour and commonly ulcerated. In dentate areas of the jaws the lesion usually arises interdental and may have an hour-glass shape with buccal and lingual swellings joined by a narrow waist between the teeth (Fig. 8.6). Radiographs may reveal superficial erosion of the crest of the interdental bone or, in edentulous areas, of the alveolar bone margin but these are not constant features. However, radiographs are required for definitive diagnosis since it is possible for a central giant cell

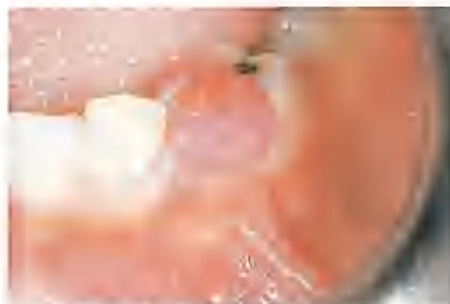

Fig. 8.6 Peripheral giant cell granuloma arising interdentally.

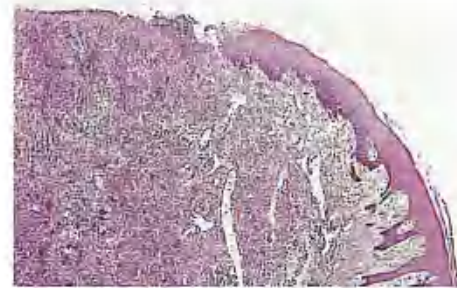


Fig. 8.7 Peripheral giant cell granuloma with ulcerated surface showing focal collections of giant cells in a vascular, cellular stroma.

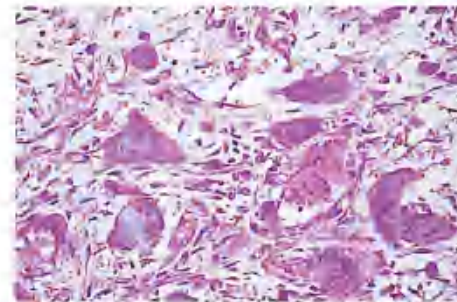


Fig. 8.8 Multinucleated giant cells in a peripheral giant cell granuloma.

granuloma (see Chapter 16) to perforate the cortex and present as a peripheral lesion.

Microscopically, the peripheral giant cell granuloma consists essentially of focal collections of multinucleated osteoclast-like giant cells lying in a richly vascular and cellular stroma (Figs 8.7, 8.8). The collections of giant cells are separated by fibrous septa. A narrow zone of fibrous tissue, often containing dilated blood vessels, also separates the core of the lesion from the covering stratified squamous epithelium.

The giant cells are numerous and show variation in size, shape, and number of nuclei. Large numbers of vascular channels of varying diameter are found throughout, and extravasated red blood cells and deposits of haemosiderin are common. The mononuclear stromal cells are ovoid or spindle-shaped and comprise a mixture of fibro-

Key points – Epulides

- localized gingival hyperplasias
- reactive to local irritation/trauma
- may recur unless predisposing factors removed
- fibrous/vascular types result from exuberant production of granulation/fibrous tissue
- vascular type may mature to fibrous type
- giant cell type clinically and histologically distinct

blasts, macrophages, and endothelial cells. Some macrophages contain phagocytosed haemosiderin. Occasionally, a few trabeculae of bone or osteoid may be found within the lesion.

The pathogenesis of the peripheral giant cell granuloma is unknown, but it is generally accepted that it is a reactive hyperplasia and, like other hyperplastic conditions of the oral mucosa, trauma may be an important aetiological factor. An origin from periosteum rather than gingiva has been suggested since the lesion can cause superficial erosion of bone and occurs in edentate as well as dentate areas of the jaws. The origin of the giant cells is not fully resolved. Although they could be of macrophage origin, derived from fusion of mononuclear precursors in the stroma, close similarities to osteoclasts have been reported. Very rarely the lesions may be multiple, associated with systemic disorders (see Box 8.1).

Pyogenic granuloma

Although the majority of pyogenic granulomas in the oral cavity arise on the gingiva, the lesion can occur at other sites, for example the tongue, and buccal and labial mucosa (Fig. 8.9) as a result of trauma. The clinical appearances and histology are the same as for the gingival lesion.

Fibroepithelial polyp

The fibroepithelial polyp is a common lesion occurring over a wide age range. It arises mainly in the cheeks, particularly along the occlusal line, lips, and tongue, and presents as a firm, pink, painless pedunculated or sessile polypoid swelling which varies in size from a few millimetres to a centimetre or more in diameter (Fig. 8.10). When the lesion occurs in the palate under a denture it becomes flattened and leaf-like and is commonly referred to as

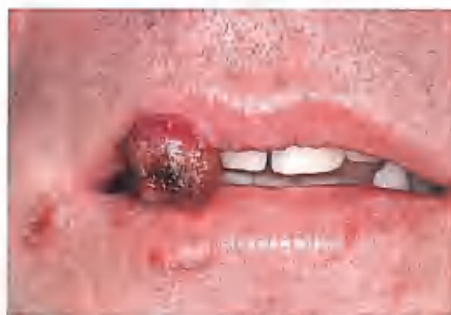

Fig. 8.9 Pyogenic granuloma.

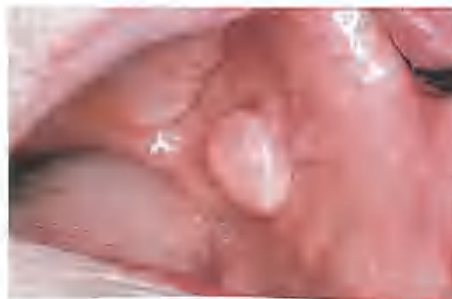

Fig. 8.10 Fibroepithelial polyp.

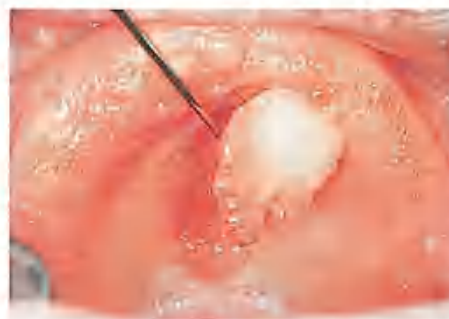

Fig. 8.11 Leaf fibroma (fibroepithelial polyp).

a leaf fibroma (Fig. 8.11). This is a misnomer since the lesion is not a benign neoplasm. Once established, the fibroepithelial polyp does not appear to increase significantly in size with time, and some patients may have been aware of a lump in the mouth for many years. Minor trauma is thought to be an important initiating factor and occasionally the surface is whitish due to mild frictional keratosis. Ulceration is not a feature unless the patient has bitten into the polyp.

Histologically, the lesion comprises a core of dense, relatively avascular and acellular fibrous tissue, which has a scar-like quality (Fig. 8.12). Thick interlacing bundles of collagen fibres are the dominant feature and they blend with those of the adjacent normal tissue through the base of the lesion. Fibroblasts are scanty although plump, angular, and occasionally multinucleate forms are sometimes observed, particularly in the subepithelial zone, and such lesions are referred to by some authors as giant cell fibromas. However, they are hyperplastic rather than neoplastic

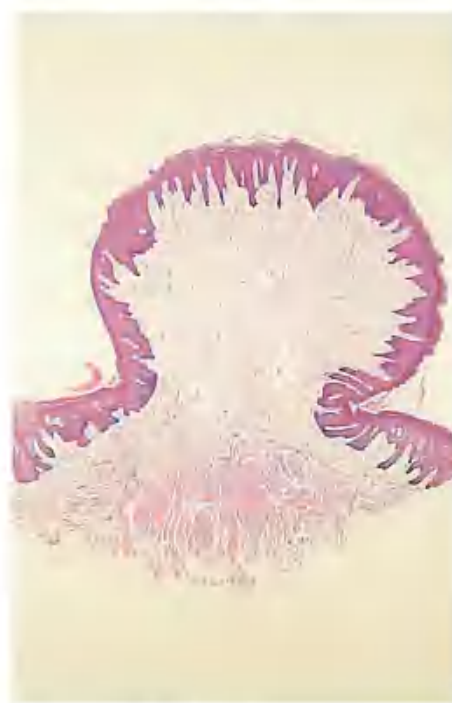


Fig. 8.12 Fibroepithelial polyp.

lesions, and tend to occur in younger patients. The surface of a fibroepithelial polyp is covered by stratified squamous epithelium which may vary in thickness and show areas of hyperkeratosis in response to frictional irritation. Typically, there is little or no inflammatory cell infiltration and the lesion can be regarded as an exuberance of reparative scar tissue.

Denture irritation hyperplasia

The term 'denture irritation hyperplasia' is applied to hyperplastic mucosa related to the periphery of an ill-fitting denture. The lesions may be single or multiple and present most frequently as one or several broad-based, leaf-like folds of tissue embracing the over-extended flange of the denture (Figs 8.13, 8.14). They usually arise in the depths of the vestibular and lingual sulci but can involve the inner surfaces of the lips and cheeks, and the palate along the posterior edge of an upper denture. They occur more frequently in relation to lower than upper dentures, and more often in females than males. Most of the patients have worn ill-fitting dentures for many years. Clinically, the hyperplastic tissue is usually firm in consistency and not grossly inflamed, but there may be ulceration at the base into which the flange of the denture fits.

Papillary hyperplasia of the palate

The aetiology of this condition is not fully understood, but minor trauma, related to rocking and rotation of ill-fitting dentures, and poor denture hygiene are factors in most cases. The patient may give a history of sleeping with dentures in and often there is a

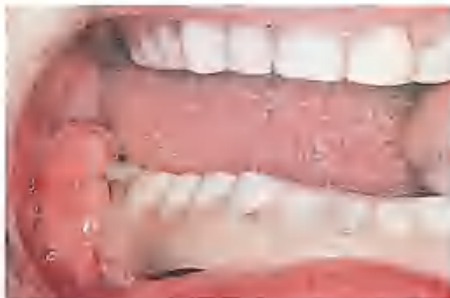

Fig. 8.13 Denture irritation hyperplasia.

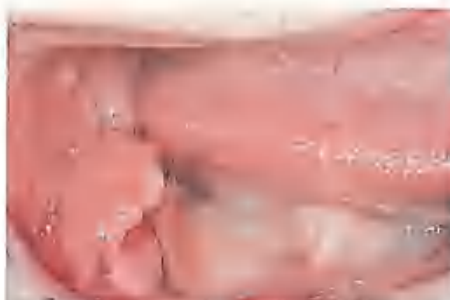

Fig. 8.14 Folds of hyperplastic tissue associated with the ill-fitting denture in Fig. 8.13.

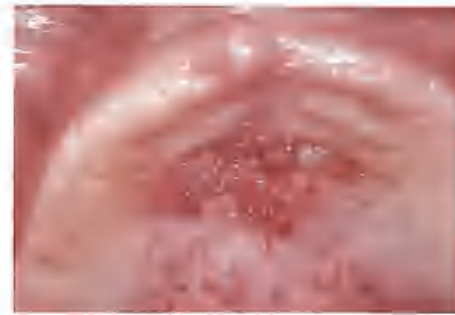

Fig. 8.15 Papillary hyperplasia of the palate.

Candida-associated denture stomatitis (see Chapter 11) which may be a contributing factor. Clinically, the condition presents as numerous, small, tightly packed papillary projections over part or all of the denture-bearing area which gives the hard palate a pebbled appearance (Fig. 8.15). The mucosa is often red and oedematous, particularly if there is an accompanying candidosis.

Microscopically, the lesion shows numerous papillary projections each comprising a core of hyperplastic, chronically inflamed granulation and fibrous tissue. The covering stratified squamous epithelium is also hyperplastic, and in some cases this may be so prominent as to mimic a squamous cell carcinoma. This appearance may be referred to as pseudo-epitheliomatous hyperplasia and is characterized by irregular proliferation and branching of rete ridges which extend for considerable distances into the underlying connective tissue, suggesting invasion. Keratin pearl formation may also occur within the hyperplastic epithelium, but there are no atypical cytological features.

Connective tissue neoplasms and allied conditions

A great variety of benign and malignant connective tissue tumours and tumour-like lesions have been reported from the oral cavity but, with few exceptions, they are all rare. Clinically, most of the benign connective tissue tumours present as swellings which may be indistinguishable from hyperplastic lesions. Histologically, oral connective tissue tumours resemble their counterparts occurring at other sites in the body. The various lesions will be discussed under their tissues of origin.

Tumours of fibrous tissue

In comparison to hyperplastic lesions, neoplasms and other causes of fibrous overgrowth (Table 8.2) are rare in the mouth.

True benign neoplastic overgrowths of fibrous tissue in the oral mucosa, if they exist at all, are seldom diagnosed since clinically and histologically they cannot reliably be distinguished from hyperplasias. The term 'fibroma' has been used inappropriately from time to time to describe reactive lesions such as the fibrous epulis and fibroepithelial polyp, but to avoid confusion the term is best avoided except for specific entities such as the odonto-

Table 8.2 Localized fibrous overgrowths of the oral mucosa. (Causes of generalized fibrous overgrowth of the gingiva are discussed in Chapter 7)

Hyperplastic lesions
– epulides (fibrous, vascular, giant cell)
– pyogenic granuloma
– fibroepithelial polyp
– denture irritation and papillary hyperplasia
Neoplastic and neoplastic-like lesions
– peripheral odontogenic fibroma
– fibrosarcoma
– fibrous histiocytoma
– nodular fasciitis
– fibromatosis

genic fibroma, which may also present as a peripheral lesion (see Chapter 15).

Fibrosarcoma of the oral soft tissues is rare but appears to have a good prognosis with reported 5-year survival rates of about 70 per cent. Examples of other rare fibrous tumours and overgrowths are included in Box 8.2 later in the chapter.

Tumours of adipose tissue

The lipoma presents as a soft, elastic, yellowish-coloured swelling which in the mouth occurs most commonly in the cheek and

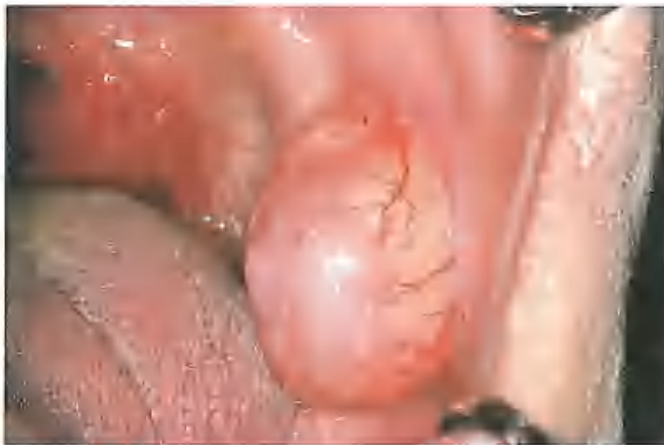

Fig. 8.16 Lipoma.



Fig. 8.17 Lipoma comprising sheets of mature adipocytes.

tongue (Fig. 8.16). Microscopically, the tumour consists of a circumscribed mass of mature adipose tissue supported by a fibrous stroma (Fig. 8.17). The amount of stroma varies considerably and in some tumours forms a significant part of the lesion. Such lesions are usually described as fibrolipomas. A typical feature of a lipoma is that the tumour floats in the fixative solution when dropped into a specimen bottle.

Liposarcomas are uncommon in the mouth and most of those reported have arisen in the cheek or floor of the mouth/base of tongue region. They respond well to local excision and generally have a good prognosis.

It should be remembered that in infants and very young children ulcerated tumour-like masses of partly necrotic fat may occasionally be seen protruding through the mucosa of the cheek as a result of traumatic herniation of the buccal pad of fat.

Tumours of vascular tissue

Haemangioma

Haemangiomas are common tumours which are generally accepted to be hamartomatous rather than truly neoplastic. They occur more commonly in the head and neck region than in any other part of the body, and most are present at birth or arise in early childhood, although some may not be noticed until old age. Oral lesions occur most commonly in the lips, tongue, cheeks, or palate and vary considerably in size and shape. They are characteristically dark reddish-purple in colour (Fig. 8.18), of soft consistency, and may present as a smooth, flat or raised, sometimes globular lesion of the mucosa. Typically, they blanch on pressure. Some may have a nodular consistency on palpation as a result of thrombosis and calcification, in which case the phleboliths may be detected radiographically. The lesions are usually symptomless although trauma may give rise to haemorrhage. A history of recent increase in size may be due to haemorrhage, thrombosis, or inflammation. Haemangiomas are usually solitary, although multiple lesions may occur and, rarely, these may be part of a generalized angiomatous syndrome.

Histologically, haemangiomas are usually divided into capillary and cavernous types depending on the size of the vascular spaces, although mixed types are common (Figs 8.19, 8.20). The spaces are lined by endothelium and contain red blood cells.

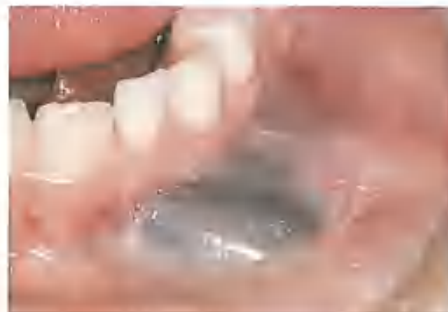

Fig. 8.18 Haemangioma.

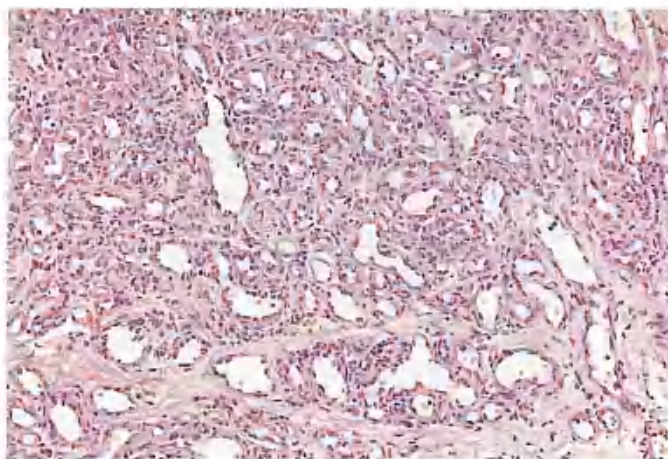


Fig. 8.19 Capillary haemangioma.

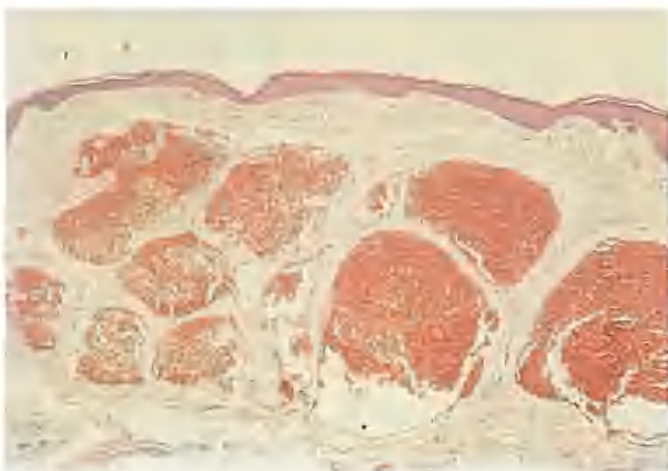


Fig. 8.20 Cavernous haemangioma.

Thrombosis, organization, and calcification may occur. Some lesions, particularly in infants, may be more solid and extremely cellular and consist of sheets of endothelial cells with little evidence of canalization. These may represent an immature stage of the capillary or cavernous type and differentiation from a pyogenic granuloma may be difficult. Angiomatous malformation may also involve arteries and veins and some lesions consist almost entirely of thick-walled vessels.

In addition to the mucosa, oral haemangiomas may also involve muscle, bone, and the major salivary glands. Although the latter are infrequent, the juvenile haemangioma is the com-

Key points – Haemangiomas

- common, hamartomatous lesions
- various clinical/histological subtypes
- may be part of an angiomatous syndrome

monest tumour occurring in the salivary glands during infancy and childhood. It occurs more frequently in females than in males.

Other vascular anomalies seen in oral mucosa are sublingual varicosities affecting the ranine veins, and local venous anomalies on the vermillion border of the lips sometimes called venous lakes. Both of these conditions increase in frequency with age.

Malignant vascular tumours are rare, but the lesions of Kaposi's sarcoma are commonly found in the mouth of patients with the acquired immunodeficiency syndrome (AIDS). It is discussed in more detail in Chapter 11.

Generalized angiomatous syndromes that may have oral lesions include:

STURGE-WEBER SYNDROME

This congenital disorder is characterized by the combination of haemangiomas of the face over one or more branches of the trigeminal nerve (Fig. 8.21), ipsilateral haemangiomas and calcifications of the leptomeninges over the cerebral cortex, and convulsions affecting the limbs on the opposite side of the body. Haemangiomas may also occur in the oral mucosa.

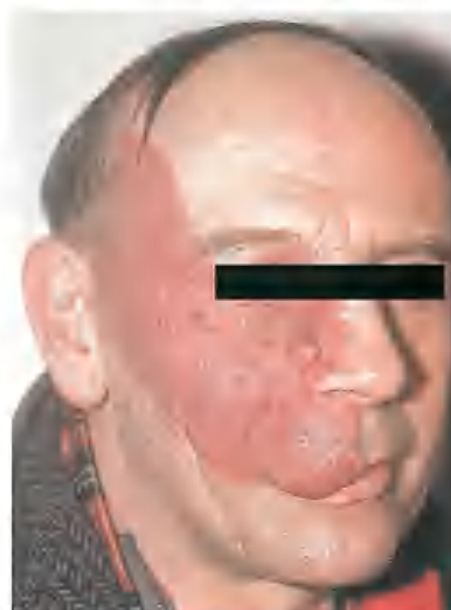

Fig. 8.21 Haemangiomas malformation related to maxillary division of the trigeminal nerve in Sturge-Weber syndrome.

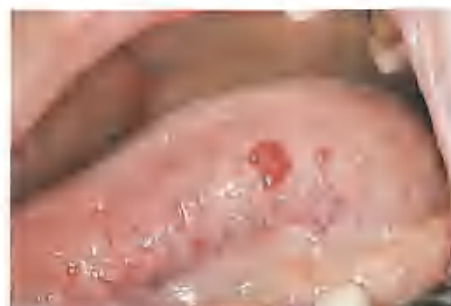

Fig. 8.22 Hereditary haemorrhagic telangiectasia.

HEREDITARY HAEMORRHAGIC TELANGIECTASIA

This disorder is transmitted as an autosomal dominant and is characterized by multiple knots of dilated malformed capillaries (telangiectases) in skin, mucous membranes (Fig. 8.22), and internal organs. Frequent nose-bleeding is the commonest presenting symptom.

Lymphangioma

Lymphangiomas are less common than haemangiomas but like the latter are considered to be hamartomatous rather than neoplastic lesions. They are usually present at birth or arise in early childhood, and although they can occur anywhere in the oral mucosa they are seen most frequently in the tongue and are a well-recognized cause of macroglossia (Fig. 8.23). Trauma to a lymphangioma may give rise to inflammation, calcification, or a sudden increase in size.

Histologically, the lesion consists of capillary or more commonly cavernous, endothelial-lined spaces containing lymph. A rather typical feature of superficially located lesions is that the

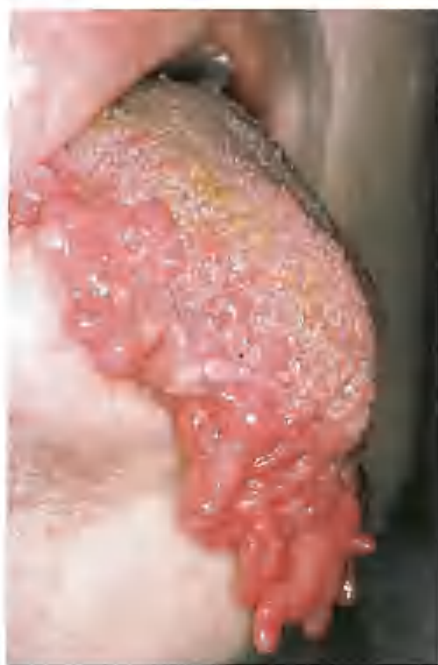

Fig. 8.23 Lymphangioma with macroglossia.

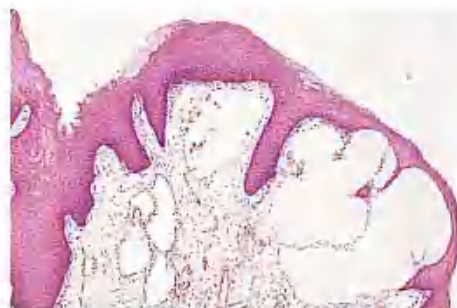

Fig. 8.24 Lymphangioma of the tongue.

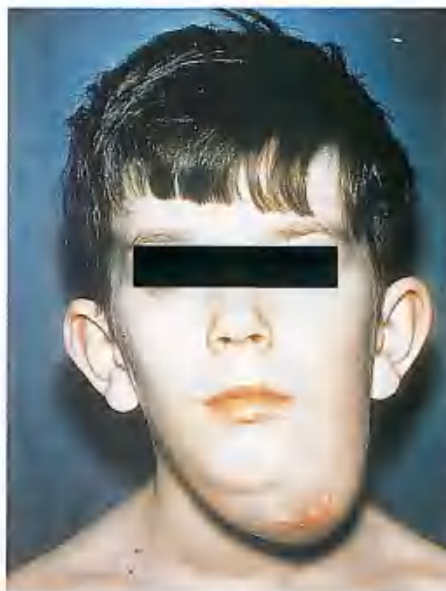

Fig. 8.25 Cystic hygroma.

lymphatic spaces extend close up to the overlying epithelium which they may cause to bulge (Fig. 8.24). Clinically, the surface of such lesions manifests numerous papillary projections or small nodular masses.

The cystic hygroma (Fig. 8.25) is a lymphangiomatous malformation which occurs early in the development of the lymphatic system and most frequently affects the head and particularly neck region. Most are detected at birth and present as large, fluctuant swellings often up to 10 cm in diameter. They may extend to involve the base of tongue, floor of mouth and, less commonly, buccal mucosa.

Tumours of peripheral nerves

The main tumours of peripheral nerves, which arise in connection with the nerve sheath, are the neurofibroma and neurilemmoma. Traumatic neuromas which are non-neoplastic, tumour-like masses also occur.

The neurofibroma may present as a solitary lesion or occur as multiple tumours associated with neurofibromatosis (von Recklinghausen's disease of nerves; see Box 8.2). The cutaneous nerves (Fig. 8.26) are usually involved and large tumour-like

Key points – Tumours of peripheral nerves

- neurofibroma
 - solitary
 - multiple (neurofibromatosis)
- neurilemmoma (Schwannoma)
- multiple mucosal neuromas
- traumatic neuroma

Box 8.2 Soft tissue tumours

Other lesions of fibrous tissue

- *fibrous histiocytoma*: rare in oral cavity; cells show fibroblastic and histiocytic differentiation; unpredictable behaviour, locally aggressive to malignant
- *nodular fasciitis*: rare in oral cavity; a reactive, non-neoplastic lesion; cause unknown; rapidly growing but self-limiting; histologically may resemble fibrosarcoma
- *fibromatoses*: very rare in oral cavity; a group of non-neoplastic but infiltrative fibrous lesions; do not metastasize; pseudosarcomatous features

Peripheral nerve tumours

- *neurofibromatosis*: type 1 associated with multiple hamartomatous, tumour-like proliferations of nerve sheath (type 2 involves central nervous system); familial history in about 50 per cent, autosomal dominant; remainder due to sporadic mutation; the NF1 gene is a tumour suppressor gene on chromosome 17
- *multiple endocrine neoplasia syndrome (MEN)*: multiple mucosal neuromas occur in MEN type 3 (also referred to as 2b); associated with medullary carcinoma of thyroid (in childhood/adolescence) and pheochromocytoma; oral lesions important to recognize as may precede thyroid cancer; the tumours are associated with mutation of the RET oncogene; family members are screened for RET mutations using peripheral blood leukocytes; a positive result indicates the need for prophylactic thyroidectomy

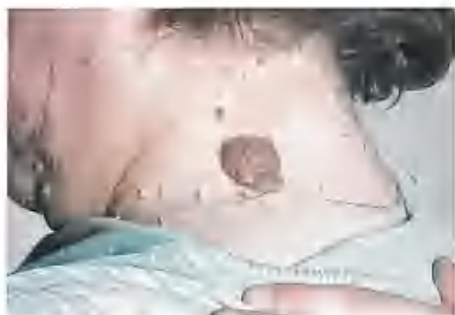


Fig. 8.26 Neurofibromatosis involving cutaneous nerves.

masses can cause considerable disfigurement – elephantiasis neuromatosa. The skin may also show melanic pigmentation described as *café-au-lait* spots, which precede the neural lesions. Oral lesions occur in about 7 per cent of cases as mucosal swellings (Fig. 8.27) involving most frequently the tongue and gingiva or, more rarely, as intraosseous growths. The latter are more common in the mandible than the maxilla and arise in association with the inferior dental and mental nerves.

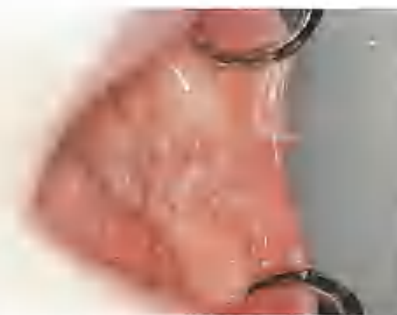

Fig. 8.27 Oral lesions in neurofibromatosis.

Malignant change in neurofibromas is a well-recognized complication in patients with neurofibromatosis, occurring in about 5–15 per cent of cases. Malignant change in solitary lesions is very rare.

Histologically, neurofibromas show considerable variation, but consist basically of a mixture of Schwann cells and fibroblasts with varying amounts of collagen and mucoid ground substance. A few nerve fibres run through the lesion which may be circumscribed or diffuse (Fig. 8.28). Lesions arising within or around the nerve trunk consist of a mass of convoluted nerves surrounded by a proliferation of Schwann cells and fibroblasts. This pattern is referred to as a plexiform neurofibroma and is characteristic of neurofibromatosis.

The neurilemmoma (Schwannoma) is an encapsulated tumour (Fig. 8.29) in which the spindle-shaped cells are often arranged in parallel bundles with palisaded nuclei (Fig. 8.30). Unlike the

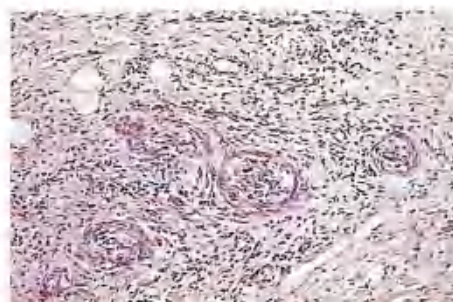


Fig. 8.28 Neurofibroma showing nerve fibres (circular structures) within the lesion, surrounded by Schwann cells and fibroblasts.

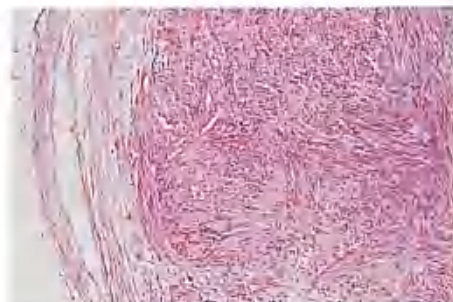


Fig. 8.29 Neurilemmoma showing encapsulation.

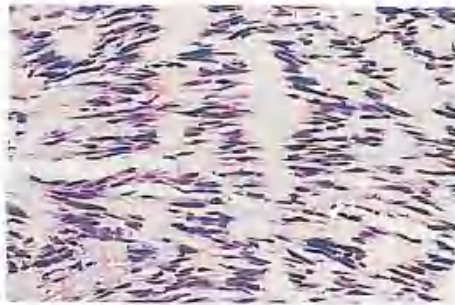


Fig. 8.30 Palisading of nuclei in neurilemmoma.

neurofibroma, nerve fibres do not run through the lesion but may be splayed over the capsule.

Multiple tumour-like malformations of peripheral nerves in oral mucosa are a feature of the multiple endocrine neoplasia syndrome which is associated with medullary carcinoma of the thyroid gland (see Box 8.1).

The traumatic neuroma is a non-neoplastic disorganized overgrowth of nerve fibres, Schwann cells, and scar tissue occurring at the proximal end of a severed nerve (Fig. 8.31). It represents an exaggeration of the normal process of nerve regeneration and usually presents as a small nodule which can give rise to considerable pain on pressure. It is uncommon in the oral cavity, which is surprising considering the frequency with which nerves are severed as a consequence of tooth extraction and other common minor surgical procedures.

The granular cell tumour

The granular cell tumour was commonly referred to in the past as the granular cell myoblastoma because it was thought to be of muscle origin. However, this is no longer accepted and the overwhelming evidence supports a neural origin from Schwann cells.

Clinically, the granular cell tumour presents as a painless, slow-growing swelling which arises most commonly in the tongue (Fig. 8.32). It occurs over a wide age range and although it is generally stated that there is no sex predilection, there is some evidence of an increased incidence in females. Multiple tumours may occur.

Histologically, the lesion is non-encapsulated and consists of sheets and strands of large cells with an extremely granular,

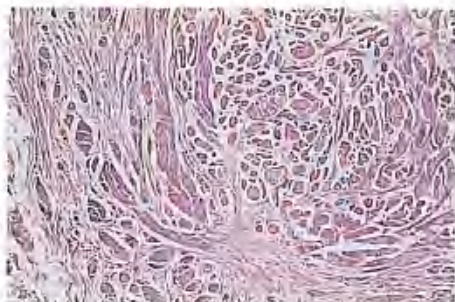


Fig. 8.31 Traumatic neuroma.

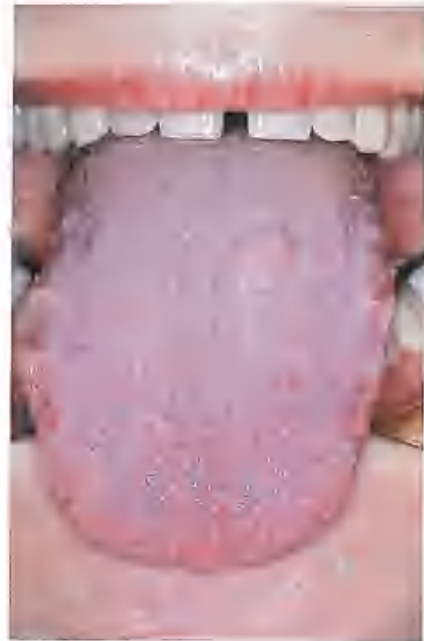

Fig. 8.32 Granular cell tumour of tongue.

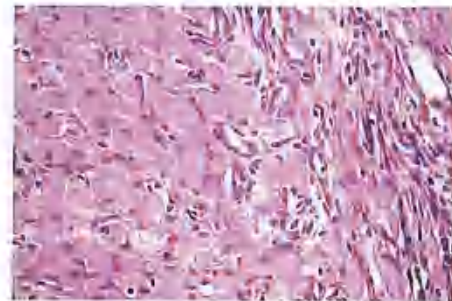


Fig. 8.33 Granular cell tumour.

eosinophilic cytoplasm (Fig. 8.33). Striated muscle fibres lying between the granular cells may give the impression of invasion but the lesion is entirely benign. The granules represent lysosomes, autophagic vacuoles, and residual bodies.

The covering stratified squamous epithelium commonly shows pseudo-epitheliomatous hyperplasia (epithelial hyperplasia that may be mistaken for carcinoma) (Fig. 8.34).

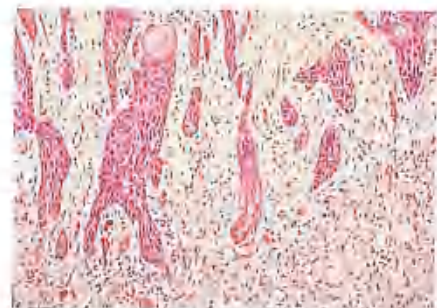


Fig. 8.34 High-power view of pseudoepitheliomatous hyperplasia associated with granular cell tumour.

Tumours of muscle

Tumours of either voluntary or smooth muscle are rare in the oral cavity.

Leiomyomas are smooth muscle tumours and in the mouth most arise from the walls of blood vessels (angiomyomas). Leiomyomatous hamartomas have also been reported but are very rare.

Leiomyosarcoma and rhabdomyosarcoma are both very rare in the oral cavity.

Malignant lymphomas

Malignant lymphomas may be defined as neoplastic proliferations of the cells of the lymphoreticular system. Numerous classifications have been devised and are still evolving as more information regarding clinical behaviour and recognition of the cell types involved in different lymphomas becomes available. However, most schemes divide lymphomas into two major categories:

- (1) Hodgkin's lymphoma (disease) (Fig. 8.35);
- (2) non-Hodgkin's lymphomas.

Hodgkin's lymphoma accounts for about 30 per cent of all malignant lymphomas and is predominantly a disease of young adults. It presents clinically with progressive, usually painless enlargement of lymph nodes and about 75 per cent of cases involve the cervical lymph nodes.

Histological diagnosis depends on identification of Reed–Sternberg cells (or their variants) which are regarded as the neoplastic component (Fig. 8.35). The classic Reed–Sternberg cell is a large cell with either a double or bilobed nucleus, the two nuclei lying side by side to produce a 'mirror image' effect.

The aetiology of the disease is unknown but genetic factors and viral infection, particularly Epstein–Barr virus infection, have been suggested. Prognosis depends on clinical staging and histological type, the prognosis decreasing from lymphocyte-predominant to lymphocyte-depleted types, but with modern

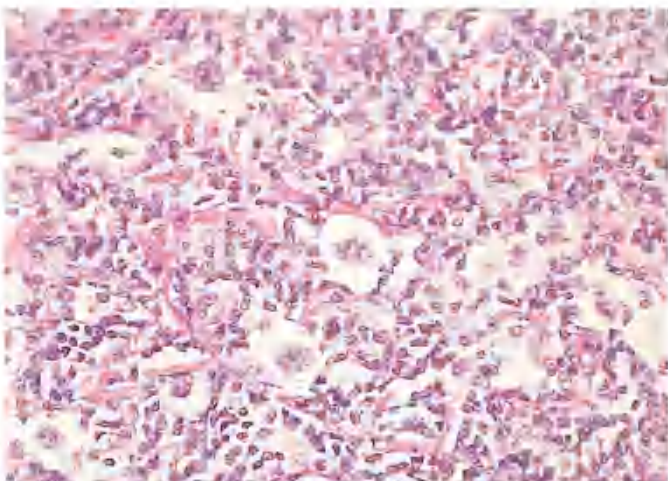


Fig. 8.35 Hodgkin's disease showing Reed-Sternberg cells.

chemotherapy overall survival rates of 50–70 per cent are reported.

The non-Hodgkin's lymphomas are divided into two main groups depending on their cell of origin:

- (1) B cell malignant lymphomas;
- (2) T/NK cell lymphomas (NK cells are closely related to T cells).

Within each group a large number of distinct entities is now recognized based on the morphological appearances and arrangement of the cells, their immunohistochemical phenotype, and genetic factors. The majority of malignant lymphomas are of B cell type (Figs 8.36, 8.37).

Malignant lymphomas in the head and neck region are relatively uncommon but may occur as part of widely disseminated disease or as a primary lesion. Their frequency is difficult to assess but Burkitt's lymphoma is of particular interest since this type, which is endemic in parts of Africa, commonly presents as a jaw tumour. It is discussed in more detail later.

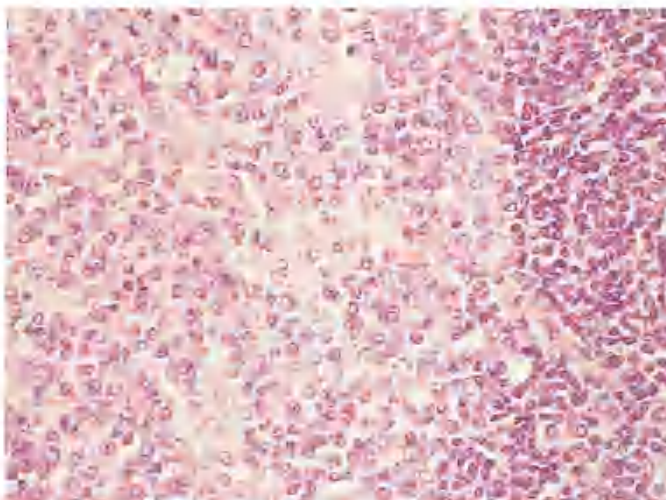


Fig. 8.36 Non-Hodgkin's malignant lymphoma. The malignant lymphoid cells (large pale cells) are replacing part of a lymph node (small dark lymphocytes).



Fig. 8.37 Corresponding field to that in Fig. 8.36. Immunohistochemical reaction (brown) using a monoclonal antibody to detect a B cell antigen in malignant lymphoid cells.

The majority of malignant lymphomas in the head and neck arise in lymphoid tissue, the cervical lymph nodes are most often affected followed by the lymphoid structures of Waldeyer's ring. Almost all types of Hodgkin's and of non-Hodgkin's lymphomas have been reported. Hodgkin's lymphoma is almost invariably nodal in distribution and part of disseminated malignancy.

Non-Hodgkin's lymphomas arising in tissues other than lymph nodes (extranodal lymphomas) are much less common than nodal tumours, but may arise in the oral soft tissues, salivary glands, and jaw bones as primary tumours which may remain as solitary lesions or progress to disseminated disease.

The lymphoid tissue associated with mucosa (including the salivary glands) forms part of a system specifically designed for mucosal defence, known as mucosa-associated lymphoid tissue or MALT. There is a tendency for lymphomas derived from MALT to remain localized for long periods and to disseminate only late in the course of the disease. MALT lymphomas have a better prognosis than nodal types. Mucosal lesions present as soft, fleshy, often ulcerated swellings. With regard to the salivary glands, malignant lymphomas may arise from lymphoid aggregates within these tissues or as malignant transformation in a myoepithelial sialadenitis (lymphoepithelial lesion) and Sjögren syndrome. The majority arise in the parotid gland.

An increased incidence of non-Hodgkin's malignant lymphomas is seen in patients with AIDS (see Chapter 11).

Burkitt's lymphoma

Burkitt's lymphoma is endemic in tropical equatorial Africa where it occurs mainly between the ages of 2 and 14 years and accounts for about 50 per cent of all malignant disease in children. Since the original reports from Africa, sporadic cases have subsequently been recorded from many countries throughout the world.

The disease is usually multifocal but in the endemic areas of Africa a jaw tumour is the presenting symptom in over half the cases. In non-African cases, abdominal lesions predominate and jaw lesions are relatively uncommon.

In the jaws, the lesions usually arise posteriorly and are more frequent in the maxilla than mandible, but more than one quadrant may be involved. The tumours are rapidly growing and are

often of massive size, producing gross facial disfigurement. In the maxilla, the tumours may extend into the sinuses, nose, nasopharynx, and orbit. Teeth in the area are loosened, displaced, and may be exfoliated.

Histologically, the tumour is of B cell type and consists of sheets of small, darkly-staining malignant lymphoid cells, scattered amongst which are numerous pale-staining macrophages producing a 'starry sky' pattern. In the areas of Africa where Burkitt's lymphoma is endemic there is strong evidence that infection with the Epstein-Barr virus (EBV) is a causal factor and that malaria is a cofactor. However, the majority of sporadic cases occurring elsewhere in the world are not associated with EBV infection. In both endemic and sporadic cases the neoplastic cells show a characteristic chromosomal abnormality associated with activation of an oncogene (see Box 8.3).

Without treatment Burkitt's lymphoma is a rapidly fatal condition, but with chemotherapy dramatic remissions are obtained in the great majority of patients.

Nasal NK/T cell lymphomas

Although NK/T cell lymphomas are uncommon, the nasal NK/T cell lymphoma is a distinct entity associated with extensive destruction of the midfacial area and can extend into adjacent structures, including the oral cavity (see Box 8.3).

Box 8.3 Malignant lymphomas

Burkitt's lymphoma

- Endemic Burkitt's lymphoma is associated with Epstein-Barr virus (EBV) infection and endemic malaria. EBV infection is ubiquitous, the main viral reservoir being B lymphocytes. Acute attacks of malaria impair the ability of EBV-specific T cells to control EBV proliferation. Repeated attacks therefore favour unrestrained growth of EBV-carrying B cells.
- Characteristic chromosome abnormality in malignant cells in Burkitt's lymphoma is reciprocal translocation of part of chromosome 8 with chromosome 14 (or, more rarely, 2 or 22). The *c-myc* oncogene is located on chromosome 8 near the point of translocation. Translocation to chromosome 14 (2 or 22) results in activation and increased transcription of the oncogene.

Nasal NK/T cell lymphoma


- It has been reported under a variety of terms in the past, including midline (lethal)/Stewart's granuloma, polymorphic reticulosis, and angiocentric T cell lymphoma.
- It arises in nose/paranasal sinuses; presents with nasal obstruction, epistaxis, and progresses to extensive necrosis.
- Neoplastic cells contain EBV which may play a role in the pathogenesis of the disease. Most cases are of NK type.

Key points – Malignant lymphomas

- divided into:
 - Hodgkin's lymphoma – characterised by Reed-Sternberg cells
 - non-Hodgkin's malignant lymphomas
 - (i) B cell types
 - (ii) T and NK cell types
- can present as nodal or extranodal lesions
- MALT lymphomas have a better prognosis than nodal types
- jaw bone lesions are a major feature of Burkitt's lymphoma

Further reading

- Epstein, J. B., Epstein, J. D., Le, N. D., and Gorsky, M. (2001). Characteristics of oral and paraoral malignant lymphoma: a population-based review of 361 cases. *Oral Surgery, Oral Medicine, Oral Pathology, Oral Radiology and Endodontics*, **95**, 519–25.
- Fowler, C. B., Hartman, K. S., and Brannon, R. B. (1994). Fibromatosis of the oral cavity and paraoral region. *Oral Surgery, Oral Medicine, Oral Pathology*, **77**, 373–86.
- Isaacson, P. G. (1990). Lymphoma of mucosa associated lymphoid tissue (MALT). *Histopathology*, **16**, 617–19.
- Kaplan, I., Calderson, S., and Kaffe, I. (1993). Radiological findings in jaws and skull of neurofibromatous type 1 patients. *Dentomaxillofacial Radiology*, **23**, 216–20.
- Magnusson, B. C. and Rasmusson, L. G. (1995). The giant cell fibroma. A review of 103 cases with immunohistochemical findings. *Acta Odontologica Scandinavica*, **53**, 293–6.
- Mighell, A. J., Robinson, P. A., and Hume, W. J. (1995). Peripheral giant cell granuloma: a clinical study of 77 cases from 62 patients, and literature review. *Oral Diseases*, **1**, 12–19.
- Ramsay, A. D. and Rooney, N. (1993). Lymphomas of the head and neck. 1: Nasofacial T-cell lymphoma. *Oral Oncology, European Journal of Cancer*, **29B**, 99–102.
- Ramsay, A. D. and Rooney, N. (1994). Lymphomas of the head and neck. 2: The B-cell lymphomas. *Oral Oncology, European Journal of Cancer*, **30B**, 155–9.
- Shapira, J. and Peylan-Ramu, N. (1998). Burkitt's lymphoma. *Oral Oncology*, **34**, 15–23.
- Williams, H. K. and Williams, D. M. (1997). Oral granular cell tumours: a histological and immunocytochemical study. *Journal of Oral Pathology and Medicine*, **26**, 164–9.
- Wolvius, E. B., van der Valk, P., van der Wal, J. E., van Diest, P. J., Huijgens, P. C., van der Waal, I., et al. (1994). Primary extranodal non-Hodgkin lymphoma of the oral cavity: an analysis of 34 cases. *Oral Oncology, European Journal of Cancer*, **30B**, 121–5.
- Yih, W. Y., Stewart, J. C., Kratochvil, F. J., and Zieper, M. B. (2002). Angiocentric T-cell lymphoma presenting as midface destructive lesion: case report and literature review. *Oral Surgery, Oral Medicine, Oral Pathology, Oral Radiology and Endodontics*, **94**, 353–60.



Keratoses and related disorders of oral mucosa

CLASSIFICATION

DEFINITION OF HISTOPATHOLOGICAL TERMS

HEREDITARY CONDITIONS

- Oral epithelial naevus (white sponge naevus)
- Other genodermatoses
- Leukoedema

TRAUMATIC KERATOSES

- Mechanical trauma – frictional keratosis
- Chemical trauma
- Thermal trauma


LEUKOPLAKIA

- Incidence
- Clinical features
- Aetiological factors
- Pathology, epithelial dysplasia
- Prognosis

DERMATOLOGICAL CAUSES OF WHITE PATCHES

- Lichen planus
- Lupus erythematosus

FURTHER READING



Keratoses and related disorders of oral mucosa

Classification

The colour of normal oral mucosa depends on the interplay between four factors: vascularity, melanin pigmentation, epithelial thickness, and keratinization. The term 'white patch' is often used clinically to describe the appearance of lesions presenting as white areas on the oral mucosa, and as many such lesions are associated with abnormal or increased keratin production, they are often described as keratoses. Oral keratoses appear white because the thickened or abnormal keratin becomes hydrated as a result of being bathed by saliva, and then evenly reflects light. A similar reaction is seen in areas of the skin, for example palms and soles, following prolonged soaking or bathing in water.

Other factors such as accumulation of keratinous debris on the surface of the epithelium may also produce a white patch. For example, a furred tongue associated with febrile illness appears white due to the retention of desquamated epithelial cells on the surface resulting from the lack of mechanical stimulation from the diet and decreased salivary flow associated with fever. However, the loosely attached cells are readily removed by wiping or gently scraping.

White patches can be grouped in a number of ways. Clinically, they can be separated depending on whether or not the lesion can be wiped away. In general, lesions which can be wiped away are due to accumulation of epithelial debris or an inflammatory exudate on the surface, as opposed to the keratoses which are resistant. Histologically, they can be divided into those which show epithelial dysplasia and those which do not (see later). They can also be grouped depending on their aetiology, and this forms the basis of their clinical differential diagnosis (Table 9.1). Carcinoma *in situ* and squamous cell carcinoma are described in Chapter 10, and white lesions of infective origin are discussed in Chapter 11.

Although the word 'leukoplakia' means 'white patch' this term is now only used to describe lesions defined by the World Health

Organization as 'a white patch or plaque that cannot be characterized clinically or histopathologically as any other disease'. This definition was modified slightly at an international symposium in 1994 to 'a predominantly white lesion of the oral mucosa that cannot be characterized as any other definable lesion'. Leukoplakia is, therefore, a clinical diagnosis arrived at by exclusion, and what is included under the term is determined by what current opinion accepts as a diagnosable disease. For example, a traumatic keratosis should not be regarded as leukoplakia since a local cause of trauma must have been identified to enable the diagnosis to be made. The classification of such lesions should then be linked to the cause, for example frictional keratosis. Similarly, although tobacco usage is an important aetiological factor in leukoplakia (see later), some white patches can be linked directly to the local effects of tobacco since they resolve when it is withdrawn and these should be described as smokers' keratosis. In both of these examples the epithelium has undergone reversible reactive changes in response to chronic irritation, and such lesions are often referred to as reactive keratoses. On removal of the cause the keratosis should resolve with time.

Table 9.1 Aetiological classification of white lesions of the oral mucosa

Hereditary	Oral epithelial naevus Oral manifestation of other rare genodermatoses (see Box 9.1) Leukoedema
Traumatic	Mechanical (frictional keratosis) Chemical Thermal
Infective	Candidosis – acute pseudomembranous – chronic hyperplastic – chronic mucocutaneous Syphilitic leukoplakia Hairy leukoplakia
Idiopathic	Leukoplakia
Dermatological	Lichen planus Lupus erythematosus
Neoplastic	Carcinoma <i>in situ</i> Squamous cell carcinoma

Key points – Keratoses

- increased and/or abnormal keratin production
- not removed by scraping
- classified on basis of aetiology

Definition of histopathological terms

The following terms are used in this chapter to describe some of the histological changes which may occur in squamous epithelium, particularly in relation to white patches.

- Orthokeratosis – the superficial cell layers (squames) of the epithelium are flattened, anucleate, and have homogeneous, eosinophilic cytoplasm.
- Parakeratosis – the superficial cell layers of the epithelium are again flattened and eosinophilic, but contain pyknotic nuclei.
- Hyperkeratosis – increased thickness of the keratin layer.
- Hyperparakeratosis – increased thickness of the parakeratin.
- Acanthosis – a type of epithelial hyperplasia in which the increased thickness is due to an increased number of cells in the prickle cell layers, producing broadening and lengthening of the rete ridges.
- Epithelial atrophy – thinning of the epithelium, usually associated with loss of rete ridges.
- Cellular atypia – a group of cellular changes which cytologically characterize epithelial dysplasia and which are typically seen in premalignant lesions.
- Epithelial dysplasia – a term applied to describe epithelium when features of cellular atypia are present. Atypia refers to cells; dysplasia is used when referring to the tissue.

Hereditary conditions

A number of hereditary disorders of skin and of mucosae covered by squamous epithelium are characterized by disturbances of keratinization. Hereditary patterns are well established in most of these diseases which are sometimes termed 'genokeratoses' or 'genodermatoses'. In general, they are rare and oral involvement in some may be absent or inconspicuous. The oral epithelial naevus is the main disorder affecting oral mucosa.

Oral epithelial naevus (white sponge naevus)

This hereditary disorder is transmitted as an autosomal dominant but with incomplete penetrance and variable expressivity. Any part of the oral mucosa may be involved (Fig. 9.1), and clinically the edges of the lesion are not well defined but gradually merge with the normal mucosa. The superficial layers of the epithelium are soft and of uneven thickness, producing a shaggy or folded surface. Other mucosal surfaces, for example the nose, oesophagus, and anogenital region, may also be involved. The oral mucosal lesions may be apparent in infancy or early childhood, or may not become evident until adolescence. Histologically, the epithelium is acanthotic and the surface shows marked hyperparakeratosis (Fig. 9.2). A characteristic feature is marked intra-

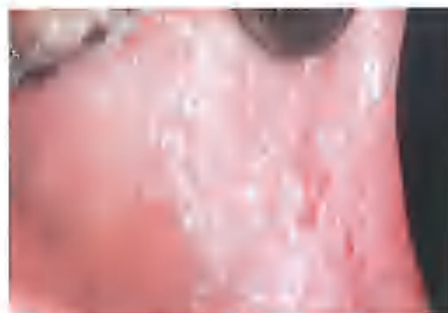

Fig. 9.1 Oral epithelial naevus affecting buccal mucosa. The other cheek was similarly affected.

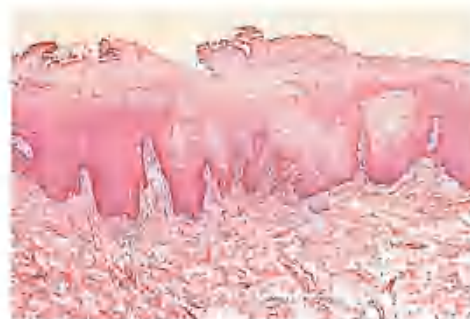


Fig. 9.2 Oral epithelial naevus.

cellular oedema of the prickle and parakeratinized cell layers. Only the cell walls and the pyknotic nuclei in the centres of the cells are visible, thus giving a so-called basketweave appearance. There are no inflammatory changes in the lamina propria and there is no cellular atypia. The oral epithelial naevus is not a premalignant lesion.

Mutations in the genes coding for keratins 4 and 13 (the pair of keratins expressed by epithelial cells in the mucosae affected by the disorder) have been identified, suggesting the disorder is due to keratin defects. The heaping-up of the cells on the surface also suggests the possibility of some abnormality of the normal desquamation process.

Other genodermatoses

The oral mucosa may be involved to a greater or lesser extent in a variety of other genodermatoses, all of which are rare (see Box 9.1).

Leukoedema

This condition is particularly evident in persons with racial pigmentation of the oral mucosa, and presents as a translucent, milky whiteness of the surface of the mucosa with a slightly folded appearance. Histologically, the epithelium is thicker than normal with broad rete ridges, and the cells in the superficial part of the prickle cell layer appear vacuolated and contain considerable quantities of glycogen. Local irritation has been suggested, but ethnic and racial clustering suggest hereditary factors, and leukoedema is best regarded as a variation of normal.

Box 9.1 Genodermatoses

Pachyonychia congenita	Autosomal dominant; gross thickening of the nails; oral white lesions may be seen on tongue/buccal mucosa; histologically resembles oral epithelial naevus
Dyskeratosis congenita	Mode of inheritance unclear; mainly affects males; skin pigmentation, dystrophic nails, hyperkeratosis of mucosae including mouth; severe gingivitis/periodontal destruction in childhood also seen; hyperkeratotic lesions potentially premalignant
Tylosis	Autosomal dominant; hyperkeratosis palms and soles (tylosis); predisposes to oesophageal carcinoma; oral hyperkeratosis may be seen
Hereditary benign intraepithelial dyskeratosis	Autosomal dominant; occurs mainly in a rare racial isolate in US; clinically resembles oral epithelial naevus; epithelium includes cells showing premature keratinization (dyskeratosis)
Follicular keratosis (Darier's disease)	Autosomal dominant, occasionally sporadic; keratotic coalescing papules skin, e.g. forehead, scalp; oral lesions in about 50 per cent, white coalescing papules, mainly hard palate/gingiva; intraepithelial acantholytic clefts with dyskeratotic cells

Traumatic keratoses

Mechanical trauma – frictional keratosis

The oral mucosa reacts to mechanical trauma in one of two ways: acute trauma leads to ulceration while chronic frictional irritation leads to epithelial thickening and hyperkeratinization. Irritants such as a sharp tooth, cheek biting, and the prolonged wearing of often ill-fitting dentures are examples of causes of chronic friction. The lesions produced are referred to as frictional keratoses and may in time become dense and white, and show a roughened surface (Figs 9.3, 9.4). To diagnose frictional keratosis a source of chronic irritation must be identified which fits the size and shape

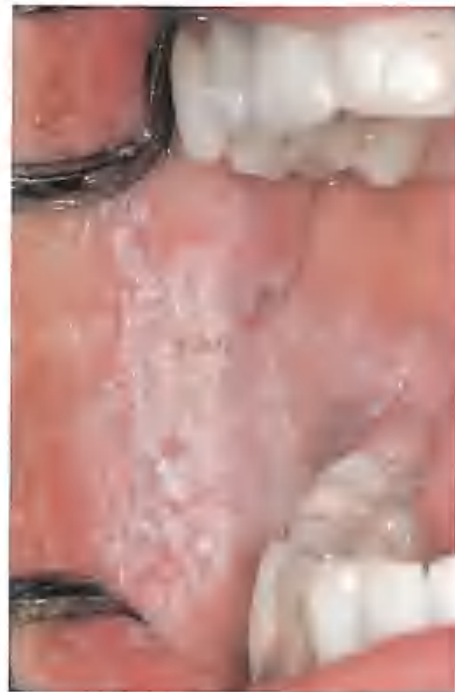

Fig. 9.3 Hyperkeratosis associated with habitual cheek chewing.

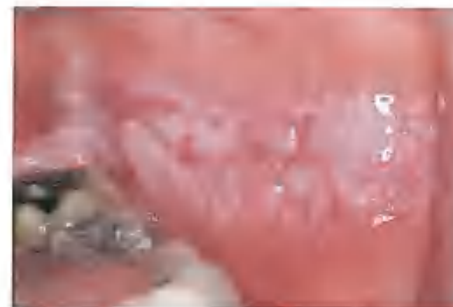

Fig. 9.4 Frictional keratosis related to the occlusal line.

of the lesion, and the lesion must resolve when the source of irritation is removed (cf. chronic traumatic ulcer). Histologically, frictional keratoses show hyperkeratosis which may be accompanied by some acanthosis but there is no dysplasia (Fig. 9.5). The lesion is innocent and is analogous to the callus on the hand of a manual worker.

Chemical trauma

Chemical insult to the oral mucosa may produce a variety of reactions depending on the severity of the insult and its duration. A severe insult such as that produced by the topical use of aspirin (aspirin burn) is likely to produce epithelial necrosis, sloughing, and ulceration (Fig. 9.6), while a low-grade, chronic insult may result in hyperkeratosis.

Chronic chemical insult to the mucosa is seen in patients who use tobacco, whether it is smoked, chewed, or used as snuff, and in those with other chewing habits such as betel nut. These habits

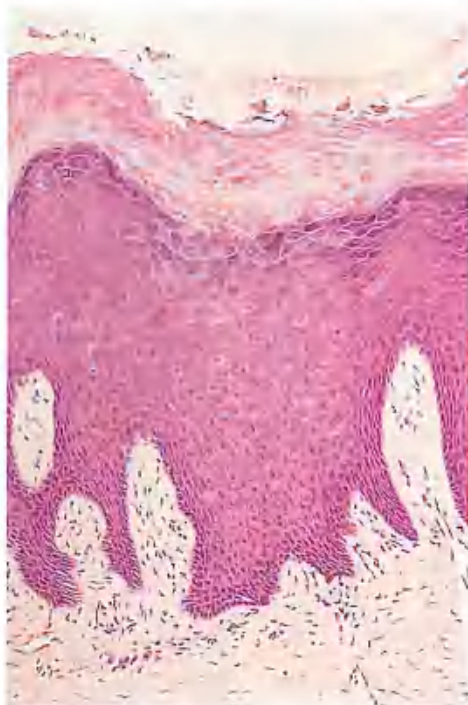

Fig. 9.5 Frictional keratosis showing hyperkeratosis and acanthosis.

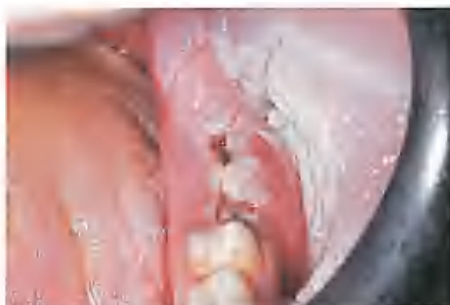

Fig. 9.6 Aspirin burn showing a range of mucosal reactions from oedema to necrosis and sloughing.

produce epithelial thickening and hyperkeratosis in a similar manner to chronic friction.

Thermal trauma

Regular smokers of cigarettes, cigars, and pipes often develop white plaques on their oral mucosa, particularly the anterior parts of the buccal mucosa, tongue, and palate. It is likely that both thermal and chemical factors are involved in the development of these hyperkeratotic lesions. Smokers who constantly dangle a cigarette from the lips may develop a localized keratosis at that site (Fig. 9.7), and similar lesions may occur in pipe smokers on the dorsum of the tongue or palate where the hot smoke constantly impinges, particularly if the pipe has a favoured position.

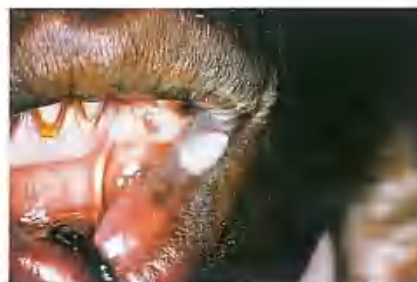

Fig. 9.7 Hyperkeratosis of lip localised to where patient habitually holds cigarette.

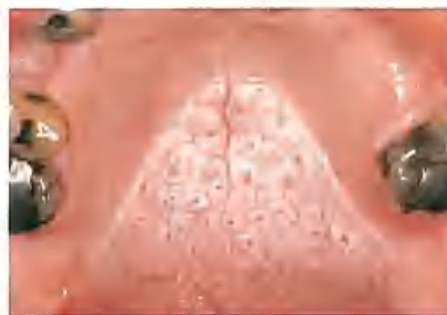

Fig. 9.8 Stomatitis nicotina of the palate in a partial denture wearer. Note, lesion only involves exposed mucosa.

Key points – Traumatic keratoses

- reaction to local causes
- reversible if cause removed

Nicotinic stomatitis of the palate is a characteristic clinical condition which may develop in association with any type of smoking, but particularly in pipe smokers. In early lesions the palatal mucosa is greyish-white with scattered red spots representing the orifices of minor salivary gland ducts. In more advanced lesions there are tessellated patches of rough white epithelium with red, umbilicated duct orifices (Fig. 9.8). Histological examination shows hyperkeratosis and acanthosis of the palatal epithelium and keratin plugs in some of the duct orifices associated with mild periductal chronic inflammation. The condition is usually reversible if smoking is stopped and is not considered to be a precancerous lesion. However, the condition does indicate that potential carcinogens are operating in the mouth and the whole of the mucosa must be carefully examined. In general, a patient with a white patch anywhere on the oral mucosa has a much greater risk of developing oral cancer than a patient without such a lesion, but this does not imply that the malignant disease always develops within the initial white patch.

Leukoplakia

Leukoplakia is currently defined as a predominantly white lesion of the oral mucosa that cannot be characterized as any other

definable lesion. This rather negative definition highlights the fact that the diagnosis of leukoplakia is one of exclusion. The definition may well be revised in the future as new knowledge accumulates.

Although leukoplakia is a clinical diagnosis which implies no particular histological change or behaviour, there is no doubt that a small percentage of leukoplakias are premalignant and some may be invasive carcinomas at presentation. It is impossible to predict which lesions are likely to become malignant, but certain clinical and histological features are recognized as being associated with an increased risk.

Incidence

The reported prevalence of oral leukoplakia in unselected populations in different parts of the world varies from less than 1 per cent to over 10 per cent, but difficulties in the standardization of diagnostic criteria make comparison of the prevalence in different areas somewhat problematical. Studies in Western Europe and North America some years ago showed that oral leukoplakia occurred predominantly in men, but recent studies show that now almost as many women in these countries are affected. This probably reflects changes in smoking habits. Leukoplakia is generally described as occurring in older people, but recent studies show that the incidence in younger adults is increasing. Leukoplakia may occur anywhere on the oral mucosa, but in Western Europe and North America, the floor of the mouth and buccal mucosa are now regarded as being the most common sites affected. However, marked variations in the incidence, sex, and age-group affected and site of leukoplakia occur between different ethnic and cultural groups, reflecting variations in possible aetiological factors such as smoking and chewing habits. Leukoplakias involving the ventral tongue and/or floor of the mouth (sublingual keratosis) have a higher risk of malignant transformation than lesions at other sites.

Clinical features

Leukoplakia may vary from a quite small and circumscribed plaque to an extensive lesion involving a large area of mucosa. Lesions may be white, whitish-yellow, or grey and may have a homogeneous or non-homogeneous surface. Homogeneous leukoplakias are usually plaque-like but some variation in the surface is allowed (Fig. 9.9). Some are smooth but others may be wrinkled or the surface may be criss-crossed by small cracks or fissures produc-

Key points – Clinical features of leukoplakia

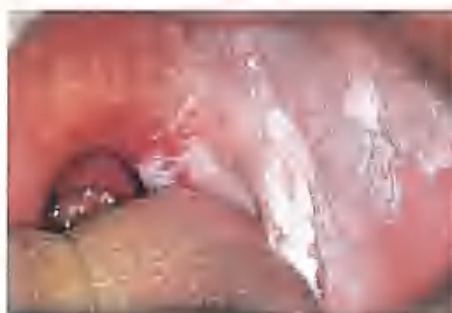
- homogeneous
 - flat, uniform, predominantly white plaques
 - may show shallow cracks/fissures
- non-homogeneous
 - irregular nodular/thickened surface
 - often speckled with areas of erythroplakia
- non-homogeneous lesions have a worse prognosis

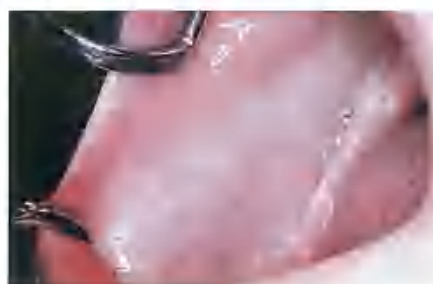
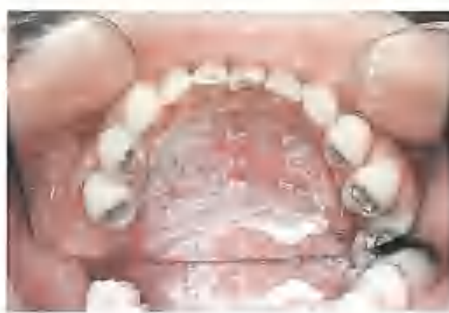
Fig. 9.9 Homogeneous leukoplakia.

ing a tessellated appearance. In contrast, non-homogeneous leukoplakias may show areas of redness, producing a speckled appearance, ulceration, nodular thickening, or heaping-up of the surface (Figs 9.10, 9.11). In some cases the lesions may take on a distinctly warty appearance, described as verrucous leukoplakia. Speckling is due to the association of leukoplakia with erythroplakia.

Erythroplakia is defined as a bright-red velvety plaque on the oral mucosa which cannot be categorized clinically or pathologically as being due to any other condition (Fig. 9.12). Erythroplakic lesions may be homogeneous with a well-defined but irregular outline, or may be intermingled with patches of leukoplakia – such lesions are often called speckled leukoplakias or erythroleukoplakia. Histologically, erythroplakia may represent carcinoma *in situ* or even invasive carcinoma (see Chapter 10). Its development in a previously uniform white lesion is, therefore, an important clinical sign that may indicate sinister change. Fixation, induration, ulceration, lymphadenopathy, and bone destruction if the lesion overlies bone are other clinical features that may indicate malignant change in a leukoplakic or erythroplakic patch.



Figs 9.10 and 9.11 Non-homogeneous leukoplakias.

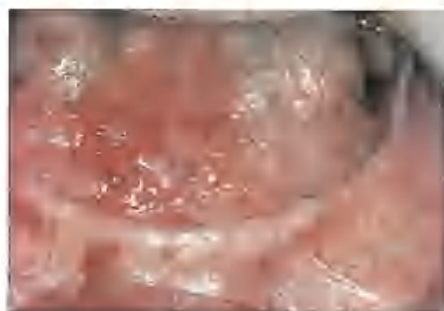

Fig. 9.12 Erythroplakia of the right floor of mouth.

Aetiological factors

The aetiology of idiopathic oral leukoplakia is by definition unknown, but in some patients predisposing factors can be identified that are associated with the development of other white lesions or in the aetiology of squamous cell carcinoma (see Chapter 10). However, that does not imply that they are causative. The following factors may be important.

Tobacco

Tobacco usage is probably the most common aetiological factor in patients with leukoplakia, the tobacco being either smoked or chewed. Studies from different countries have shown a higher prevalence of leukoplakia among smokers than non-smokers and that the prevalence increases with the amount of tobacco use. Any part of the mucosa may be involved and the distribution of the lesions may vary with the particular type of habit. In cigarette smokers the lesion may be diffuse and seen on the cheeks, lips, tongue, and less frequently the floor of the mouth. In India, bidi smoking, a type of cigarette made with a locally grown tobacco, typically produces lesions at the labial commissure. Reverse smoking, in which the glowing end of the cigarette is held inside the mouth, is practised in some parts of the world and is associated with diverse changes including white patches, red areas, and ulceration.

In many parts of the world the use of smokeless tobacco is also prevalent and is associated with oral keratosis. Tobacco chewing is widely practised in Asia, where it is frequently combined with betel nut and lime and wrapped in a betel leaf to form a small parcel, a pan (see Chapter 10). This is usually kept in the area of the lower buccal sulcus close to the molars and produces lesions on the buccal mucosa. Tobacco chewing is also practised by coal miners as a substitute for smoking in the underground conditions where smoking would be dangerous.

Snuff dipping is a similar habit seen particularly in Scandinavia and parts of the USA and involves the use of a wet snuff which is placed in the buccal sulcus. In some countries snuff may also be purchased in small sachets designed to be held in the mouth.

In those patients whose tobacco-associated keratosis regresses on cessation of the habit the lesion should not be classified as leukoplakia.

Alcohol

There is no clear evidence to show the importance of alcohol in the aetiology of leukoplakia (cf. oral squamous cell carcinoma), but it is likely that it does have some part to play. Many heavy smokers are also heavy drinkers.

Candida

As discussed in Chapter 11, candidal hyphae can be demonstrated in biopsies of chronic hyperplastic candidosis (candidal leukoplakia), but are occasionally found in association with idiopathic leukoplakia. Doubts still remain as to whether such candidal infection is a cause of leukoplakia or a superimposed infection. Although candida plays a causal role in chronic hyperplastic candidosis, the organism thrives particularly well in altered tissues and this may be why it is occasionally seen in other keratoses.

Viruses

Many studies have shown that human papilloma viruses (HPV) can be detected in oral leukoplakia, including types 16 and 18 which are regarded as high-risk types because of their association with carcinoma of the uterine cervix. However, HPV 16 and HPV 18 may also be found in a proportion of healthy oral mucosa and their role in the pathogenesis of leukoplakia is uncertain.

Note that so-called 'hairy leukoplakia' seen in some immunocompromised patients (see Chapter 11) is associated with infection with the Epstein-Barr virus. However, since this lesion has a recognizable cause it should not be classified as leukoplakia, but nevertheless the term 'hairy leukoplakia' is now entrenched in the literature. The lesion has no premalignant potential.

Oral epithelial atrophy

There is a tendency for leukoplakia to develop in atrophic epithelium. Conditions which predispose to epithelial atrophy and leukoplakia include iron deficiency, oral submucous fibrosis, tertiary syphilis, and possibly some vitamin deficiencies. Sideropenic dysphagia (Patterson-Kelly or Plummer-Vinson syndrome) is associated particularly with postcricoid carcinoma but may also be associated with oral leukoplakia and oral squamous cell carcinoma.

Tumour-suppressor genes

Tumour-suppressor genes are involved in regulation of the normal cell-proliferation cycle. One of the best known is the p53 gene located on chromosome 17p. Mutation of the gene can result in inactivation of the normal suppressor activity of the p53 protein leading to uncontrolled cell proliferation. Abnormalities of the p53 gene have been identified in a wide range of malignancies, including oral cancer (see Chapter 10) and in some leukoplakias.

Key points – Oral leukoplakia

- aetiology likely to be multifactorial
- tobacco use is a major factor

particularly those showing dysplasia (see below) and those associated with heavy smoking and drinking. A variety of other genetic abnormalities have also been detected involving areas of the genome thought to harbour other tumour-suppressor genes. It is likely that the pattern and timing of these genetic changes are the key to understanding the progression from normal mucosa to dysplasia and invasive squamous cell carcinoma. They are discussed more fully in Chapter 10.

Pathology, epithelial dysplasia

There is a wide range in the histological appearances of oral leukoplakia which reflect varying degrees of keratinization, epithelial thickness, epithelial dysplasia, and chronic inflammatory cell infiltration in the lamina propria. However, it must be appreciated that leukoplakia is a clinical diagnosis arrived at after the exclusion of other diseases and is not based on any specific histopathological features. The term leukoplakia has no histological connotation.

The hyperkeratosis may be due to orthokeratosis, parakeratosis, or a mixture of both, and may vary in thickness. Orthokeratin is generally associated with a prominent granular cell layer (Fig. 9.13). The epithelium may be hyperplastic or atrophic (Fig. 9.14), areas of erythroplakia often being associated with epithelial atrophy. The junction between the abnormal and normal epithelium at the edge of the lesion may be abrupt, or there may be a gradual transition from one to the other. In some cases, melanin pigment may be present both in the basal epithelial cells

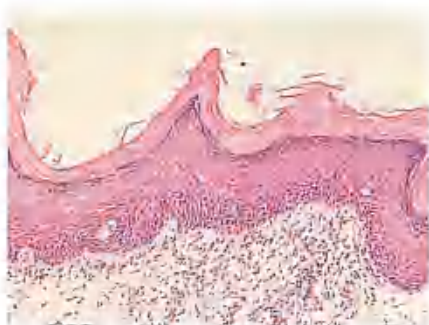


Fig. 9.13 Hyperorthokeratosis with chevron pattern often related to tobacco smoking.

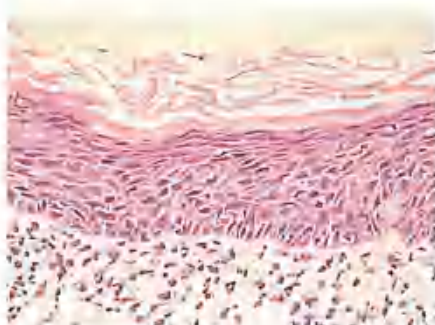


Fig. 9.14 Atrophic hyperkeratotic and dysplastic epithelium.

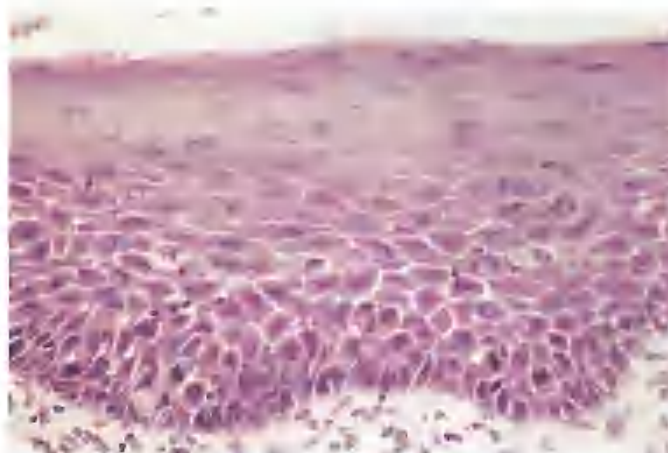


Fig. 9.15 Epithelial dysplasia involving the lower third of the epithelium showing pleomorphism, suprabasal mitoses, and loss of ordered stratification.

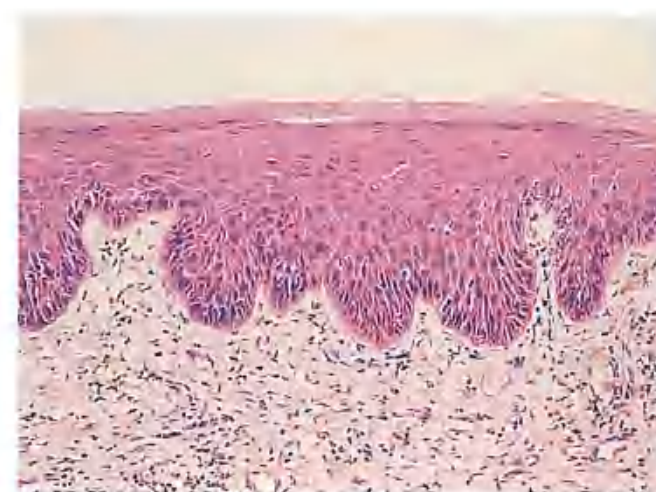


Fig. 9.16 Epithelial dysplasia showing basal cell hyperplasia and drop-shaped rete pegs.

and in macrophages in the lamina propria as a result of leakage of melanin from basal cells (melanin incontinence). Melanin pigmentation accounts for the grey colour of some leukoplakias. The presence of chevron peaks in the keratin (Fig. 9.13) and of melanin pigment incontinence in the lamina propria is highly suggestive of smoking as an important aetiological factor.

In some cases, hyperkeratosis and variation in epithelial thickness are the only epithelial abnormalities but other leukoplakias show features of epithelial dysplasia (Figs 9.15–9.18). The individual cellular changes (cellular atypia) seen in dysplastic epithelium reflect abnormalities in proliferation, maturation, and differentiation of epithelial cells. The histopathological features that may be seen in epithelial dysplasia are listed in Table 9.2. The first seven reflect mainly abnormalities in cell proliferation

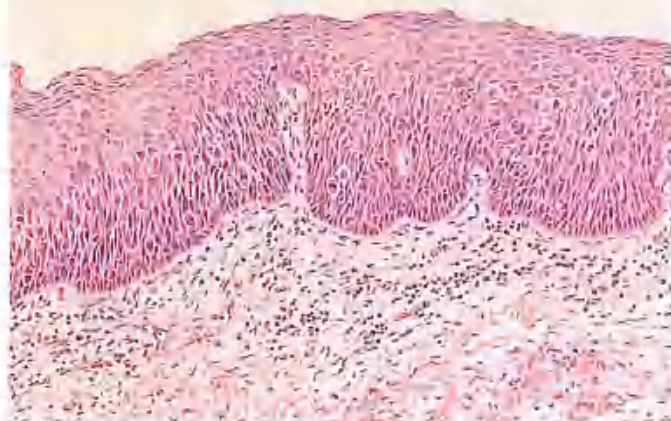


Fig. 9.17 Moderate/severe epithelial dysplasia involving about two-thirds of the epithelium.

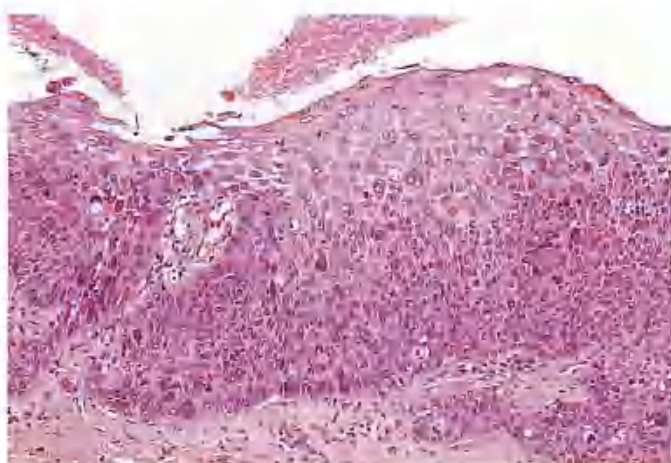


Fig. 9.18 Severe epithelial dysplasia showing marked cellular atypia and disturbed maturation of the epithelium.

whilst the last four relate mainly to abnormalities of maturation and differentiation of epithelial cells.

Not all of these changes are seen in any one case, and cellular atypia of a minor degree may be seen in reaction to inflammation in conditions such as lichen planus and candidosis (reactive cellular atypia). Although it is not possible to predict the presence and severity of dysplasia from the clinical appearances of the lesion, erythroplakias and non-homogeneous leukoplakias are much more likely to be dysplastic (or even invasive carcinoma) than homogeneous leukoplakias. Several studies have demonstrated that only about 10 per cent of homogeneous leukoplakias are dysplastic as opposed to 50 per cent or more of non-homogeneous types. Speckled leukoplakias, in particular, show a very high incidence of dysplasia, which approaches 100 per cent as the extent of the speckling increases and the clinical features more closely

Table 9.2 Histopathological features of epithelial dysplasia

1. Increased and abnormal mitoses. Mitoses may be increased in number, occur higher up in the epithelium than is usual (i.e. away from the basal layer – suprabasal mitoses), or have an abnormal form (for example triradiate mitoses).
2. Basal cell hyperplasia. The presence of several layers of cells of basaloid appearance. It is often associated with drop-shaped rete pegs.
3. Drop-shaped rete pegs. The rete pegs are wider at their deepest part than they are more superficially.
4. Disturbed polarity of the basal cells or loss of cellular orientation. The cells in the basal layer have no definable long axis and the nuclei have no regular polarity.
5. Alteration (invariably an increase) is seen in the nuclear/cytoplasmic ratio by either area or volume.
6. Nuclear hyperchromatism. Nuclear staining which is abnormally intense.
7. Prominent and enlarged nucleoli.
8. Irregular epithelial stratification or disturbed maturation. The cells no longer show a proper sequence of morphological and maturational changes as they pass from the basal layer to the surface.
9. Nuclear and cellular pleomorphism. Nuclei and cells are of different size and shape.
10. Abnormal keratinization. Keratinization occurring below the normal keratin layer, either as individual cell keratinization within the stratum spinosum or as disturbed maturation of groups of cells resulting in the formation of intraepithelial keratin pearls.
11. Loss or reduction of intercellular adhesion (or cohesion). This may be difficult to distinguish from intercellular oedema.

Key points – Leukoplakia

- it is a clinical diagnosis
- it has no histological connotation
- epithelial dysplasia may or may not be present
- epithelial dysplasia reflects abnormalities in proliferation, maturation, and differentiation of epithelial cells
- non-homogeneous types are more likely to be dysplastic
- the severity of dysplasia is assessed subjectively

resemble erythroplakia. Attempts to give a numerical score to the severity of dysplasia in the hope that it would correlate with prognosis have proven unsuccessful, and so the degree of dysplasia is usually subjectively assessed using terms such as mild, moderate, and severe.

Prognosis

Leukoplakia has an unpredictable tendency to undergo malignant transformation. There is a marked variation in the reported malig-

Key points – Prognosis of oral leukoplakia

- a proportion undergo malignant transformation
- transformation times vary from one to several years
- dysplastic lesions carry an increased risk of malignant transformation
- malignant transformation likely to be due to progressive accumulation of genetic changes over time
- the potential for malignant transformation is greater in high-risk sites

nant transformation rates in studies from different areas of the world, ranging in most cases from 0.3 per cent to 18 per cent over prolonged periods. This wide range is likely to be due to many factors including differences in diagnostic criteria and in aetiological factors, such as smoking, other habits, and nutritional status, between different countries and also between different cultural groups within a country. Despite these problems, by combining the results from several studies, a rate of about 14 per cent over a period of up to 20 years has been reported. A malignant transformation rate in Western Europe of 4 per cent over 10 years is likely to be a reasonable estimate. In Denmark, an annual incidence of malignant transformation of 0.75 per cent has been reported which is consistent with the long-term transformation rate.

Although the rate of malignant transformation is variable, the ventral tongue, floor of the mouth, and the lingual aspect of the lower alveolar mucosa are high-risk sites. Lesions in these areas are often designated as sublingual keratosis to draw attention to the importance of site. Studies in the United Kingdom and in America have shown about 25 per cent of such lesions are invasive squamous cell carcinoma when first biopsied (see Fig. 10.8) and that about a further 25 per cent will subsequently develop carcinoma when followed up over varying periods of time.

It is generally accepted that a leukoplakia showing epithelial dysplasia is more likely to become malignant than one not showing epithelial dysplasia, and that the more severe the features of epithelial dysplasia, the greater the risk of malignant transformation. Transformation rates for dysplastic leukoplakias range from less than 10 per cent to over 30 per cent in different studies. However, several series have shown that the majority of dysplastic leukoplakias remain unchanged during the observation period and that a proportion will improve or regress. There is no clear correlation, therefore, between histological appearances and clinical behaviour. This is particularly relevant to sublingual keratoses where importance must be attached to even mild dysplasia. Speckled and other non-homogeneous types of leukoplakia also have an increased rate of malignant transformation compared to homogeneous lesions, which presumably reflects the higher incidence of dysplasia in non-homogeneous leukoplakias. Speckled leukoplakias associated with candidal infection (candidal leuko-

Box 9.1 DNA content in leukoplakia

- The DNA content of cells is related to the number of chromosomes they contain.
- Normal cells have two copies of each chromosome, i.e. they are diploid.
- Malignant and premalignant epithelial cells may have abnormal numbers of chromosomes because of deletions and/or mutation in genes controlling DNA replication and mitosis.
- Reduplication of chromosomes prior to mitosis leads to polyploidy, e.g. tetraploid cells.
- Abnormalities of segregation of chromosomes at mitosis leads to cells with wide variations in chromosome numbers, i.e. they are aneuploid.
- Although only a few studies have been undertaken the findings are summarized below. More studies are required to confirm these observations.
- Leukoplakias which are aneuploid are high-risk lesions; the majority progress to carcinoma (over 80 per cent in one study).
- Leukoplakias which are diploid are low-risk lesions; the minority progress to carcinoma (less than 5 per cent in one study).
- Leukoplakias which are tetraploid are intermediate-risk lesions (about 50 per cent progressed to carcinoma in one study).

plakias, see Chapter 11) also have a high incidence of dysplasia and about 30 per cent of patients with such lesions may develop oral carcinoma on follow-up.

As discussed previously, erythroplakia, whether as part of a speckled leukoplakia or as a separate lesion, is an important and serious condition and one of the most common manifestations of early malignant change. Biopsy studies have shown that about half of such lesions are invasive carcinoma or carcinoma *in situ* on initial biopsy and that the great majority of those remaining show severe dysplasia.

Although it is assumed that the risk of developing carcinoma increases as the severity of dysplasia increases, there are no reliable methods to predict the behaviour of premalignant lesions. Considerable research is currently directed towards the identification of prognostic markers, involving study of genetic alterations, oncogene and tumour suppressor gene activities, and abnormalities in the control of the cell cycle. At present, most of these techniques are research tools and no reliable prognostic indicator has been identified. However, recent studies have shown that those leukoplakias where the epithelial cells have abnormal DNA content are more likely to undergo malignant transformation (see Box 9.1).

Measurement of the DNA content of cells in a biopsy of oral leukoplakia may become an important prognostic indicator in the future but, for the present, the assessment of risk of malignant change is still based on consideration of the size, site, and clinical appearances of the lesion, together with an assessment (albeit subjective) of the degree of epithelial dysplasia on histological examination.

Dermatological causes of white patches

A number of primarily dermatological diseases in addition to the genodermatoses have oral lesions which may present as white patches. Lichen planus is by far the commonest, but it is convenient here to include lupus erythematosus since, clinically and histologically, the chronic discoid type may mimic lichen planus. The other diseases are very rare and beyond the scope of this book.

Lichen planus

This relatively common disease, the prevalence of which varies from about 0.5 to 2 per cent in the general population, has a worldwide distribution and involves the skin and mucous membranes. The majority of patients are between 30 and 50 years of age and about 60 per cent are women. Oral lesions can be detected in approximately 50 per cent of patients who initially present with skin lesions, but the prevalence of skin lesions in patients who are primarily seen for oral lichen planus is lower and ranges from about 10 to 50 per cent in reported series. Oral lesions may occur before, at the same time as, or after skin lesions.

Clinical features

The characteristic skin lesion is a violaceous, itchy papule which may have distinctive white streaks on the surface (Wickham's striae). The papules may have a variable pattern, discrete, linear, annular, or widespread rashes being described. Almost any area of skin may be involved, but the flexor surface of the wrist is the commonest site. Fingernails are involved in up to 10 per cent of patients, vertical ridges being the usual abnormality. The skin lesions develop slowly and 85 per cent resolve within 18 months, although recurrences are not uncommon. In contrast, oral lichen planus pursues a much more chronic course, in some patients extending over several years.

In patients with oral lichen planus the buccal mucosa is involved in the great majority of cases while the tongue, gingiva, palate, and lips may also be affected. Involvement of the floor of the mouth is very uncommon. Lesions are generally bilateral and a wide spectrum of clinical presentations may occur, alone or in various combinations (Table 9.3). The reticular, plaque-like, and papular patterns (Fig. 9.19) are usually symptom-free, in contrast to the atrophic/erosive types which often occur together (Fig. 9.20). The mucosa in the atrophic/erosive forms has a red and glazed appearance with areas of superficial ulceration of varying extent which may take several weeks to heal. Occa-

Table 9.3 Clinical types of lichen planus listed in order of frequency of involvement of the oral mucosa

Reticular	– lace-like striae
Atrophic	– diffuse red lesions resembling erythroplakia
Plaque-like	– white plaques resembling leukoplakia
Papular	– small white papules that may coalesce
Erosive	– extensive areas of shallow ulceration
Bullous	– subepithelial bullae

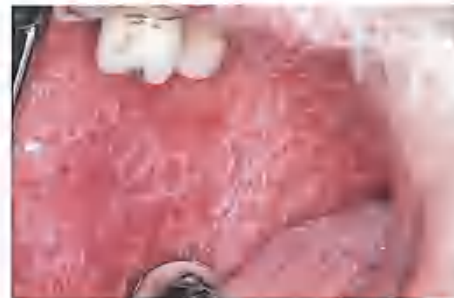

Fig. 9.19 Lichen planus – reticular pattern.

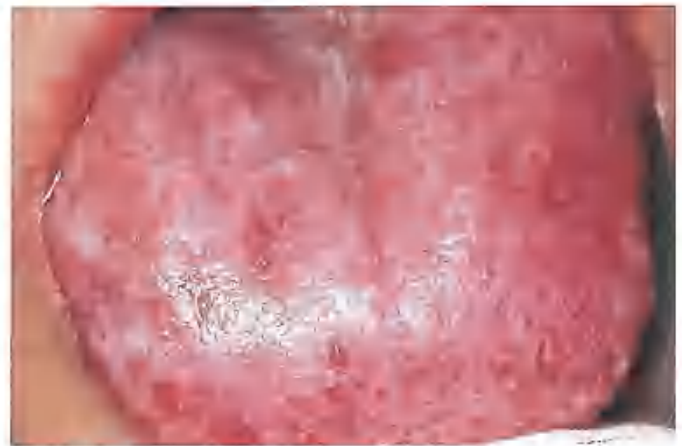


Fig. 9.20 Atrophic/erosive lichen planus.

sionally, they are preceded by bullae (bullous lichen planus). Erosive lesions are often associated with typical areas of non-erosive lichen planus round the edges of the lesions. Pain and discomfort may be considerable and severe, intractable ulceration is very occasionally seen.

Lichen planus involving the gingiva often presents as a desquamative gingivitis (see Chapter 7 and Fig. 7.15). In some patients, more typical non-erosive lesions of lichen planus can usually be found elsewhere on the oral mucosa.

Pathology

In oral lichen planus the epithelium may be ortho- or parakeratinized and it varies considerably in thickness. It may be atrophic



Fig. 9.21 Lichen planus with irregular acanthosis and dense subepithelial lymphocytic infiltration.

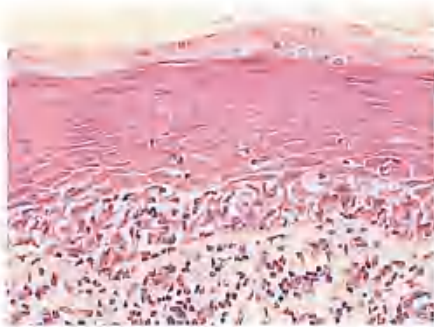


Fig. 9.22 Liquefactive degeneration of basal cells in lichen planus.

or acanthotic, the latter usually resulting in irregular elongation and widening of the rete processes, although a sawtooth pattern, classically described in skin lesions, may be seen (Fig. 9.21). There is a dense, well-defined band of underlying mononuclear inflammatory cell infiltration, consisting mainly of T lymphocytes (Fig. 9.21). Plasma cells are absent or inconspicuous. A characteristic finding is degeneration of basal cells associated with oedema and lymphocytic infiltration of the basal region of the epithelium, described as liquefactive degeneration of basal cells (Fig. 9.22). The degenerating cells appear as hyaline, shrunken/condensed bodies (Civatte bodies) and represent basal cells undergoing apoptosis. In some cases, a lack of cohesion between epithelium and the lamina propria as a result of basal cell degeneration and oedema may result in the formation of subepithelial bullae (blisters). Once ulceration has occurred there is a non-specific

Key points – Oral lichen planus

- may occur alone or in association with skin lesions
- more common in women than in men
- mucosal lesions are usually bilateral
- non-erosive forms may be symptomless
- buccal mucosa is commonest site
- gingival lesions may present as desquamative gingivitis

Key points – Lichen planus histopathology

- ortho- or parakeratinized surface
- acanthotic or atrophic epithelium
- subepithelial band of T lymphocytes
- liquefactive degeneration of basal cells

inflammatory response which makes histological diagnosis more difficult.

Almost all cases of oral lichen planus run a benign course, but malignant transformation has been described in a very small proportion. Some studies have suggested that the atrophic/erosive forms are more likely to undergo such change because of the decreased barrier presented to potential carcinogens. In contrast, others have found malignant transformation to be associated mainly with plaque lesions. There is considerable variation in the reported transformation rates, although in most studies it ranges from about 0.5 to 2.5 per cent over a 5-year period.

Aetiology and pathogenesis

The aetiology and pathogenesis of lichen planus are not fully understood but it is widely accepted that cell-mediated immune responses to an external antigen, or to internal antigenic changes in the epithelial cells, are involved (see Box 9.2). In most cases the precipitating factors are unknown and the disease is idiopathic. However, in some patients lichen planus is triggered by hypersensitivity to drugs or to dental materials, most often amalgam where hypersensitivity to mercuric salts has been implicated (Fig. 9.23). In such cases the condition usually resolves on withdrawal of the offending drug or use of an alternative dental material. Such lesions are often referred to as lichenoid reactions to distinguish them from idiopathic lichen planus, although

Box 9.2 Possible immunological mechanism in lichen planus

- External antigenic challenge and/or modified antigenic structure of epithelial cells induces cytokine release from Langerhans cells and keratinocytes.
- The cytokines are chemotactic to T cells and also induce the epithelial cells to express adhesion molecules, particularly intercellular adhesion molecule-1 (ICAM-1).
- Thus emigrating T cells are attracted to, and accumulate in, the basement membrane zone and basal epithelial strata.
- The infiltrate includes CD4 (helper) and CD8 (cytotoxic/suppressor) lymphocytes.
- The majority of the intraepithelial T cells are CD8 lymphocytes and their activation may be responsible for the characteristic damage to basal cells.

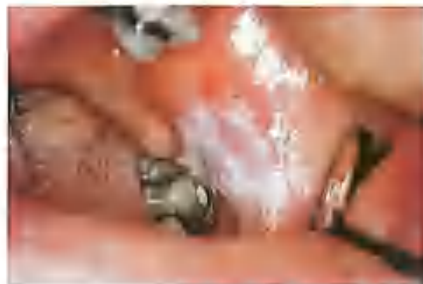

Fig. 9.23 Lichenoid reaction related to corroded amalgam restorations in a patient with hypersensitivity to mercuric salts. This lesion probably also has a frictional component.

Key points – Pathogenesis of lichen planus

- T cell mediated
- resembles type-IV hypersensitivity
- cytotoxic (CD8) lymphocytes damage basal epithelium

clinically and histologically they are essentially similar. Lichen planus has also been associated with a variety of systemic diseases, although in many a cause-and-effect relationship has not been established and the systemic disorder may merely exacerbate a pre-existing lesion. However, there is strong evidence of an association in some patients with chronic liver disease associated with hepatitis C virus infection.

Oral and cutaneous lesions are also seen as part of a graft-versus-host reaction in patients who have received bone marrow transplants. In such cases the transplanted T lymphocytes are reacting to antigens on the host epithelial cells, which they regard as 'foreign'. This lends support to the idea that immune-mediated cell damage is involved in lichen planus.

Lupus erythematosus

Two main forms of this disease are recognized: chronic discoid lupus erythematosus, which is a localized disease, and systemic lupus erythematosus, which is a disseminated disease involving almost every organ of the body. A variety of autoantibodies, for example antinuclear antibodies, are present in the systemic form. Females are affected much more frequently than males.

The lesions in chronic discoid lupus erythematosus are often restricted to the skin and usually occur on the face. They present as scaly red patches which later heal with scar formation. Sometimes the skin lesions in either the discoid or systemic types have a symmetrical distribution over the nose and cheek, the so-called butterfly pattern. Oral lesions have been reported in up to 50 per cent of cases of discoid lupus erythematosus, and, although any part of the mucosa may be involved, the cheeks are most frequently affected. There is considerable variation in the type of oral lesion seen, but the most usual is a discoid area of erythema or ulceration surrounded by a white keratotic border

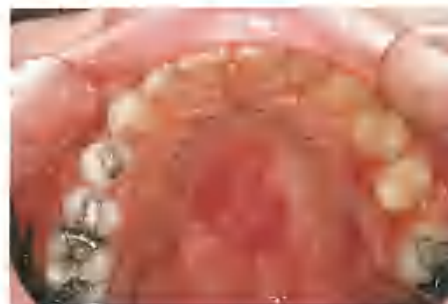

Fig. 9.24 Chronic discoid lupus erythematosus.

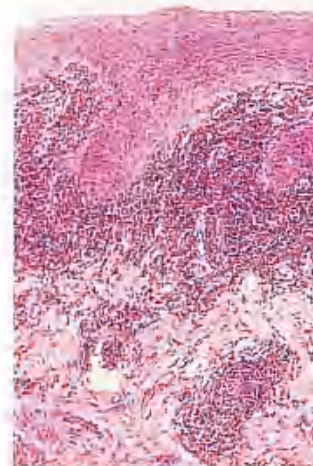


Fig. 9.25 Chronic discoid lupus erythematosus showing perivascular extension of inflammation.

Key points – Lupus erythematosus

- females affected more frequently than males
- chronic discoid (localized) form
 - facial skin may be involved
 - cheeks commonest oral site
 - discoid area of erythema with keratotic borders
- systemic form
 - skin rashes and systemic involvement
 - oral lesions variable


sometimes with radiating striae (cf. lichen planus) (Fig. 9.24). Histological examination of the oral lesions shows subepithelial and deeply situated perivascular foci of lymphocytes present in the connective tissue and there may be liquefactive degeneration of basal cells (cf. lichen planus) (Fig. 9.25). Immunofluorescent studies show abundant deposits of immunoglobulin (mainly IgG) and complement in the basement membrane zone forming a prominent 'lupus band'.

The lesions in systemic lupus erythematosus include skin rashes that typically occur on the cheeks, but oral lesions are very variable. The most commonly described are superficial erosions

and erythematous patches on the buccal mucosa. White, keratotic areas are not so frequently seen as in the discoid type. The histology of oral lesions shows a diffuse infiltration of lymphocytes and the appearances are nonspecific.

Further reading

- Axell, T., Pindborg, J. J., Smith, C. J., and van der Waal, I. (1996). Oral white lesions with special reference to precancerous and tobacco-related lesions: conclusions of an international symposium held in Uppsala, Sweden, May 18–21 1994. *Journal of Oral Pathology and Medicine*, 25, 49–54.
- Banoczy, J., Gintner, Z., and Dombi, C. (2001). Tobacco use and oral leukoplakia. *Journal of Dental Education*, 65, 322–6.
- Barnard, N. A., Scully, C., Eveson, J. W., Cunningham, S., and Porter, S. R. (1995). Oral cancer development in patients with oral lichen planus. *Journal of Oral Pathology and Medicine*, 22, 421–4.
- Bratel, J., Hakeberg, M., and Jontell, M. (1996). Effect of replacement of dental amalgam on oral lichenoid reactions. *Journal of Dentistry*, 24, 41–5.
- Eisen, D. (2002). The clinical features, malignant potential, and systemic associations of oral lichen planus: a study of 723 patients. *Journal of the American Academy of Dermatology*, 46, 207–14.
- Lumermann, H., Freedman, P., and Kerpel, S. (1995). Oral epithelial dysplasia and the development of invasive squamous cell carcinoma. *Oral Surgery, Oral Medicine, Oral Pathology, Oral Radiology and Endodontics*, 79, 321–9.
- Mattsson, U., Jontell, M., and Holmstrup, P. (2002). Oral lichen planus and malignant transformation: is a recall of patients justified? *Critical Reviews in Oral Biology and Medicine*, 13, 390–6.
- Ostman, P.-O., Anneroth, G., and Skoglund, A. (1996). Amalgam: associated oral lichenoid reactions. *Oral Surgery, Oral Medicine, Oral Pathology, Oral Radiology and Endodontics*, 81, 459–65.
- Porter, S. R., Kirby, A., Olsen, I., and Barrett, W. (1997). Immunologic aspects of dermal and oral lichen planus: a review. *Oral Surgery, Oral Medicine, Oral Pathology, Oral Radiology and Endodontics*, 83, 858–66.
- Scully, C., Beyli, M., Ferreiro, M. C., Ficarra, G., Gill, Y., Griffiths, M., et al. (1998). Update on oral lichen planus: etiopathogenesis and management. *Critical Reviews in Oral Biology and Medicine*, 9, 86–122.
- Sudbo, J., Kildal, W., Risberg, B., Koppang, H. S., Danielsen, H. E., and Reith, A. (2001). DNA content as a prognostic marker in patients with leukoplakia. *New England Journal of Medicine*, 344, 1270–8.
- van der Waal, I., Schepman, K. P., van der Meig, E. H., and Smeele, L. E. (1997). Oral leukoplakia: a clinicopathological review. *Oral Oncology*, 33, 291–301.
- Yamamoto, T., Osaki, T., Yoneda, K., and Ueta, E. (1994). Cytokine production by keratinocytes and mononuclear infiltrates in oral lichen planus. *Journal of Oral Pathology and Medicine*, 23, 309–15.



Oral epithelial tumours, melanocytic naevi, and malignant melanoma

SQUAMOUS CELL PAPILLOMA AND OTHER BENIGN LESIONS ASSOCIATED
WITH HUMAN PAPILLOMAVIRUS (HPV)

- Squamous cell papilloma
- Verruca vulgaris (common wart)
- Condyloma acuminatum (venereal wart)
- Focal epithelial hyperplasia (Heck's disease)

SQUAMOUS CELL CARCINOMA

- Epidemiology
- Aetiological factors
- Oncogenes and tumour-suppressor genes
- Clinical presentation
- Pathology
- Prognosis
- Verrucous carcinoma
- Carcinoma in situ

PRECANCEROUS (OR PREMALIGNANT) LESIONS AND CONDITIONS

BASAL CELL CARCINOMA (RODENT ULCER)

MELANOCYTIC NAEVI AND MALIGNANT MELANOMA

- Melanocytic naevi
- Malignant melanoma

FURTHER READING

1870
1871
1872
1873
1874
1875
1876
1877
1878
1879
1880
1881
1882
1883
1884
1885
1886
1887
1888
1889
1890
1891
1892
1893
1894
1895
1896
1897
1898
1899
1900

1901
1902
1903
1904
1905
1906
1907
1908
1909
1910
1911
1912
1913
1914
1915
1916
1917
1918
1919
1920
1921
1922
1923
1924
1925
1926
1927
1928
1929
1930

Oral epithelial tumours, melanocytic naevi, and malignant melanoma

The main tumours derived from oral epithelium are the squamous cell papilloma and squamous cell carcinoma. The squamous cell papilloma is a benign neoplasm, but a variety of virally induced epithelial hyperplasias, such as viral warts, may mimic the papilloma clinically and these are included in this chapter. Basal cell carcinoma does not occur in the oral cavity but may present on the lip and involve the vermilion border.

The melanocytic naevi and malignant melanomas are hamartomatous and neoplastic lesions, respectively, derived from melanocytes and/or their precursors. Whilst there is an intimate relationship between these cells and the epithelium, melanocytes are derived from the neuroectoderm of the neural crest and are a population of cells distinct from keratinocytes.

Squamous cell papilloma and other benign lesions associated with human papillomavirus (HPV)

HPV are DNA viruses and more than 75 types are now recognized, of which at least 16 have been isolated from oral lesions. The majority are low-risk types (e.g. 6, 11, 13, and 32) which are associated with benign lesions of the skin and oral mucosa, such as verruca vulgaris, condyloma acuminatum, and focal epithelial hyperplasia. However, certain types of HPV may be present in clinically healthy oral mucosa and the identification of HPV in a lesion does not necessarily imply a causal relationship. The possible role of HPV in the aetiology of squamous cell carcinoma is discussed later in this chapter; their role in leukoplakia is discussed in Chapter 9.

Key points – HPV

- infect keratinocytes
- associated with abnormal epithelial proliferation
 - hyperplasia – warts
 - benign neoplasia – papilloma
 - oral premalignant lesions – leukoplakia
 - malignant neoplasia – squamous cell carcinoma
- may be present in normal epithelium

Squamous cell papilloma

This common benign tumour is usually a solitary lesion and can occur anywhere on the oral mucosa. Most occur in adults but they may also be seen in children.

Papillomas vary in size and may be either pedunculated or sessile. They present as warty or cauliflower-like growths with a white or pink surface depending on the amount of keratin present (Fig. 10.1). Histological examination shows finger-like processes of proliferating stratified squamous epithelium supported by thin cores of vascular connective tissue (Fig. 10.2). The epithelium may show hyperkeratosis. Mitotic figures are often seen in the basal layer of the epithelium, but features of epithelial dysplasia are not present.

Malignant change has not been described in a squamous cell papilloma of the oral mucosa and it is not a premalignant lesion.

Verruca vulgaris (common wart)

Clinically, these lesions present as squamous cell papillomas and may be sessile or pedunculated, single or multiple. They appear white because of hyperkeratosis and are seen most often in children when they may be associated with autoinoculation from warts on the fingers and lips.

Histologically, they consist of papillary processes of proliferating, acanthotic, hyperkeratotic squamous epithelium supported by thin cores of vascular connective tissue. The hyperplastic rete ridges around the margins usually slope inwards towards the centre of the lesion (Fig. 10.3).

Common warts on the skin are usually associated with HPV types 2 or 4 infection.

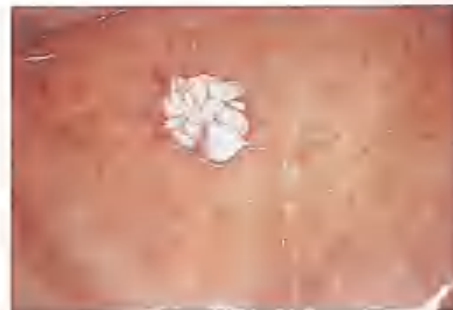

Fig. 10.1 Squamous cell papilloma.

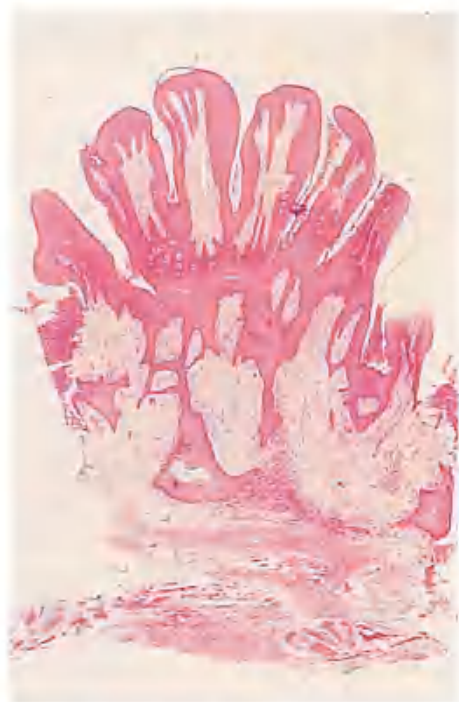

Fig. 10.2 Squamous cell papilloma.

Condyloma acuminatum (venereal wart)

Characteristically, these warts occur in the anogenital region but they may be seen on the oral mucosa. Clinically, they present as multiple pink nodules which grow and coalesce to form soft, pink, pedunculated or sessile papillary lesions similar in colour to the surrounding mucosa (Fig. 10.4). In some patients they are an oral manifestation of HIV infection (see Chapter 11).

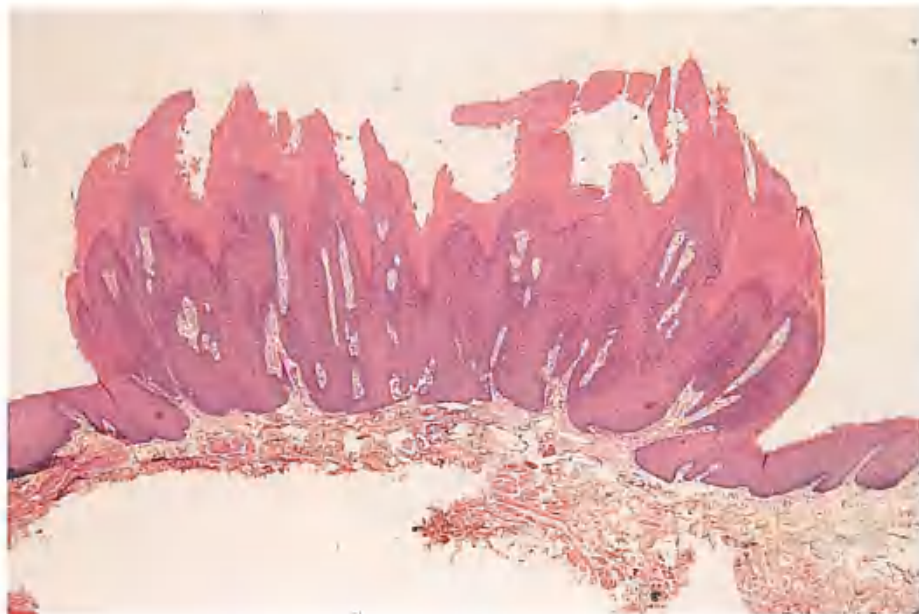


Fig. 10.3 Verruca vulgaris.

Histologically, the dominant epithelial feature is a prominent acanthosis with marked broadening and elongation of the rete ridges (Fig. 10.5). Keratinization is not a feature although there may be a surface layer of parakeratotic cells.

Condyloma acuminatum is associated with HPV types 6, 11, and 16 (Fig. 10.6).

Focal epithelial hyperplasia (Heck's disease)

This rare disease was originally described in native North Americans and Inuit but occurs in other ethnic groups and in some immunocompromised patients. It is characterized by multiple small elevated epithelial plaques or polypoid lesions most frequently involving the lower lips and buccal mucosa.

Histological examination shows hyperparakeratosis and acanthosis of the oral epithelium.

HPV types 13 and 32 appear to be specific to oral focal epithelial hyperplasia.

Squamous cell carcinoma

Epidemiology

Squamous cell carcinoma accounts for 90 per cent or more of all oral malignant neoplasms.

The incidence of oral cancer varies enormously around the world, and data in some cases are difficult to interpret since cancer registration using internationally agreed criteria (based on the WHO International Classification of Diseases (ICD)) is comparatively recent. In both the United Kingdom and the USA oral cancer accounts for less than 4 per cent of all cancers, but in India and South-East Asia it accounts for up to 40 per cent of all malignant tumours. The incidence rates for large countries, such as India and the USA, conceal regional and ethnic variations. For

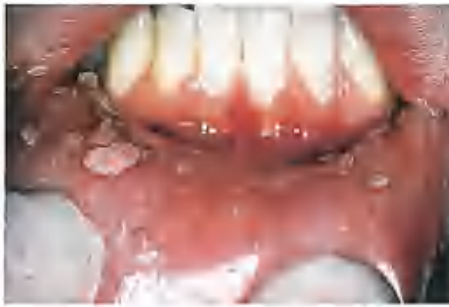

Fig. 10.4 Condyloma acuminatum.

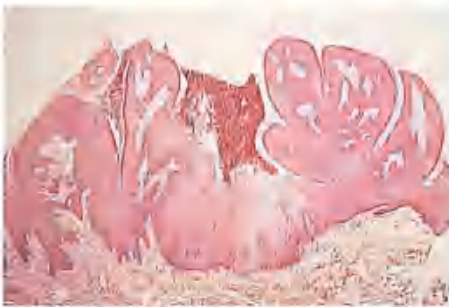


Fig. 10.5 Condyloma acuminatum.



Fig. 10.6 Immunohistochemical demonstration of HPV type 6 (black reaction product) in oral condyloma acuminatum.

example, incidence rates tend to be higher in urban as opposed to rural communities, and in the USA are higher for blacks than whites. In the United Kingdom, incidence rates are slightly higher in Scotland than in England and Wales.

In the United Kingdom oral cancer ranks in incidence about 15th of all cancers in men and 20th of all cancers in women, but on a global basis it has been estimated that it is the fourth commonest cancer in men and the sixth commonest in women. When data for both sexes are combined it is the sixth commonest form of malignant disease, and ranks about eighth in incidence for all cancers in developed countries, and third in incidence in developing countries.

In the United Kingdom the incidence of oral cancer is about 4 per 100 000 population. The disease is more common in men than in women, although the difference for intraoral cancer is now less marked in England and Wales than previously as incidence rates in men have fallen proportionally more than those for women. The male:female ratio for intraoral cancer in England and Wales is presently about 2:1, and about 3:1 in Scotland. In contrast, lip cancer is some six to eight times more common in men.

Over 90 per cent of oral cancer occurs in patients over the age of 40 years when there is then a sharp and almost linear increase in incidence with age. In England and Wales 85 per cent of cases occur in patients over the age of 50 years.

Although the incidence and mortality rates of oral cancer, particularly in men, have decreased significantly in the United Kingdom and in other developed countries from those of the first half of the twentieth century, there is evidence that the rates are now increasing. In addition, the age of patients with oral cancer, particularly men, has been declining. To what extent this upward trend will continue is unknown but it presumably reflects changes in aetiological factors. In most cases, the reasons for the increasing incidence are unknown but, as discussed later, the increase in cancer of the tongue in the USA has been linked to the increase in use of smokeless tobacco. In the United Kingdom the increased consumption of alcohol that has occurred over the past 30 to 40 years may be a factor but the evidence is inconclusive. Mortality rates show considerable geographic variation but even in affluent Western societies the death : registration ratio is

Key points – Epidemiology of oral cancer

- incidence varies around the world
 - less than 4 per cent of all cancers in UK and USA
 - up to 40 per cent of all cancers in India and other parts of Asia
- globally is one of the 10 commonest cancers
- incidence in developed countries now on the increase
- in the UK oral cancer is 2–3 times more common in men than women
- in the Western world oral cancer occurs mainly in people over the age of 40
- in the Western world the incidence in people aged under 40 years is increasing
- death : registration ratio 30–40 per cent

about 30–40 per cent. Despite advances in treatment mortality rates have not changed significantly in the last few decades. However, the five-year survival rates have increased significantly.

Oral carcinoma may occur on any part of the oral mucosa, but there are geographical variations in the sites particularly at risk which partly reflect different aetiological factors. In the United Kingdom the tongue and floor of mouth are the commonest sites. The palate is an unusual location for carcinoma to develop. In contrast, in India the buccal mucosa is the most frequent site, and this can be ascribed to the widespread chewing of betel quid or pan and to smoking habits in that part of the world, as discussed later.

Aetiological factors

Many factors are involved in the aetiology of oral cancer (see Table 10.1) and these vary in different ethnic groups. However, epidemiological studies have shown that tobacco and alcohol are the two most important and probably account for about 75 per cent of intraoral cancers in the Western world. Poor diet probably accounts for another 10–15 per cent.

Tobacco

A wealth of epidemiological and experimental data implicate tobacco, however used, as an important factor in the aetiology of

oral cancer. However, the relative risks associated with different methods of consumption are still unresolved, and the relationship is complicated further by possible synergistic effects when tobacco is combined with other extrinsic factors, such as alcohol and pan chewing (see below).

Polycyclic aromatic hydrocarbons are present in tobacco smoke, but the main carcinogenic agents present in tobacco, regardless of how it is used, are thought to be nitrosamines derived from nicotine.

TOBACCO SMOKING

It is now accepted that there is an aetiological relationship between the smoking of tobacco and oral carcinoma regardless of the type of tobacco and method of consumption. Pipe and cigar smoking have been linked with carcinoma of the lip for many years, and the evidence linking cigarette smoking with intraoral carcinoma is now firmly established. The risk increases with the number of cigarettes smoked per day and with the duration of smoking. For example, persons smoking 40 or more cigarettes per day have a relative risk of oral cancer 10 to 20 times greater than non-smokers. In subjects who stop smoking the relative risk falls to that of non-smokers after about 10 years.

The type of tobacco, curing methods, and method of smoking may also influence the relative risk of oral cancer. For example, in India the habit of reverse smoking (i.e. with the burning end inside the mouth) is associated particularly with cancer of the palate, one of the rarest sites for oral cancer in other groups. The relative risk of oral cancer for reverse smokers is over 40 times that of non-smokers. For more conventional smoking habits site associations are less clear. However, carcinogens in tobacco smoke may dissolve in saliva and collect in the gutter areas where saliva tends to pool, increasing the risk of oral cancer developing in the floor of the mouth and ventral or lateral tongue, and the soft palate.

SMOKELESS TOBACCO

Snuff is powdered tobacco which, in addition to being inhaled, can also be placed in contact with the oral mucosa in the buccal and labial sulci (snuff dipping). It is widely practised in the south-eastern USA and in Sweden. It is also available in the USA in sachets for oral use and it has been suggested this is one of the factors that may have led to the increase in oral cancer in young people. However, the relative risk of oral cancer from the use of oral snuff is unclear. Although hyperkeratosis and squamous cell carcinoma have been reported, epidemiological surveys have not demonstrated an increased risk of oral cancer. (Apart from Sweden the sale of loose and packeted snuff is banned in the European Union.)

Tobacco chewing was relatively common in the United Kingdom in the early part of the twentieth century, particularly in occupations such as mining where smoking was environmentally dangerous because of the possibility of explosion. However, in most Western countries the habit has declined, but chewing habits are particularly prevalent in certain parts of the world as discussed below.

Betel quid (pan) and other chewing habits

Pan chewing is one of the most widespread habits in the world and is practised by over 200 million people worldwide. It is par-

Table 10.1 Aetiological factors in oral cancer

Tobacco smoking	
pipes	
cigars	
cigarettes	
bidis	
reverse smoking	
Smokeless tobacco	
snuff dipping	
tobacco sachets	
tobacco chewing	
Betel chewing, betel quid, areca nut	
Alcohol	
spirits	quality/quantity
wines and beers	
alcohol and tobacco synergism	
Diet and nutrition	
iron deficiency	
vitamins A and C	
nutritional deficiencies and alcoholism	
Dental factors	
Ultraviolet light	
Viruses	
herpes simplex viruses	
human papillomaviruses	
human immunodeficiency virus	
Immunosuppression	
Chronic infections	
candidosis	
syphilis	
Occupation	

ticularly common in South-East Asia and the Indian subcontinent and is also prevalent within these ethnic communities in parts of the UK. The composition of the quid varies but basically it consists of betel nut and slaked lime wrapped in a betel leaf to which tobacco and various spices are often added. The quid is usually placed in the buccal sulcus and is frequently kept in the mouth for a long time. As the quid is chewed, alkaloids are released from the nut and the tobacco which are said to aid digestion and to produce a slight euphoric effect. The habit is more common in women than in men, and although the frequency of use increases with age the habit often starts in childhood.

This habit induces leukoplakia where the pan is held in the mouth, and malignant transformation is usually evidenced clinically by the development of a papilliferous, ulcerated mass. Unravelling the roles of the constituents of the pan in the aetiology of leukoplakia and squamous cell carcinoma presents major problems which are compounded by possible interactions between components of the pan. For example, slaked lime can hydrolyse one of the alkaloids of betel nut (arecoline) to produce arecolidene which has been shown experimentally to be carcinogenic. The increased incidence of oral cancer in Malaysia and Papua New Guinea where betel nut is chewed with lime, but without tobacco, suggests that such mechanisms could play a role. However, several epidemiological studies have shown that the relative risk of oral cancer is greatly increased when tobacco is present in the pan.

Chewing of the areca nut alone is the main aetiological factor in oral submucous fibrosis (see Chapter 13) which is regarded as a precancerous condition (see later).

Alcohol

Epidemiological studies from several countries have demonstrated an increased risk of oral cancer associated with alcohol consumption. Although there is evidence to support a dose/time relationship, this is less striking than that seen with tobacco smoking. Pure ethanol has not been shown to be carcinogenic and it is thought that other chemicals in the beverage, called congeners, are responsible for the increased cancer risk. The consumption of unmaturred home-stilled spirits containing carcinogenic by-products may be particularly important in certain parts of the world. All forms of alcoholic beverages are dangerous; the relative risk for beer and wine drinkers is as high as, and in some studies greater than, that for spirit drinkers. The increasing incidence of oral cancer, especially in younger persons, may be linked to the rise in alcohol consumption over the past few decades.

Unravelling the role of alcohol in the aetiology of oral cancer has been complicated because of the close association between drinking and smoking habits. Although alcohol is an important factor independent of smoking, many studies have shown a marked increase in the relative risk when smoking and drinking are practised concurrently, suggesting a synergistic or multiplicative effect.

The mechanisms by which alcohol consumption increases the risk of oral cancer are still unclear. Mention has already been made

Key points – Tobacco and alcohol

- both are independent risk factors for oral cancer
- their effect together is synergistic
- relative risk for tobacco increases with amount and duration of use
- relative risk for tobacco influenced by method of use and type
- main carcinogens in tobacco are N-nitrosamines derived from nicotine
- alcoholic drinks may include constituents (congeners) and/or contaminants that are carcinogenic
- alcoholic drinks may enhance transport of carcinogens across the mucosal barrier
- nutritional deficiencies in chronic alcohol abuse may impair the mucosal barrier
- liver disease in chronic alcohol abuse may impair its ability to detoxify carcinogens
- immunosuppression in chronic alcohol abuse may increase the risk of developing cancer

of possible carcinogenic contaminants and congeners that may be present in alcoholic beverages and such drinks may also enhance the penetration of carcinogens across the mucosal barrier. It is also possible that nutritional deficiencies and impaired metabolism which are common in heavy drinkers could damage the ability of the oral mucosa to maintain its barrier function. Histological studies suggest that alcohol and tobacco usage are associated with atrophy of oral epithelium. Chronic alcohol intake may impair the ability of the liver to detoxify potential carcinogens, and can also suppress immune responses, increasing the risk of cancer.

Concern has also been expressed regarding the potential risk from mouthwash use. The evidence is inconclusive, but an increased risk of oral cancer has been reported in subjects using high alcohol content (25 per cent or higher) mouthwashes.

Diet and nutrition

The increased risk of oesophageal, pharyngeal, and oral cancer associated with primary sideropenic anaemia (Plummer-Vinson or Patterson-Kelly syndrome) has been recognized for many years. Iron is essential for the maintenance of oral epithelium and it is possible that atrophic changes in iron-deficiency anaemia render the mucosa more susceptible to chemical carcinogens. (A similar effect may be associated with other diseases showing epithelial atrophy, such as lichen planus and tertiary syphilis.)

Vitamin A is also important in the maintenance of stratified squamous epithelium, and several epidemiological studies have shown that individuals whose diets are high in the antioxidant vitamins A, C, and E have a decreased risk of oral cancer. The risk decreases with increasing consumption of fresh fruit and

Key points – Diet and oral cancer

- dietary deficiencies or imbalances may account for 15 per cent of oral cancer
- deficiencies of iron and of the antioxidant vitamins A, C, and E increase the risk for oral cancer
- diets high in fresh fruit and vegetables decrease the risk of oral cancer

vegetables. The strongest protective effect is related in particular to a diet with a high fruit intake. The possibility of nutritional deficiencies associated with alcoholism has been discussed above.

Dental factors

Poor oral hygiene, faulty restorations, sharp edges of teeth, and ill-fitting dentures have all been incriminated in the aetiology of oral cancer, but the evidence for this is meagre. Many patients with oral malignancy have poor dentitions but they also smoke and drink heavily, and the relative importance of the various factors in the aetiology of oral carcinoma is difficult to evaluate. Experimental carcinogenesis has shown that mechanical irritation can act as a promoter, but not as an initiator, and dental factors may have a similar role in oral carcinoma in humans.

Occupational risks

Outdoor workers such as those employed in agriculture, forestry, and fishing are at risk of high exposure to ultraviolet light, which is an important factor in squamous cell carcinoma of the lip. In countries with particularly sunny climates, such as Australia, lip cancer can account for over 50 per cent of oral cancers. Lip (vermillion border) cancer occurs much more frequently in the lower than the upper lip, is much more common in men than women, and is associated particularly with outdoor occupations. It is rare in dark-skinned races because of the protection conferred against ultraviolet light by melanin pigment. Squamous cell carcinoma of the lip may be preceded by hyperkeratotic and dysplastic changes – solar keratosis.

The possible role of other occupational and environment factors, such as atmospheric pollution by chemicals and dusts, is largely unknown.

Viruses

HERPES SIMPLEX VIRUSES (HSV)

Laboratory experiments have shown that HSV can be carcinogenic or cocarcinogenic under certain circumstances and so must be considered as possible aetiological agents in oral carcinoma. Although viral markers for HSV have been demonstrated in some tumours, this does not necessarily imply a causal relationship. If HSV do play a role in the aetiology of oral carcinoma, it remains to be explained why such ubiquitous agents so rarely produce tumours.

HUMAN PAPILLOMAVIRUSES (HPV)

HPV types 16 and 18 are important factors in the aetiology of squamous cell carcinoma of the uterine cervix, but their role in oral carcinomas and oral premalignancy is less clear. HPV have been identified with increasing frequency in the progression from normal mucosa, through dysplasia to carcinoma, but detection rates vary depending on the sensitivity of the assays used. In most studies HPV DNA has been found in about 25–35 per cent of oral carcinomas. HPV 16 is the most common isolate, but since the virus can also be detected in a relatively high proportion of normal oral mucosa its role in oral carcinogenesis is unclear.

However, certain HPV genes code for proteins which can bind and inactivate the products of the tumour-suppressor genes p53 and Rb (retinoblastoma gene). Mutation or inactivation of these genes, from whatever cause, is thought to be a significant step in the development of oral cancer (as discussed later), and for this reason HPV are likely to be an important cofactor in the aetiology of at least some oral cancers.

EPSTEIN-BARR VIRUS (EBV)

EBV has an aetiological role in the development of some nasopharyngeal carcinomas and some malignant lymphomas, but a similar role in the development of oral squamous cell carcinoma has not been established. Although the virus has been demonstrated more frequently in carcinoma than in normal epithelium, it is probably present only as a passenger virus.

Immunosuppression

Reports have been published of an increased risk of carcinoma of the lip in patients following renal and other organ transplantation, and it is likely that this is in some way related to the immunosuppressive therapy that such patients receive. Oral squamous cell carcinoma has been reported as an oral lesion associated with HIV infection (see Chapter 11), but the evidence of an increased risk in HIV-positive patients is inconclusive.

Smoking, alcohol, and iron deficiency also reduce the effectiveness of cell-mediated immunity, but the significance of this in their aetiological roles in oral cancer is unknown.

Chronic infections

CHRONIC CANDIDAL INFECTION

This is often associated with speckled leukoplakias, and such lesions are particularly prone to undergo malignant transformation (see Chapter 9). It has been suggested that the fungus is in some way responsible for the transformation. Chronic hyper-

Key points – Viruses and oral cancer

- no unequivocal role established
- evidence for role for HPV in some premalignant lesions and oral carcinomas increasing
- HSV and EBV are probably incidental passenger viruses

plastic candidosis (see Chapter 11) also presents as a leukoplakic lesion and may have premalignant potential. However, chronic oral candidal infections, such as those seen in patients with chronic mucocutaneous candidosis, do not undergo malignant transformation, even though there may be an associated immune deficiency or abnormality. The role of candidal infection in malignant transformation must, therefore, be regarded as uncertain.

SYPHILIS

Historically, tertiary syphilis has been linked with oral cancer, particularly on the dorsum of the anterior two-thirds of the tongue. Epithelial atrophy in the late stages of the disease may render the mucosa more susceptible to carcinogens. Syphilitic leukoplakia, a premalignant lesion, may precede invasive carcinoma. However, late-stage syphilis is now exceedingly rare and its relevance to the aetiology of oral cancer today is insignificant.

Oncogenes and tumour-suppressor genes

Oral cancer has a multifactorial aetiology and is the result of genetic damage allowing uncontrolled proliferation of cells. It is a multistep process involving multiple sequential mutations (see Box 10.1) which accumulate within the cell. Mutations in the genes which regulate cell growth and proliferation are particularly important. These genes are the growth-promoting proto-

oncogenes found in normal cells, and the tumour-suppressor genes that encode for growth inhibitory proteins. Under normal circumstances cellular proliferation is controlled by the balance between these growth-promoting and growth-inhibiting genes. During carcinogenesis a proto-oncogene may undergo mutation and become an activated oncogene, resulting in enhanced activity, and/or tumour-suppressor genes may be mutated or their products inactivated. The result in both cases leads to deregulation of cell proliferation and tumour formation.

Oncogenes

Oncogenes (for example, the *c-myc* and *ras* families) encode for a range of growth-promoting proteins such as growth factor receptors, signal-transmitting proteins, and stimulatory cell-cycle regulating proteins. In contrast, tumour-suppressor genes encode for growth-inhibitory proteins, such as p53 which plays a vital role in inhibiting the cell cycle (Fig. 10.7) and, if necessary, arresting the

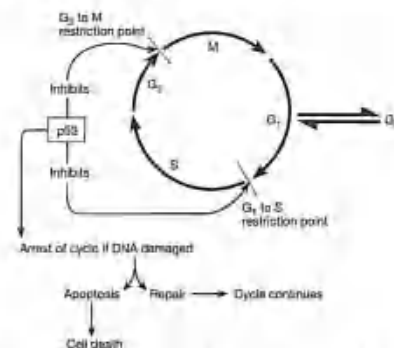


Fig. 10.7 The cell cycle and restriction points. After mitoses (M), cycling cells enter a gap phase (G₁) during which growth factors drive the cell towards S phase, where DNA synthesis occurs. Before the cell is committed to DNA replication it must pass the G₁ to S restriction point (checkpoint). If the DNA is damaged the cycle is arrested to allow time for repair or activation of apoptosis. After S phase the cell enters a second gap phase (G₂). If there has been an error in reduplication of DNA, the cycle can be arrested at the G₂ to M restriction point before cell division occurs. During G₁ cells may also enter a resting stage (G₀) of varying duration before re-entering the cycle.

Key points – Oncogenes

- derived from mutated proto-oncogenes of normal cells
- mutation results in enhanced or inappropriate gene expression
- code for growth-promoting factors
- excess or abnormal oncogene product may lead to uncontrolled cell growth
- over-expression of certain oncogenes is involved in the aetiology of oral cancer

Box 10.1 Genetic abnormalities in oral cancer

- The development of oral cancer involves the progressive accumulation of 6 to 10 genetic alterations in an epithelial cell leading to uncontrolled proliferation and clonal expansion.
- Different genetic alterations occur at different times in the histological progression from normal epithelium through dysplasia to carcinoma *in situ* and invasive growth; genetic progression models are being developed.
- Genetic alterations can be detected by identifying loss of chromosomal material from specific areas of a chromosome, called loss of heterozygosity (LOH).
- A genetic progression model based on chromosomes frequently identified as showing LOH in oral carcinogenesis suggests:
 - normal mucosa → LOH at 9p; predysplastic lesion
 - predysplastic lesion → additional LOH at 3p, 17p leading to dysplasia
 - dysplasia → additional LOH at 11q, 13q, 14q leading to carcinoma *in situ*
 - carcinoma *in situ* → additional LOH at 6p, 8, 4q leading to invasion.
- These areas of LOH contain known or presumptive tumour-suppressor genes, e.g. p53 gene (17p), retinoblastoma gene (13q).

Key points – Tumour-suppressor genes

- present in normal cells
- code for proteins that regulate cell proliferation (the cell cycle)
- mutations/deletions result in defective/deficient protein production
- defective/deficient protein may lead to uncontrolled cell growth
- mutation of the p53 gene is involved in many human cancers, including oral cancer
- normal p53 protein detects DNA damage and arrests the cell cycle
- mutant p53 protein allows cells with damaged DNA to continue to cycle

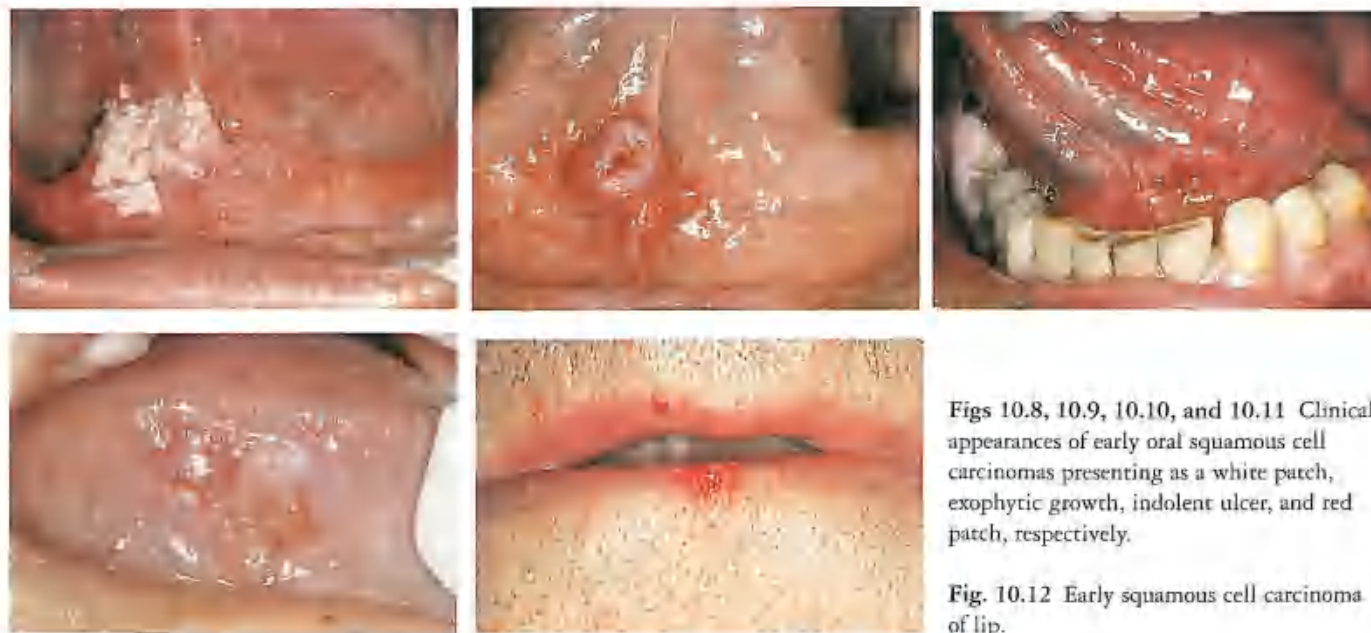cycle and switching cells into apoptosis. The most important oncogenes and tumor-suppressor genes so far identified appear to influence pathways controlling the first stages of the cell cycle, i.e. the progression through the G₁ phase (the phase before DNA synthesis) into S phase (the phase of DNA synthesis). Most oncogenic agents probably exert significant effects during the G₁ phase of the cell cycle and the G₁ to S transition is carefully regulated by inhibitory proteins, particularly p53. Thus, cells with damaged DNA are normally blocked at this G₁ checkpoint. This allows time for repair of the damaged DNA, or, if that fails, to switch the cell into apoptosis, so preserving the integrity of the genome. Mutations of the p53 gene can therefore result in loss of regulation of the checkpoint, allowing cells with damaged DNA

to undergo replication. Mutation of the p53 gene is a common and significant event in many cancers throughout the body.

Clinical presentation

The clinical presentation of oral squamous cell carcinoma can take many forms. Early diagnosis is the most important factor influencing prognosis, and clinicians must be suspicious of any lesion for which no cause can be found or which does not respond as expected when putative causes have been eliminated. Oral cancer is also a relatively uncommon disease and lesions may present in areas of the mouth that are difficult to examine. Clinicians must therefore be vigilant in their examination of the mucosa. Vigilance and suspicion are key words in the diagnosis of early carcinoma.

Early lesions are usually asymptomatic. Common modes of presentation are a white patch, a small exophytic growth which in the early stages may show no ulceration or erythema, a small indolent ulcer, or an area of erythroplakia (Figs 10.8–10.11). Pain is seldom present. Clinical features which should arouse suspicion of an early carcinoma are persistent ulceration, induration, and fixation of affected tissue to underlying structures. Induration is rubbery hardness caused by invasion of the carcinoma resulting in loss of the normal elasticity and compliance of the oral mucosa. Fixation is caused by the carcinoma infiltrating through and binding together (tethering) different natural tissue planes. Underlying bone destruction may also be detected in the case of carcinomas arising from the alveolar mucosa. Lymph node involvement may occur early in oral carcinomas, but enlarged regional nodes do not necessarily indicate metastatic spread as they may show only non-specific changes of reactive hyperplasia. Carcinoma developing on the vermilion border of the lip is clearly visible and so may be noticed at an early stage as a slightly raised



Figs 10.8, 10.9, 10.10, and 10.11 Clinical appearances of early oral squamous cell carcinomas presenting as a white patch, exophytic growth, indolent ulcer, and red patch, respectively.

Fig. 10.12 Early squamous cell carcinoma of lip.

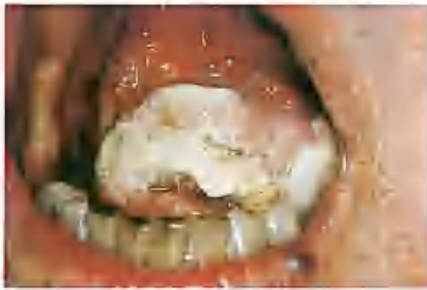

Fig. 10.13 Advanced squamous cell carcinoma of the floor of the mouth and ventral tongue presenting as a mass with a grossly necrotic surface.

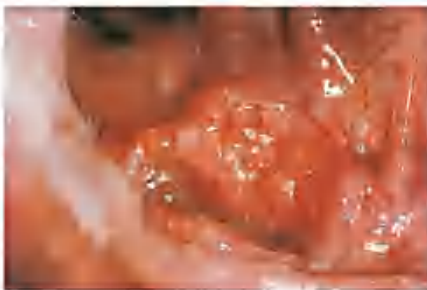


Fig. 10.14 Squamous cell carcinoma of the floor of the mouth presenting as a deep, crater-like ulcer.

swelling or a crusty, inconspicuous lesion resembling delayed healing of herpes labialis (Fig. 10.12).

An advanced or late lesion may present as a broad-based, exophytic mass with a rough, nodular, warty, haemorrhagic, or necrotic surface (Fig. 10.13), or as a deeply destructive and crater-like ulcer with raised, rolled everted edges (Fig. 10.14). Infiltration of the oral musculature may result in functional disturbances, particularly if the tumour involves the tongue or floor of mouth. Because of reduced mobility of the tongue patients may complain of impaired speech or of difficulty in swallowing. Pain may be a feature of an advanced lesion. Bone invasion may be detected on

Key points – Clinical features of oral squamous cell carcinoma

- presents in a variety of ways
- early detection requires clinical vigilance and suspicion
- local invasion leads to:
 - induration and fixation of tissues
 - destruction of tissues
 - distortion of tissues
 - dysfunction of tissues
- metastatic spread to regional lymph nodes
 - enlarged, firm nodes
 - may be mobile or fixed

radiographs and may be suggested clinically by mobility of teeth, and in the mandible, by altered sensation over the distribution of the mental nerve, or pathological fracture.

It is important to note that the size of the surface lesion does not indicate the extent of underlying invasion.

Pathology

There is considerable variation in the histological appearances of oral squamous cell carcinoma. However, all show invasion and destruction of local tissues, and it is this that accounts for the induration and tethering or fixation that may be detected clinically (Fig. 10.15).

It is customary to grade squamous cell carcinoma into well-differentiated, moderately differentiated, and poorly differentiated types. In well-differentiated tumours, the neoplastic epithelium is obviously squamous in type and consists of masses of prickle cells with a limiting layer of basal cells around the periphery. Intercellular bridges are readily recognizable. Keratin pearls are often found within the masses of infiltrating cells, each pearl consisting of a central area of keratin surrounded by whorls of prickle cells (Fig. 10.16). Nuclear and cellular pleomorphism is not prominent and there are relatively few mitotic figures. Moderately differentiated tumours show less keratinization and more nuclear and cellular pleomorphism and mitotic activity, but are still readily identified as squamous in type. In contrast, in poorly differentiated tumours keratinization is usually absent and the cells show prominent nuclear and cellular pleomorphism and

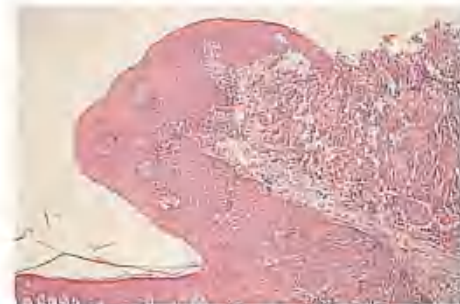


Fig. 10.15 The edge of a malignant ulcer showing invasive squamous cell carcinoma.

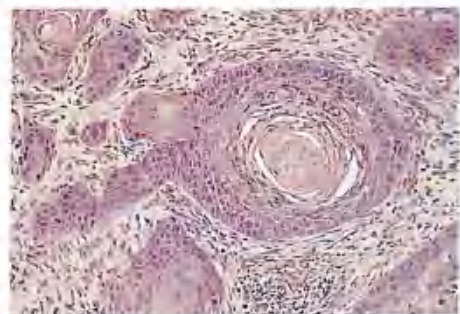


Fig. 10.16 Well-differentiated squamous cell carcinoma showing keratin pearls.

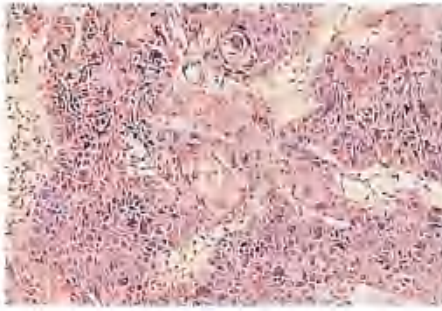


Fig. 10.17 Moderate/poorly-differentiated squamous cell carcinoma.

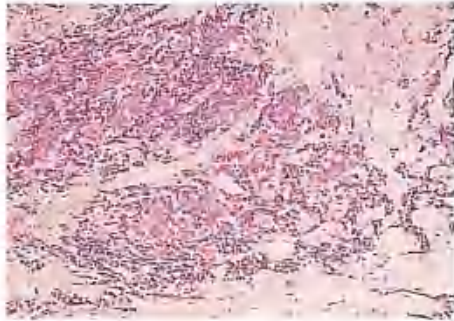


Fig. 10.18 Poorly differentiated squamous cell carcinoma.

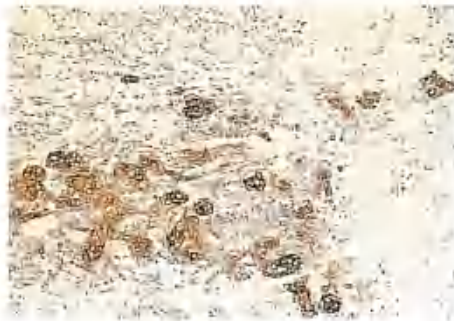


Fig. 10.19 Immunohistochemical demonstration of cytokeratin (brown reaction product) in poorly differentiated squamous cell carcinoma.

abundant, often bizarre, mitoses. It must be appreciated that the assessment of grade is entirely subjective and that a degree of overlap between them is inevitable (Fig. 10.17). In some poorly differentiated tumours the cells may be so abnormal as to hardly be recognizable as epithelial cells (Fig. 10.18). In such cases, immunohistochemistry to demonstrate cytokeratins (intermediate filament proteins that characterize epithelia) is particularly valuable (Fig. 10.19).

There is variable lymphocytic and plasma cell infiltration in the stroma supporting the invasive malignant epithelium, which probably represents a reaction by the host's immune system to tumour antigens as well as a response to tumour necrosis and ulceration.

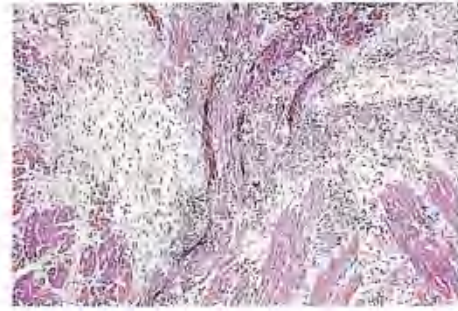


Fig. 10.20 Squamous cell carcinoma of the tongue showing sarcolemmal spread. Note the darkly-staining (blue/purple) cords of malignant epithelial cells invading muscle fibres and snaking from the top to the bottom of the figure.

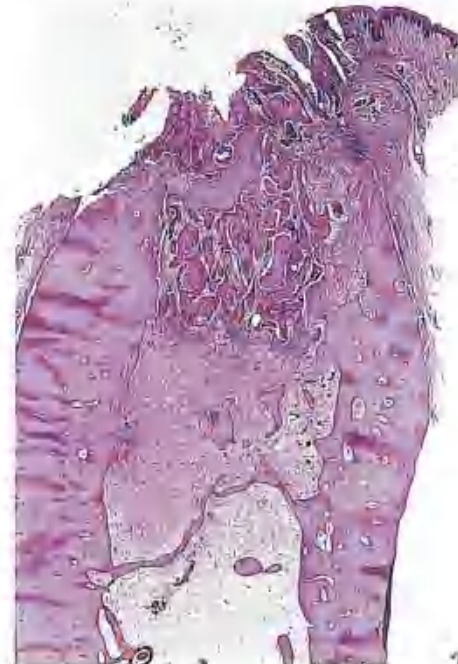

Fig. 10.21 Invasion of the mandible by squamous cell carcinoma spreading from the alveolar crest.

Most oral squamous cell carcinomas are extremely locally destructive. The pattern of infiltration of the adjacent tissues by the neoplastic epithelium is variable. In some tumours the appearances suggest a broad front of invasion, but in others apparently separate islands of carcinoma or even individual malignant cells may be seen well in advance of the main growth. Tumours where the invasive front consists of broad groups or sheets of malignant cells are said to have a cohesive invasive front, in contrast to those showing small islands, narrow strands, or individual cell infiltration which are non-cohesive. Tumours with a cohesive front tend to have a better prognosis. Lymphatic permeation, vascular invasion, sarcolemmal, and perineural spread may occur. Slender cords of malignant epithelium may infiltrate for considerable distances within muscle fibres (Fig. 10.20) and along nerve

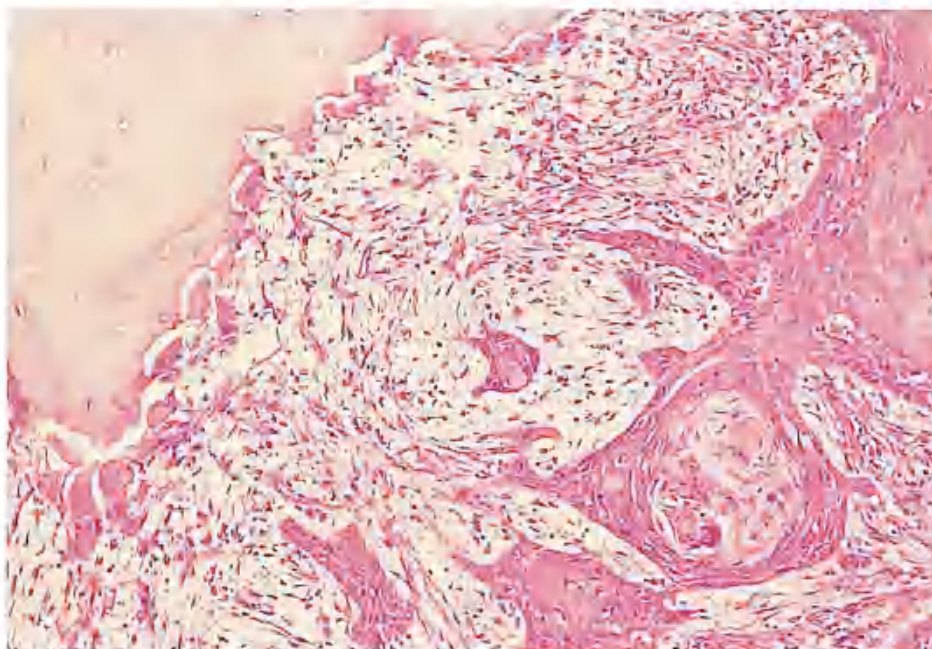


Fig. 10.22 Destruction of bone associated with infiltration of marrow spaces by squamous cell carcinoma.

bundles, necessitating excision of a wide margin of surrounding tissue in the surgical management of such a tumour. Invasion of bone occurs as a result of local spread. In the edentulous jaws (Fig. 10.21) the main route of entry appears to be through the crest of the ridge, following the path of vessels communicating between the marrow and periosteum rather than through the cortical plates. In the dentate patient, tumour may also invade via the periodontal ligament. Within the jaws the tumour spreads through the marrow spaces (Fig. 10.22) between the cancellous trabeculae and, particularly in the mandible, along neurovascular

bundles. The extent of bone involvement may, therefore, be greater than that suggested on routine radiographs.

Lymphatic spread to the regional lymph nodes is a variable feature, but the frequency of cervical metastasis tends to increase with increasing size of the primary tumour. The cervical lymph nodes are usually divided into five groups (Fig. 10.23). Tumours tend to metastasize initially to the nodes in the superior drainage groups (levels I and II), with progressive involvement of the more inferior groups in the chain as metastatic disease spreads. As the metastatic carcinoma destroys and replaces the nodal lymphoid tissue it may also invade through the capsule of the node into the

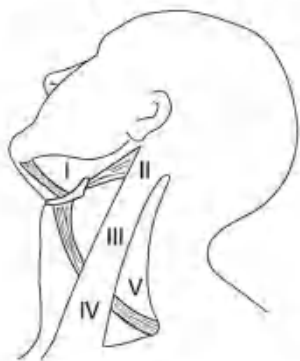


Fig. 10.23 Main lymph node groups in the neck.
 Level I: nodes of the submandibular and submental triangles.
 Level II: nodes of the upper cervical (jugular) chain.
 Level III: nodes of the mid-cervical (jugular) chain.
 Level IV: nodes of the lower cervical (jugular) chain.
 Level V: nodes of the posterior triangle of the neck.
 Level I is bounded by the digastric muscle. Levels II, III, and IV nodes lie deep to the upper, mid, and lower thirds of the sternocleidomastoid muscle and are related to the internal jugular vein. The omohyoid muscle separates levels III and IV.

Key points – Pathology of oral squamous cell carcinoma

- cytologically malignant squamous epithelium
- keratinization varies with degree of differentiation
- local invasion
 - lymphatic permeation
 - sarcolemmal spread
 - perineural spread
 - bone, edentulous/dentate
- metastatic spread to regional lymph nodes in neck

– intracapsular spread	– tumour confined within capsule of node	} related to clinical features and management.
– extracapsular spread	– tumour infiltrates through the capsule into the adjacent tissue of the neck	
- blood-borne metastases to distant sites occur relatively late in the course of the disease

surrounding tissues, resulting in fixation of the node on clinical examination. Extracapsular spread is an important feature which has an adverse affect on prognosis. Blood-borne metastases occur later in the clinical course of the disease. Previously, many patients died before distant metastases became apparent, but their incidence is now increasing as a result of better local and regional control of the primary tumour. The risk of distant metastases increases with increasing involvement of nodal metastases in the neck.

Prognosis

The survival rate of patients with oral carcinoma depends on a number of factors, but early diagnosis is by far the most important. It is influenced by the site of the lesion, and generally the further back in the mouth the tumour, then the worse the prognosis. This is probably because tumours at the back of the mouth tend not to be diagnosed at an early stage, but the rich lymphatic drainage around the base of the tongue may also favour early metastatic spread. Carcinomas in females have a better prognosis than carcinomas in males, possibly because they tend to be diagnosed and treated at an earlier stage. This probably reflects the fact that more females are regular dental attenders than males. Age affects prognosis, partly because with increasing age the patient becomes less well able to withstand extensive surgery or radiotherapy. Reduction in the effectiveness of cell-mediated immune responses may also be involved.

Although the past few decades have seen major advances in the methods used to treat oral cancer, the overall 5-year mortality rates have not changed significantly. Local recurrence at the primary site, or within the neck in patients with metastatic disease, is the major cause of death. A few patients also develop new primary tumours.

The major factors thought to influence prognosis have been incorporated into clinical staging systems which assess the extent of disease in the patient. The most widely used is the TNM system (Table 10.2) which is based on three parameters: T, the size of the primary lesion; N, the extent and distribution of metastases in the regional lymph nodes; M, the presence or not of distant metastases.

The reduction in survival rates related to metastatic spread is well established. Several studies have shown 5-year survival rates of about 80 per cent for patients without lymph node metastases compared to between 45 per cent and 65 per cent for those with metastases, depending on their extent. In particular, the presence

Table 10.2 Clinical staging of malignant neoplasms of the oral cavity (ICD9, 140, 141, 143–145) based on the TNM system

<i>Tumour</i>			
T1	Greatest diameter of primary tumour 2 cm or less		
T2	Greatest diameter of primary tumour > 2 cm but not > 4 cm		
T3	Greatest diameter of primary tumour > 4 cm		
T4	Massive tumour > 4 cm with gross local invasion		
<i>Nodes</i>			
N0	No clinically positive nodes		
N1	Single ipsilateral node not greater than 3 cm diameter		
N2	(a) Single ipsilateral node > 3 cm but not > 6 cm diameter (b) Multiple ipsilateral nodes not > 6 cm diameter (c) Bilateral or contralateral nodes not > 6 cm diameter		
N3	Any node > 6 cm diameter		
<i>Metastasis</i>			
M0	No distant metastases		
M1	Distant metastases		
<i>Clinical staging</i>			
Stage 1	T1	N0	M0
Stage 2	T2	N0	M0
Stage 3	T3	N0	M0 or
	T1, T2, or T3	N1	M0
Stage 4	T4	N0 or N1	M0 or
	any T	N2 or N3	M0 or
	any T	any N	M1

Table 10.3 Histopathological features related to prognosis of oral squamous cell carcinoma

Diameter of tumour (directly related to clinical T stage)
Depth of invasion (including invasion into bone)
Non-cohesive pattern of invasion
Perineural invasion
Lymphatic and vascular invasion
Metastatic disease (directly related to clinical N and M stages)
Extracapsular spread of nodal metastases

of extracapsular spread is an important indicator of poor prognosis. The main histopathological features that influence prognosis are listed in Table 10.3.

Verrucous carcinoma

This is an uncommon but distinctive pathological variety of low-grade squamous cell carcinoma which presents as a slow-growing, thick, white, warty plaque of heaped-up tissue. Histologically, it is a very well differentiated, heavily keratinizing squamous cell carcinoma with little or no cytological atypia. It is predominantly an exophytic tumour but also has a slowly advancing, pushing, cohesive invasive front causing local destruction. It has a good prognosis and is said not to metastasize.

The diagnosis of verrucous carcinoma is difficult and strict criteria must be adopted. The tumour must be differentiated from a

Key points – Prognosis of oral squamous cell carcinoma

- early diagnosis is the major factor determining prognosis
- site and late onset of symptoms adversely affect early diagnosis
- prognosis decreases with increasing clinical stage (related to early diagnosis)
- histopathological features influence prognosis

well-differentiated papillary squamous cell carcinoma or from leukoplakic lesions with warty surfaces, variously called verrucous hyperplasia or verrucous leukoplakia.

Carcinoma *in situ*

This term is used to describe severe epithelial dysplasia in which the whole, or almost the whole, thickness of the epithelium is involved but the basement membrane is intact and there is no invasion of the lamina propria (Fig 10.24).

Oral carcinoma *in situ* usually presents clinically as leukoplakia or erythroplakia (Fig. 10.25). It is a precancerous (pre-malignant) lesion (see below) but its natural history is not well understood. In some patients the lesion may progress to invasive carcinoma but in others it remains static for long periods and, in some, the degree of dysplasia may regress or fluctuate with time. It is common to find histological changes of dysplasia, including carcinoma *in situ*, in the epithelium surrounding an invasive carcinoma, even though this may appear clinically healthy. This suggests that in some patients there may be a field of potentially precancerous change involving a wide area of mucosa (Fig. 10.26). It is probable that some carcinomas thought to be recurrent tumours represent new primary lesions arising in such a field change.

Precancerous (or pre-malignant) lesions and conditions

A precancerous (or pre-malignant) lesion is defined as a morphologically altered tissue in which cancer is more likely to occur

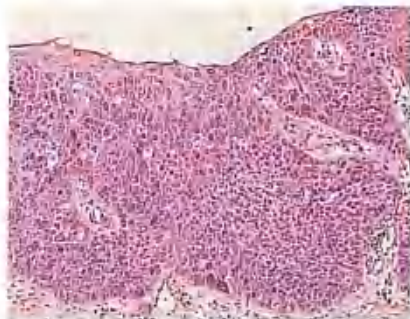


Fig. 10.24 Carcinoma *in situ* of the oral mucosa.

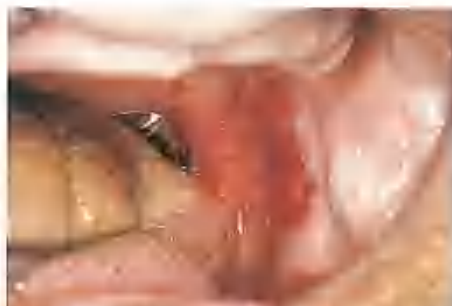

Fig. 10.25 Carcinoma *in situ* presenting as erythroplakia.

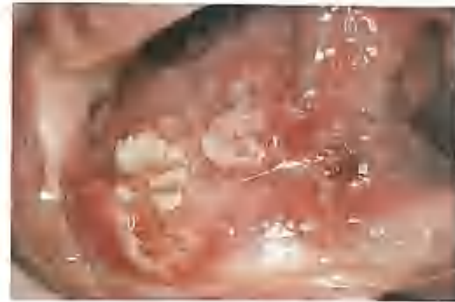

Fig. 10.26 Multifocal invasive carcinoma arising in an extensive field change of carcinoma *in situ* presenting as erythroplakia.

than in its normal counterpart, for example leukoplakia. That is, the lesion itself undergoes malignant transformation. In contrast, a precancerous (or pre-malignant) condition is a generalized disorder associated with a significantly increased risk of cancer developing somewhere in the mouth, for example oral submucous fibrosis. However, it must be remembered that relatively few oral carcinomas are preceded by a recognizable pre-malignant lesion or condition.

The following may be described as precancerous lesions or conditions of the oral mucosa and most are discussed elsewhere.

1. Precancerous lesions:

- (a) leukoplakia— homogeneous, non-homogeneous, nodular, and speckled types, including candida-associated lesions (chronic hyperplastic candidosis), and proliferative verrucous leukoplakia
- (b) erythroplakia
- (c) carcinoma *in situ*.

2. Precancerous conditions:

- (a) oral submucous fibrosis
- (b) lichen planus
- (c) actinic keratosis (for cancer of the lip)
- (d) other conditions associated with epithelial atrophy, e.g. sideropenic dysphagia.

Basal cell carcinoma (rodent ulcer)

This is a common neoplasm of the skin of the face, particularly in elderly patients with a history of long exposure to ultraviolet radiation (Fig. 10.27). Occasionally, basal cell carcinomas present on the lips, particularly the upper lip, but many are probably skin tumours that have spread to involve the vermilion. Multiple naevoid basal cell carcinomas arising at a younger age and on non-sun-exposed sites are a characteristic feature of the naevoid basal cell carcinoma syndrome (see Chapter 6).

The typical basal cell carcinoma presents as a slow-growing nodule that eventually ulcerates centrally. Histologically, it consists of cytologically malignant basaloid cells, arranged in a variety of patterns, invading adjacent tissues.

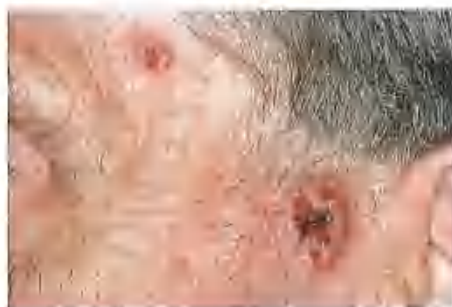

Fig. 10.27 Basal cell carcinoma (rodent ulcer).

Melanocytic naevi and malignant melanoma

Melanocytes are dendritic cells located mainly in the basal layer of the epidermis and in some mucous membranes. They are widely distributed and present in large numbers in the oral mucosa of clinically pigmented and non-pigmented races, the difference being one of activity rather than of number. Their function is to produce melanin which they then pass to the adjacent keratinocytes. Melanocytes are of neuroectodermal origin and do not contain intermediate filaments of the cytokeratin family.

A variety of lesions are associated with abnormality of melanocytes. Those presenting as tumours or tumour-like conditions (i.e. the naevi and neoplastic proliferations) are considered in this chapter. Other types of hypermelanosis of the oral mucosa, some of which are associated with systemic disease, are discussed in Chapter 13.

Melanocytic naevi

A naevus is any developmental blemish on skin or mucosa (Latin *naevus*, birthmark). Melanocytic naevi (often referred to as moles) are exceedingly common, particularly in the skin of the head and neck. Most present in childhood and adolescence. Despite their abundance in skin, they are rare in the oral mucosa. Most of those reported have presented in adult life as slightly elevated, pigmented lesions on the hard palate or buccal mucosa. Melanocytic naevi are hamartomatous lesions formed by proliferation of melanocytes or their precursors. The amount of melanin pigment they contain is highly variable. In most oral melanocytic naevi the naevus cells are located entirely within the lamina propria, that is, they are of intramucosal type (equivalent to the intradermal naevus of skin) (Fig. 10.28).

Malignant melanoma

Since excessive exposure to ultraviolet light is the most important predisposing factor for malignant melanoma of the skin, many tumours arise in the head and neck region. Skin tumours may present as pigmented plaques or nodular lesions and may be preceded by malignant melanoma *in situ*.

Malignant melanoma of the oral mucosa is rare. It is slightly more common in men than women, and over 70 per cent of cases

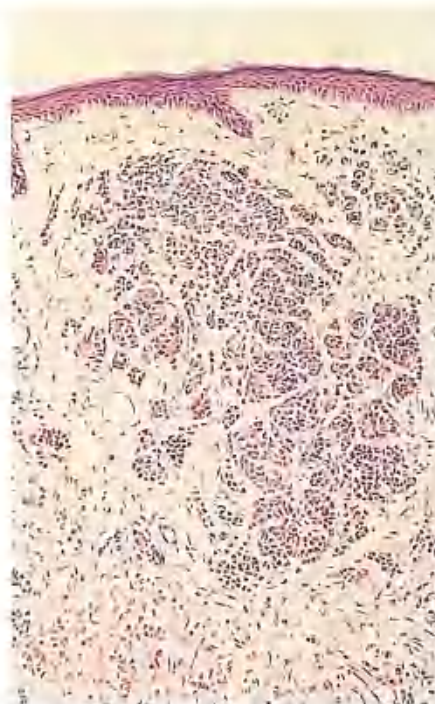


Fig. 10.28 Intramucosal/intradermal naevus of lip.

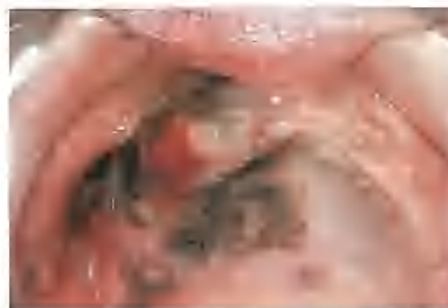

Fig. 10.29 Malignant melanoma.

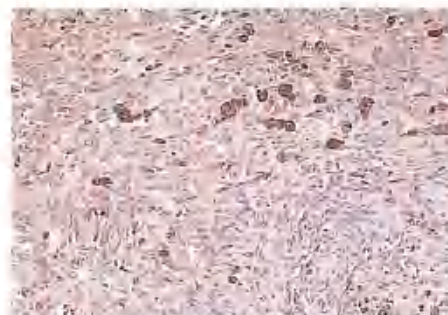


Fig. 10.30 Malignant melanoma (pigmented).


involve the posterior maxillary alveolar ridge and hard palate (Fig. 10.29). Most are advanced and extensively invasive lesions at presentation, but in about a third of cases there is a history of previous pigmentation in the area.

Most oral malignant melanomas present as dark-brown or bluish-black slightly raised lesions with an uneven nodular or

papillary surface. Histologically, they are highly pleomorphic neoplasms. The amount of melanin pigment is variable and in some may be absent (Fig. 10.30). The prognosis for most patients is very poor.

Further reading

- Buchner, A., Leider, A. S., Merrell, P. W., and Carpenter, W. M. (1990). Melanocytic naevi of the oral mucosa: a clinicopathologic study of 130 cases from northern California. *Journal of Oral Pathology and Medicine*, **19**, 197–201.
- Califano, J., van der Riet, P., Westra, W., Nawroz, H., Clayman, G., Piantadosi, S., *et al.* (1996). Genetic progression model for head and neck cancer: implications for field cancerization. *Cancer Research*, **56**, 2488–92.
- Field, J. K. (1992). Oncogenes and tumour-suppressor genes in squamous cell carcinoma of the head and neck. *Oral Oncology, European Journal of Cancer*, **28B**, 67–76.
- Field, J. K., Pavelic, Z. P., Spandidos, D. A., Stambrook, P. J., Jones, A. S., and Gluckman, J. L. (1993). The role of the p53 tumour suppressor gene in squamous cell carcinoma of the head and neck. *Archives of Otolaryngology Head and Neck Surgery*, **119**, 1118–22.
- Girod, S. C., Pfeiffer, P., Ries, J., and Pape, H.-D. (1998). Proliferative activity and loss of function of tumour-suppressor genes as 'biomarkers' in diagnosis and prognosis of benign and preneoplastic oral lesions and oral squamous cell carcinoma. *British Journal of Oral and Maxillofacial Surgery*, **36**, 252–60.
- Gorsky, M. and Epstein, J. B. (1998). Melanoma arising from the mucosal surfaces of the head and neck. *Oral Surgery, Oral Medicine, Oral Pathology, Oral Radiology and Endodontics*, **86**, 715–19.
- Hicks, M. J. and Flaitz, C. M. (2000). Oral mucosal melanoma: epidemiology and pathobiology. *Oral Oncology*, **36**, 152–69.
- Johnson, N. (2001). Tobacco use and oral cancer: a global perspective. *Journal of Dental Education*, **65**, 328–38.
- La Vecchia, C., Tavani, A., Franceschi, S., Levi, F., Corrao, G., and Negri, E. (1997). Epidemiology and prevention of oral cancer. *Oral Oncology*, **33**, 302–12.
- Lippman, S. M. and Hong, W. K. (2001). Molecular markers of the risk of oral cancer. *New England Journal of Medicine*, **344**, 1323–6.
- Miller, C. S. and White, D. K. (1996). Human papillomavirus expression in oral mucosa, premalignant conditions, and squamous cell carcinoma. *Oral Surgery, Oral Medicine, Oral Pathology, Oral Radiology and Endodontics*, **82**, 57–68.
- Moore, S. R., Johnson, N. W., Pierce, A. M., and Wilson, D. F. (2000). The epidemiology of mouth cancer: a review of global incidence. *Oral Diseases*, **6**, 65–74.
- Nagpal, J. K. and Das, B. R. (2003). Oral cancer: reviewing the present understanding of its molecular mechanisms and exploring the future directions for its effective management. *Oral Oncology*, **39**, 213–21.
- Ogden, G. R. and Wight, A. J. (1998). Aetiology of oral cancer: alcohol. *British Journal of Oral and Maxillofacial Surgery*, **36**, 247–51.
- Raybaud-Diogenè, H., Têtu, B., Morency, R., Fortin, A., and Monteil, R. A. (1996). P53 overexpression in head and neck squamous cell carcinoma: review of the literature. *Oral Oncology, European Journal of Cancer*, **32B**, 143–9.
- Scully, C. (1992). Oncogenes, onco-suppressors, carcinogenesis and oral cancer. *British Dental Journal*, **173**, 53–9.
- Scully, C. (1992). Viruses and oral squamous cell carcinoma. *Oral Oncology, European Journal of Cancer*, **28B**, 57–9.
- Scully, C. (1993). Oncogenes, tumour suppressors and viruses in oral squamous carcinoma. *Journal of Oral Pathology and Medicine*, **22**, 337–47.
- Sugerman, P. B. and Savage, N. W. (1999). Current concepts in oral cancer. *Australian Dental Journal*, **44**, 147–56.
- Winn, D. (1995). Diet and nutrition in the etiology of oral cancer. *American Journal of Clinical Nutrition*, **61** (suppl), 437S–45S.
- Woods, K. V., Shillitoe, E. J., Spitz, M. R., Schantz, S. P., and Adler-Storath, K. (1993). Analysis of human papillomavirus DNA in oral squamous cell carcinomas. *Journal of Oral Pathology and Medicine*, **22**, 101–8.
- Woolgar, J. A. (1999). Histological distribution of cervical lymph node metastases from intraoral/oropharyngeal squamous cell carcinomas. *British Journal of Oral and Maxillofacial Surgery*, **37**, 175–80.
- Woolgar, J. A., Rogers, S., West, C. R., Errington, R. D., Brown, J. S., and Vaughan, E. D. (1999). Survival and patterns of recurrence in 200 oral cancer patients treated by radical surgery and neck dissection. *European Journal of Cancer*, **35**, 257–65.
- Woolgar, J. A., Scott, J., Vaughan, E. D., Brown, J. S., West, C. R., and Rogers, S. (1995). Survival, metastasis and recurrence of oral cancer in relation to pathological features. *Annals of the Royal College of Surgeons of England*, **77**, 325–31.



Infections of the oral mucosa

VIRAL INFECTIONS

- Herpetic stomatitis
- Chickenpox and herpes zoster (shingles)
- Herpangina
- Hand, foot, and mouth disease
- Infectious mononucleosis (glandular fever)
- Measles
- Cytomegalovirus (CMV)

BACTERIAL INFECTIONS

- Necrotizing ulcerative gingivitis (NUG) (acute ulcerative gingivitis, acute necrotizing ulcerative gingivitis (AUG, ANUG))
- Noma (cancrum oris)
- Actinomycosis
- Syphilis (primary, secondary, tertiary, congenital)
- Tuberculosis
- Leprosy
- Gonorrhoea

FUNGAL INFECTIONS

- Candida* species and opportunistic infection
- Classification of oral and perioral candidosis
- Pseudomembranous candidosis (acute and chronic)
- Erythematous candidosis (acute and chronic)
- Chronic hyperplastic candidosis (candidal leukoplakia)
- Candida*-associated denture stomatitis (chronic atrophic candidosis)
- Candida*-associated and other forms of angular cheilitis
- Median rhomboid glossitis
- Chronic mucocutaneous candidoses and oral manifestations of deep visceral mycoses

HUMAN IMMUNODEFICIENCY VIRUS (HIV) INFECTION AND AIDS

- Oral manifestations of HIV infection

FURTHER READING

Faint, illegible text, possibly bleed-through from the reverse side of the page. The text is arranged in several lines and appears to be a list or a series of entries.

Infections of the oral mucosa

The common oral mucosal infections are caused by viruses, bacteria, and fungi. Helminthic and protozoal infections may involve oral tissues, but discussion of these is outside the scope of this book.

Viral infections

The main viral infections of the oral mucosa are listed in Table 11.1; some of the diseases are discussed elsewhere in this book. Human immunodeficiency virus (HIV), mumps, and influenza are included in the table since there may be associated mucosal lesions. HIV is discussed later in this chapter. Mumps primarily affects salivary glands (see Chapter 14), but may be associated with a non-specific stomatitis because of the reduced salivary flow. An acute non-specific stomatitis may also be seen as an early feature in patients with influenza.

Herpetic stomatitis

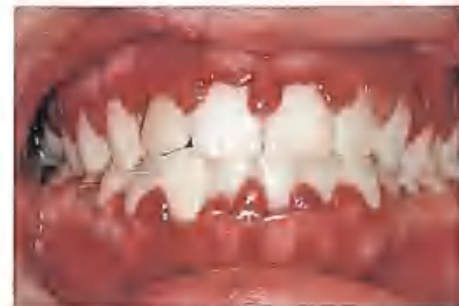The herpes simplex viruses (HSV) are DNA viruses and are the most frequent cause of a viral infection of the mouth. There are two types of HSV with serological, biological, and clinical differ-

ences. Type 1 is traditionally associated with infections of the skin and oral mucous membranes, and type 2 virus with infections of the genitalia. However, in sexually active subjects either type may be associated with oral and/or genital infection. HSV have also been implicated in recurrent erythema multiforme (see Chapter 12).

Primary infection with HSV type 1 is common and is transmitted by droplet spread or contact with the lesions. It occurs predominantly in young children and in the majority of cases is subclinical or causes a mild pharyngitis. However, in some patients it presents as primary herpetic gingivostomatitis. Following an incubation period of about 5 days the patient complains of prodromal symptoms of malaise and fever, and within a day or two the mouth becomes uncomfortable with the development of numerous small vesicles on any part of the oral mucosa and lips. There is also usually a widespread inflammation of the gingiva which is erythematous and oedematous (Fig. 11.1). The vesicles soon ulcerate (Fig. 11.2) and become secondarily infected and this is accompanied by regional lymphadenitis. Fresh crops of vesicles develop over the next few days, but the symptoms begin to subside about the sixth day of fever with the oral lesions taking 10–14 days to resolve. Circumoral crusting lesions on the lips may be seen, the crusting being due to coagulation of serum which exudes from ruptured vesicles (Fig. 11.3). Extraoral lesions may also be present, particularly in children. For example, vesicles may occur on the skin of the chin as a result of drooling of saliva and on the fingers as a result of sucking. Infections involving the nail-bed, herpetic whitlow, may be quite painful and infection may be transmitted to the eyes by rubbing.

Table 11.1 Viral infections causing, or associated with, diseases of the oral mucosa

Disease	Virus
Herpetic stomatitis, primary/ recurrent	Herpes simplex viruses, types 1 and 2
Chickenpox and shingles (herpes zoster)	Varicella-zoster virus
Herpangina	Coxsackie A virus
Hand, foot, and mouth disease	Coxsackie A virus
Infectious mononucleosis	Epstein-Barr virus
Measles	Paramyxovirus
Hairy leukoplakia	Epstein-Barr virus
Viral warts/epithelial hyperplasias	Human papillomaviruses
Oral manifestations of:	
HIV infection	Human immunodeficiency virus
Mumps	Paramyxovirus
Influenza	Influenza virus
Cytomegalovirus infection	Cytomegalovirus



Figs 11.1 Acute herpetic stomatitis showing acute gingivitis.

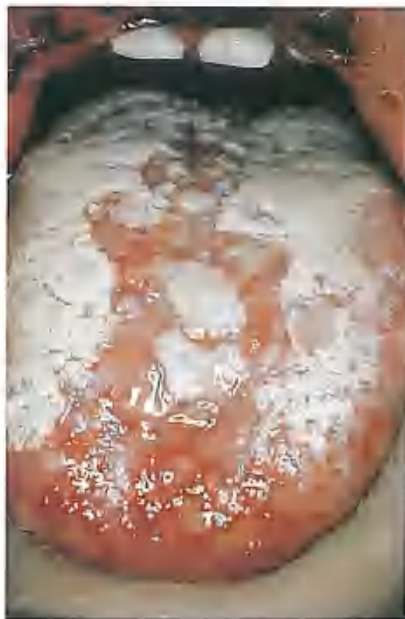

Fig. 11.2 Acute herpetic stomatitis showing lingual ulceration. The white coating of the tongue is due to overgrowth of filiform papillae, following lack of normal mechanical debridement during mastication because of pain and discomfort.

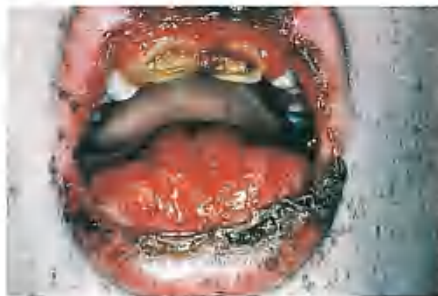

Fig. 11.3 Acute herpetic stomatitis showing extensive circumoral crusting following rupture of vesicles on the lips. (As an incidental finding this patient also has Peutz-Jeghers syndrome (see Chapter 13).)

Key points – Primary infection with HSV

- occurs mainly in young children
- mainly transmitted by droplet spread from saliva
- frequently subclinical
- may present as an acute stomatitis with vesicles, ulcers, malaise

Histological examination of an intact herpetic vesicle shows an intraepithelial blister (Fig. 11.4). The vesicle results from distension and rupture of the virally infected epithelial cells by intracel-

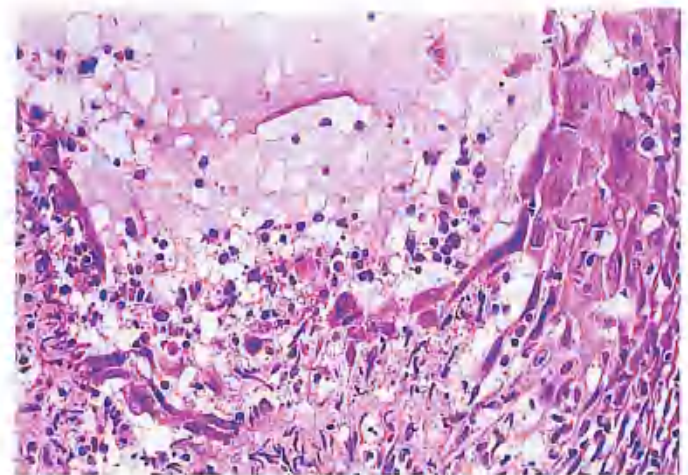


Fig. 11.4 Intraepithelial vesicle in herpes labialis.

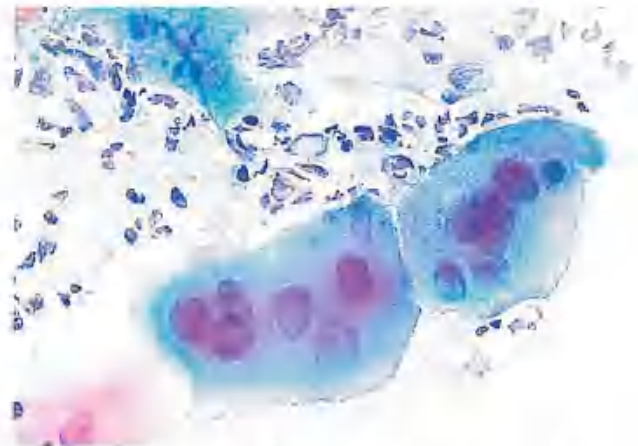


Fig. 11.5 Cytopathic changes and multinucleate cells in smear from a herpetic vesicle.

lular oedema and the coalescence of disrupted cells. The rupture of infected cells releases new viral particles to infect adjacent epithelial cells and the virus also gains access to the sensory axons of the trigeminal nerve. The infected cells are swollen and have eosinophilic cytoplasm and large, pale vesicular nuclei. These changes are described as ballooning degeneration. Giant cells containing many such nuclei also form as a result of fusion of the cytoplasm of infected cells (Fig. 11.5). The balloon cells and multinucleate giant cells can often be identified in smears taken from an intact vesicle or from one which has recently ruptured. The lamina propria shows a variable inflammatory infiltrate, the density of which depends on the stage and severity of the disease, and inflammatory cells also extend into the epithelium.

About one in three of those who have had a primary infection, either clinical or subclinical, later develop recurrent HSV infections. This is due to reactivation of the virus which, following the primary infection, has remained latent in the sensory ganglion of the trigeminal nerve (see Box 11.1). Recurrent infection may

Key points – Pathology of HSV infection

- infection of epithelial cells
- replication of viral particles results in cytopathic changes in infected cells
- degeneration and rupture of infected cells results in intraepithelial vesicles
- rupture of cells releases new viral particles
- in addition to infecting adjacent epithelial cells, virus gains access to axons of sensory nerves

Box 11.1 Latency of HSV

- Latency is a characteristic property of the herpes viruses.
- During the primary infection HSV gains access to sensory neurons and viral DNA is transported to the trigeminal ganglion.
- In the ganglion transcription of HSV DNA is blocked, resulting in latency. This balance between the host and the virus is probably related to cell-mediated immunity.
- Factors which impair the host's immune response disturb the balance, allowing transcription of HSV DNA until the balance is restored.
- Viral particles travel down the axons to the nerve endings where they may be shed asymptotically into the mouth or reinfect epithelial cells.
- Damage to epithelial cells, e.g. trauma/UV radiation, may favour reinfection.
- Immunity to HSV does not protect against recurrent infection, but constitutional symptoms are absent/minimal.

Key points – Recurrent HSV

- reactivation of latent virus in the trigeminal sensory ganglion
- triggered by a variety of factors that may impair host defences
- recurrent herpes labialis is the most common clinical manifestation
- usually a minor local problem in immunocompetent patients
- in immunocompromised patients recurrences may be severe and intractable

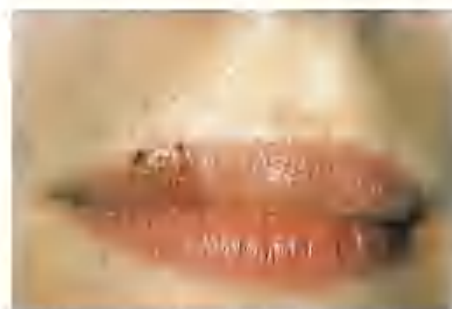

Fig. 11.6 Recurrent herpes labialis.

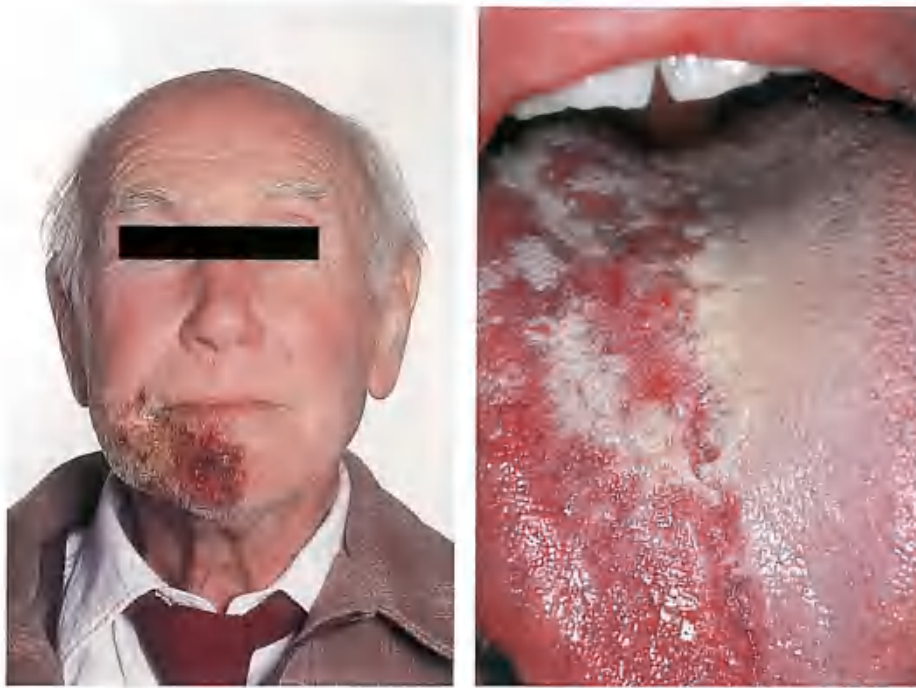result in asymptomatic shedding of HSV into the oral cavity or in local symptoms. Systemic symptoms are usually absent because of the immunity acquired during the primary infection. Herpes labialis is the most frequent type of recurrent infection (Fig. 11.6), and appears as clusters of vesicles on the lips and adjacent skin a few hours after prodromal symptoms of itching or tingling. The vesicles rupture within a short time and become crusted. They usually heal within a week. Recurrences may be brought on by a number of different stimuli, including mild febrile infections such as the common cold, ultraviolet light, mechanical trauma, menstruation, stress, and immunosuppression. Recurrent intraoral lesions occur occasionally, almost always on the hard palate or gingiva.

Chickenpox and herpes zoster (shingles)

Both chickenpox and herpes zoster are caused by the same virus, the varicella-zoster virus (VZV), which is another member of the herpesviruses.

The lesions of chickenpox may be found on the oral mucosa, especially the soft palate and fauces, and may precede the characteristic skin rash. The oral lesions usually present as small ulcers. Intact vesicles are seldom seen but when examined histologically show cytopathic effects indistinguishable from those of herpes simplex. Zoster is the manifestation of recurrent infection following a primary attack of chickenpox, and in this respect is similar to recurrent herpes simplex infection except that repeated attacks of zoster are unusual.

Following infection by chickenpox, the virus remains latent in the sensory ganglia probably for the remainder of the life of the host. Reactivation of the virus to cause zoster is uncommon but may occur apparently spontaneously or when the host defences are depressed. Severe infection may be seen in immunocompromised patients. The lesions are localized to the distribution of one or more sensory nerves. The characteristic unilateral vesicular eruption is frequently preceded by prodromal symptoms of pain and paraesthesia for up to two weeks. When the trigeminal nerve is involved the first division (ophthalmic) is most frequently affected. Involvement of the second or third division causes facial pain and the patient may complain of toothache, followed by the development of vesicles in the distribution of one or more branches of the trigeminal nerve (Figs 11.7, 11.8). The vesicles may be entirely intraoral where they rapidly ulcerate and become



Figs 11.7 and 11.8 Herpes zoster involving the mandibular division of the trigeminal nerve. The skin shows recently ruptured, crusted vesicles. The tongue shows a later stage with healing ulcers.

secondarily infected. The disease usually runs a course of about 14 days. The most distressing complication of zoster is post-herpetic neuralgia, probably caused by fibrosis in and around the sensory nerves and ganglia. Although zoster involves sensory nerves it occasionally presents with lower motor neurone-type facial paralysis as the Ramsay–Hunt syndrome. The syndrome is due to extension of primary involvement of the geniculate ganglion to affect the facial nerve.

Herpangina

This infection is caused by various types of coxsackievirus A. Coxsackieviruses are RNA viruses.

The infection is seen most commonly in children and is characterized, clinically, by the sudden onset of a mild illness with fever, anorexia, dysphagia, and sore throat. Vesicles, which rapidly break down into ulcers 1–2 mm in diameter, are seen on the tonsils, soft palate, and uvula (Fig. 11.9). The symptoms persist

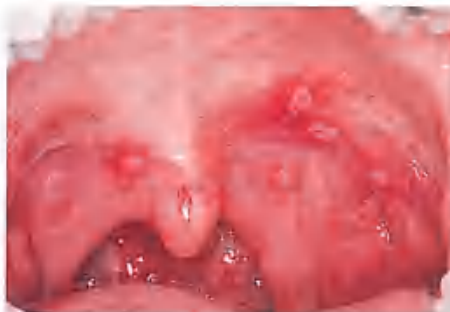

Fig. 11.9 Herpangina.

for 2–3 days only. Clinically, it may be difficult to distinguish from acute primary herpes. However, the latter is a gingivostomatitis, whereas herpangina is an oropharyngitis.

Hand, foot, and mouth disease

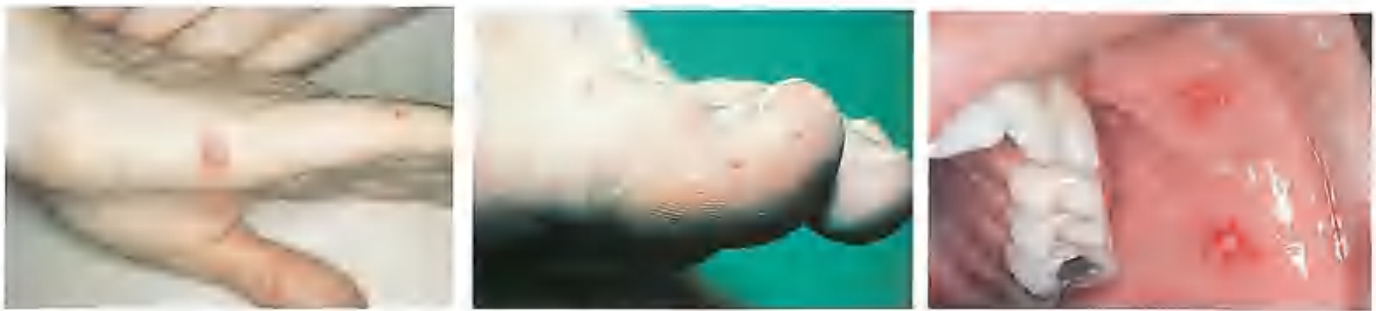This infection is also caused by various types of coxsackievirus A, especially type 16. It occurs predominantly in children and is transmitted in conditions of close association such as within households. The disease is characterized by shallow, painful oral ulcers together with vesicles and ulcers on the hands and feet (Figs 11.10–11.12). It usually lasts about 7–10 days.

Infectious mononucleosis (glandular fever)

This infection is caused by the Epstein–Barr virus (EBV), a member of the herpes group. It occurs predominantly in teenagers and young adults and is transmitted by contact with saliva, especially by kissing, either from an infected patient or a healthy carrier.

The disease is characterized by lymph node enlargement, fever, and inflammation of the pharynx, and may be associated with prolonged periods of malaise lasting months or more. Petechial haemorrhages at the junction of the soft and hard palate and inflammation and ulceration of the oral mucosa may be seen, but the oral changes are non-specific. Cases have also been reported presenting as pericoronitis.

As discussed in previous chapters, EBV is associated with Burkitt's lymphoma and has also been detected in oral squamous cell carcinoma. It is also the cause of hairy leukoplakia which is discussed later in this chapter.



Figs 11.10, 11.11, and 11.12 Hand, foot, and mouth disease.

Measles

This infection occurs predominantly in children, and in developed countries is usually a mild disease with low mortality. In other countries the mortality is high. Prodromal symptoms may resemble a common cold and are accompanied by the appearance of Koplik's spots on the oral mucosa, especially the buccal mucosa opposite the molar teeth. They present as pin-point bluish-white spots against an erythematous background, and range from few in number to several hundred. They are likely to be overlooked, particularly as they start to disappear as the characteristic skin rash develops some 3–4 days later.

In parts of West Africa, noma (cancrum oris), discussed later in this chapter, may occur as a complication of measles in malnourished patients.

Cytomegalovirus (CMV)

Cytomegalovirus (CMV) is a herpes group virus that rarely causes disease in immunocompetent individuals but which is an important pathogen in immunocompromised hosts, for example AIDS patients and organ transplant patients. However, subclinical infection is common, affecting 40–80 per cent of adults. Previously uninfected transplant patients may acquire the virus from the transplanted organ or transfused blood.

The most common oral manifestation is non-specific oral ulceration. CMV infection of salivary glands is also common but usually asymptomatic (see Chapter 14). However, it has been reported that the virus is strongly associated with the xerostomia seen in AIDS patients.

Bacterial infections

It is surprising how few specific bacterial infections of the oral mucosa occur in view of the enormous number of bacteria and the wide range of species (including pathogens) normally present in the oral cavity. This is a reflection of the normal defence mechanisms operating in the mouth. These include the barrier function of the oral epithelium, the mechanical cleansing action and the specific and non-specific antimicrobial substances in saliva, and the migration of phagocytic cells, predominantly neutrophils, into the gingival crevice and oral cavity.

Necrotizing ulcerative gingivitis (NUG) (acute ulcerative gingivitis, acute necrotizing ulcerative gingivitis (AUG, ANUG))

This condition is now relatively uncommon in industrialized countries, although there has been a global increase associated with HIV infection. In industrialized countries the disease occurs mostly in young adults and is more common in males than females, but in developing countries it is seen almost exclusively in children, related to poverty and malnutrition.

The infection presents with necrosis and crater-like, punched-out ulceration of the interdental papillae of sudden onset which may also involve the gingival margins (Fig. 11.13). The ulcers are covered with a greyish-green pseudomembrane demarcated from the surrounding mucosa by a linear erythema. Other signs and symptoms include gingival bleeding, either spontaneously or on minor trauma, pain or soreness of the gums, marked halitosis, a bad taste often described as metallic, and increased salivation. Malaise, cervical lymphadenopathy, and fever may be present in advanced cases. There is a high recurrence rate of infection unless underlying predisposing factors are adequately treated.

The pseudomembrane consists of necrotic tissue debris, inflammatory exudate, and bacteria. Gram-stained smears of the pseudomembrane show a multiplicity of organisms (Fig. 11.14) with a great preponderance of spirochetes, pleomorphic rods, and fusiform organisms (the fusospirochaetal complex) (Table 11.2).

Key points – NUG

- polymicrobial, endogenous infection
- decreased host resistance/immune response disturbs host–parasite relationship
- overgrowth of associated endogenous flora – the fusospirochaetal complex
- punched-out necrotic ulcers at the tips of the interdental papillae spreading to involve the gingival margins

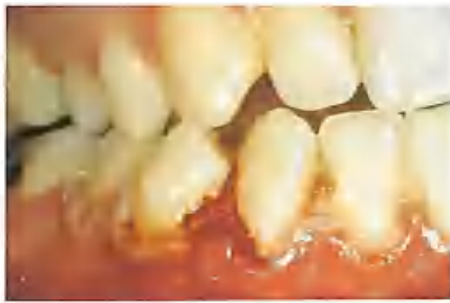

Fig. 11.13 Necrotizing ulcerative gingivitis.

Table 11.2 Microorganisms implicated in necrotizing ulcerative gingivitis

<i>Treponema</i> species for example	<i>T. vincentii</i>
<i>Prevotella</i> species for example	<i>P. intermedia</i>
<i>Porphyromonas</i> species for example	<i>P. gingivalis</i>
<i>Selenomonas</i> species for example	<i>S. sputigena</i>
<i>Fusobacterium</i> species for example	<i>F. fusiformis</i>

Superficial bacterial invasion of the tissues has also been demonstrated by electron microscopy. The precise role of the various types of bacteria is unclear, but the disease is usually regarded as an endogenous, opportunistic polymicrobial infection.

It is likely that a variety of factors may disturb the normal symbiotic host-parasite relationship, facilitating overgrowth of the organisms of the fusospirochaetal complex. These include a variety of inter-related factors that can decrease host resistance and immune responses at a local or general level, pre-existing chronic gingivitis, and trauma (Fig. 11.15).

A persistent form of necrotizing gingivitis is associated with HIV infection (see later) and NUG is an important factor in the development of noma.

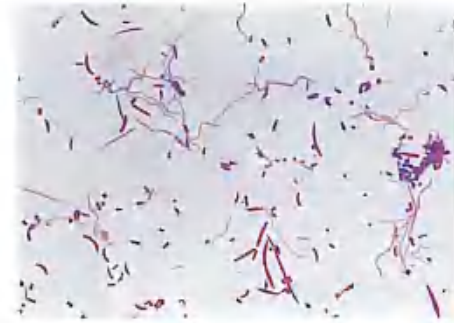


Fig. 11.14 Fusospirochaetal complex in necrotizing ulcerative gingivitis.

Noma (cancrum oris)

Noma is a severe, rapidly developing gangrene of the orofacial tissues and jaws that occurs almost exclusively in developing countries, especially sub-Saharan Africa. The majority of cases are preceded by NUG, followed by rapid spread of necrosis from the original gingival lesions into the cheek and development of an area of demarcated gangrene of the orofacial tissues (Fig. 11.16). Almost all cases of noma appear to develop in malnourished children whose resistance has been lowered still further by intercurrent infection such as measles or malaria. The microbiological features are similar to NUG but *Fusobacterium necrophorum* and *Prevotella intermedia* are considered to be key organisms.

Actinomycosis

Actinomycosis is a chronic, suppurative, polymicrobial infection caused by endogenous bacteria, amongst which *Actinomyces* species, especially *Actinomyces israelii*, predominate. *Actinomyces* are anaerobic bacteria. In actinomycosis other anaerobic bacteria act synergistically, creating conditions suitable for the growth of *Actinomyces* species as well as contributing to tissue injury.

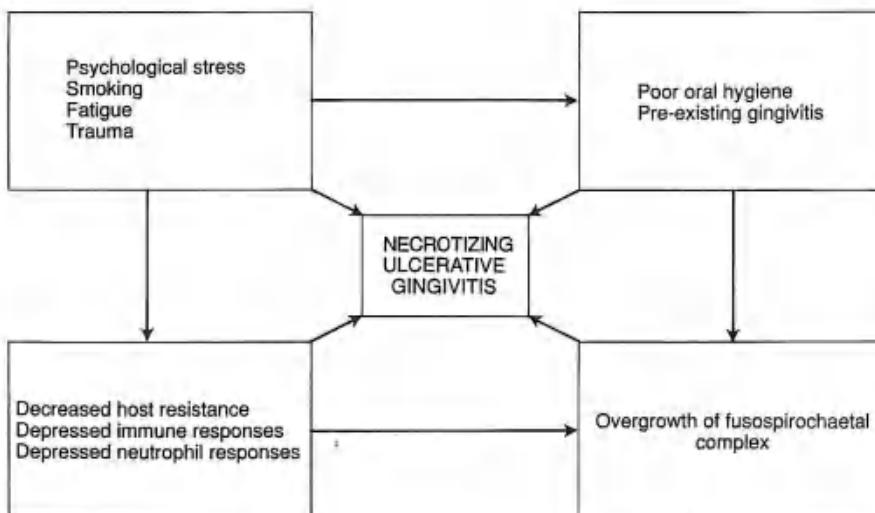


Fig. 11.15 Factors involved in the aetiology of necrotizing ulcerative gingivitis.

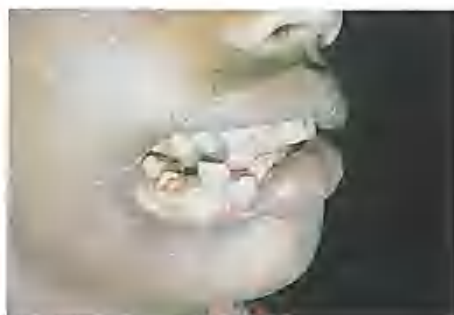


Fig. 11.16 Noma (cancrum oris).

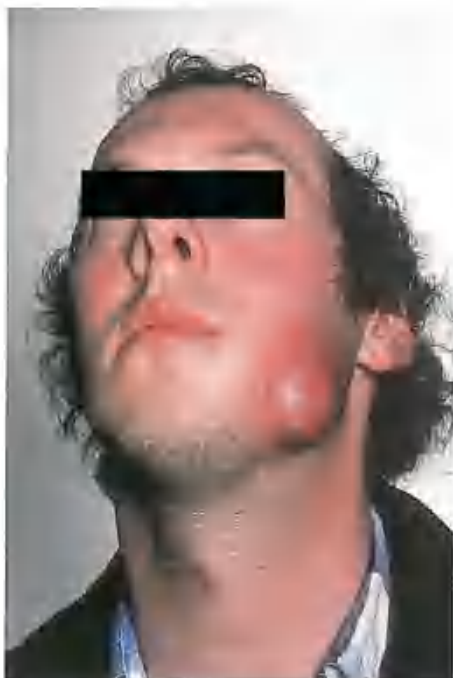

Fig. 11.17 Actinomycosis.

The soft tissues of the submandibular area and neck are most commonly involved in cervicofacial actinomycosis. The infection is characterized by multiple foci of chronic suppuration. It presents with the development of firm swellings which eventually soften and are accompanied by the formation of pus which discharges through multiple sinuses (Fig. 11.17). Pain is variable and the swellings are often painless. The multiple abscesses which eventually form tend to point on to the skin rather than the mucosal surface and are accompanied by marked fibrosis of the surrounding tissues. Infection is endogenous, and either a tooth socket, most commonly a lower third molar, or an infected root canal are thought to be the portals of entry.

Actinomycotic lesions develop as areas of granulomatous inflammation surrounded by abundant granulation tissue and fibrous tissue. Fresh foci of infection develop adjacent to the primary site following transport of some of the organisms by phagocytic cells, and a central area of suppurative necrosis

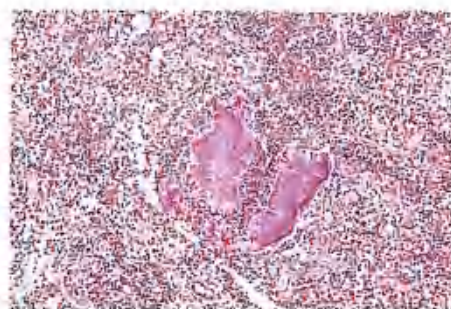


Fig. 11.18 Colony of actinomycetes in pus.

eventually develops in most of these foci. Granules consisting of tangled meshes of Gram-positive filaments of actinomycetes with radiating filaments projecting on the surface are present (Fig. 11.18) and may be seen clinically as 'sulphur granules' in pus from actinomycotic lesions.

Syphilis (primary, secondary, tertiary, congenital)

Syphilis is an infection caused by the spirochaete *Treponema pallidum*. The incidence in Western countries has now declined significantly. The primary lesion (chancre) usually occurs on the genitalia, but in a minority of patients may present on the oral mucosa, usually the lips. It appears as a shallow, painless ulcer with an indurated base. The regional lymph nodes are also enlarged. Histologically, the chancre consists of ulcerated granulation tissue with a dense mononuclear inflammatory cell infiltrate chiefly composed of plasma cells. It heals spontaneously within a 3–6 week period.

The signs and symptoms of secondary syphilis develop about 6 weeks after the appearance of the primary chancre, some 2–3 months after the initial exposure. A generalized skin rash is the predominant feature and may be accompanied by oral lesions of which the so-called mucous patch is the most frequent. 'Mucous patches' are flat areas of ulceration. They are usually multiple and may coalesce to produce lesions of irregular outline called 'snail-track ulcers'.

Tertiary or late-stage syphilis may develop many years after the initial exposure. Gummas (areas of necrosis associated with delayed (type IV) hypersensitivity reactions to syphilitic antigens) may occur, especially on the hard palate, leading to perforation into the nasal cavity (Fig. 11.19). Histologically, a gumma consists of a central mass of coagulative necrosis surrounded by granulation tissue infiltrated by lymphocytes, plasma cells, and macrophages with occasional giant cells. Spirochaetes are very scanty or absent.

Endarteritis obliterans is thought to be the cause of the atrophic glossitis which is also a feature of tertiary syphilis, the smooth surface of the tongue being broken up by fissures resulting from atrophy and fibrosis of the tongue musculature. Hyperkeratosis (syphilitic leukoplakia) (Fig. 11.20) frequently

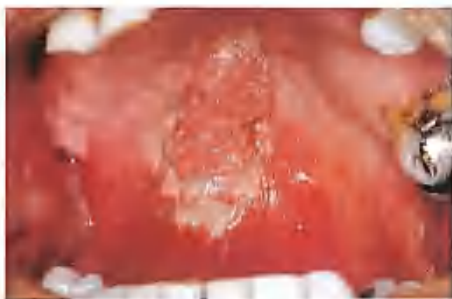


Fig. 11.19 Syphilitic gumma.

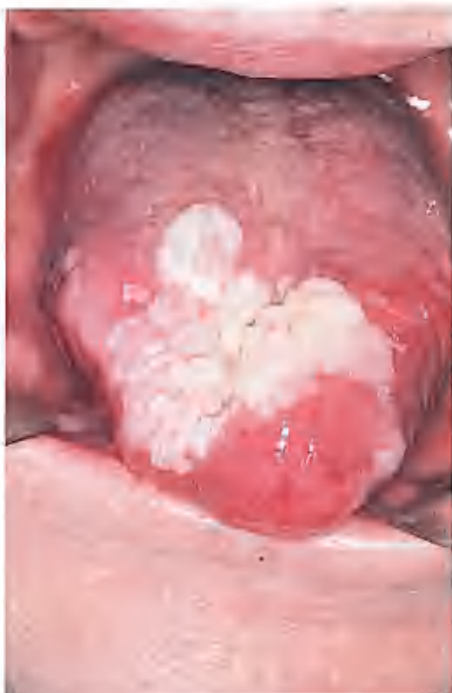

Fig. 11.20 Syphilitic leukoplakia.

follows, and carcinoma of the tongue develops with far greater frequency than coincidence would permit. However, tertiary syphilis is now a rare factor in the aetiology of oral cancer (see Chapter 10).

Congenital syphilis is now rare in affluent countries but in some community groups, such as drug abusers or those with lack of prenatal care, including some of the poorer countries of the world, it is still an important cause of miscarriage, stillbirth, or neonatal infection.

Congenital syphilitic infection is associated with infection of the developing tooth germs of the permanent incisors (Hutchinson's incisors) (Fig. 11.21) and first molars (Moon's molars or mulberry molars). The maxillary central incisors are most frequently involved and are characterized by central notching of the incisal edge and a tapering 'screwdriver' appearance. Mulberry molars, usually the first permanent molars, are characterized by hypoplastic defects of the occlusal surface and defective cusp develop-

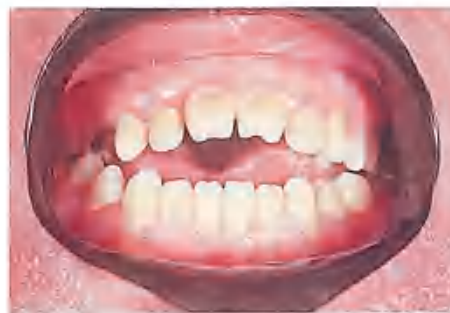

Fig. 11.21 Hutchinson's incisors.

ment with rounded, globular masses of hard tissue producing their mulberry appearance.

Collapse of the bridge of the nose, due to infection and destruction of the developing nasal bones, produces the characteristic saddle deformity of the bridge and the 'dished' appearance of the face.

Tuberculosis

Tuberculosis is an infection caused by mycobacteria, usually *Mycobacterium tuberculosis*, but *M. bovis* and other atypical mycobacteria may also cause disease in man.

Globally, about 8 million people develop tuberculosis each year but oral infection is uncommon. Primary lesions of the oral mucosa may occur, but secondary infections associated with the coughing-up of infected sputum from pulmonary tuberculosis are more likely. A chronic, painless undermined ulcer covered with a greyish-yellow slough occurring most commonly on the tongue is the classical description of oral tuberculosis, but other types of ulcer and granulating gingival lesions have also been described.

Key points – Granulomatous infections

- Actinomycosis
 - endogenous polymicrobial infection
 - submandibular swellings
 - chronic suppuration; multiple sinuses
 - 'sulphur' granules in pus
- Syphilis
 - primary: chancre
 - secondary: snail-track ulcers, mucous patches
 - tertiary: gumma, lingual leukoplakia
 - congenital: dental anomalies, 'dished' face
- Tuberculosis
 - oral usually secondary to pulmonary
 - painless, chronic lingual ulcer
- Leprosy
 - oral lesions in lepromatous type
 - secondary to nasal involvement
 - nodular masses palate/anterior maxilla

Patients may also present with tuberculous lymphadenitis, most frequently affecting the cervical nodes, but the intra- and extra-parotid groups are occasionally involved.

Diagnosis usually follows a biopsy, and the finding of typical tuberculoid granulomas, but tubercle bacilli must be demonstrated either in stained sections or by culture of the tissue before the diagnosis can be established.

Leprosy

Leprosy is another infection caused by a mycobacterium, *Mycobacterium leprae*. It is rare in Northern Europe and America but endemic to certain tropical areas. Two forms of infection exist depending on the immune response of the host to the organism. In the lepromatous type there is widespread infection throughout the body, whilst in the tuberculoid type the infection remains localized.

Oral lesions occur almost exclusively in the lepromatous type and have been reported in about 50 per cent of patients. They present as nodular inflammatory masses which tend to ulcerate and heal with fibrosis. The hard and soft palates, anterior gingivae in the maxilla, and the tongue are most often affected. Oral lesions are usually secondary to nasal involvement.

Patients with lepromatous leprosy may show varying degrees of facial deformity associated with bone lesions, particularly of the nasomaxillary complex.

Gonorrhoea

Gonorrhoea is a venereal disease caused by *Neisseria gonorrhoea*. Although the oral mucosa is considered to be highly resistant to gonococcal infection, tonsillar and oropharyngeal lesions have been reported in sexually active adults, particularly homosexuals. The oral manifestations vary from a generalized painful erythematous stomatitis to vesiculation and ulceration associated with burning and pain on speaking and swallowing. Lesions have been reported from all areas of the mucosa.

Fungal infections

Candida species and opportunistic infection

The fungal infections of the oral mucosa most frequently encountered are those due to species of the genus *Candida*. *Candida albicans* is the principal species associated with infection, but other species such as *C. glabrata*, *C. tropicalis*, *C. krusei*, and *C. parapsilosis* are also pathogenic for man. Most *Candida* species are dimorphic and exist as ovoid yeast forms or hyphae. They multiply primarily by the production of buds from ovoid yeast cells.

Candida species, principally *C. albicans*, are commensal organisms in the mouth of about 40 per cent of the population. Carriage rates are increased in the presence of systemic disease, and in pregnancy, tobacco smokers, and denture wearers. In children the peak carriage, about 45 per cent, occurs during the first 18 months of life. The primary oral reservoir for the organism in carriers is the dorsum of the tongue. There is an overlap in the candidal

Key points – *Candida* species and infection

- commensal organisms; posterior dorsum of tongue is main reservoir
- carriage rates vary; about 40 per cent of population
- opportunistic pathogens
- predisposing factors disturb balance between host and organism
- most predisposing factors result in suppression of host immune response
- *C. albicans* is the most common pathogenic species

Table 11.3 Factors predisposing to oral candidal infection

Local factors
Mucosal trauma
Denture (appliance) wearing
Denture (appliance) hygiene
Tobacco smoking
Carbohydrate-rich diet
Age
Extremes of age:
neonates/infants; old age
Drugs
Broad-spectrum antibiotics
Steroids, local/systemic
Immunosuppressant/cytotoxic agents
Xerostomia
Drugs, radiotherapy
Sjögren syndrome
Systemic disease
Iron deficiency; iron-deficiency anaemia
Megaloblastic anaemias
Acute leukaemia
Other malignant disease
Diabetes mellitus
HIV infection and AIDS
Other immunodeficiency states

counts in saliva from carriers and from individuals showing infection, and so isolation of *Candida* from the mouth of an adult is not confirmatory evidence of infection and must be considered together with the clinical findings. It is often presumed that *Candida* has a direct aetiological relationship with a lesion if hyphae are present in smears or in histological sections of the lesion, the presence of yeasts alone not being regarded as confirmatory evidence.

Candida species are notorious opportunistic pathogens whenever the balance between the host and the organism is disturbed. Both local and systemic factors are important in the pathogenesis of candidal infections (Table 11.3). They act by altering the homeostatic mechanisms which maintain the host-organism balance, and the defence mechanisms of the oral cavity in health.

Non-specific and specific factors are involved in protection of the oral mucosa from candidal infection. Non-specific factors include shedding of epithelial cells, salivary flow, antimicrobial factors in saliva, commensal bacteria, and the phagocytic activity of neutrophils and macrophages.

Specific antibodies to *Candida* are present in the sera of most individuals, but secretory immunity is probably more important than systemic immunity in protection of the oral mucosa. For example, secretory IgA levels in saliva are raised in patients with oral candidosis and may inhibit adherence of the organisms to oral epithelium. There is considerable evidence that cell-mediated immune responses are impaired in patients with candidal infection, particularly in chronic candidoses. Many of the predisposing factors associated with drugs and systemic disease may act by suppressing the host's immune response, leading to varying degrees of immunocompromise.

The mechanisms by which *Candida* species exert a pathological effect on the tissues are not fully understood. However, they can secrete a variety of enzymes such as proteinases and phospholipases and it is likely that these enable the hyphae to invade the oral epithelium. In addition, they can produce nitrosamine compounds which may play a role in oral carcinogenesis (see Chapter 10). Candidal antigens may also induce a delayed hypersensitivity reaction, leading to tissue injury. In addition to these factors the organism must be able to adhere to epithelial cells for colonization, carriage, and the development of infection. A number of mechanisms involving surface proteins have been identified.

Classification of oral and perioral candidosis

A variety of candidal infections involve the oral mucosa and perioral tissues and a number of classifications have been proposed. However, most share similar features in that they distinguish between acute and chronic infections and between infections confined to the oral and perioral tissues, and those where oral infection is a manifestation of a generalized systemic candidosis. In addition, *Candida* may be found in association with other mucosal lesions, for example median rhomboid glossitis, where a causal relationship has not been fully established.

The classification of candidal infections used in this chapter is given in Table 11.4.

Oral candidal infection is an almost universal finding in patients with severe cell-mediated (T cell) immunodeficiencies, particularly in patients suffering from HIV infection. The types of infection seen in these patients tend to be very protracted, lasting several months in some cases. For example, as discussed later in this chapter, chronic pseudomembranous and chronic erythematous candidoses are seen in patients with HIV infection.

Pseudomembranous candidosis (acute and chronic)

Pseudomembranous candidosis (commonly referred to as thrush) is usually an acute infection but persistent infection may be seen

Table 11.4 Classification of oral candidosis

<i>Group 1: Primary oral candidoses – candidoses confined to the oral mucosa</i>	
Acute	
Pseudomembranous (thrush)	
Erythematous (atrophic)	
Chronic	
Pseudomembranous	(protracted forms of the above seen in immunocompromised host)
Erythematous	
Hyperplastic (candidal leukoplakia)	
<i>Candida-associated lesions</i>	
Denture stomatitis	
Angular cheilitis	
Median rhomboid glossitis	
<i>Group 2: Secondary oral candidoses – manifestations of generalized candidoses</i>	
Systemic mucocutaneous candidoses (hereditary and sporadic types associated with systemic disorders, e.g. endocrine disorders, immunodeficiency states)	

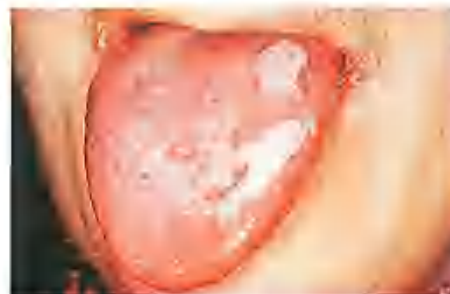

Fig. 11.22 Pseudomembranous candidosis in a debilitated elderly patient.

in immunocompromised hosts, in which case it is described as chronic. The signs and symptoms of acute and chronic types are essentially the same; the duration is the distinguishing feature. Thrush also occurs in up to 5 per cent of newborn infants, when it is probably associated with immature antimicrobial defences, *Candida* being picked up from the birth canal. The infection is also seen in about 10 per cent of elderly debilitated patients. As for any patient with candidal infection it is important to identify underlying predisposing factors (see Table 11.3).

The disease presents clinically as a thick white coating (the pseudomembrane) on the affected mucosa, said to resemble milk curds (Figs 11.22, 11.23) which can be wiped away (albeit with difficulty in some cases) to leave a red, raw, and often bleeding base. Lesions may occur on any mucosal surface of the mouth and vary in size from small drop-like areas to confluent plaques covering a wide area.

The pseudomembranous plaque consists of the superficial necrotic and desquamating parakeratotic layers of the epithelium infiltrated by candidal hyphae and yeasts, and by an acute inflammatory exudate with abundant neutrophils and fibrin. Examina-

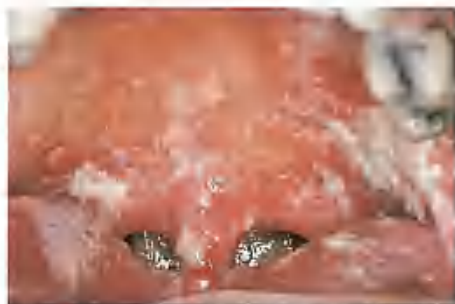

Fig. 11.23 Pseudomembranous candidosis associated with use of steroid inhaler in an asthmatic patient.

tion of appropriately stained smears of the pseudomembrane reveals the epithelial and inflammatory debris matted together by candidal hyphae and yeasts, and may be useful in some cases in establishing the diagnosis (Fig. 11.24).

Erythematous candidosis (acute and chronic)

Erythematous candidosis is usually an acute infection but, as for pseudomembranous candidosis, chronic infection may occur. It is seen most commonly on the dorsum of the tongue in patients undergoing prolonged corticosteroid or antibiotic therapy, but it may develop after only a few days of topical application of an antibiotic. Antibiotic therapy alters the oral bacterial flora allowing resistant organisms, such as *Candida*, to flourish, and the condition is sometimes referred to as antibiotic sore tongue. It presents as a red and often painful area of oral mucosa, most commonly on the dorsum of the tongue, which may also appear depapillated (previously the condition was referred to as acute atrophic candidosis). The palate is also often involved.

Chronic hyperplastic candidosis (candidal leukoplakia)

This form of candidosis (commonly referred to as candidal leukoplakia) presents clinically as a persistent white patch on the oral

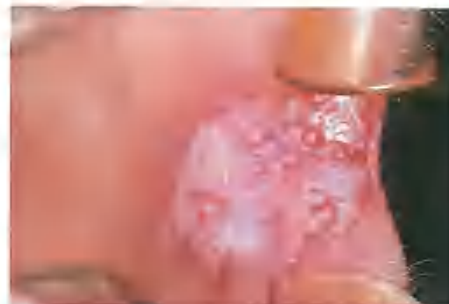

Fig. 11.25 Chronic hyperplastic candidosis.

mucosa which is indistinguishable from leukoplakia. Characteristically, the lesions present as dense, opaque white patches of irregular thickness and density with a rough or nodular surface. They cannot be removed by scraping. In some cases, areas of erythematous mucosa are present within the plaque producing a speckled leukoplakia (Fig. 11.25). Lesions are seen most frequently on the buccal mucosa adjacent to the commissure of the lips and present as roughly triangular, often bilateral white plaques tapering posteriorly. They are often associated with angular cheilitis. Less frequently, the palate or tongue may be involved and when multiple sites are affected the term 'chronic multifocal oral candidosis' is sometimes applied. In many patients there is a strong association with tobacco smoking. Other local factors, such as denture wearing and occlusal friction, may also be involved.

Histologically, the epithelium shows hyperparakeratosis and prominent, irregular acanthosis (Fig. 11.26). Many of the cells in the parakeratinized surface of the epithelium are separated by oedema and numerous neutrophil leucocytes, the neutrophils often collecting together as microabscesses (Fig. 11.27). Candidal hyphae invade the parakeratin more or less at right angles to the surface, but never penetrate deeper into the prickle cell layers (Fig. 11.28). A variable number of acute and chronic inflammatory cells are present throughout the prickle cell layer and there is a mixed chronic inflammatory cell infiltrate, in which plasma cells

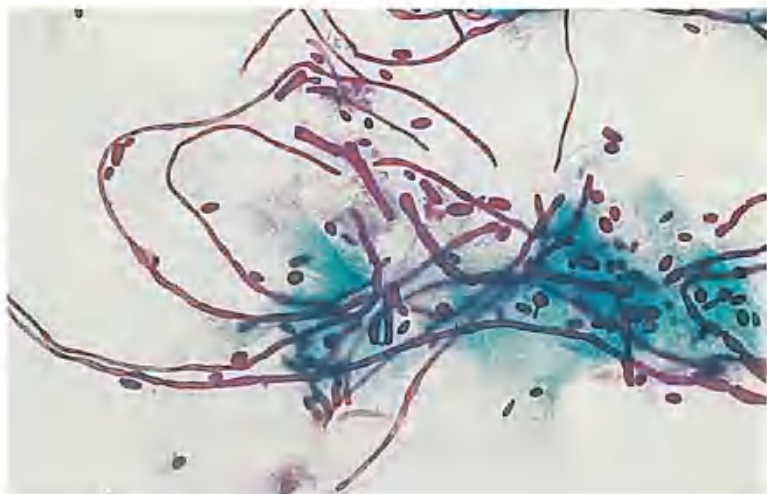


Fig. 11.24 Candidal hyphae and yeasts in smear from a patient with oral candidosis.

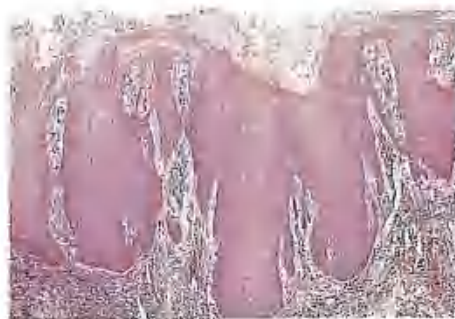

Fig. 11.26 Prominent acanthosis of the epithelium and chronic inflammatory cell infiltration of the lamina propria in chronic hyperplastic candidosis.

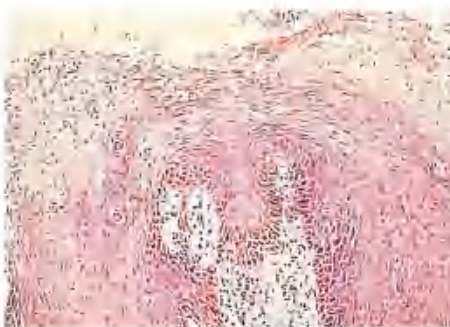


Fig. 11.27 Oedema and neutrophil infiltration of the parakeratin with superficial microabscess formation in chronic hyperplastic candidosis.




Fig. 11.28 Invasion of parakeratin by candidal hyphae in chronic hyperplastic candidosis.

are often prominent, in the lamina propria. Areas of atrophic epithelium may be present within the lesion and in these areas the superficial layers of candida-infected parakeratin may be missing. Focal absence of the infected parakeratin layer may be responsible for the speckled erythematous appearances seen clinically.

Chronic hyperplastic candidosis is considered to be a pre-malignant lesion. Varying degrees of cellular atypia which characterize epithelial dysplasia (see Chapter 9) are seen in about 50 per cent of cases. Although *Candida* species can generate carcinogens, such as nitrosamines, in some cases the cellular atypia resolves following treatment. In such cases the cellular atypia can be described as a reactive atypia, in response to irritation from candi-

dal products and the associated chronic inflammation. However, it has been estimated that about 15 per cent of cases progress to truly dysplastic lesions. As with idiopathic leukoplakia (see Chapter 9), the severity of the dysplasia is increased in speckled, non-homogeneous lesions.

It has not been conclusively shown whether chronic hyperplastic candidosis is primarily leukoplakia with a secondary candidal infection, or whether it is primarily a chronic candidal infection which in time leads to epithelial dysplasia. From 10 to 50 per cent of all leukoplakias in reported series may be infected by candidal species but only the minority show the characteristic histological features described above, which are common to other candidal infections. In addition, some lesions respond to antifungal therapy, supporting an aetiological role for *Candida* species.

Candida-associated denture stomatitis (chronic atrophic candidosis)

This common and usually symptomless condition was previously referred to as chronic atrophic candidosis. It is regarded as being a secondary candidal infection of tissues modified by the continual wearing of often ill-fitting dentures and is associated with poor denture hygiene. The condition is characterized clinically by chronic erythema and oedema of the mucosa directly covered by the denture, the affected mucosa being clearly delineated by the outline of the denture. The palate is almost invariably affected but it is very unusual to see lesions related to lower dentures, probably because they fit much less closely than upper dentures and so an environment favouring the overgrowth of *Candida* is not present. The condition may also occur under orthodontic appliances.

Clinically, three patterns of inflammation can be identified (Newton's classification):

- (1) pin-point areas of erythema – localized inflammation (Fig. 11.29);
- (2) diffuse areas of erythema – generalized inflammation;
- (3) erythema associated with a granular or multinodular mucosal surface (Fig. 11.30) – chronic inflammatory papillary hyperplasia (see Chapter 8).

The confined space between the mucosa and the upper denture, inadequate cleaning of the fitting surface, and wearing the



Fig. 11.29 Pin-point pattern of erythema in *Candida*-associated denture stomatitis.

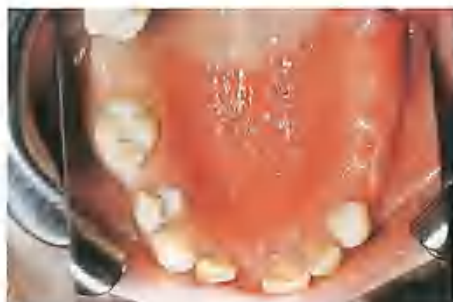

Fig. 11.30 *Candida*-associated denture stomatitis with diffuse erythema and papillary hyperplasia.

denture throughout the night all appear to favour the overgrowth of *Candida*, resulting in a local imbalance of the host–parasite relationship. A high-carbohydrate diet predisposes to infection. The fitting surface of the denture is the reservoir of infection and improved denture hygiene is key to the management of this condition, in order to avoid reinfection. *Candida* adheres readily to acrylic and microscopic irregularities on the fitting surface also provide a suitable environment for growth and retention of the organism. Invasion of epithelium by candidal mycelia is not a feature of this condition.

Candida-associated and other forms of angular cheilitis

Angular cheilitis is a multifactorial disease of infectious origin. It occurs predominantly in denture wearers and is seen in about 30 per cent of patients with denture stomatitis and less frequently with other types of oral candidosis. In patients with no evidence of candidal infection *Staphylococcus aureus* or, less frequently, beta-haemolytic streptococci may be involved. In some cases, combinations of these organisms are implicated.

Clinically, angular cheilitis is characterized by soreness, erythema, and fissuring at the corners of the mouth (Fig. 11.31). Deep folds of skin at the angles of the mouth, which may be associated with loss of occlusal height in old age or result from incorrectly designed or old dentures, may be contributory factors. The folds predispose to infection because of local maceration of the keratinized layers of the skin as a result of continual wetting by

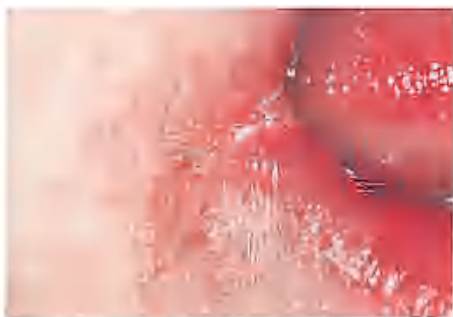


Fig. 11.31 *Candida*-associated angular cheilitis.

saliva. Nutritional deficiencies, in particular iron deficiency and deficiencies of riboflavin, folic acid, and of vitamin B₁₂, are predisposing factors in some cases.

Median rhomboid glossitis

This condition is characteristically located in the midline of the dorsal surface of the tongue, just anterior to the foramen caecum. The lesion is roughly rhomboidal in shape and is devoid of papillae. The surface appears reddish in colour and may be smooth, nodular, or fissured (Fig. 11.32). It is usually asymptomatic.

The pathogenesis of this condition is uncertain. For many years it was regarded as a developmental anomaly, and although this cannot definitely be excluded, in most cases it is associated with candidal infection. This suggests that the lesion represents a peculiarly localised form of chronic candidosis, although it is unlikely that the area will repapillate following antifungal therapy. The posterior dorsum of the tongue is the main reservoir of candida in the mouth and it is possible that local factors, such as trauma or variation in the surface anatomy, allow candidal hyphae to proliferate leading to infection of the superficial epithelial layers and development of the lesion. In some patients, usually smokers, an opposing ('kissing') lesion may be seen on the palate and the term 'multifocal candidosis' has been used to describe this.

Histologically, the area is devoid of lingual papillae and the surface is covered by parakeratotic acanthotic squamous epithelium. There is neutrophil infiltration of the parakeratin associated with infection by candidal hyphae, and chronic inflammatory cell infiltration of the lamina propria, often with fibrosis.

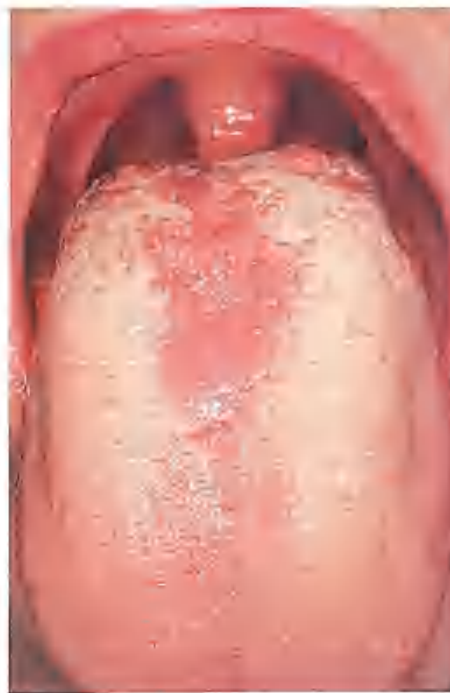

Fig. 11.32 Median rhomboid glossitis.

Key points – Candidal infections: clinical aspects

- pseudomembranous and chronic hyperplastic present as white lesions
- pseudomembrane can be wiped away; white patch of hyperplastic type is fixed
- pseudomembranous occurs anywhere in the mouth; hyperplastic typically involves commissures
- erythematous candidosis and denture stomatitis present as red patches
- erythematous involves mainly tongue; denture stomatitis virtually confined to palate
- erythematous usually sore; denture stomatitis usually symptomless
- angular cheilitis may be associated with denture stomatitis or chronic hyperplastic
- median rhomboid glossitis, a reddish smooth/nodular area anterior to foramen caecum

Key points – Candidal infections: pathological aspects

- mycelia invade the superficial parakeratinised layers except in denture stomatitis
- neutrophil infiltration and microabscess formation in parakeratinised layers except for denture stomatitis
- no mycelial invasion of epithelium in denture stomatitis; organism colonizes denture base
- prominent acanthosis in chronic hyperplastic
- epithelial dysplasia in chronic hyperplastic

Chronic mucocutaneous candidoses and oral manifestations of the deep visceral mycoses

The chronic mucocutaneous candidoses are a rare group of disorders characterized by persistent superficial candidal infections of mucosae, nails, and skin, the oral mucosa being involved in almost all cases (Fig. 11.33). Oral lesions resemble those seen in chronic hyperplastic candidosis and may involve any part of the mucosa (see Box 11.2).

The systemic or deep-seated visceral mycoses are rare outside endemic areas and are found mainly in South America and parts of the USA. Oral lesions are uncommon but may present as non-specific ulceration or as nodular granulomatous areas (see Box 11.2).

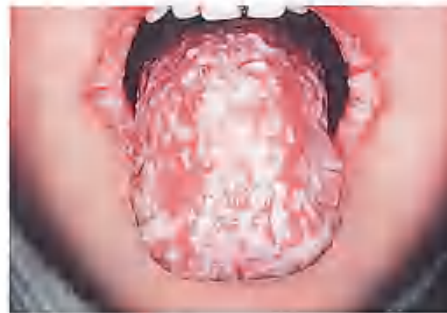

Fig. 11.33 Chronic mucocutaneous candidosis.

Box 11.2 Chronic mucocutaneous candidoses (CMC) and deep visceral mycoses

- Various subgroups of CMC are identified based on clinical features and age of onset.
- CMC may be inherited or acquired and may be associated with endocrine abnormalities or immunodeficiency.
- The five main subgroups are:
 - familial CMC: early onset, autosomal recessive, mild oral/skin lesions
 - diffuse CMC: early onset, autosomal recessive/sporadic, severe oral/skin lesions
 - candidosis endocrinopathy syndrome: early onset, autosomal recessive/sporadic, mild/moderate oral/skin lesions, hypoparathyroidism/other endocrine abnormalities
 - late-onset CMC: late onset, sporadic in patients with thymoma, mild skin/oral lesions
 - CMC associated with primary immunodeficiency: early onset, sporadic/hereditary, oral/skin involvement variable.
- Examples of the deep visceral mycoses which may be associated with oral lesions are:
 - blastomycosis: North American and South American types
 - coccidioidomycoses: Southwestern USA, Central and South America
 - histoplasmosis: worldwide, especially Central USA, Central and South America, Far East.

Human immunodeficiency virus (HIV) infection and AIDS

HIV is transmitted by the exchange of blood or body fluids principally through sexual contact (both homosexual and heterosexual), the injection of blood or blood products (for example

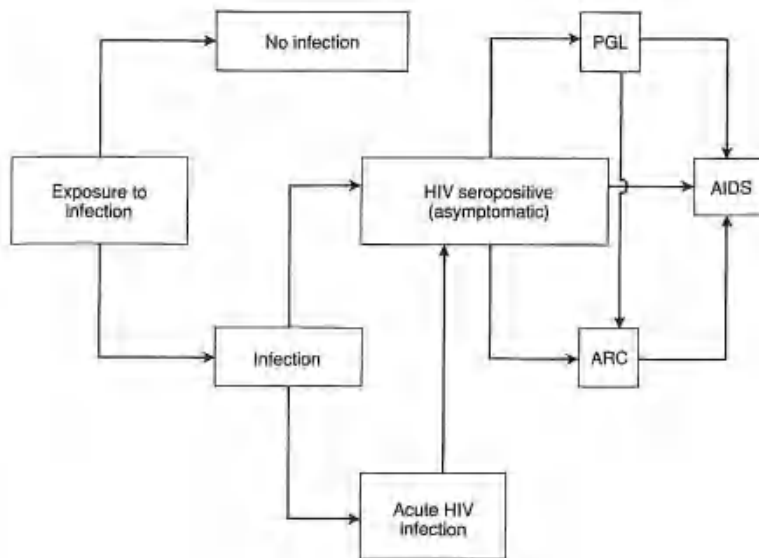


Fig. 11.34 Clinical responses to HIV.

intravenous drug abusers and haemophiliacs), or from mother to child (perinatal infection). Transmission of the virus may be followed by infection which is detected by the appearance of HIV antibodies in the blood (seroconversion). This generally occurs within three months of exposure. A few patients have an acute HIV infection at this time, the clinical features of which include pyrexia, skin rash, headache, diarrhoea, sore throat, and erythema of the buccal and palatal mucosa. The clinical responses to HIV infection are shown in Fig. 11.34.

Following seroconversion most patients remain symptom-free for many years (HIV seropositive), but in time may develop persistent generalized lymphadenopathy (PGL). In both PGL and asymptomatic HIV-seropositive patients there may then be progression to the AIDS-related complex (ARC) which is characterized by lymphadenopathy, persistent pyrexia, diarrhoea, weight loss, fatigue, and malaise. The final stage of infection is fully developed AIDS (acquired immune deficiency syndrome), characterized by opportunistic infections, Kaposi's sarcoma, and non-Hodgkin's lymphoma, but patients may also develop thrombocytopenia and neurological disease.

Infection by HIV involves the binding of the virus to many target cells, but binding to the CD4 receptor of T-helper lymphocytes plays a major role in the pathogenesis of HIV disease. In due course, infected T-helper cells die with a consequent reduction in the number of T-helper cells and a decrease in CD4 helper/CD8 suppressor cell ratios. The ability to mount a normal immune response is, therefore, impaired, particularly in response to T cell-dependent antigens such as viruses, fungi, and encapsulated bacteria, and this accounts for most of the clinical manifestations of the disease.

Oral manifestations of HIV infection

The oral manifestations of HIV infection are numerous and have been divided into three groups based on the strength of their asso-

ciation with HIV infection. The main lesions in each group are listed in Table 11.5. However, the prevalence of some of these lesions, particularly those associated with opportunistic infection, notably oral candidosis, hairy leukoplakia, Kaposi's sarcoma, and necrotizing periodontal disease, is now markedly reduced following the introduction of highly active antiretroviral therapy (HAART).

Oral candidosis

This is the most frequent oral manifestation of HIV infection. *Candida albicans* is the commonest cause but other species, including azole-resistant strains, are occasionally involved. The pseudomembranous and erythematous varieties are seen most frequently but, unlike their counterparts in non-HIV infected patients, they may persist for months. Pseudomembranous candidosis (Fig. 11.35) may involve any part of the oral mucosa but the palate, cheeks, lips, and dorsum of the tongue are most frequently affected. Erythematous candidosis (Fig. 11.36) presents as a red lesion, and most commonly affects the palate and dorsum of the tongue where it is also associated with loss of the filiform papillae and resembles median rhomboid glossitis. Hyperplastic candidosis is most frequently seen on the cheeks but the commissures are rarely involved, as is usually the case in HIV-seronegative patients. The prevalence of oral candidosis in HIV infection varies but is about 20 per cent in HIV-positive patients who have not developed AIDS compared to 70 per cent or more in those with AIDS. However, the prevalence is decreasing since the introduction of HAART.

HIV-associated periodontal diseases

HIV infection may be associated with atypical and sometimes severe periodontal diseases. The reported prevalence varies in different series but is generally less than 10 per cent and is

Table 11.5 Classification of oral lesions associated with HIV infection

<i>Group I: Lesions strongly associated with HIV infection</i>	
Candidosis	
Erythematous	
Hyperplastic	
Pseudomembranous	
Hairy leukoplakia (EBV)	
HIV-associated periodontal disease	
HIV-gingivitis	
Necrotizing ulcerative gingivitis	
HIV-periodontitis	
Necrotizing stomatitis	
Kaposi's sarcoma	
Non-Hodgkin's lymphoma	
<i>Group II: Lesions less commonly associated with HIV infection</i>	
Atypical ulceration (oropharyngeal)	
Idiopathic thrombocytopenic purpura	
Salivary gland disorders	
Dry mouth, decreased salivary flow rate	
Uni- or bilateral swelling of major glands	
Viral infections (other than EBV)	
Cytomegalovirus	
Herpes simplex virus	
Human papillomavirus	
Varicella-zoster virus	
<i>Group III: Lesions possibly associated with HIV infection</i>	
Bacterial infections other than gingivitis/periodontitis	
Fungal infection other than candidosis	
Melanotic hyperpigmentation	
Neurologic disturbances	
Facial palsy	
Trigeminal neuralgia	

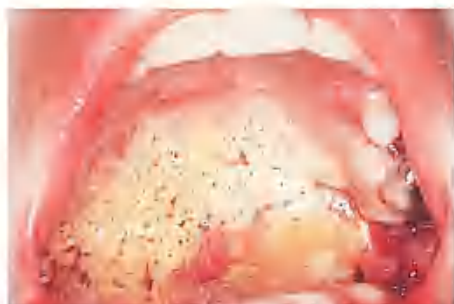

Fig. 11.35 Severe pseudomembranous candidosis associated with HIV.

decreasing since the introduction of HAART. Three main clinical types are recognized:

- (1) linear gingival erythema;
- (2) necrotizing ulcerative gingivitis (NUG);
- (3) necrotizing ulcerative periodontitis.

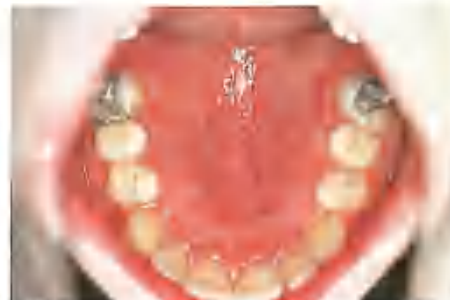

Fig. 11.36 Erythematous candidosis associated with HIV.

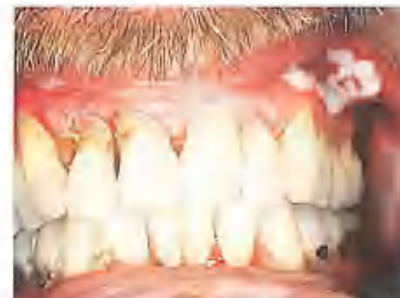

Fig. 11.37 HIV-associated periodontal disease (necrotizing ulcerative periodontitis) together with an area of pseudomembranous candidosis.

Linear gingival erythema presents as a red band involving the free gingival margins, but does not appear to be related to the accumulation of dental plaque. It may represent gingival hyperaemia due to the release of vasoactive cytokines rather than gingival inflammation. Necrotizing ulcerative periodontitis is a severe, rapidly destructive process resulting in necrosis of gingival and periodontal tissues, sometimes with necrosis, exposure, and sequestration of alveolar bone (Fig. 11.37). It is associated with severe impairment of local defence mechanisms, probably involving significant reductions in CD4-T cell activity and defective functioning of polymorph neutrophils. Necrotizing ulcerative gingivitis has been described earlier in this chapter but in HIV-positive patients the lesions may be persistent and extensive, and may not respond to conventional treatment.

Viral infections

Infections with herpes simplex and varicella-zoster viruses in association with HIV infection are more severe and extensive than when occurring in an HIV-seronegative patient, and frequently recur. Viral warts are often seen in the mouths of patients infected with HIV, and unusual types of HPV have been identified in some of these lesions. Disseminated CMV infection may be seen in AIDS, and EBV is the cause of hairy leukoplakia and may be associated with some lymphomas. Kaposi's sarcoma is associated with a herpesvirus. The prevalence of some of the lesions associated with viral infection, particularly hairy leukoplakia, has reduced significantly since the introduction of HAART. In contrast, the prevalence of oral warts has increased.

Hairy leukoplakia

Hairy leukoplakia (HL) presents as a white patch which cannot be removed. It occurs most frequently on the lateral borders of the tongue, bilaterally, but occasionally other areas of the oral mucosa are affected. The most characteristic lesions present as vertical white folds on the lateral border of the tongue with a raised, corrugated, or hairy surface (Fig. 11.38). However, the lesions may also have a smooth flat surface. Histological examination of HL typically shows acanthotic, parakeratinized epithelium (Fig. 11.39) often with long, finger-like surface projections of parakeratin producing the hairy or corrugated appearance seen clinically. Candidal hyphae may be present in the parakeratin, but the candidosis is a secondary rather than a causal infection. There is an absence of associated inflammatory cells both in the epithelium and in the lamina propria. Swollen or balloon cells with prominent cell boundaries are present as a band in the prickle cell layer beneath the parakeratin (Fig. 11.40). Some have small, darkly staining nuclei and perinuclear vacuoles. The swollen cells contain Epstein–Barr virus and have been described as koilocytes or koilocyte-like cells (Fig. 11.41). (Strictly, the term 'koilocyte' should be confined to cells infected with HPV.) Demonstration of EBV is essential to confirm the diagnosis.

HL is seen in HIV-infected patients from all risk groups, with a prevalence of about 20–25 per cent overall, which is reduced to about 12 per cent in patients taking HAART. However, the prevalence rate increases as the CD4-lymphocyte count falls and immunocompetence declines. It is common in patients with late-

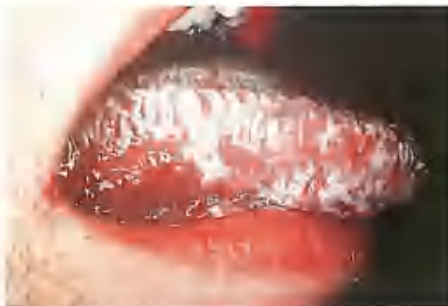

Fig. 11.38 HIV-associated hairy leukoplakia.

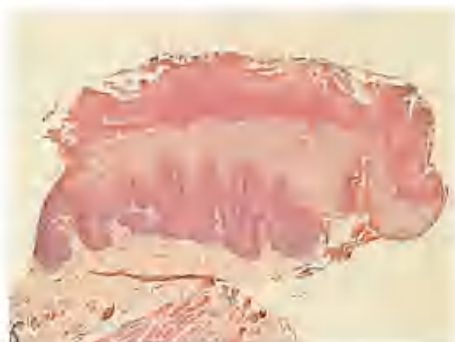


Fig. 11.39 Hairy leukoplakia showing hyperkeratosis and underlying balloon cells.

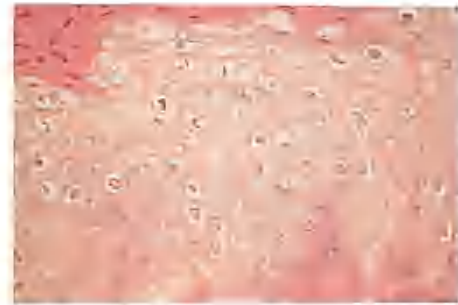


Fig. 11.40 Ballooned cells with perinuclear vacuoles in hairy leukoplakia.



Fig. 11.41 *In situ* DNA hybridization for Epstein–Barr virus showing positive signals (black) over nuclei in ballooned cells.

stage HIV infection and the development of HL may herald the onset of AIDS. HL also occurs in non-HIV-infected patients receiving immunosuppressive therapy (for example, renal or heart transplant patients) and a few rare cases have been reported in apparently healthy persons. There is no evidence that HL is a pre-malignant lesion. (Note that the term 'leukoplakia' is used in this context simply to mean 'white patch'. As discussed in Chapter 9, HL is distinct from leukoplakia as defined by the WHO.)

HL is caused by opportunistic infection of the oral epithelium by EBV, huge numbers of which are present in the swollen vacuolated cells seen on routine microscopy. A long-term carrier state for EBV usually follows natural infection, either subclinically or as glandular fever. Subsequently, in immunocompromised patients there may be continuous shedding of the virus into saliva (possibly from the oropharynx or salivary glands), leading to repeated direct infection of oral epithelial cells. Minor trauma to the tongue could allow access of EBV from saliva to receptors on the prickle cells. A marked reduction of Langerhans cells is also seen in HL lesions resulting in impaired antigen handling in the mucosa. This, together with the immunosuppression associated with HIV may allow enhanced viral replication within the epithelial cells.

Kaposi's sarcoma (KS)

Although KS is the commonest tumour associated with HIV infection its prevalence is low, particularly for patients on HAART. KS is more common in males than in females and in patients whose behaviour is associated with increased risk of

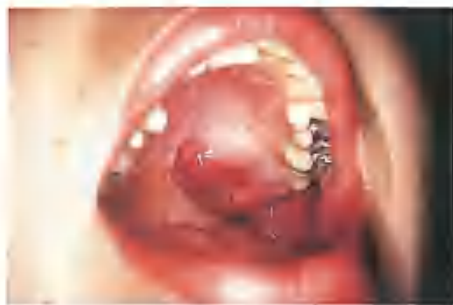

Fig. 11.42 Oral Kaposi's sarcoma associated with HIV.

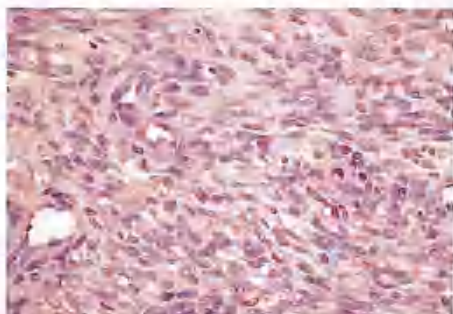


Fig. 11.43 Kaposi's sarcoma showing atypical spindle cells and vascular channels.

male-to-male transmission of HIV infection. KS is associated with infection by a herpesvirus referred to as KSHV or as human herpesvirus 8 (HHV8), which appears to have a causal role.

KS is a multifocal tumour involving skin and mucosal surfaces and presents first as reddish-purple patches which then become nodular. Oral lesions may be the presenting feature and are seen most frequently on the palate (Fig. 11.42), although other sites may be involved. The tip of the nose is the most frequent facial site.

Early lesions of KS consist of proliferating endothelial cells and atypical, often cleft-like, vascular channels together with extravasated erythrocytes, haemosiderin, and inflammatory cells. A few atypical spindle-shaped cells may be seen in the interstitial tissues. Distinction from granulation tissue and other vascular lesions such as haemangiomas and pyogenic granulomas may be difficult. However, in the later stages the vascular component decreases and the atypical spindle cells predominate (Fig. 11.43). There is no curative treatment, but the lesions may respond to radiotherapy or chemotherapy.

Non-Hodgkin's lymphoma (NHL)

An increased incidence of NHL is seen in AIDS patients (as in other groups of immunocompromised patients), and oral mucosal involvement has been described. Some of these lymphomas are associated with EBV.

Neurological disturbances

HIV is neurotropic and may directly involve the central nervous system leading, for example, to peripheral neuropathy or demen-

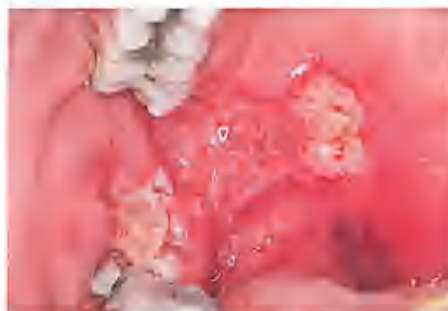

Fig. 11.44 Atypical oral ulceration associated with HIV.

tia. Facial nerve palsy may follow involvement of neurones in the central nervous system.

Atypical ulceration

Atypical ulceration (Fig. 11.44), particularly of the oropharynx, has been described in AIDS risk groups and may resemble aphthous stomatitis. Some may be associated with viral infection such as CMV.

Idiopathic thrombocytopenic purpura

Small purpuric lesions or larger areas of bruising may be seen on the oral mucosa, associated with thrombocytopenia resulting from an autoimmune response.

HIV-associated salivary gland disease

Xerostoma and salivary gland enlargement associated with lymphocytic infiltrates may occur in up to 10 per cent of adult patients with AIDS (see Chapter 14). Lymphoepithelial cysts may also arise.

Oral pigmentation

Melanin pigmentation of the oral mucosa has been described in patients with HIV, but whether this is directly related to the


Key points – HIV infection

- oral signs and symptoms may be the initial manifestation
- a wide variety of oral manifestations described
- opportunistic infections are a major feature
- the prevalence of opportunistic infection is decreased by HAART
- oral candidosis (pseudomembranous, erythematous types) is the most prevalent oral lesion
- HL may indicate progression to AIDS
- HL associated with EBV infection of oral epithelium
- severe, specifically related periodontal diseases occur in some patients
- KS associated with HSV8 infection; palate most common oral site

infection, or associated with drug therapy, or adrenal gland insufficiency has not been determined.

Further reading

- Axéll, T., Samaranayake, L. P., Reichert, P. A., and Olsen, I. (1997). A proposal for reclassification of oral candidosis. *Oral Surgery, Oral Medicine, Oral Pathology*, 84, 111–12.
- Barr, C. E. (1995). Periodontal problems related to HIV-1 infection. *Advances in Dental Research*, 9, 147–51.
- Berthold, P. (2003). Noma: a forgotten disease. *Dental Clinics of North America*, 47, 559–74.
- Cannon, R. D., Holmes, A. R., Mason, A. B., and Monk, B. C. (1995). Oral candida: clearance, colonization or candidiasis. *Journal of Dental Research*, 74, 1152–61.
- Challacombe, S. J. (1994). Immunologic aspects of oral candidiasis. *Oral Surgery, Oral Medicine, Oral Pathology*, 78, 202–10.
- Chang, F., Syrjänen, S., Kellokoski, J., and Syrjänen, K. (1991). Human papillomavirus (HPV) infections and their association with oral disease. *Journal of Oral Pathology*, 20, 305–17.
- EEC Clearinghouse on Oral Problems Related to HIV Infection (1991). An update of the classification and diagnostic criteria of oral lesions in HIV infection. *Journal of Oral Pathology and Medicine*, 20, 97–100.
- Eng, H.-L., Lu, S.-Y., Yang, C.-H., and Chen, W.-J. (1996). Oral tuberculosis. *Oral Surgery, Oral Medicine, Oral Pathology, Oral Radiology and Endodontics*, 81, 415–20.
- Epstein, J. B., Sherlock, C. H., and Wolber, R. A. (1993). Oral manifestations of cytomegalovirus infection. *Oral Surgery, Oral Medicine, Oral Pathology*, 75, 443–51.
- Greenberg, M. S. (1996). Herpesvirus infections. *Dental Clinics of North America*, 40, 359–68.
- Greenspan, D. and Greenspan, J. S. (1996). HIV-related oral disease. *Lancet*, 348, 729–33.
- Holmstrup, P. and Westergaard, J. (1994). Periodontal diseases in HIV-infected patients. *Journal of Clinical Periodontology*, 21, 270–80.
- Laskaris, G. (1996). Oral manifestations of infectious diseases. *Dental Clinics of North America*, 40, 395–423.
- McIntyre, G. (2001). Oral candidosis. *Dental Update*, 28, 132–9.
- Oakley, C., Epstein, J. B., and Sherlock, C. H. (1997). Reactivation of oral herpes simplex virus: implications for clinical management of herpes simplex virus recurrence during radiotherapy. *Oral Surgery, Oral Medicine, Oral Pathology, Oral Radiology and Endodontics*, 84, 472–8.
- Patton, L. L. (2003). HIV disease. *Dental Clinics of North America*, 47, 467–92.
- Patton, L. L., McKaig, R., Strauss, R., Rogers, D., and Enron, J. J., Jr. (2000). Changing prevalence of oral manifestations of human immunodeficiency virus in the era of protease inhibitor therapy. *Oral Surgery, Oral Medicine, Oral Pathology, Oral Radiology and Endodontics*, 89, 299–304.
- Radford, D. R., Challacombe, S. J., and Walter, J. D. (1999). Denture plaque and adherence of *Candida albicans* to denture-base materials *in vivo* and *in vitro*. *Critical Reviews in Oral Biology and Medicine*, 10, 99–116.
- Rowland, R. W. (1999). Necrotizing ulcerative gingivitis. *Annals of Periodontology*, 4, 65–73.
- Samaranayake, L. (1992). Oral mycoses in HIV infection. *Oral Surgery, Oral Medicine, Oral Pathology*, 73, 171–80.
- Scully, C. (1992). Oral infections in the immunocompromised patient. *British Dental Journal*, 172, 401–7.
- Scully, C., el-Kabir, M., and Samaranayake, L. P. (1994). Candida and oral candidosis: a review. *Critical Reviews in Oral Biology and Medicine*, 5, 125–57.
- Sitheeque, M. A. M. and Samaranayake, L. P. (2003). Chronic hyperplastic candidosis/candidiasis (candidal leukoplakia). *Critical Reviews in Oral Biology and Medicine*, 14, 253–67.
- Stoopler, E. T. and Greenberg, M. S. (2003). Update on herpesvirus infections. *Dental Clinics of North America*, 47, 517–32.



Oral ulceration and vesiculobullous diseases

CLASSIFICATION OF ORAL ULCERATION

TRAUMATIC ULCERATION

RECURRENT APHTHOUS STOMATITIS (RAS)

Clinical features of RAS

Aetiology of RAS

Histopathological and immunological features of RAS

Behçet's disease (syndrome)

VESICULOBULLOUS DISEASES

Classification

Pemphigus vulgaris

Erythema multiforme

Pemphigoid

Mucous membrane pemphigoid

Dermatitis herpetiformis


Linear IgA disease

Epidermolysis bullosa

Epidermolysis bullosa acquisita

Angina bullosa haemorrhagica (oral blood blisters)

FURTHER READING



Oral ulceration and vesiculobullous diseases

Classification of oral ulceration

Injury to the oral mucosa, from whatever cause, may result in a localized defect of the surface in which the covering epithelium is destroyed, leaving an inflamed area of exposed connective tissue. Such defects are called ulcers or erosions, the latter term sometimes being used to describe a superficial ulcer. Ulceration is the most common lesion of the oral mucosa and is a manifestation of many local and general disorders. Oral ulceration may be classified on an aetiological basis and the main causes are listed in Table 12.1. Several of these conditions are dealt with elsewhere in this book. This chapter is primarily concerned with traumatic

Table 12.1 Causes of oral ulceration

- | |
|---|
| 1. <i>Infective</i> |
| Bacterial |
| Viral |
| Fungal |
| 2. <i>Traumatic</i> |
| Mechanical |
| Chemical |
| Thermal |
| Factitious injury |
| Radiation |
| Eosinophilic ulcer (traumatic granuloma) |
| 3. <i>Idiopathic</i> |
| Recurrent aphthous stomatitis |
| minor aphthous ulcers |
| major aphthous ulcers |
| herpetiform ulcers |
| 4. <i>Associated with systemic disease</i> |
| Haematological diseases |
| Gastrointestinal tract diseases |
| Behçet's disease (syndrome) |
| HIV infection |
| Other diseases |
| 5. <i>Associated with dermatological diseases</i> |
| Lichen planus |
| Chronic discoid lupus erythematosus |
| Vesiculobullous diseases |
| 6. <i>Neoplastic</i> |
| Squamous cell carcinoma |
| Other malignant neoplasms |

ulceration, recurrent aphthous stomatitis, and ulceration associated with systemic diseases and the vesiculobullous diseases.

Traumatic ulceration

Mechanical trauma from biting, sharp cusps, outstanding teeth, or ill-fitting intraoral appliances is a common cause of oral ulceration (Fig. 12.1). Such ulcers do not usually present a problem in clinical diagnosis, but three criteria should be fulfilled:

1. A cause of trauma must be identified.
2. The cause must fit the site, size, and shape of the ulcer.
3. On removal of the cause the ulcer must show signs of healing within 10 days.

Problems in diagnosis may arise with chronic traumatic ulcers, for example related to overextended flanges of a denture. Such ulcers may have been present for several weeks and may be deep crater-like lesions with rolled edges which are indurated on palpation because of surrounding fibrosis. Differentiation from a neoplastic ulcer may, therefore, be difficult. Biopsy is indicated when a presumed traumatic ulcer does not show signs of healing within 10 days. A traumatic ulcer shows the histological features of chronic non-specific inflammation.

A wide variety of chemicals may cause oral ulceration. These include irritant or caustic agents used in dental practice that may be accidentally applied to the oral mucosa, and preparations used by patients in self-treatment of oral complaints. The latter include various antiseptic mouthwashes, particularly if inadequately diluted, and aspirin misused by some patients as a local

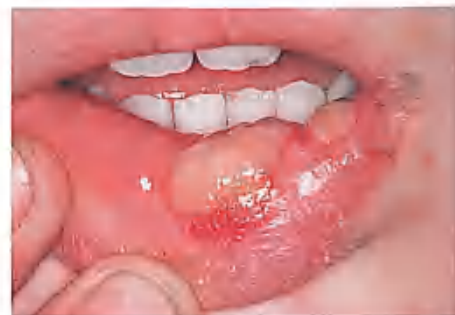

Fig. 12.1 Traumatic ulcer due to lip biting.

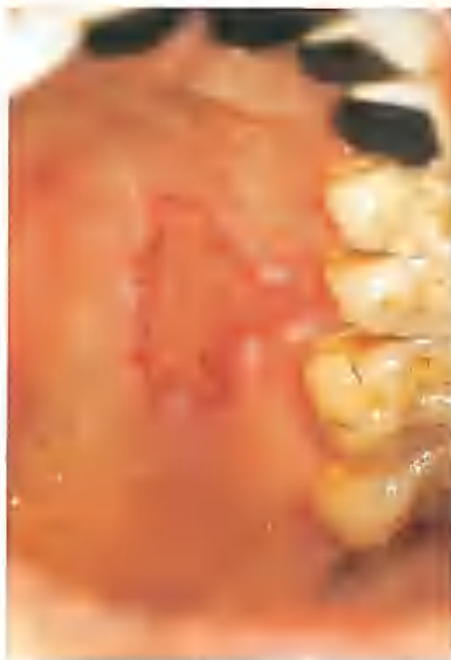

Fig. 12.2 Traumatic ulcer due to thermal burn.

obundant for the relief of toothache. The caustic action of aspirin is dose- and time-related and reactions vary in severity from oedema through to necrosis of the epithelium. The oedematous epithelium resembles leukoedema; the necrotic epithelium presents as soggy white plaques which slough off to leave areas of ulceration (see Fig. 9.6).

Ulceration due to acute thermal trauma, for example from taking very hot food or drink, can occur on any part of the oral mucosa but is most commonly seen in the palate (Fig. 12.2).

Factitious ulcers are self-inflicted and may be a manifestation of stress, anxiety, or more severe emotional disturbance. Their appearances and distribution vary considerably depending on how they are induced. Common causes are biting or chewing of lips, cheeks, or tongue, and damage, for example to the gingivae, from sharp finger-nails (Figs 12.3, 12.4).

In patients undergoing radiotherapy for head and neck cancer the oral mucosa may suffer immediate damage due to the direct effects of radiation on the cells, or delayed effects due to epithelial

atrophy and damage to the underlying vascular bed. The immediate effects include erythema, radiation mucositis, and ulceration. These changes usually appear within 2–3 weeks and heal within a similar period, after completion of the therapy. Oedema due to obstruction of the regional lymphatics may also occur. The later effects of vascular damage and epithelial atrophy render the mucosa susceptible to trauma and even minimal trauma can cause ulceration which may take months to heal. Ulcers occurring at the site of the original neoplasm may be difficult to differentiate from recurrent tumour, but radiation ulcers are generally painful whereas this is not a common symptom of early malignant disease.

An unusual type of ulceration, sometimes referred to as eosinophilic ulcer, traumatic granuloma, or eosinophilic granuloma of soft tissues, appears to be associated particularly with trauma and crush injury to muscle, although the pathogenesis of the lesion is unclear. It occurs most commonly on the tongue and presents clinically as a chronic, well-demarcated ulcer which may mimic a squamous cell carcinoma (Fig. 12.5). Histological examination shows an ulcer covered by a thick layer of fibrinous exudate with a dense, chronic inflammatory cell infiltrate in its base involving underlying damaged muscle. The deeper parts of the lesion are characterized by an infiltrate rich in histiocytes and eosinophils, as reflected in the various names applied to this lesion. However, true granulomas are not present and the condition has no relationship to eosinophilic granuloma of bone.

Recurrent aphthous stomatitis (RAS)

Although a variety of oral ulcers may recur, for example those associated with mechanical trauma and dermatological diseases, there is a group of idiopathic ulcers whose natural history is characterized by frequent recurrences over a number of years. It is to this group that the collective term recurrent aphthous stomatitis (RAS) is applied. Three types of ulcers are recognized, based primarily on their clinical features:

- (1) minor aphthous ulcers;
- (2) major aphthous ulcers;
- (3) herpetiform ulcers.

In addition, any of the three types may be associated with Behçet's disease (see later).

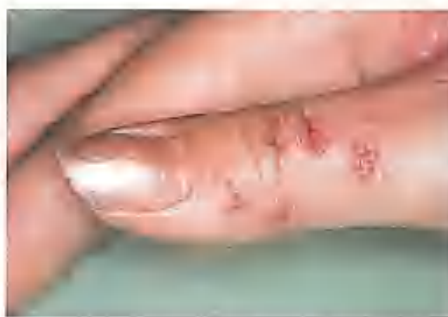
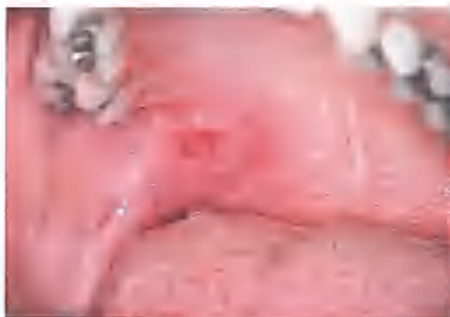
Fig. 12.3, 12.4 Factitious ulcer caused by finger-nail. Notice also bite marks on thumb.

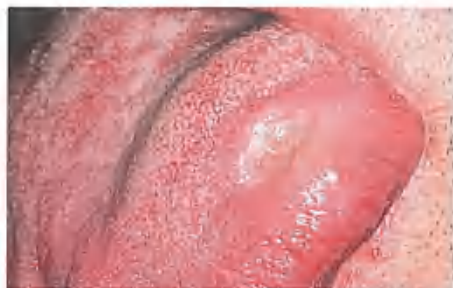

Fig. 12.5 Traumatic eosinophilic ulcer (traumatic granuloma).

Clinical features of RAS

Prodromal symptoms described as soreness, burning, or prickling sensations are recognized by many patients 1–2 days before the onset of ulceration. The mucosa may appear normal at this stage or there may be erythematous macules at the sites of future ulcers. The salient clinical features of the three types of RAS are listed in Table 12.2.

Minor aphthous ulceration

Minor aphthous ulceration accounts for 80 per cent or more cases of RAS. The condition is characterized by the occurrence of from one to five, shallow, round or oval ulcers which affect the non-keratinized areas of the oral mucosa (Figs 12.6, 12.7). The ulcers are less than 10 mm in diameter (generally they are about 4–5 mm across), and have a grey/yellow base with an erythematous margin. They heal without scarring, usually within about 10 days, and they tend to recur at 1–4 month intervals, although this is very variable.

Major aphthous ulceration

Major aphthous ulcers are larger than minor aphthae and are usually greater than 10 mm in diameter (Fig. 12.8). They may occur anywhere in the mouth, including the keratinized oral mucosa, but the lips, soft palate, tonsillar areas, and oropharynx are common sites. The number of ulcers varies from one to ten and they may take 4–6 weeks to heal, and may heal with scarring.

Table 12.2 Clinical features of recurrent aphthous stomatitis

	Minor	Major	Herpetiform
Age of onset (years)	10–19	10–19	20–29
Number of ulcers	1–5	1–10	10–100
Size of ulcers (mm)	< 10	> 10	1–2 but often coalesce
Duration (days)	7–14	> 30	10–30
Principal sites	Lips, cheeks, tongue	As for minor plus palate, pharynx	As for minor plus floor of mouth, palate, pharynx, and gingiva

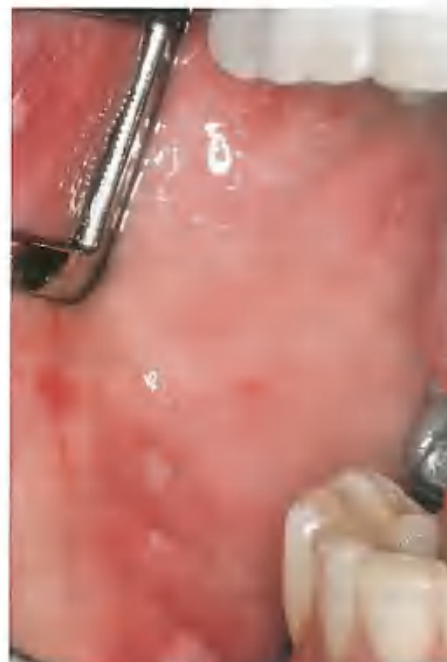

Fig. 12.6 Minor aphthous ulceration.

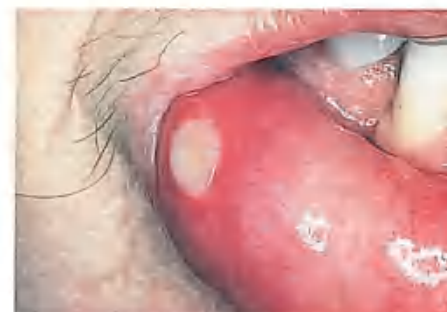

Fig. 12.7 Minor aphthous ulceration.

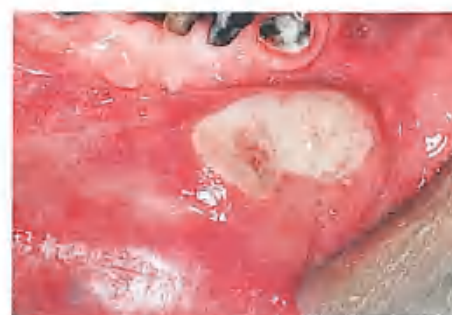

Fig. 12.8 Major aphthous ulceration.

They tend to recur at less than monthly intervals, so that in severe cases ulceration of the oral cavity is virtually continuous and may be associated with severe discomfort and with difficulty in eating and speaking. Unlike the shallow ulceration of minor aphthae, major aphthae extend deeper and may present as crater-like ulcers

Key point – Recurrent aphthous stomatitis

- differential diagnosis of the three subtypes is based entirely on clinical features.

with rolled margins which are indurated on palpation because of underlying fibrosis. Differentiation of an isolated lesion from a malignant ulcer may be difficult. It should be appreciated that major and minor aphthae represent a spectrum of the same disease process and intermediate forms may be seen.

Herpetiform ulceration

Herpetiform ulceration is characterized by multiple, small, pin-head sized ulcers (about 1–2 mm across) that can occur on any part of the oral mucosa (Fig. 12.9). As many as a hundred ulcers may be present. When several ulcers are clustered together, confluence can result in larger areas of ulceration of irregular outline. The ulcers usually heal within 2–3 weeks. Large confluent ulcers may take longer and may heal with scarring, but this is not otherwise prominent. The ulcers tend to recur at less than monthly intervals and, as for major aphthae, may be associated with severe discomfort. It is the least common type of ulceration associated with RAS and tends to occur in an older age group compared to minor and major aphthae.

Aetiology of RAS

The aetiology of RAS is far from clear, but there is increasing evidence that damaging immune responses are involved. In addition, a number of local and general factors have also been incriminated (Table 12.3) and one or more of these may play a contributory role in a proportion of cases. These factors include the following.

Hereditary predisposition

A family history is found in up to 45 per cent of patients, but the mode and pattern of inheritance has not been established.

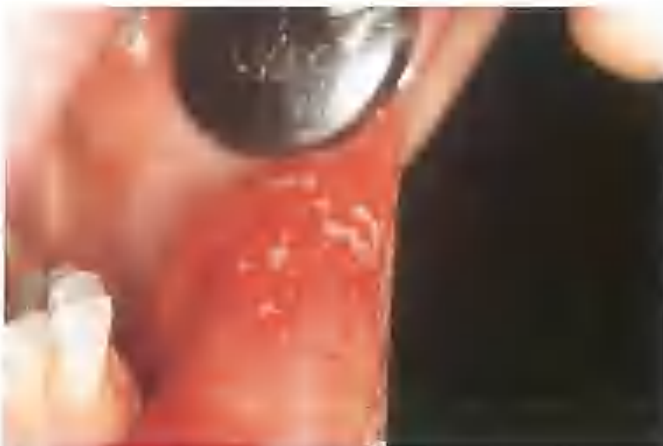

Fig. 12.9 Herpetiform ulceration.

Table 12.3 Aetiological factors in recurrent aphthous stomatitis

Hereditary predisposition
Trauma
Emotional stress and other psychological factors
Bacterial and viral infection
Allergic disorders
Haematological and deficiency disorders
Gastrointestinal diseases
Hormonal disturbance

Although some studies have suggested an increased prevalence associated with certain of the genetically determined histocompatibility antigens, no consistent patterns have been established.

Trauma

Trauma may precipitate and influence the site of some ulcers but does not play an essential role in the aetiology of RAS.

Emotional stress

Epidemiological studies have suggested that emotional stress may be a precipitating factor but it is unlikely to be the direct cause of ulceration. Stress may also be associated with pernicious habits, such as cheek biting, which may precipitate and influence the pattern of ulceration. Cigarette smoking has been reported to protect against RAS, and the onset of RAS in some patients has been associated with cessation of tobacco smoking. Whether the protective effect is related to increased keratinization of the mucosa or to a systemic mechanism is unknown.

Infective agents

Various microorganisms have been isolated from recurrent oral ulcers but attempts to incriminate them as causal factors have been largely unsuccessful. Hypersensitivity to *Streptococcus sanguis* antigens has been implicated in the pathogenesis of RAS, but studies of hypersensitivity to the organism in patients and control subjects have produced conflicting results. Nevertheless, there is some evidence of cross-reacting antigens between *Streptococcus sanguis* and oral mucosa and there is a possibility that these could be involved in the immunopathogenesis of RAS (see Box 12.1).

A viral aetiology has been suggested but there is little evidence to support such a hypothesis. Adenoviruses have been isolated occasionally from RAS but there is no evidence that they are causal. They are ubiquitous organisms and their presence may be purely incidental, as so-called passenger viruses. A rise in IgM antibody titres to varicella-zoster virus and to cytomegalovirus has also been reported during recurrences, but the significance of this is unknown.

Allergic disorders

Some patients with RAS associate the onset of ulceration with certain foods and this, together with the raised level of IgE found in some patients, has led to the claim that food allergies play a role

Box 12.1 Immunopathogenesis of RAS

- Epithelial destruction is most likely the result of T cell-mediated cytotoxicity.
- The preulcerative lesion is characterized by infiltration of mainly CD4⁺-positive (inducer/helper) T cells (CD4⁺/CD8⁺ ratio about 2:1).
- The ulcerative stage is characterized by a marked increase in CD8⁺ (suppressor/cytotoxic) T cells (CD4⁺/CD8⁺ ratio about 1:10).
- The healing phase is characterized by a striking reversal of this ratio and CD4⁺ T cells predominate (CD4⁺/CD8⁺ ratio about 10:1).
- Immune-mediated damage may be due to cross-reactivity between streptococcal protein antigens and epithelial plasma membrane proteins.
- Cross-reactivity between bacterial and epithelial heat shock proteins (HSP) has been demonstrated. HSP are ubiquitous defence proteins expressed when cells are shocked.
- T cells bearing the gamma-delta receptor are the first line of defence of the immune system to bacterial proteins such as HSP. Gamma-delta T cells can mediate cytotoxic damage.
- Gamma-delta T cells are increased in patients with RAS. Their cytotoxic activity in response to streptococcal HSP may cross-react with epithelial HSP (mitochondrial membrane HSP may be the target), leading to cell death.

in the aetiology of RAS. However, the evidence is often anecdotal, and results from controlled studies in which patients were challenged with specific foods are inconclusive. (Gluten-sensitive enteropathy is considered under gastrointestinal diseases.)

Haematological disorders

Haematological abnormalities associated with deficiencies of haematins may be found in up to 20 per cent of patients with RAS. Iron (ferritin) deficiency, which may or may not be associated with anaemia, occurs most frequently, but in the majority of patients no underlying cause can be identified. Deficiencies of folate and/or vitamin B₁₂ are also associated with RAS, but much less frequently than iron.

The role of haematological deficiency states in the aetiology of RAS is unclear, although it is known that deficiencies of iron, folate, and vitamin B₁₂ can produce atrophic changes in the oral mucosa. However, the ulceration in some patients improves when the deficiency is corrected, suggesting a causal role.

In some patients haematological deficiency states are secondary to gastrointestinal disease.

Key points – Aetiology of RAS

- most likely to be immune-mediated
- a variety of additional co-factors may operate in an individual patient
- haematitic deficiency and/or underlying systemic disease associated in a minority of patients

Gastrointestinal diseases

RAS has been reported in patients with a variety of gastrointestinal diseases, some of which are associated with secondary haematological abnormalities as a result of malabsorption or chronic blood loss. An association with coeliac disease (idiopathic steatorrhoea or gluten-sensitive enteropathy) is well recognized, but the incidence of coeliac disease in patients with RAS is low, probably only about 2–4 per cent. In contrast RAS, usually of the minor aphthous type, is a common symptom amongst patients with coeliac disease. RAS may also be seen in patients with ulcerative colitis and Crohn's disease.

Hormonal disturbance

In a small number of female patients a relationship between RAS and the menstrual cycle has been reported. A hormonal association in some patients has also been suggested by observations that the onset of ulceration may coincide with puberty and that remissions may occur in pregnancy. However, no consistent association between RAS and the premenstrual period, pregnancy, or the menopause has been established.

Histopathological and immunological features of RAS

Histopathological studies have shown that in the preulcerative (premonitory stage) there is infiltration of the lamina propria by a mononuclear, predominantly lymphocytic infiltrate. Small numbers of lymphocytes also infiltrate the epithelium. As the ulcerative phase approaches there is increased infiltration of the tissues, especially of the epithelium, by lymphocytes, associated

Key points – Pathogenesis of RAS

- involves immune-mediated cytotoxic damage to oral epithelium
- associated with increased activity of T cell subpopulations that mediate cytotoxic damage
- the trigger for the immune response against keratinocyte-associated antigen(s) unknown
- evidence suggests that cross-reactivity between antigens shared by oral streptococci and oral epithelial cells is involved

with oedema and damage to epithelial cells, leading eventually to their death and the formation of an ulcer. In the healing phase the number of lymphocytes decreases.

The fluctuation in lymphocytic infiltration throughout the ulcerative cycle suggests that immune mechanisms are involved in the pathogenesis of RAS. This is supported by immunological studies which have shown that the infiltrate comprises different subpopulations of T lymphocytes at different stages of the cycle. In particular, as the ulcerative phase begins the population of T lymphocytes capable of inducing cytotoxic effects in epithelial cells increases dramatically, particularly within the epithelial infiltrate. Thus, current evidence suggests that RAS is due to immune-mediated cytotoxic damage to oral epithelial cells, through the activity of T lymphocytes (see Box 12.1).

The epithelial antigen, or antigens, which are responsible for triggering the immune response leading to the cytotoxic damage remain unknown. However, in both RAS and Behçet's disease (see below) cross-reactivity between certain streptococcal antigens and oral epithelial antigens is thought to be an important pathogenic mechanism. Thus, in susceptible individuals, the host's immune response to streptococcal antigens may, inadvertently, also damage the oral epithelium (see Box 12.1).

Behçet's disease (syndrome)

Behçet's disease (syndrome) is characterized by recurrent aphthous stomatitis (RAS) and at least two of the following: genital ulcers, eye lesions, skin lesions, or rapid acute inflammation of skin in response to minor trauma (the pathergy test). Lesions involving other body systems may also be seen. It is a rare disorder in Western countries and is seen mainly in countries from the eastern Mediterranean area to the Far East, corresponding to the route of the ancient silk traders. There is a strong genetic link with the histocompatibility antigen HLA-B51 in patients from these countries. In addition to a genetic predisposition, immune-mediated mucosal damage (as discussed previously for RAS) and vasculitis associated with the hyperactivity of polymorph neutrophils are involved in the pathogenesis of the lesions.

Vesiculobullous diseases

The vesiculobullous diseases are included in this chapter because they usually present as oral ulceration following rupture of the vesicles or bullae. The latter are collections of clear fluid within or just below the epithelium, which patients may refer to as blisters. The distinction between a vesicle and a bulla is simply one of size, the distinction being somewhat arbitrary, but the term bulla is generally applied to a lesion greater than 5 mm in diameter.

Classification

The vesiculobullous diseases are divided into two major groups depending on the histological location of the lesions. In the first, the lesions form within the epithelium – intraepithelial vesicles; in the second, they form between the epithelium and the lamina propria (or dermis of the skin) – subepithelial vesicles.

Table 12.4 Vesiculobullous diseases that may effect the oral mucosa

I. <i>Intraepithelial vesiculobullous diseases</i>	
Acantholytic lesions	
pemphigus vulgaris	
paraneoplastic pemphigus and other variants	
Darier's disease	
Non-acantholytic lesions	
viral infections of the oral mucosa	
II. <i>Subepithelial vesiculobullous diseases</i>	
Erythema multiforme	
Pemphigoid	
mucous membrane (cicatrical) pemphigoid	
Dermatitis herpetiformis and linear IgA disease	
Epidermolysis bullosa	
Angina bullosa haemorrhagica (oral blood blisters)	
Bullous lichen planus	

The intraepithelial vesiculobullous diseases can be subdivided into two groups depending on the mechanisms of formation of the lesion:

1. Acantholytic vesicles and bullae, for example pemphigus. The lesions are produced by breakdown of the specialized intercellular attachments (desmosomes) between epithelial cells.
2. Non-acantholytic vesicles and bullae, for example viral infections of oral mucosa. The lesions are produced by death and rupture of groups of epithelial cells.

The main vesiculobullous diseases which may affect the oral mucosa are listed in Table 12.4.

Erythema multiforme is listed in the subepithelial group for convenience although, as its name implies, the manifestations are very variable and may include intraepithelial vesicles. Some forms of epidermolysis bullosa are also associated with intraepithelial vesicles but the majority are subepithelial in type.

The viral infections have been dealt with in Chapter 11. Darier's disease and bullous lichen planus are discussed in Chapter 9 since they usually present in the mouth as white lesions. The remaining conditions are all uncommon and are essentially skin diseases with oral manifestations.

Pemphigus vulgaris

Pemphigus is a group of uncommon autoimmune diseases of which pemphigus vulgaris is the most common type (see Box 12.2 for rarer types). Pemphigus vulgaris usually presents in middle age. It is more common in women than in men and in certain ethnic groups, particularly Ashkenazi Jews, where there may be a genetic link. It is characterized by widespread bullous eruptions involving the skin (Fig. 12.10) and mucous membranes. The oral mucosa is ultimately involved in nearly all patients and in about 50 per cent of cases is the site of the initial lesions. In some patients the disease remains confined to the oral cavity. The bullae are fragile and readily rupture forming crusted or weeping areas of denudation on the skin and irregular, ragged

Box 12.2 Pemphigus

- In addition to pemphigus vulgaris, oral lesions may also be seen in:
 - pemphigus vegetans: a milder form of pemphigus vulgaris; exuberant granulation tissue (vegetative masses) develop following rupture of bullae
 - drug-induced pemphigus, e.g. as side-effect of penicillamine, captopril, and others
 - paraneoplastic pemphigus: associated with malignant disease, e.g. leukaemia, lymphoma.
- The different types of pemphigus and their clinical features may be related to production of autoantibodies against different proteins forming the desmosome complex.
- The desmosome is a junctional complex mediating cell-cell contact. It comprises intercellular attachment plaques on the opposing plasma membranes of the adjacent cells and the intervening intercellular space bridged by adhesion proteins (see Fig. 12.14).
- The desmogleins are important transmembrane adhesion proteins. Autoantibodies to desmoglein 3 are found in pemphigus limited to mucosal sites; autoantibodies to desmoglein 1 and desmoglein 3 are found in pemphigus involving skin and mucosae.



Fig. 12.10 Skin bullae in pemphigus vulgaris.

mucosal ulcers (Fig. 12.11). Any part of the oral mucosa may be involved but the soft palate, buccal mucosa, and lips are most frequently affected. There may also be a desquamative gingivitis. The bullae are produced as a result of acantholysis and this process extends laterally into the surrounding epithelium, often for a considerable distance. As a result, gentle lateral pressure to the mucosa in an involved area can lead to the formation of a bulla (Nikolsky's sign).

Histological examination shows characteristic intraepithelial vesicles or bullae and cleft-like spaces produced by acantholysis. Typically, these changes occur between stratum spinosum cells just above the basal cell layer (Fig. 12.12). The basal cells forming the base of the lesion remain attached to the lamina propria and project into the bulla like a row of tombstones. There is remarkably little inflammatory cell infiltration until the lesion ruptures.

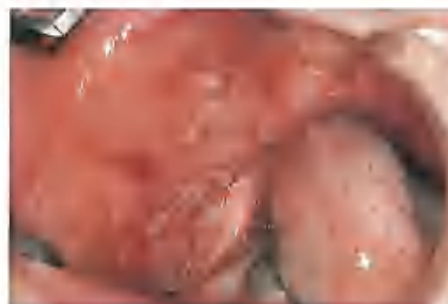

Fig. 12.11 Ragged oral ulcers in pemphigus vulgaris.

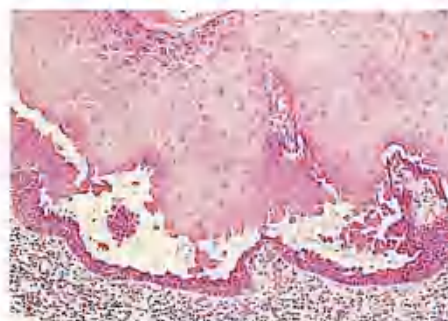


Fig. 12.12 Intraepithelial vesicle in pemphigus vulgaris.

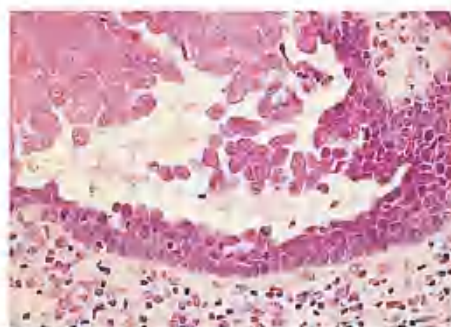


Fig. 12.13 Pemphigus vulgaris vesicle and acantholytic cells.

Acantholytic stratum spinosum cells occurring singly or in small clumps are found lying free within the blister fluid (Fig. 12.13). Unlike normal polyhedral stratum spinosum cells they are small and rounded and contain enlarged hyperchromatic nuclei (Tzanck cells). They may be identified in cytological smears taken from a blister.

Immunological studies are important in establishing the diagnosis and may be helpful in monitoring the progress of the disease. Circulating autoantibodies to the proteins which mediate cell-cell attachment via the desmosomes, the specialized intercellular attachment structures of squamous epithelium (see Fig. 12.14), can be demonstrated in the serum of patients. Their titre is related to the severity of the disease and monitoring the titre over time may be helpful in assessing the course of the disease and response to treatment. However, circulating antibodies may not be detectable in all patients, especially in the early stages of the disease, and biopsy of perilesional mucosa to detect

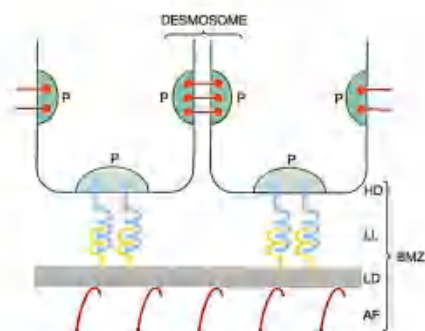


Fig. 12.14 Structure of desmosome and basement membrane zone. Intercellular attachments of epithelial cells are mediated by desmosomes comprising opposing attachment plaques (P) and intercellular adhesion proteins. Attachment of epithelium to connective tissue is mediated by hemidesmosomes (HD) and proteins of basement membrane zone (BMZ). Adhesion proteins from the hemidesmosome attachment plaque interact in the lamina lucida (LL) with adhesion proteins from the lamina densa (LD). Specialized collagen of the LD interacts with specialized collagen of the anchoring fibrils (AF). Collagen of AF interacts with underlying collagen fibres in the lamina propria.




Fig. 12.15 Immunofluorescent demonstration of epithelial-bound autoantibody in pemphigus bulla.

Key points – Pemphigus

- intraepithelial, acantholytic vesicles and bullae
- ragged oral ulcers
- oral lesions often the presenting feature
- autoantibodies to desmosomal protein

direct binding of autoantibodies to the intracellular area of the epithelium is an essential diagnostic test. This is undertaken on fresh (unfixed) tissue when direct binding of autoantibodies (of IgG type) can be demonstrated by immunofluorescent techniques (direct immunofluorescence) (Fig. 12.15).

There is strong evidence that IgG autoantibodies against the intercellular proteins of the desmosomes are responsible for inducing acantholysis (see Box 12.2), but the mechanisms by

which this occurs are unclear. However, it is likely to involve the activity of proteinases.

Erythema multiforme

Erythema multiforme is a disease of abrupt onset involving skin and mucous membranes and has a wide range of clinical presentations, hence 'multiforme'. The pathogenesis of the disease is unknown, although many precipitating factors have been implicated including drugs (particularly sulphonamides) and preceding infection (especially herpes simplex infection). However, many cases appear to arise spontaneously. It has been suggested that the disease represents a hypersensitivity reaction and that the manifestations may be related to deposition of immune complexes in which the antigen may be of drug, bacterial, or viral origin.

Erythema multiforme occurs mainly in young adults and is more common in males than in females. There may be a prodromal phase with upper respiratory infection, headache, malaise, nausea, and sometimes arthralgia. The severity of the disease varies considerably. In its severe form, the Stevens-Johnson syndrome, there is widespread involvement of the skin and oral, genital, and ocular mucosae. Ocular involvement (Fig. 12.16) can lead to conjunctival scarring and visual impairment. Milder forms may involve the oral mucosa, with or without skin lesions, or the skin alone may be involved. Generally, the disease tends to subside after 10–14 days but recurrences may occur. Recurrent erythema multiforme is associated in particular with recurrent attacks of herpes simplex virus infection.

The skin lesions have a variety of forms, including erythematous maculopapular rashes and vesiculobullous eruptions in addition to the characteristic and virtually diagnostic target or iris

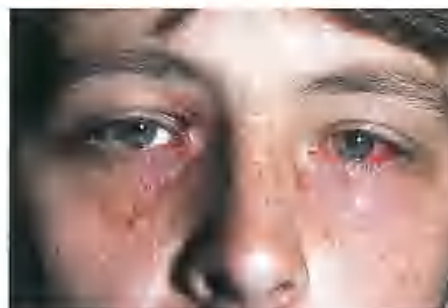

Fig. 12.16 Ocular lesions in erythema multiforme.

Key points – Erythema multiforme

- mucosal vesicles and bullae variable
- oral ulceration/circumoral crusting, haemorrhagic lesions
- target/iris skin lesions
- precipitated by drugs/herpesvirus antigens
- immune complex vasculitis

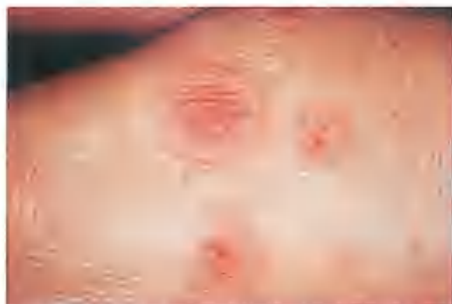

Fig. 12.17 Target skin lesions in erythema multiforme.

lesions (Fig. 12.17). These consist of concentric rings of varying erythema and oedema, in the centre of which may be an intact or ruptured and crusted bulla. The hands and feet are most commonly involved.

Oral lesions may involve any part of the mucosa, although the lips and anterior parts of the mouth are most commonly affected (Figs 12.18, 12.19). The appearance of the lesions varies with time. Erythematous patches are quickly followed by vesiculobullous eruptions which rapidly break down into erosions as the bullae disintegrate. The erosions on the lips are accompanied by bleeding and crusting. Circumoral crusting haemorrhagic lesions are an important sign in arriving at a clinical diagnosis.

The diagnosis of erythema multiforme is based primarily on the clinical findings. The histopathological features are non-specific (although biopsy may be useful to exclude other diseases) and a wide spectrum of histological changes has been described. The epithelium is oedematous and shows varying degrees of cellular damage, leading to foci of necrosis of the keratinocytes and vesicle formation (Fig. 12.20). The lamina propria is oedematous and there is a variable, mononuclear inflammatory cell infiltration which extends perivascularly into the deeper tissues.

The pathogenesis of erythema multiforme is not fully understood but it is probably due to the formation of immune complexes and a type III hypersensitivity reaction. Deposition of immune complexes leads to complement activation, chemotaxis of neutrophils, and vasculitis, resulting eventually in necrosis of epithelium. Circulating immune complexes have been detected in patients with erythema multiforme and in some cases they have been associated with herpes simplex viral antigens.

Pemphigoid

Pemphigoid is a general term applied to a group of immune-mediated blistering diseases characterized by the production of autoantibodies to various components of the hemidesmosomes and epithelial basement membrane (Fig. 12.14). These structures mediate the attachment between epithelium and the underlying connective tissue. They are damaged in the pemphigoid group of diseases, resulting in the formation of subepithelial vesicles. The classification of this group of diseases is evolving and becoming ever more complicated as the target antigens, in the hemidesmosome–basement membrane complex, to which the specific autoantigens react, are identified. The different subtypes and their clinical manifestations most likely reflect damage to different target antigens, alone or in combination. However, they can be divided into two groups clinically:

- (1) those involving skin alone, or with only minimal mucosal involvement, referred to as bullous pemphigoid;
- (2) those involving mucosa alone, or with only minimal skin involvement, referred to as mucous membrane pemphigoid.

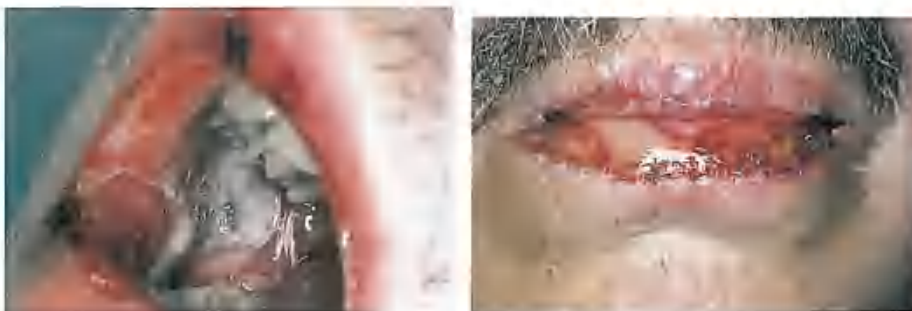Oral manifestations occur in almost all patients with mucous membrane pemphigoid group; they are very uncommon in bullous pemphigoid.

Mucous membrane pemphigoid

Mucous membrane pemphigoid is a group of disorders (see Box 12.3) which occur mainly in women in the sixth decade of life. The oral mucosa is almost always affected, either alone or in association with other mucosae.

Key points – Pemphigoid

- complex group of subepithelial blistering diseases
- autoantibodies attack hemidesmosome – basement membrane antigens
- different clinical subtypes of pemphigoid reflect damage to different antigens
- mucosal lesions, including the mouth, occur predominantly in the mucous membrane pemphigoid subtypes



Figs 12.18, 12.19 Oral lesions in erythema multiforme.

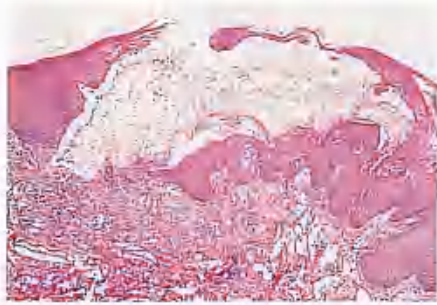


Fig. 12.20 Vesicle in erythema multiforme.

Box 12.3 Mucous membrane pemphigoid (MMP)

- Adhesion of epithelium to connective tissue is mediated by the hemidesmosome – basement membrane complex (Fig. 12.14).
- The hemidesmosome is an intracellular attachment plaque on the basal plasma membrane of the basal epithelial cells.
- The basement membrane consists of two distinct zones when examined by electron microscopy: the lamina lucida adjacent to the basal epithelial plasma membrane and the lamina densa adjacent to the underlying connective tissue.
- The hemidesmosome, lamina lucida, and lamina densa contain complex arrays of attachment proteins (at least 10 of which have been identified), including collagens/collagen-like proteins, laminins, and integrins.
- Different combinations of autoantibodies to antigens on these attachment proteins have been identified and are probably related to different clinical subtypes of MMP.
- The most common target antigen in MMP with oral manifestations is a transmembrane protein with intra- and extracellular components (i.e. it bridges between the hemidesmosome and the basement membrane). It is identical/similar to an antigen found in some cases of bullous pemphigoid and is referred to as BP antigen 2.

Bullae, which are occasionally haemorrhagic, occur anywhere on the oral mucosa. Unlike those seen in pemphigus vulgaris they tend to be tense and, because the lid consists of a full-thickness epithelium, are relatively tough and may remain intact for a few days (Fig. 12.21). When they rupture they give rise to erosions which heal slowly, sometimes with scarring, hence the alternative name for this disease – cicatricial pemphigoid (Fig. 12.22). Although bullae can occur on any part of the mucosa, the most consistent oral lesions in dentate patients, occurring in over 90 per cent of cases, involve the gingiva where the condition presents as desquamative gingivitis (Fig. 12.23). In some patients this is the only manifestation, in which case it may be referred to as oral pemphigoid.

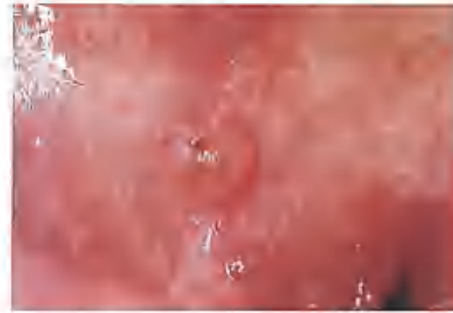


Fig. 12.21 Oral manifestations of mucous membrane pemphigoid showing intact bullae.



Fig. 12.22 Extensive oral ulceration (erosions) associated with mucous membrane pemphigoid.

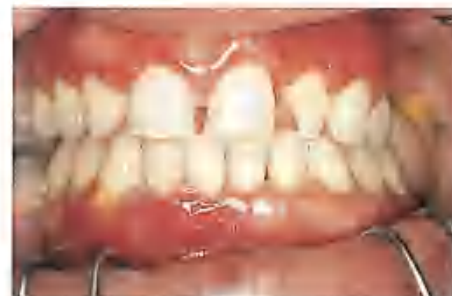

Fig. 12.23 Mucous membrane pemphigoid presenting as desquamative gingivitis.

In addition to the oral mucosa, the conjunctiva and mucosae of the nose, larynx, pharynx, oesophagus, and genitalia may be involved. Ocular involvement is the most serious complication with scarring leading to adhesions between the bulbar and palpebral conjunctiva, opacity of the cornea, and blindness (Fig. 12.24).

Histopathological examination of established pemphigoid lesions shows separation of the full thickness of the epithelium from the lamina propria producing a subepithelial bulla, with a thick roof (Fig. 12.25). Initially, there is no evidence of an inflammatory reaction in the lamina propria but as the vesicle develops there is infiltration by variable numbers of neutrophils and eosinophils around and within the developing bulla. These changes are accompanied by a perivascular mononuclear, mainly

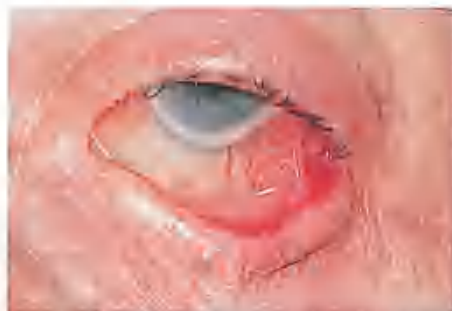

Fig. 12.24 Ocular lesions in mucous membrane pemphigoid.

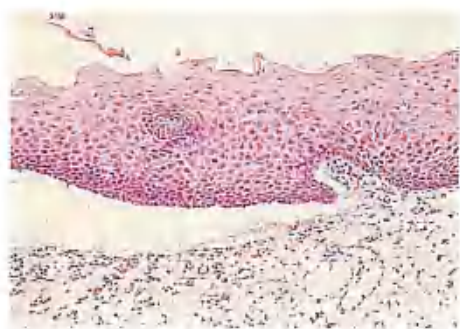


Fig. 12.25 Subepithelial bulla in mucous membrane pemphigoid.

Table 12.5 Major immunological findings in subepithelial bullous disorders

Disease	Direct IF	Indirect IF (circulating antibodies)
Bullous pemphigoid	Linear, IgG, C3; BM zone	Positive (75–80%)
Mucous membrane pemphigoid	Linear, IgG, +/- IgA, C3; BM zone	Positive (80%) using special techniques
Dermatitis herpetiformis	Granular IgA, C3; tips of dermal papillae	Negative
Linear IgA disease	Linear, IgA, C3; BM zone	Positive (30%)
Epidermolysis bullosa acquisita	Linear IgG, C3; BM zone	Positive (30–40%)

lymphocytic, infiltrate in the lamina propria, the intensity of which increases as the lesion develops.

Direct immunofluorescence studies of fresh, unfixed biopsy material to detect tissue-bound immune products are essential to establish the diagnosis (Table 12.5). In mucous membrane pemphigoid there is linear binding of immunoglobulin, predominantly IgG, but also IgA in more severe cases, in the basement membrane zone (Fig. 12.26). Linear binding of complement



Fig. 12.26 Linear binding of IgG in the basement membrane zone in mucous membrane pemphigoid.

Key points – Mucous membrane pemphigoid

- subepithelial vesicles and bullae
- occasionally intact oral vesicles and bullae
- extensive oral ulceration
- desquamative gingivitis
- autoantibodies to hemidesmosomal proteins

products, principally C3, also occurs. Bulla formation involves protease activity, probably released from neutrophils and eosinophils following the activation of complement and generation of chemotactic factors in the basement membrane zone. Although circulating autoantibodies to basement membrane antigens were seldom identified in the past by routine indirect immunofluorescence, using modern techniques they can now be detected in the serum of about 80 per cent of patients. Their titre also correlates with the severity of the disease.

Dermatitis herpetiformis

Dermatitis herpetiformis is a chronic, intensely pruritic subepidermal autoimmune blistering disease of skin. Oral manifestations are variable and range from small symptomless erythematous areas to extensive erosions.

Immunofluorescence studies show granular deposits of IgA in the tips of the connective tissue papillae together with complement components (Table 12.5). Activation of the alternative complement pathway by IgA and the subsequent generation of chemotactic factors for polymorph neutrophils are thought to be important in the pathogenesis of the lesions.

About 90 per cent of patients with dermatitis herpetiformis also have abnormalities of their jejunal mucosa associated with gluten hypersensitivity.

Linear IgA disease

This is a rare subepidermal blistering disease of skin which clinically overlaps with dermatitis herpetiformis and bullous pemphigoid. Oral lesions have been reported. Patients may have

gluten hypersensitivity, but this is much less common than in dermatitis herpetiformis.

Immunopathological studies show linear binding of IgA along the basement membrane zone similar to the pattern seen in pemphigoid (Table 12.5).

Epidermolysis bullosa

The inherited forms of epidermolysis bullosa form a diverse and complex group of syndromes of which over 30 types have been reported. They are due to mutation in the genes coding either for specific keratins in the basal epithelial cells (resulting in intra-epithelial bullae) or for various collagens and other attachment proteins of the basement membrane (resulting in subepithelial bullae).

In general, they are characterized by the formation of skin bullae which may be manifest at birth or appear shortly afterwards. There is extreme fragility of the skin and the bullae usually develop in response to minimal trauma or pressure, but they may arise spontaneously. Hands, feet, knees, elbows, buttocks, and occiput are common sites. Oral and other mucosae may be involved. The bullae tend to heal slowly with scarring which can result in claw-like deformity of the hands (Fig. 12.27) and other complications, such as difficulties in eating, speaking, and swallowing as a result of involvement of the mouth, larynx, and pharynx. Several types are incompatible with life.

Oral lesions may appear in neonates in response to suckling, and, later, minimal trauma from toothbrushing and routine dental treatment can cause serious consequences. The bullae rupture to leave painful erosions, and subsequent scarring can restrict the opening of the mouth, movement of lips and tongue, and cause obliteration of the sulci. Effective oral hygiene may be impossible and rampant caries and its sequelae add to the dental complications. Dental defects, especially enamel hypoplasia, have been described in some patients.

Epidermolysis bullosa acquisita

This is an uncommon autoimmune blistering disease acquired in adult life. Linear binding of IgG and C3 is seen in the basement membrane zone, resulting in the formation of subepithelial bullae. Oral lesions may occur.

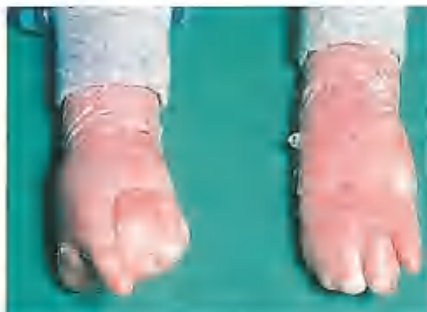

Fig. 12.27 Epidermolysis bullosa – scarring of hands.

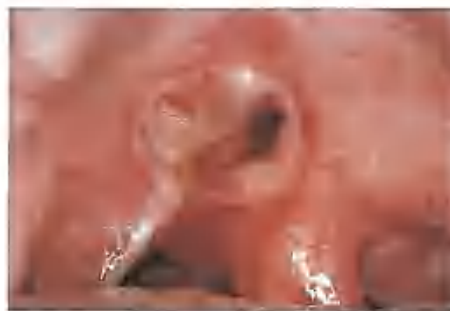

Fig. 12.28 Recently ruptured oral blood blister.

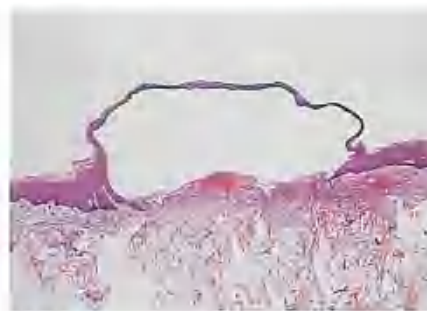

Fig. 12.29 Subepithelial bulla associated with oral blood blister.


Angina bullosa haemorrhagica (oral blood blister)

Spontaneous blood-filled bullae (blisters) occasionally develop on the oral mucosa to which the term 'angina bullosa haemorrhagica' has been applied. They are usually solitary and present in middle-aged or elderly patients. They may be up to 2–3 cm in diameter and occur on any part of the oral mucosa, although they are seen most commonly on the soft palate (Fig. 12.28). The patient may notice a pricking sensation when the blister arises and if large it may be uncomfortable. Early perforation is frequent, leaving an ulcer which heals uneventfully. Histology shows a subepithelial bulla with separation within the basement membrane zone (Fig. 12.29). Immunological findings are negative and no abnormalities in blood coagulation or in the tissues have been identified. The cause remains a mystery but it is probable that the bullae are related to trauma. The use of steroid inhalers has also been implicated in some patients.

Further reading

- Axéll, T. (2001). Hypersensitivity of the oral mucosa: clinics and pathology. *Acta Odontologica Scandinavica*, 59, 315–19.
- Challacombe, S. J., Setterfield, J., Shirlaw, P., Harman, K., Scully, C., and Black, M. (2001). Immunodiagnosis of pemphigus and mucous membrane pemphigoid. *Acta Odontologica Scandinavica*, 59, 226–34.
- Dayan, S., Simmons, R. K., and Ahmed, A. R. (1999). Contemporary issues in the diagnosis of oral pemphigoid: a selective review of the literature. *Oral Surgery, Oral Medicine, Oral Pathology, Oral Radiology and Endodontics*, 88, 424–30.

- el-Mofty, S. K., Swanson, P. E., Wick, E. R., and Miller, A. S. (1993). Eosinophilic ulcer of the oral mucosa. Report of 38 new cases with immunohistochemical observations. *Oral Surgery, Oral Medicine, Oral Pathology*, 75, 716–22.
- Eversole, L. R. (1994). Immunopathology of oral mucosal ulcerative, desquamative, and bullous diseases. Selective review of the literature. *Oral Surgery, Oral Medicine, Oral Pathology*, 77, 555–71.
- Farthing, P. M., Maragou, P., Coates, M., Tatnall, F., Leigh, I. M., and Williams, D. M. (1995). Characteristics of the oral lesions in patients with cutaneous recurrent erythema multiforme. *Journal of Oral Pathology and Medicine*, 24, 9–13.
- Giuliana, M., Favia, G. F., Lajolo, C., and Miani, C. M. (2002). Angina bullosa haemorrhagica: presentation of eight new cases and a review of the literature. *Oral Diseases*, 8, 54–8.
- Porter, S. R., Scully, C., and Pedersen, A. (1998). Recurrent aphthous stomatitis. *Critical Reviews in Oral Biology and Medicine*, 9, 306–21.
- Sakane, T., Takeno, M., Suzuki, N., and Inaba, G. (1999). Behçet's disease. *New England Journal of Medicine*, 341, 1284–91.
- Scully, C. and Challacombe, S. J. (2002). Pemphigus vulgaris: update on etiopathogenesis, oral manifestations, and management. *Critical Reviews in Oral Biology and Medicine*, 13, 397–408.
- Scully, C., Gorsky, M., and Lozada-Nur, F. (2003). The diagnosis and management of recurrent aphthous stomatitis: a consensus approach. *Journal of the American Dental Association*, 134, 200–7.
- Ship, J. A. (1996). Recurrent aphthous stomatitis. An update. *Oral Surgery, Oral Medicine, Oral Pathology, Oral Radiology and Endodontics*, 81, 141–7.
- Vincent, S. D., Lilly, G. E., and Baker, K. A. (1993). Clinical, historic and therapeutic features of cicatricial pemphigoid. *Oral Medicine, Oral Surgery, Oral Pathology*, 76, 453–9.
- Weinberg, M. A., Insler, M. S., and Campen, R. B. (1997). Mucocutaneous features of autoimmune blistering diseases. *Oral Surgery, Oral Medicine, Oral Pathology, Oral Radiology and Endodontics*, 84, 517–34.



Miscellaneous disorders of oral mucosa

FORDYCE'S GRANULES

SUBLINGUAL VARICES

LINGUAL TONSIL, FOLIATE PAPILLITIS

GEOGRAPHIC TONGUE (BENIGN MIGRATORY GLOSSITIS)

OROFACIAL GRANULOMATOSIS

CROHN'S DISEASE

SARCOIDOSIS

PYOSTOMATITIS VEGETANS

WEGENER'S GRANULOMATOSIS

PROGRESSIVE SYSTEMIC SCLEROSIS (SCLERODERMA)

VERRUCIFORM XANTHOMA

ORAL SUBMUCOUS FIBROSIS

AMYLOIDOSIS

ORAL PIGMENTATION

AGE CHANGES IN THE ORAL MUCOSA

FURTHER READING

1914
1915
1916
1917
1918
1919
1920
1921
1922
1923
1924
1925
1926
1927
1928
1929
1930
1931
1932
1933
1934
1935
1936
1937
1938
1939
1940
1941
1942
1943
1944
1945
1946
1947
1948
1949
1950
1951
1952
1953
1954
1955
1956
1957
1958
1959
1960
1961
1962
1963
1964
1965
1966
1967
1968
1969
1970
1971
1972
1973
1974
1975
1976
1977
1978
1979
1980
1981
1982
1983
1984
1985
1986
1987
1988
1989
1990
1991
1992
1993
1994
1995
1996
1997
1998
1999
2000
2001
2002
2003
2004
2005
2006
2007
2008
2009
2010
2011
2012
2013
2014
2015
2016
2017
2018
2019
2020
2021
2022
2023
2024
2025

Miscellaneous disorders of oral mucosa

Fordyce's granules

Sebaceous glands in the oral mucosa are usually known as Fordyce's spots or granules, and are seen as separate small, yellowish bodies beneath the surface, although on occasions they may be so numerous as to form slightly raised confluent plaques. They are commonly seen in the mucosa of the upper lip, cheeks, and anterior pillar of the fauces, and usually have a symmetrical distribution. They rarely occur in the lower lip. The glands are present in about 60–75 per cent of adults, but the number of glands varies greatly between individuals. The prevalence and number in the upper lip increase at puberty, and there is an increase in the number of the glands in the cheeks in later life.

The glands lie quite superficially and consist of a number of lobules of sebaceous cells grouped around one or more ducts (Fig. 13.1). Sebaceous glands do not appear to have any function in the oral cavity, and no significant pathological changes are associated with them.

Sublingual varices

The prevalence of varicosities of the lateral branches of the sublingual veins increases with age (Fig. 13.2). They have no relationship with systemic diseases. Histological investigation of the distribution of elastic tissue and fat in the supporting tissues has not revealed any morphological changes to account for their development. The varices have no clinical significance. Similar lesions are seen occasionally elsewhere in the mouth and on the lips.

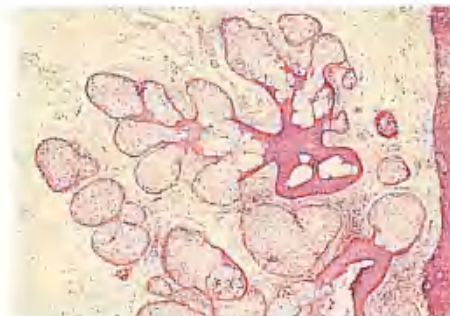


Fig. 13.1 Fordyce's granules – ectopic sebaceous glands.

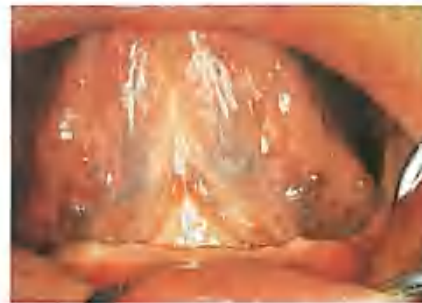

Fig. 13.2 Sublingual varicosities.

Lingual tonsil, foliate papillitis

Lingual tonsillar tissue is mainly located on the posterior part of the lateral aspect of the tongue and may be associated with vertical folds of mucosa, sometimes referred to as foliate papillae (Fig. 13.3). Small aggregates of subepithelial lymphoid tissue are occasionally found elsewhere in the oral cavity.

Diseases of lingual tonsillar tissue are uncommon, but they may become enlarged as a result of trauma from teeth or dentures, inflammation, or reactive hyperplasia of the lymphoid tissue. Inflammatory changes are sometimes referred to as foliate papillitis (Fig. 13.4). Occasionally, crypts may become obstructed and undergo cystic dilatation as a result of accumulation of squamous debris.

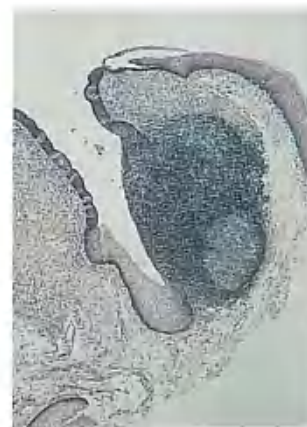

Fig. 13.3 Foliate papilla and lingual tonsillar tissue.

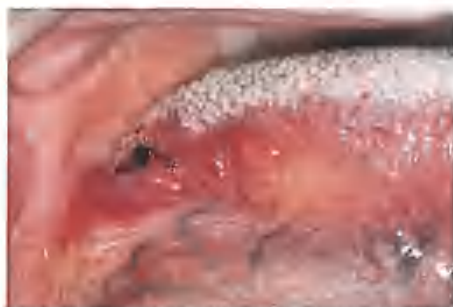

Fig. 13.4 Foliate papillitis associated with denture trauma.

Geographic tongue (benign migratory glossitis)

This condition, of unknown aetiology, is seen clinically as irregular, partially depapillated, red areas on the anterior two-thirds of the dorsal tongue surface and is associated with loss of the filiform papillae, the fungiform papillae remaining as shiny, dark-red eminences (Fig. 13.5). The margins of the lesions are often outlined by a thin, white line or band and the disorder is frequently associated with fissured (scrotal) tongue (Fig. 13.6). The affected areas may begin as small lesions only a few millimetres in diameter which, after gradually enlarging, heal and then reappear in another location. The condition may regress for a period and then recur. It is usually symptomless but there may be some irritation associated with acid and spicy foods. The reported prevalence is approximately 1 per cent of the population and there

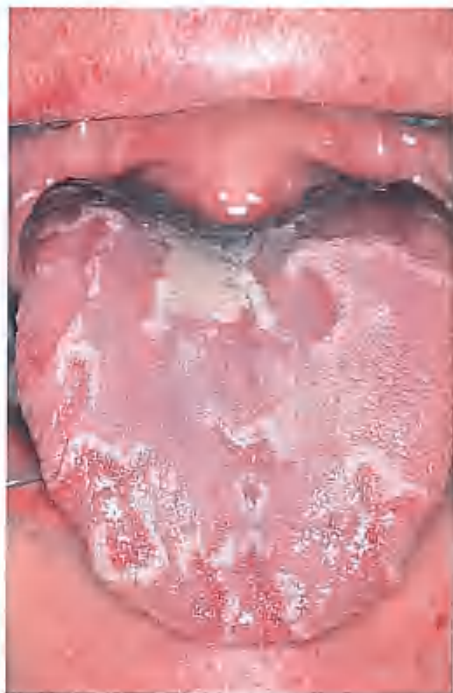

Fig. 13.5 Geographic tongue.

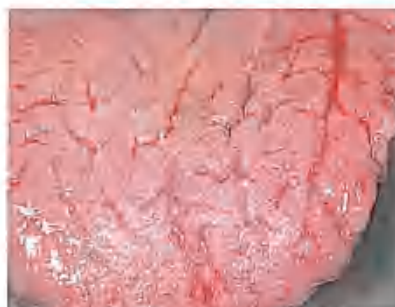

Fig. 13.6 Fissured (scrotal) tongue.

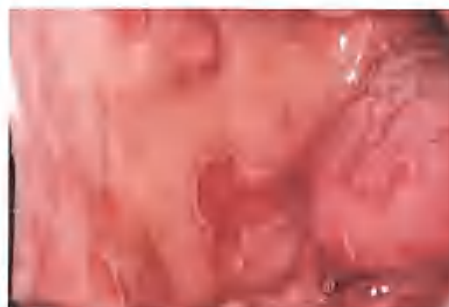

Fig. 13.7 Migratory stomatitis.

is often a family history. The disorder occurs over a wide age range and presents both in children and adults.

Similar lesions are seen occasionally affecting other areas of the oral mucosa, mainly lips and cheeks, and in these cases the condition may be referred to as migratory (or geographic) stomatitis or as erythema migrans (Fig. 13.7). Geographic tongue and erythema migrans have been reported in patients with psoriasis and it is possible that these disorders share the same underlying genetic predisposing factors.

Histological examination shows the epithelium at the edges of the lesions to be acanthotic with a dense, neutrophil leucocyte infiltration throughout the epithelium and the lamina propria. In the centres of the lesions, the loose desquamating cells on the surface have been lost and there is underlying chronic inflammatory cell infiltration.

Orofacial granulomatosis

Orofacial granulomatosis is not a disease entity but a term used to describe the common clinicopathological manifestations of a variety of different disorders. Typically, orofacial granulomatosis presents as recurrent or persistent diffuse enlargement of the lips and cheeks or as diffuse facial swelling, and is characterized histologically by non-caseating epithelioid cell granulomas with or without giant cells, and oedema of the tissues. The time of onset varies from infancy to old age.

Orofacial granulomatosis should be regarded as a provisional diagnosis indicating the need for further investigation, since the condition includes localized disorders affecting the mouth and face as well as oral manifestations of systemic diseases. The

Key points – Orofacial granulomatosis

- typical clinical features: swelling of lips and cheeks
- typical histopathological features: poorly formed non-caseating granulomas, and oedema
- the common clinicopathological appearances of a variety of disorders
- several possible causes:
 - Crohn's disease
 - sarcoidosis
 - other causes of granulomatous inflammation, e.g. infection/foreign bodies
 - Melkersson–Rosenthal syndrome
 - allergic reaction to topical allergens
 - idiopathic

latter include sarcoidosis and Crohn's disease (see later). (To avoid confusion the term 'orofacial granulomatosis' should only be used until evidence of coexisting disease is found.) Orofacial granulomatosis also encompasses the disorders described as Melkersson–Rosenthal syndrome and its incomplete form, cheilitis granulomatosa. Classically, the Melkersson–Rosenthal syndrome consists of the triad of facial swellings, fissured tongue, and unilateral facial palsy. The full syndrome is rarely seen, and in all cases further investigation of the patient is indicated as some patients with the syndrome or its incomplete form may have underlying sarcoidosis, Crohn's disease, or allergies.

In all cases where the histopathological picture is characterized by granulomatous inflammation the possibility of infective granulo-

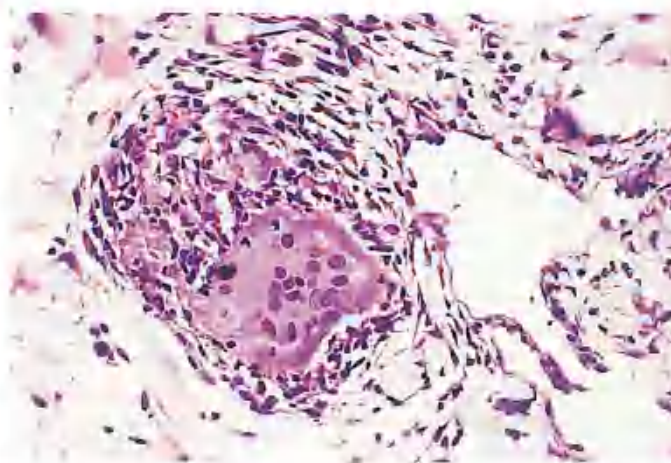
matous disease, such as tuberculosis (see Chapter 11), needs to be considered. However, several studies have failed to find any evidence of mycobacterial infection in orofacial granulomatosis. Histological sections also need to be scrutinized carefully for foreign material to exclude foreign-body reactions.

The aetiology of orofacial granulomatosis in patients where no infective or underlying systemic cause can be found remains obscure. It is assumed that such cases represent a localized condition and there is evidence that allergic reactions to specific food substances, toothpastes, and occasionally dental materials are involved. Intolerance to specific foods, flavourings, or preservatives in the diet such as cinnamaldehyde, cocoa, and benzoates has been implicated most frequently.

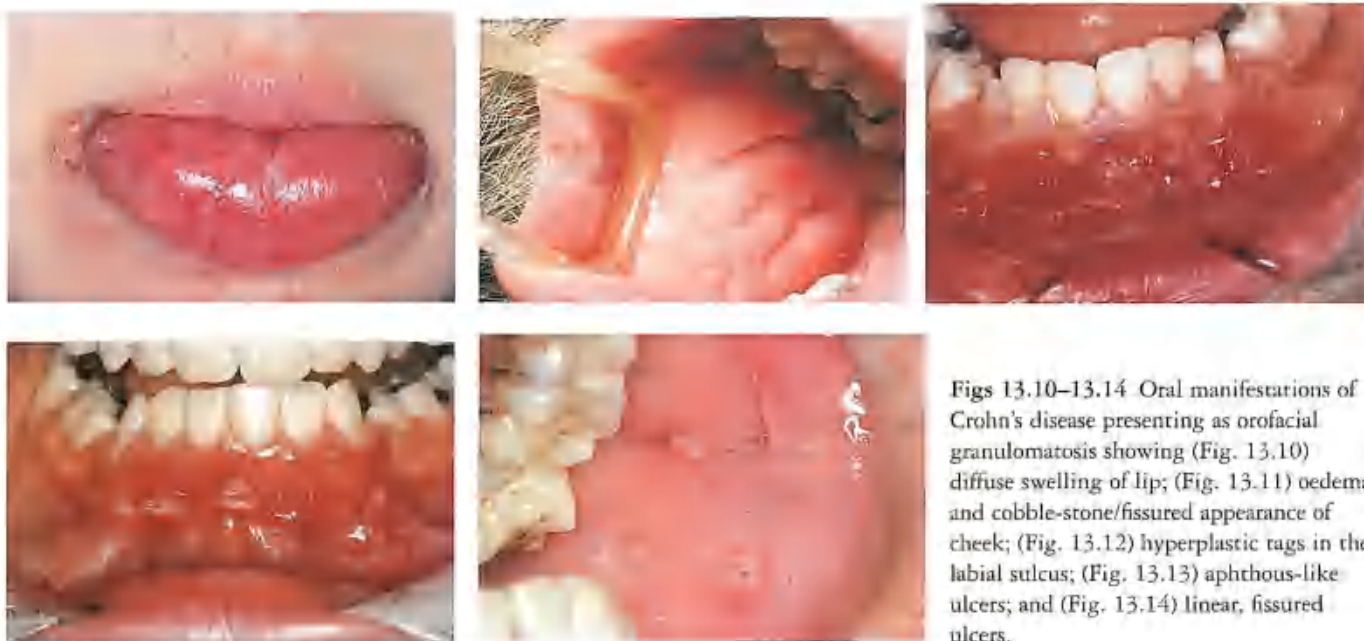Crohn's disease

This is a chronic granulomatous disease involving any part of the gastrointestinal tract, but most commonly the terminal ileum. Oral lesions may occur in patients with established Crohn's disease of the intestine or may be the presenting feature. The disease runs a chronic course, periods of quiescence being interrupted by episodes of varying severity and duration.

The aetiology is unknown but an excessive, probably cell-mediated, immune response to exogenous or endogenous bacteria in the gut, or to some other extrinsic agent, has been suggested. In some cases atypical mycobacteria have been implicated. Histological examination of affected tissues shows fibrosis and a dense, often focal, infiltration of the mucosa and submucosa with lymphocytes and plasma cells. Lymphoedema and dilated lymphatics may be a prominent feature. Non-caseating, often poorly formed granulomas consisting of macrophages, epithelioid cells, and occasional giant cells are present in about half of the cases and are often found in and around the dilated lymphatics (Figs 13.8, 13.9). Intestinal involvement usually causes recurrent episodes of abdominal pain, and nutritional deficiencies due to malabsorption are frequent.



Figs 13.8, 13.9
Oedema of the lamina propria and granulomatous inflammation in oral Crohn's disease.



Figs 13.10–13.14 Oral manifestations of Crohn's disease presenting as orofacial granulomatosis showing (Fig. 13.10) diffuse swelling of lip; (Fig. 13.11) oedema and cobble-stone/fissured appearance of cheek; (Fig. 13.12) hyperplastic tags in the labial sulcus; (Fig. 13.13) aphthous-like ulcers; and (Fig. 13.14) linear, fissured ulcers.

The oral manifestations of Crohn's disease include:

1. Diffuse swellings of the lips and cheeks (Fig. 13.10). Crohn's disease is the most common systemic condition associated with orofacial granulomatosis.
2. Oedematous and hyperplastic thickening of the buccolabial mucosa together with fissuring, producing a 'cobble-stone' appearance (Fig. 13.11).
3. Oedematous and hyperplastic enlargements of the buccolabial mucosa, often involving the sulci, presenting as polypoid tag-like lesions or deep folds of mucosa that can mimic denture irritation hyperplasia (Fig. 13.12).
4. Aphthous (Fig. 13.13) or linear fissure-like ulcers involving any part of the mouth (Fig. 13.14).
5. Glossitis secondary to deficiency or malabsorption of iron, vitamin B₁₂, or folic acid.

Sarcoidosis

This systemic chronic granulomatous disorder of unknown aetiology most commonly affects young adults, and presents most frequently with bilateral hilar lymphadenopathy, pulmonary infiltration, and skin or eye lesions. Oral mucosal and gastrointestinal tract involvement is rare. Characteristically, the disease has an insidious onset. The signs and symptoms generally disappear in time but sometimes leave residual swelling.

Histological examination of affected tissue shows small tuberculoid granulomas consisting of macrophages and epithelioid cells, often with Langhans-type giant cells but with no caseous necrosis in the centre (Fig. 13.15). Blood examination usually shows a raised erythrocyte sedimentation rate (ESR). The level of serum angiotensin-converting enzyme (SACE) is usually raised in

active phases of the disease, the enzyme being synthesized by macrophages within the granulomas. Hypercalciuria is also common.

Sarcoid involvement of the oral mucosa is uncommon, but may present as submucosal, painless red nodules covered by normal mucosa and as erythema, granularity, or hyperplasia of the gingiva (Fig. 13.16). It may also present as orofacial granulomatosis. Salivary gland involvement (usually the parotid) may occur. The combination of uveitis, parotitis, and facial paralysis in sarcoidosis is known as uveoparotid fever, or Heerfordt syndrome.

Pyostomatitis vegetans

Pyostomatitis vegetans is a rare disorder associated with inflammatory bowel disease, especially ulcerative colitis. The lips and cheeks are diffusely inflamed with erosions, fissured ulcers, and pustules separating papillary projections and irregular outgrowths (vegetations) arising from the mucosal surface (Fig. 13.17). Cervical lymphadenitis and pyrexia are usual. Skin lesions (pyodermatitis) often occur at the same time as oral lesions. Histological examination shows acanthosis and multiple microabscesses containing numerous eosinophils at the tips of the connective tissue papillae and within the epithelium. The lamina propria is densely inflamed.

Ulcerative colitis also predisposes to recurrent aphthous stomatitis (see Chapter 12).

Wegener's granulomatosis

This systemic disease is characterized by a necrotizing, destructive granulomatous inflammation principally involving the respiratory tract, and a generalized necrotizing vasculitis. The disease may occur at any age with a peak in the fourth and fifth decades.

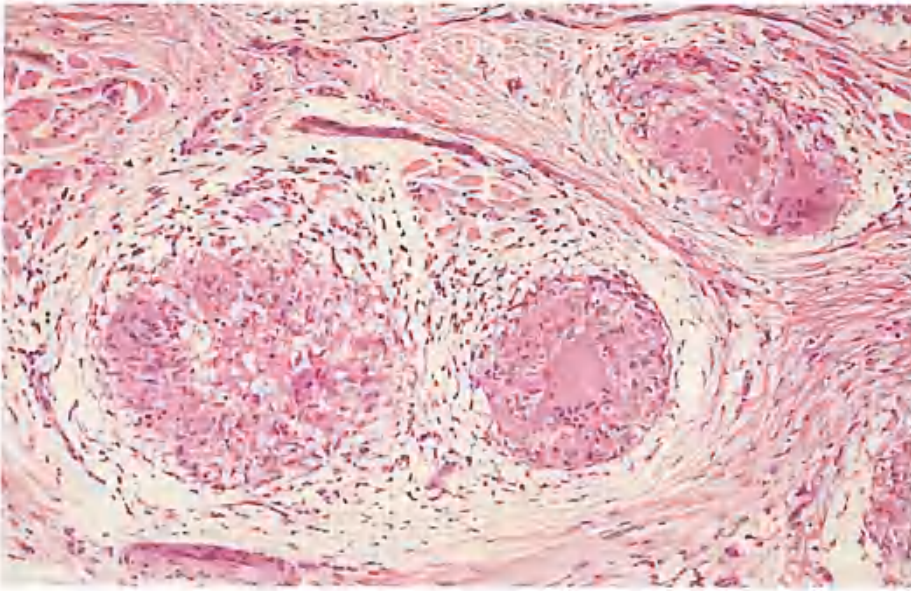


Fig. 13.15 Non-caseating granulomas in sarcoidosis.

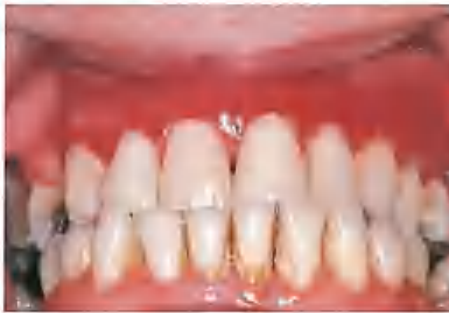

Fig. 13.16 Sarcoidosis of the gingiva.

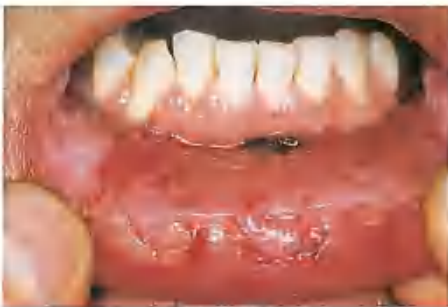

Fig. 13.17 Pyostomatitis vegetans.

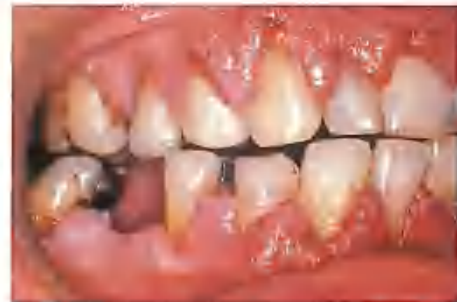

Fig. 13.18 Wegener's granulomatosis presenting as hyperplastic (strawberry) gingivitis.

Many patients present with intractable rhinitis and sinusitis, cough, and haemoptysis. The prevalence of oral lesions varies but is about 15 per cent, and very rarely they may be the presenting feature. They include a characteristic type of hyperplastic gingivitis (strawberry gingivitis) (Fig. 13.18) with heavily inflamed granular exophytic lesions, and deep, necrotic oral ulceration.

Histological examination of the lesions shows granulation tissue with a very dense mixed inflammatory cell infiltrate comprising neutrophils, eosinophils, macrophages, lymphocytes, and plasma cells. Giant cells and areas of necrosis are frequently seen.

Involved vessels characteristically show fibrinoid necrosis of their walls and intimal proliferation (Figs 13.19, 13.20). However, necrotizing vasculitis is not seen in gingival lesions, probably because the vessels are too small.

The aetiology of Wegener's granulomatosis is obscure. An autoantibody directed against cytoplasmic constituents of neutrophils (antineutrophil-cytoplasmic antibody type-c, c-ANCA) may be involved in the pathogenesis of immune vascular injury. Estimation of the level of this antibody in the serum is useful in the diagnosis of Wegener's granulomatosis, although it is not specific, and can be used as a marker of disease activity. Over 90 per cent of patients with active disease are c-ANCA positive. The disease may be controlled with corticosteroids and cytotoxic drugs, otherwise it is rapidly fatal, usually following renal failure.

Progressive systemic sclerosis (scleroderma)

Progressive systemic sclerosis is a chronic multisystem disease characterized by diffuse fibrosis (sclerosis) of the skin with similar

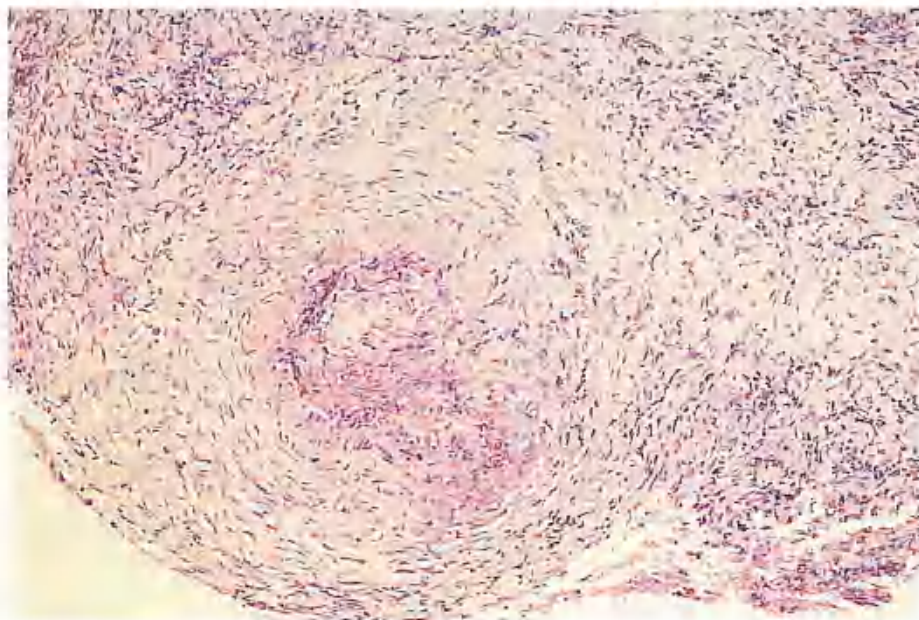


Fig. 13.19 Necrotizing vasculitis in Wegener's granulomatosis showing fibrinoid necrosis (red) and intimal proliferation almost occluding the lumen.

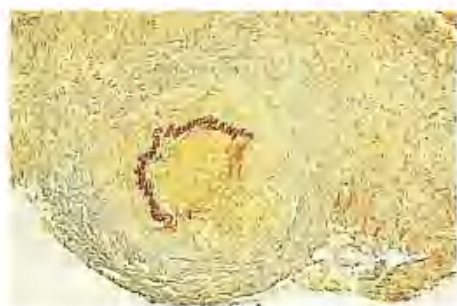

Fig. 13.20 The corresponding field to that in Fig. 13.19 stained to demonstrate elastic tissue shows disruption of the internal elastic lamina associated with necrosis.

involvement of internal organs, such as the gastrointestinal tract, lungs, and kidney. The face may be involved with the sclerosis leading to restricted mouth opening, smoothing of the lines of facial expression, and an expressionless (mask-like) face. Widening of the periodontal ligament space, particularly on posterior teeth, is a characteristic radiological finding.

The disease most commonly affects females between the ages of 20 and 50 years. It is often associated with other connective tissue disease, such as systemic lupus erythematosus or rheumatoid arthritis and occasionally Sjögren syndrome, which suggests an immunological basis and possibly an autoimmune disorder.

Verruciform xanthoma

This is an uncommon disorder which occurs most frequently on the masticatory mucosa of the gingiva and hard palate. It presents as a flat or slightly raised, but otherwise symptomless, lesion with

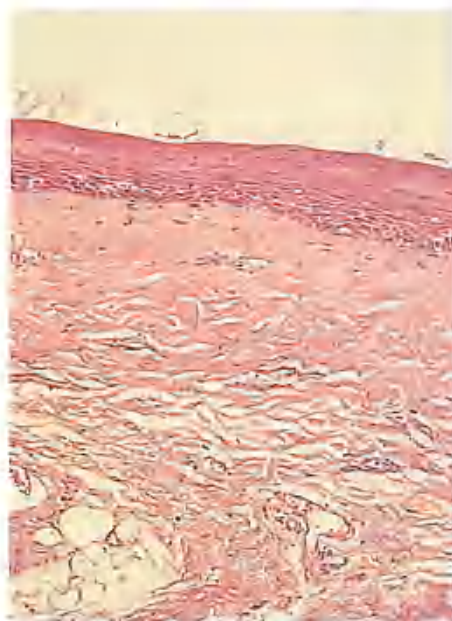


Fig. 13.21 Oral submucous fibrosis.

a papillary/warty (hence verruciform) surface. Histological examination shows hyperplastic epithelium thrown into papillary projections, but the characteristic feature is infiltration of the connective tissue papillae by lipid-containing foam cells. The infiltrate is sharply limited to the papillary lamina propria.

The aetiology of the disorder is unknown. It is not associated with HPV infection or with disorders of lipid metabolism. It is probably a reactive inflammatory process associated with focal accumulation of foam cells in reaction to release of lipid from degenerating epithelial cells.

Oral submucous fibrosis

Oral submucous fibrosis is an insidious chronic disease which may affect any part of the oral mucosa and occasionally may extend into the pharynx and oesophagus. Increasing stiffening of the oral mucosa associated with progressive underlying fibrosis leads to difficulty in opening the mouth and to a binding down of the tongue. Examination shows the mucosa to have a characteristic blanched, marble appearance, often with palpable bands of fibrous tissue. The disease occurs almost exclusively among Asiatic Indians. The aetiology is unknown, but is strongly linked to areca-nut chewing habits (betel quid, betel nut). Genetic susceptibility may also be involved, but the role of nutritional factors such as vitamin deficiency remains unclear.

Histological examination in an advanced case shows hyalinization of the subepithelial connective tissue with very few fibroblasts present and the blood vessels narrowed or totally obliterated by the fibrosis (Fig. 13.21). Lymphocytes and plasma cells are scattered throughout the hyalinized tissue. In the earlier stages the hyalinization is less intense, the vessels may be dilated, and the collagen bundles are partly separated by oedema. The overlying epithelium is generally atrophic with no rete ridges and the surface is keratinized or parakeratinized. Epithelial dysplasia has been found in about 10–15 per cent of biopsies.

Oral submucous fibrosis can be regarded as a premalignant condition because it is often associated with epithelial atrophy and dysplasia. In addition, in geographical areas where oral submucous fibrosis is common, it is found in many patients with oral carcinoma.



Fig. 13.22 Submucosal deposits of amyloid stained orange by Congo red.

Rates of malignant transformation increase with increasing duration of follow-up of patients, to about 8% over a 15–20 year period.

Amyloidosis

Amyloidosis is a disease characterized by the extracellular deposition of fibrillar proteinaceous material – amyloid – in a wide variety of tissues. The chemical structure of amyloid is variable. In primary (idiopathic) amyloidosis and amyloidosis associated with multiple myeloma it arises as a result of derangement of immunoglobulin synthesis and consists of fragments of immunoglobulin molecules. It is referred to as amyloid of immunoglobulin origin or AL type since the protein material in the amyloid fibril consists largely of fragments of immunoglobulin light (L) chains. Secondary or reactive amyloidosis occurs as a complication of a variety of other diseases, especially chronic destructive inflammatory lesions, such as rheumatoid arthritis, and certain malignant conditions. This type is chemically distinct from the AL type and does not contain light-chain fragments. In reactive amyloidosis the fibrils are composed of amyloid A protein (AA type), a polypeptide related to an acute-phase protein found in serum. Amyloid-like material is also a feature of the calcifying epithelial odontogenic tumour (see Chapter 15).

Oral manifestations are described in primary amyloidosis, and in amyloidosis associated with multiple myeloma; macroglossia is the best known feature. This may occur in up to half of the patients but is usually a late event. The enlargement of the tongue is usually diffuse and symmetrical and the lateral borders may be indented by adjacent teeth. Mobility is diminished and the tongue is firm and indurated. Other oral manifestations include petechiae, ecchymoses, haemorrhagic bullae which rupture leaving shallow ulcers, and localized amyloid deposits in the form of yellowish macules or papules, but widespread symptomless infiltration of oral tissues also occurs. Involvement of salivary glands may result in xerostomia.

Where amyloidosis is suspected on clinical grounds, diagnosis must be confirmed by biopsy and the identification of deposits by various staining reactions. Classically, amyloid is positively stained by Congo red (Fig. 13.22), and when then viewed with polarized light produces a characteristic apple-green birefringence. Even in suspected cases, without apparent oral involvement, biopsy of the tongue or of gingival tissues may be a useful diagnostic test. The prognosis for most patients with primary, and many with secondary, amyloidosis is poor.

Oral pigmentation

Oral pigmentation may result from the localization of exogenous substances on or within the mucosa, or may be due to deposition in the tissues of endogenous pigments (i.e. substances produced by the body), of which melanin is the most common.

The main causes of oral mucosal pigmentation are listed in Table 13.1. Some of the conditions are described elsewhere in this book.

Table 13.1 Causes of oral mucosal pigmentation

I. Exogenous pigmentation	
Superficial staining of the mucosa	
Black hairy tongue	
Foreign bodies	
amalgam tattoo	
miscellaneous	
Heavy metal salts	
II. Endogenous pigmentation due to melanin	
Developmental causes	
Racial pigmentation	
Pigmented naevi	
Peutz-Jeghers syndrome	
Acquired causes	
Associated with systemic disease	
Addison's disease	
pulmonary disease	
HIV infection	
Associated with hyperkeratosis, chronic inflammation, and lichen planus	
Drug-induced	
Idiopathic oral melanotic macule (oral freckle)	
Lentigo simplex	
Neoplastic causes	
Malignant melanoma <i>in situ</i>	
Malignant melanoma	
III. Other endogenous pigments	
Blood breakdown products and disturbances of iron metabolism	

Superficial staining of the mucosa

This may be caused by a great variety of foods, drinks, and topical medicaments, as well as habits such as chewing betel nut or betel quid, and smoking or chewing tobacco.

Black hairy tongue

This is a condition in which there is marked hyperplasia of filiform papillae, sometimes up to about 1 cm in length, and discoloration associated with overgrowth of pigment-producing bacteria and fungi (Fig. 13.23). The aetiology is unknown but smoking may be a factor, and in some patients the disorder follows antibiotic therapy suggesting that disturbance of the normal oral flora is also involved. The condition is usually symptomless but 'tickling' of the soft palate may cause gagging and nausea. Black hairy tongue should be distinguished from a simple staining where there is no associated overgrowth of filiform papillae.

Foreign bodies

A variety of foreign substances may be implanted in the oral mucosa giving rise to localized areas of pigmentation. Amalgam is the commonest and best known example but other materials include road grit following road traffic accidents and traumatic implantation of graphite in lead-pencil chewers. Some individuals may even have artistic tattooing of the mucosa (Fig. 13.24).

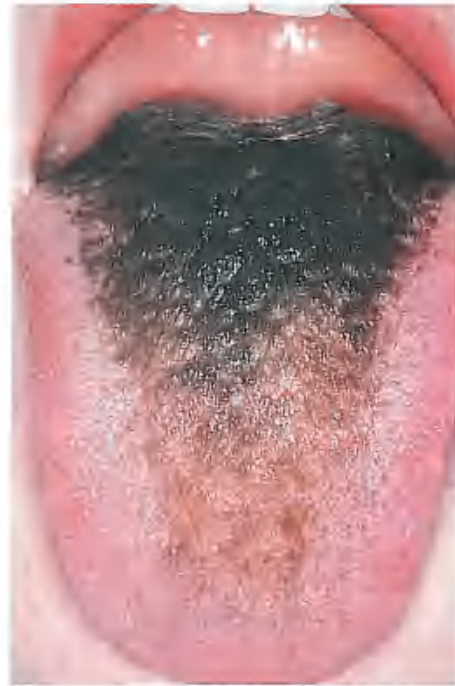

Fig. 13.23 Black hairy tongue.

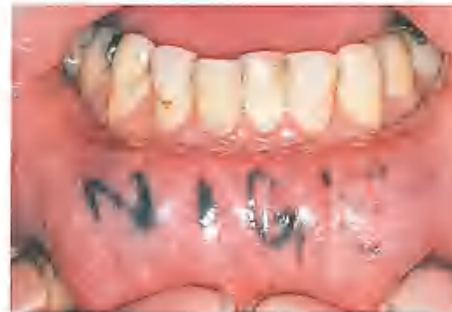

Fig. 13.24 Tattooing of the oral mucosa.

Amalgam tattoo

This is a relatively common, often incidental clinical finding, which rarely produces symptoms other than that of an area of discoloration. It manifests as a localized blue/black or greyish area (Fig. 13.25) and is due to the introduction of amalgam into the soft tissues during such dental procedures as the insertion or removal of restorations, the extraction of teeth when portions of fractured restorations may fall into sockets, and retrograde filling of a root canal after apicectomy. The tattoos may be found in any part of the mouth but are most common in mandibular gingival or alveolar mucosa (Figs 13.26, 13.27). Histologically, the pigment is present as widely dispersed, fine brownish or blackish granules, or as solid fragments of varying size which when large may be detected on radiographs. The pigment granules may be scattered haphazardly but are often associated with collagen and elastic fibres and basement membranes, and may be seen intra-

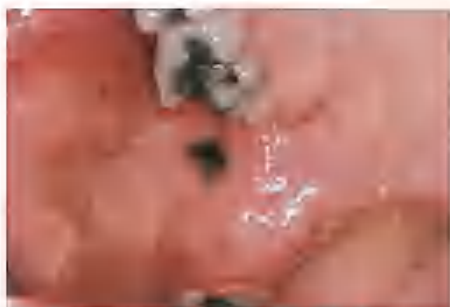


Fig. 13.25 Amalgam tattoo of the buccal mucosa.

cellularly within fibroblasts, endothelial cells, macrophages, and occasional foreign-body giant cells (Fig. 13.28). Apart from the macrophages and giant cells there is little or no tissue reaction. Ultrastructural and analytical studies have shown that the amalgam is slowly corroded and that mercury, together with some tin, is lost leaving silver residues. The silver released by corrosion may become associated with sulphur and be picked up by various cells and fibres in the connective tissue.

Heavy metal salts

Deposits of metallic sulphides in the marginal gingiva are now rarely seen. They may follow absorption of bismuth, lead, or mercuric salts either as a result of environmental or occupational exposure or, historically, following therapeutic administration. The salts are present in crevicular fluid and are precipitated as sulphides by the action of hydrogen sulphide released as a waste product from plaque organisms. The precipitates cause linear grey or blue/black lines of pigmentation which follow the gingival contour around the necks of the teeth. Faint purplish discoloration of the gingiva may also follow prolonged therapeutic administration of gold compounds, the pigmentation being due mainly to deposition of colloidal metal itself rather than gold salts.

Melanin pigmentation – developmental causes

Melanin is the commonest of the endogenous pigments in skin and oral mucosa, and is produced by melanocytes present in the basal layer of the epithelium. These specialized dendritic cells are of neural crest origin. Melanin is formed in melanosomes

within the cytoplasm of melanocytes, the melanin then passing into the dendritic processes to be injected into, or ingested by, neighbouring keratinocytes.

There is no difference in the number of melanocytes between fair- and dark-skinned individuals, the variation in skin and mucosal pigmentation between racial groups being related to differences in activity of the melanocytes. The intensity and distribution of racial pigmentation of the oral mucosa is very variable not only between races but also between different individuals of the same race and within different areas of the same mouth. Pigment may be found in any part of the mucosa but the gingiva is the most common site (Fig. 13.29).

Pigmented naevi are the commonest cause of abnormal melanin pigmentation of skin and every person has a variable number of such lesions, between 20 and 30 on average. However, they are relatively rare in oral mucosa (see Chapter 10).

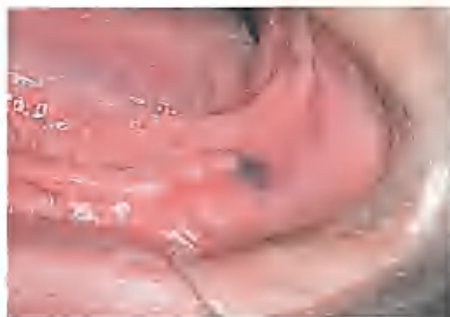Hypermelanic pigmentation of skin and/or oral mucosa is also associated with various other developmental conditions which are not primarily disorders of the melanocyte system.

Peutz-Jeghers syndrome is transmitted through an autosomal dominant gene and is characterized by mucocutaneous pigmentation and gastrointestinal polyposis. The polyposis chiefly affects the small intestine and the lesions are not generally considered as premalignant. The melanic pigmentation resembles freckling and appears in infancy. In the mouth the buccal mucosa and lips (Figs 11.3, 13.30) are usually affected and skin pigmentation occurs rather characteristically around the mouth, nostrils, and eyes. Other areas of the skin and other mucosae may be affected. There is a tendency for the skin pigmentation to fade in adult life but the mucosal pigmentation persists.

Melanin pigmentation of skin, described as *café-au-lait* spots because of their light brown colour, is also seen in some cases of polyostotic fibrous dysplasia and in patients with neurofibromatosis. Pigmentation of the oral mucosa is absent or has only rarely been recorded.

Melanin pigmentation – acquired causes

Acquired melanosis of the oral mucosa may be a manifestation of systemic disease, malignancy, or of a simple local disorder. It is an important sign indicating the need for careful investigation of the patient.



Figs 13.26, 13.27 Amalgam tattoo associated with a large fragment of a restoration detectable on radiograph.

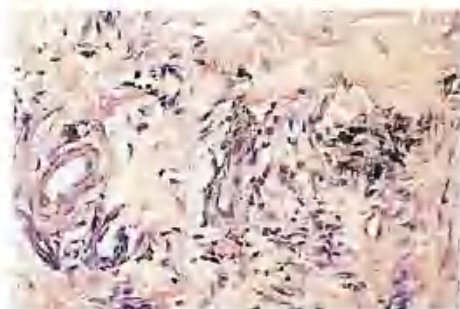


Fig. 13.28 Finely dispersed pigmented silver residues in an amalgam tattoo.

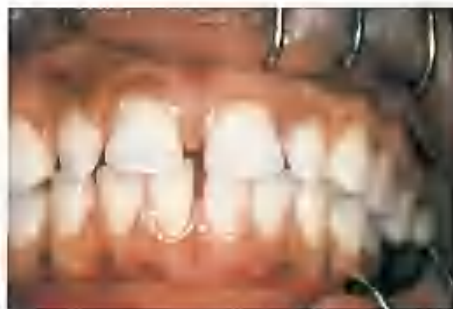

Fig. 13.29 Racial pigmentation.

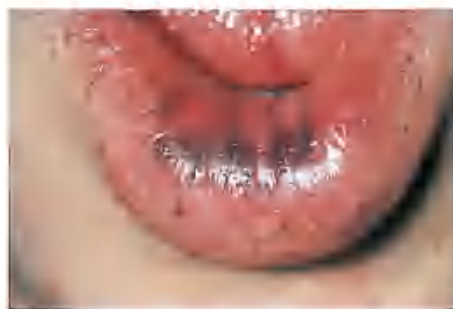

Fig. 13.30 Pigmentation of the lip in Peutz-Jeghers syndrome.

Key points – Abnormal melanin pigmentation

- underlying local and/or systemic factors must be considered
- may precede malignant melanoma

The association of oral pigmentation with Addison's disease is well recognized and may be the initial manifestation of adrenal insufficiency. Adrenal insufficiency results in elevated secretion of adrenocorticotrophic hormone (ACTH) by the pituitary, the melanocyte-stimulating properties of the heptapeptide core probably being responsible for the pigmentation. The pigmentation is most common in areas subjected to masticatory trauma, especially the cheeks, but can involve any part of the oral mucosa. Oral hypermelanosis may also be seen in patients with HIV infection (see Chapter 11).

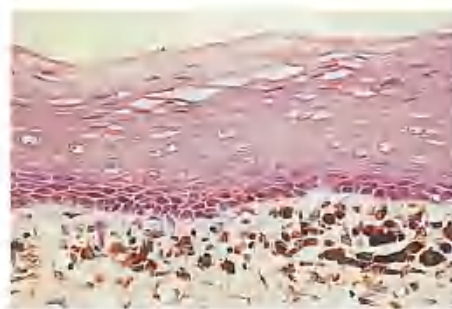


Fig. 13.31 Incontinence of melanin associated with hyperkeratosis showing melanin pigment in subepithelial macrophages.

Melanin pigmentation is an occasional feature of some hyperkeratoses, giving the lesions a dusky or greyish hue, and less commonly of some other chronic inflammatory mucosal diseases. In many patients with pigmented hyperkeratosis smoking appears to be an important aetiological factor. An association between smoking, pigmentation of the soft palate, and pulmonary disease, especially bronchogenic carcinoma, has also been shown. The pigmentation is presumably a reaction of melanocytes to chronic irritation and there may also be some associated dysfunction in the transfer and/or uptake of melanin from melanocytes to keratinocytes. This is suggested since much of the melanin in these lesions is present in subepithelial macrophages having apparently leaked out of melanocytes and/or basal cells (melanin incontinence) (Fig. 13.31). Similar changes may be seen in lichen planus as a result of basal cell degeneration and may persist after the lesions have healed.

Drug-induced melanin pigmentation of the oral mucosa is rare, but may be seen in some patients taking various cytostatic agents and may also be produced by progestogens in oral contraceptives. Pigmentary changes, especially of the hard palate, may be seen in patients taking antimalarial drugs. The nature of this pigment is uncertain but melanin may be involved. Oral pigmentation has also been reported in patients taking minocycline, a tetracycline derivative widely used for the treatment of acne. As with other tetracyclines the drug may also be incorporated in and cause discoloration of bones and teeth (see Chapter 3).

Occasionally, patients present with single, or less frequently multiple, pigmented macules of the oral mucosa which cannot be classified histologically into any of the recognized types of melanotic lesion and for which no local or systemic cause can be found. They occur more often in women than in men and usually present around 40 years of age. The vermillion border of the lower lip, gingiva, and buccal mucosa are the commonest sites. Histological examination shows a localized area of increased melanin pigment in the basal cell layer, with or without melanin incontinence. The term 'idiopathic oral melanotic macule' (Figs 13.32, 13.33) has been applied to this lesion but it is also referred to as an oral ephelis (freckle). The lesion is not associated with increase in the number of melanocytes or with melanocytic atypia. It has no sinister connotations.

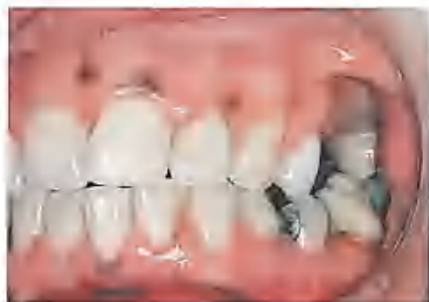

Fig. 13.32 Idiopathic oral melanotic macules.

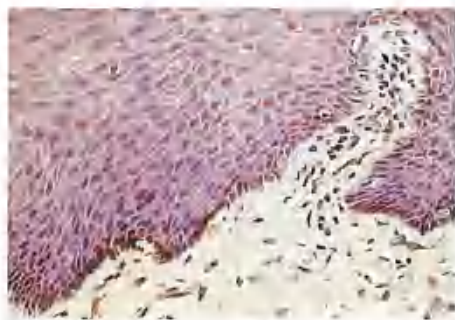


Fig. 13.33 Histological appearances of a melanotic macule showing hypermelanosis in the basal layer.

Primary malignant melanoma of the oral mucosa is rare and is discussed in Chapter 10.

Other endogenous pigments

Oral pigmentation due to other endogenous substances is uncommon apart from transitory discoloration caused by blood breakdown products in a haematoma and the yellowish hue produced by bilirubin in patients with jaundice (Fig. 13.34).

Pigmentation associated with disturbances of iron metabolism is seen in the rare disorder, haemochromatosis. Haemosiderin is deposited in many organs and tissues and there is also pigmentation of the skin and oral mucosa. Classically, the pigmentation produces coppery or bronze discoloration and is chiefly due to melanin, although haemosiderin is also deposited. The serious manifestations are due to deposition of haemosiderin in the myocardium, liver, and pancreas.

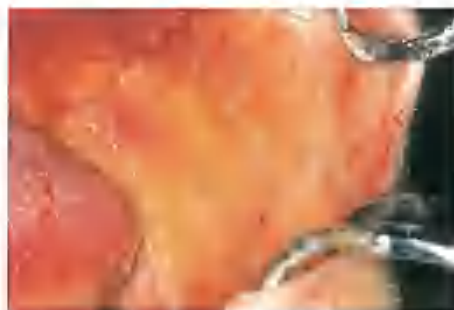

Fig. 13.34 Yellow pigmentation of the oral mucosa in a patient with jaundice.

Age changes in the oral mucosa

Although a variety of changes may occur in the oral mucosa of the elderly, distinguishing those attributable to ageing from those due to systemic disease, nutritional deficiencies, or the side-effects of medication can be difficult. Atrophic changes have been reported in lingual mucosa related to an almost linear reduction in epithelial thickness with increasing age, by about 30 per cent of the initial thickness around 85 years of age. However, this may not apply to other oral mucosal surfaces. The question of whether increased keratinization of the oral mucosa occurs in old age has not been resolved.

Oral mucosal connective tissues become more fibrosed, less vascular, and less cellular with age. Atherosclerotic changes are also seen in arteries of the oral mucosa, and a progressive, partial ischaemia may contribute to some of the atrophic changes.

Certain local oral mucosal lesions are reported to occur more frequently in the elderly, examples being sublingual varices, increased prominence of Fordyce's granules, and enlargement of foliate papillae, but supportive evidence is often lacking.

Further reading

- Assimakopoulos, D., Parrikakos, G., Fotika, C., and Elisof, M. (2002). Benign migratory glossitis or geographic tongue: an enigmatic lesion. *American Journal of Medicine*, 113, 751–5.
- Cox, S. C. and Walker, D. M. (1996). Oral submucous fibrosis: a review. *Australian Dental Journal*, 41, 294–9.
- Editorial (1991). Orofacial granulomatosis. *Lancet*, 338, 20–1.
- Handlers, J. P., Waterman, J., Abrams, A. M., and Melrose, R. J. (1985). Oral features of Wegener's granulomatosis. *Archives of Otolaryngology*, 111, 267–70.
- Harrison, J. D., Rowley, P. S. A., and Peters, P. D. (1977). Amalgam tattoos: light and electron microscopy and electron-probe microanalysis. *Journal of Pathology*, 121, 83–92.
- Healy, C. M., Farthing, P. M., Williams, D. M., and Thornhill, M. H. (1994). Pyostomatitis vegetans and associated systemic disease. *Oral Surgery, Oral Medicine, Oral Pathology*, 78, 323–8.
- Israelson, H., Binnie, W. H., and Hurt, W. C. (1981). The hyperplastic gingivitis of Wegener's granulomatosis. *Journal of Periodontology*, 52, 81–7.
- Kaugars, G. E., Heise, A. P., Riley, W. T., Abbey, L. M., and Svirsky, J. A. (1993). Oral melanotic macules. A review of 353 cases. *Oral Surgery, Oral Medicine, Oral Pathology*, 76, 59–61.
- Murti, P. R., Bhonsle, R. B., Gupta, P. C., Daftary, D. K., Pinborg, J. J., and Mehta, F. S. (1995). Etiology of oral submucous fibrosis with special reference to the role of areca nut chewing. *Journal of Oral Pathology and Medicine*, 24, 145–52.
- Philipsen, H. P., Reichart, P. A., Takata, T., and Ogawa, I. (2003). Verruciform xanthoma: biological profile of 282 oral lesions based on a literature survey with nine new cases from Japan. *Oral Oncology*, 39, 325–36.

- Pillai, R., Balaram, P., and Reddiar, K. S. (1992). Pathogenesis of oral submucous fibrosis. Relationship to risk factors associated with oral cancer. *Cancer*, 69, 2011-20.
- Sainsbury, C. P. Q., Dodge, J. A., Walker, D. M., and Aldred, M. J. (1987). Orofacial granulomatosis in childhood. *British Dental Journal*, 163, 154-7.
- Scheper, H. J. and Brand, H. S. (2002). Oral aspects of Crohn's disease. *International Dental Journal*, 52, 163-72.
- Scully, C. and Porter, S. R. (1994). Oral mucosal disease: a decade of new entities, aetiologies and associations. *International Dental Journal*, 44, 33-43.
- Weisenfeld, D., Ferguson, M. M., Mitchell, D. N., Macdonald, D. G., Scully, C., Cochran, K., and Russell, R. I. (1985). Oro-facial granulomatosis—a clinical and pathological analysis. *Quarterly Journal of Medicine, New Series*, 54, No. 213, 101-13.
- Zhu, J. F., Kaminski, M. J., Pulitzer, D. R., Hu, J., and Thomas, H. F. (1996). Psoriasis: pathophysiology and oral manifestations. *Oral Diseases*, 2, 135-44.

Diseases of salivary glands

DEVELOPMENTAL ANOMALIES

SIALADENITIS

- Bacterial sialadenitis**
- Viral sialadenitis**
- Postirradiation sialadenitis**
- Sarcoidosis**
- Sialadenitis of minor glands**

OBSTRUCTIVE AND TRAUMATIC LESIONS

- Salivary calculi (sialoliths)**
- Necrotizing sialometaplasia**

SJÖGREN SYNDROME

SIALADENOSIS

HIV-ASSOCIATED SALIVARY GLAND DISEASE

SALIVARY GLAND TUMOURS

- Classification**
- Adenomas**
- Carcinomas**

AGE CHANGES IN SALIVARY GLANDS

FURTHER READING

1870
1871
1872
1873
1874
1875
1876
1877
1878
1879
1880
1881
1882
1883
1884
1885
1886
1887
1888
1889
1890
1891
1892
1893
1894
1895
1896
1897
1898
1899
1900

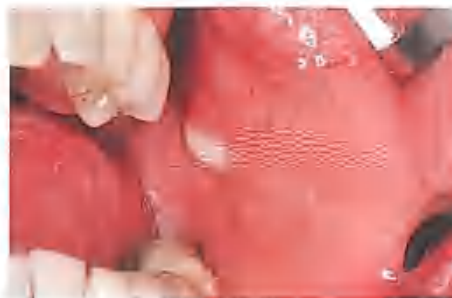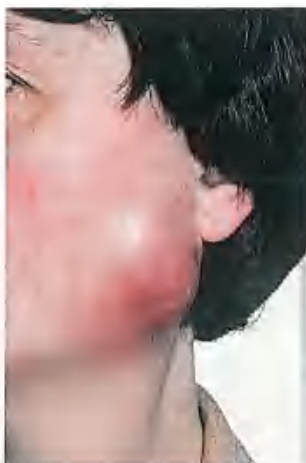Diseases of salivary glands

The salivary glands consist of three paired major glands, parotid, submandibular, and sublingual, and the countless minor salivary glands found in almost every part of the oral cavity, except the gingiva and anterior regions of the hard palate. The secretion of saliva is essential for the normal function and health of the mouth, and disorders of salivary gland function, which affect the composition and secretion of saliva, predispose to oral disease. Functional disorders in salivary secretion and composition may be associated with organic disease of the salivary glands, but in other cases are caused by systemic factors, such as neurological disease, drug therapy, and endocrine disturbances. This chapter is only concerned with organic salivary gland diseases; for further discussion of functional disorders, the reader is referred to texts in oral medicine.

Developmental anomalies

Developmental anomalies of the salivary glands are rare. Aplasia of one or more major glands and atresia of one or more major salivary gland ducts have been reported. Congenital aplasia of the parotid gland may be associated with other facial abnormalities, for example mandibulofacial dysostosis, aplasia of the lacrimal glands, and hemifacial microsomia.

Heterotopic salivary tissue has been reported from a variety of sites in the head and neck, the most frequent being its inclusion at the angle or within the body of the mandible, presenting as



Stafne's idiopathic bone cavity (see Chapter 6). Accessory parotid tissue within the cheek or masseter muscle is relatively common and is subject to the same diseases that may affect the main gland.

Sialadenitis

Inflammatory disorders of the major salivary glands are usually the result of bacterial or viral infection but occasionally sialadenitis is due to other causes, such as trauma, irradiation, and allergic reactions.

Bacterial sialadenitis

Bacterial sialadenitis may present as an acute or chronic condition.

Acute bacterial sialadenitis

This uncommon disorder principally involves the parotid gland. Acute parotitis is an ascending infection, that is, the bacteria reach the gland from the mouth by ascending the ductal system, the main organisms involved being *Streptococcus pyogenes* and *Staphylococcus aureus*. Less commonly, *Haemophilus* species or members of the 'black-pigmented bacteroides' group may be isolated. It was once a common postoperative complication in debilitated and dehydrated patients, particularly following abdominal surgery, but is a rare complication nowadays. Reduced salivary flow is the major predisposing factor, and acute parotitis may occur in patients with Sjögren syndrome or following the use of drugs with xerostomic side-effects. Acute infection may also arise in immunocompromised patients or as a result of acute exacerbation in a previously chronic sialadenitis. The latter is usually the cause when acute sialadenitis involves the submandibular gland.

Figs 14.1, 14.2 Acute bacterial sialadenitis of the parotid gland with pus being expressed from the duct.

The onset of acute sialadenitis is rapid. Clinically, it presents as swelling of the involved gland accompanied by pain, fever, malaise, and redness of the overlying skin. Pus may be expressed from the affected duct (Figs 14.1, 14.2).

Chronic bacterial sialadenitis

Chronic sialadenitis of the major salivary glands is usually a non-specific inflammatory disease associated with duct obstruction, most often due to salivary calculi (discussed later in this chapter) and low-grade ascending infection. The submandibular gland is much more commonly involved than the parotid gland. In cases where no cause of obstruction can be identified, the predisposing factor may be a disorder of secretion resulting in decreased salivary flow. The sialadenitis is usually unilateral, and the symptoms of recurrent tender swelling of the affected gland are mainly related to the associated obstruction. The duct orifice may appear inflamed and in acute exacerbations there may be a purulent or salty-tasting discharge. Histological examination shows varying degrees of dilatation of the ductal system, hyperplasia of duct epithelium, periductal fibrosis, acinar atrophy with replacement fibrosis, and chronic inflammatory cell infiltration (Figs 14.3, 14.4). The duct obstruction, destruction of glandular tissue, and duct dilatation (sialectasia) may be demonstrated by sialography.

In the submandibular gland, progressive chronic inflammation may result eventually in almost complete replacement of the parenchyma by fibrous tissue (Fig. 14.4) producing a firm mass

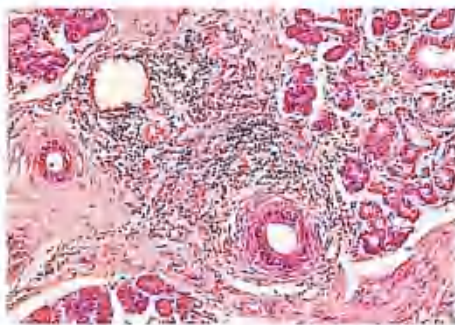


Fig. 14.3 Chronic bacterial sialadenitis showing early perioductal chronic inflammation and fibrosis.

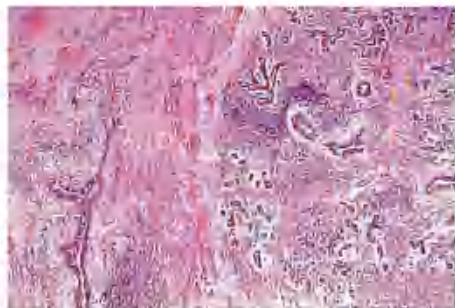


Fig. 14.4 Destruction of glandular tissue and extensive replacement fibrosis in long-standing chronic bacterial sialadenitis.

that may be mistaken clinically for a neoplasm. This type of inflammatory reaction may be referred to as chronic sclerosing sialadenitis.

Recurrent parotitis

Recurrent parotitis is a rare disorder which can affect children or adults. Rarely the adult form may follow on from the childhood type, but in most cases it is probably due to persistence of factors, such as calculi or duct strictures, leading to recurrent attacks of low-grade ascending infection.

The aetiology of the childhood type is unclear but an abnormally low secretion rate predisposing to ascending infection and immaturity of the immune response in infants may be involved. Congenital abnormalities of the ductal system have also been suggested and almost all cases show sialectasia or some other duct abnormality on sialography. The condition may be unilateral or bilateral and is associated with recurrent painful swelling of the gland. Pus may be expressed from the duct orifice. In most cases the condition resolves spontaneously by the time the patient reaches early adult life, but repeated infection may result in irreversible damage to the main duct predisposing to duct obstruction. This may lead to further episodes of ascending infection and damage and to recurrent parotitis in adult life.

Viral sialadenitis

Mumps (epidemic parotitis)

Mumps is an acute, contagious infection which often occurs in minor epidemics and is caused by a paramyxovirus. It is the commonest cause of parotid enlargement and the commonest of all the salivary gland diseases. Although infection can occur at any age, it is most common in childhood. The virus is transmitted by direct contact with infected saliva and by droplet spread, and has an incubation period of 2–3 weeks. Non-specific prodromal symptoms of fever and malaise are followed by painful swelling of sudden onset involving one or more salivary glands. The parotid glands are almost always involved, bilaterally in about 70 per cent of cases, and occasionally the submandibular and sublingual glands may be affected, but rarely without parotid involvement

Key points – Bacterial sialadenitis

- ascending infections associated with decreased salivary flow
- may be acute or chronic
- acute: uncommon, mainly parotid gland, suppurative inflammation
- chronic: mainly submandibular gland, associated with salivary calculi
- chronic: acinar atrophy, chronic inflammation, and replacement fibrosis

also. The salivary gland enlargement gradually subsides over a period of about 7 days. The virus is present in the saliva 2–3 days before the onset of sialadenitis and for about 6 days afterwards.

Occasionally in adults other internal organs are involved, such as testes, ovaries, central nervous system, and pancreas. Orchitis is the most common complication, occurring in about 20 per cent of cases of mumps in adult males.

The diagnosis of mumps is usually made on clinical grounds, but in atypical cases can be confirmed by the detection of IgM class antibodies and by the rise in serum antibody titre to mumps virus antigens which occurs within the first week. After an attack immunity is long-lasting and so recurrent infection is rare.

Cytomegalic inclusion disease (salivary gland inclusion disease)

Infection with cytomegalovirus, a member of the herpesvirus group, is common in humans and endemic worldwide. Most primary infections are asymptomatic, but the virus can cause severe disseminated disease in neonates and in immunocompromised hosts such as transplant patients and HIV-infected patients (see Chapter 11). Salivary gland involvement is usually an incidental histological finding, the characteristic feature being the presence of large, doubly contoured 'owl-eye' inclusion bodies within the nucleus or cytoplasm of duct cells of the parotid gland. It may be associated with xerostomia in HIV-infection. In disseminated disease similar inclusions frequently occur in the kidneys, liver, lungs, brain, and other organs.

Postirradiation sialadenitis

Radiation sialadenitis is a common complication of radiotherapy and there is a direct correlation between the dose of irradiation and the severity of the damage. The latter is often irreversible leading to fibrous replacement of the damaged acini and squamous metaplasia of ducts, but with less severe damage some degree of function may return after several months. Serous acini are more sensitive to radiation damage than mucous acini.

Sarcoidosis

Sarcoidosis (see Chapter 13) may affect the parotid and minor salivary glands. Parotid involvement presents as persistent, often painless, enlargement and may be associated with involvement of the lacrimal glands in Heerfordt syndrome.

Sialadenitis of minor glands

Sialadenitis of minor glands is often an incidental and insignificant finding although it may be of diagnostic significance, for example in sarcoidosis and Sjögren syndrome. However, it is seen most frequently in association with mucous extravasation cysts and stomatitis nicotina of the palate.

Very rarely, sialadenitis of minor glands may present with multiple mucosal swellings associated with cystic dilatation of ducts and chronic suppuration. This condition may be referred to as stomatitis glandularis. It occurs most commonly on the lips, and

probably represents an acute exacerbation of a previously chronic sialadenitis associated with obstruction, for example from denture trauma, or reduction in salivary flow.

Obstructive and traumatic lesions

Duct obstruction and trauma are important factors in the aetiology of a number of salivary gland diseases, such as chronic sialadenitis in major glands and mucoceles in minor glands (salivary cysts are discussed in Chapter 6). Duct obstruction may be due to a blockage within the lumen or result from disease in or around the duct wall, such as fibrosis or neoplasia. It can involve any part of the ductal tree. Obstruction to the duct orifice is usually due to chronic trauma, for example from sharp cusps or overextended dentures, resulting in fibrosis and stenosis.

Salivary calculi (sialoliths)

Salivary calculi cause obstruction within the duct lumen and can occur at any age, but are most common in middle-aged adults. Calculi may form in ducts within the gland or in the main excretory duct. Data on their distribution vary considerably but the submandibular gland is most frequently involved, accounting for about 70–90 per cent of cases (Fig. 14.5). The parotid gland is the next most commonly involved, whereas sialolithiasis in sublingual and minor glands is uncommon and generally accounts for only about 2 per cent of cases. Calculi are usually unilateral, although multiple stones in the same gland are not uncommon. The typical signs and symptoms of calculi associated with major glands are pain and sudden enlargement of the gland, especially at meal times when salivary secretion is stimulated. The reduction in salivary flow predisposes to ascending infection and chronic sialadenitis. The calculi may be detected by palpation and on radiographs, and may be round or ovoid, rough or smooth, and vary considerably in size. They are usually yellowish in colour and comprise mainly calcium phosphates with smaller amounts of carbonates (Fig. 14.6). On section, they may be homogeneous but many have a lamellated structure (Fig. 14.7).

The aetiology and pathogenesis of salivary calculi are largely unknown. It is generally thought that they form by deposition of

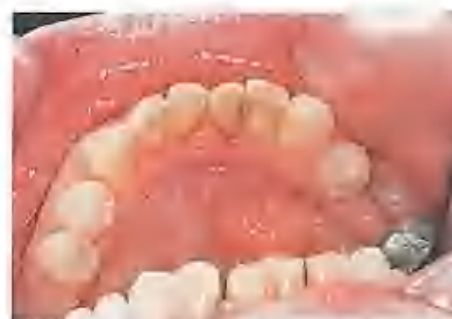

Fig. 14.5 Swelling of the floor of the mouth associated with a calculus in the submandibular duct.

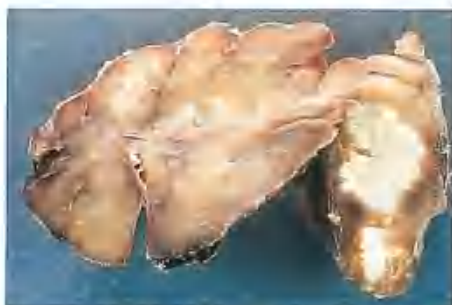

Fig. 14.6 Calculus in the intraglandular portion of the submandibular duct.

calcium salts around an initial organic nidus which might consist of altered salivary mucins together with desquamated epithelial cells and microorganisms. Successive deposition of inorganic and organic material would produce a lamellated calculus. Ultrastructural studies have also shown that microcalculi form in acinar cells and stagnant secretions of the submandibular gland, especially during periods of secretory inactivity. Although in the normal gland these microcalculi are eliminated, if there is disturbed secretion they could accumulate and lead to the formation of calculi.

Necrotizing sialometaplasia

Necrotizing sialometaplasia is a relatively uncommon disorder which clinically and on histological examination may be mistaken for malignant disease. It occurs most frequently on the hard plate in middle-aged patients and is about twice as common in men as women. It presents most commonly as a deep crater-like ulcer which may mimic a malignant ulcer and which may take up to 10–12 weeks to heal. In some cases the ulcer may be preceded by an indurated swelling.

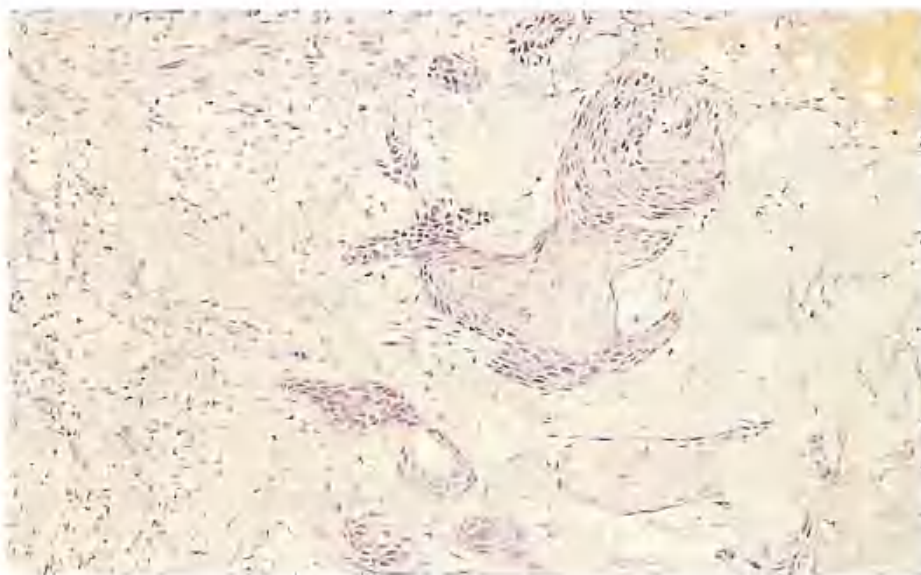


Fig. 14.8 Necrosis of salivary tissue and squamous metaplasia of ducts in necrotizing sialometaplasia.

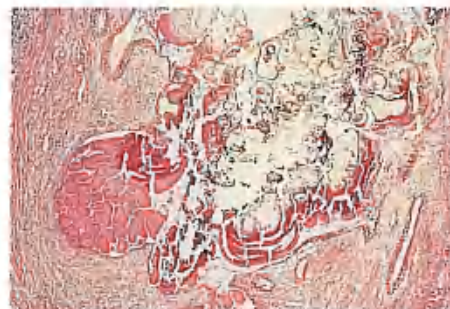


Fig. 14.7 Decalcified section showing a lamellated calculus in dilated submandibular duct.

Key points – Duct obstruction and salivary calculi

- duct obstruction may be due to blockage of the lumen, disease in/around the duct wall, stenosis of the orifice
- salivary calculi are commonest cause of duct obstruction
- salivary calculi occur mainly submandibular gland or duct
- recurrent swelling related to gustatory stimuli
- duct obstruction predisposes to ascending infection and chronic sialadenitis

Histopathological examination shows lobular necrosis of salivary glands, squamous metaplasia of ducts and acini, mucous extravasation, and inflammatory cell infiltration (Fig. 14.8). The overlying palatal mucosa shows pseudoepitheliomatous hyperplasia and the histopathological features may be mistaken for either squamous cell carcinoma or mucoepidermoid carcinoma (discussed later in this chapter).

The aetiology of the condition is unknown, but ischaemia leading to infarction of salivary lobules is the most widely accepted theory. In some patients there may be a history of trauma from a variety of causes, including local anaesthetic injection and previous surgery.

Sjögren syndrome

Sjögren syndrome is a chronic autoimmune disease characterized by lymphocytic infiltration and acinar destruction of lacrimal and salivary glands, leading to dry eyes and dry mouth. In about half of the cases the syndrome occurs in association with another autoimmune disease, most frequently rheumatoid arthritis or systemic lupus erythematosus. On this basis the syndrome is divided into:

- (1) *primary Sjögren syndrome* – the combination of dry mouth (xerostomia), and dry eyes (xerophthalmia or keratoconjunctivitis sicca);
- (2) *secondary Sjögren syndrome* – the triad of xerostomia, xerophthalmia, and an autoimmune connective tissue disease (usually rheumatoid arthritis) (Figs 14.9–14.11).

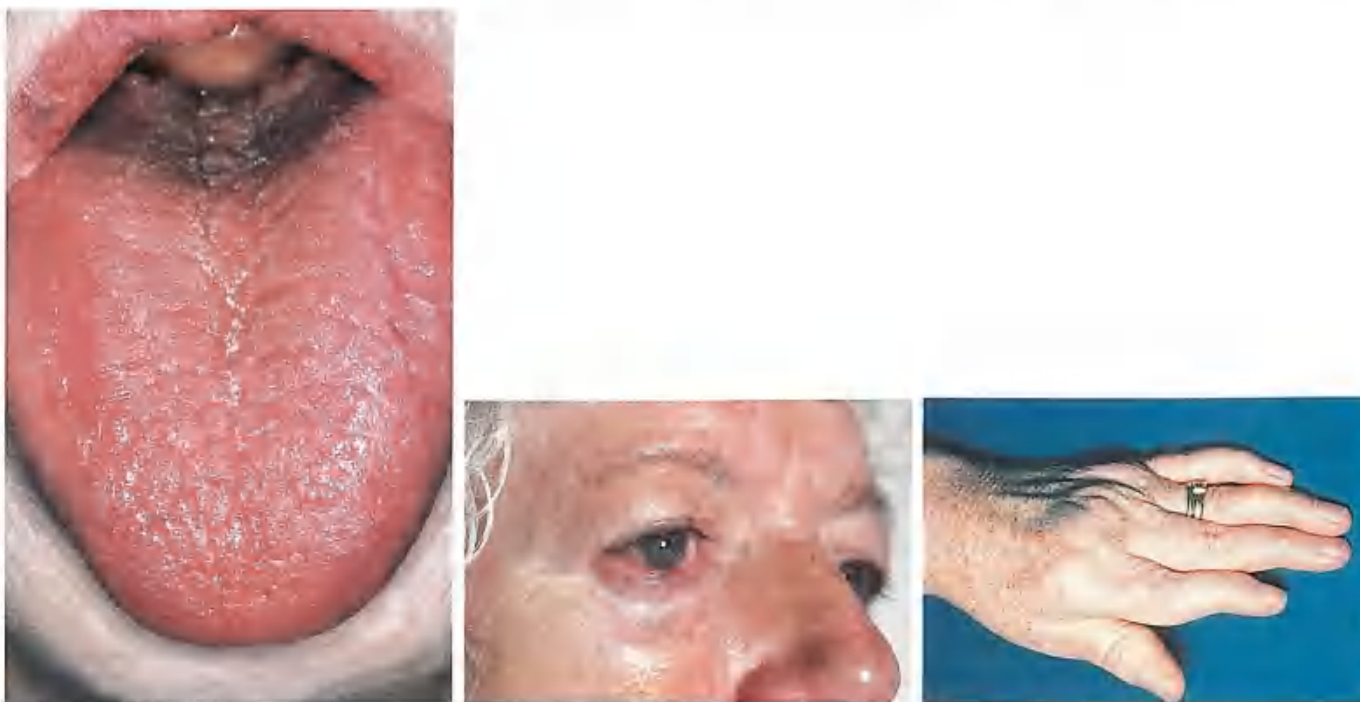Primary Sjögren syndrome is also known as the sicca syndrome. Unless otherwise specified, the general term 'Sjögren syndrome' is used to encompass both types. In addition to xerostomia and xerophthalmia, Sjögren syndrome can present with a wide spectrum of clinical features involving abnormalities of other exocrine glands and a variety of extraglandular manifestations

Table 14.1 Manifestations of Sjögren syndrome

<i>Glandular (exocrine glands)</i>	
Salivary	– xerostomia
Lacrimal	– xerophthalmia
Skin	– xeroderma
Respiratory tract	– nasal dryness, sinusitis, tracheitis
Pharynx and GI tract	– dysphagia, atrophic gastritis, pancreatitis
Reproductive system	– vaginal dryness
<i>Extraglandular</i>	
Joints	– arthritis
Skin	– purpura, Raynaud's phenomenon
Liver	– primary biliary cirrhosis
Renal	– renal tubular defects
Endocrine	– thyroiditis
Neurological	– central and peripheral neuropathies
Haematological	– anaemia, leucopenia, thrombocytopenia
Immunological	– autoantibodies, hypergammaglobulinaemia

(Table 14.1). (Defined criteria for the diagnosis of Sjögren syndrome are now widely accepted (see Box 14.1).)

Sjögren syndrome predominantly affects middle-aged females (the female:male ratio is about 9:1), and symptoms related to dryness and soreness of the mouth and eyes are common presentations. Xerostomia may be associated with difficulty in swallowing and speaking, increased fluid intake, and disturbances of taste. In addition, it predisposes to oral candidosis, bacterial sialadenitis, and dental caries. The oral mucosa appears dry, smooth, and



Figs 14.9–14.11 Secondary Sjögren syndrome showing lingual changes associated with xerostomia (Fig. 14.9), xerophthalmia (Fig. 14.10), and rheumatoid arthritis (Fig. 14.11).

Box 14.1 Sjögren syndrome

- European diagnostic criteria relate to: (i) ocular symptoms, (ii) ocular signs, (iii) oral symptoms, (iv) salivary gland function, (v) labial salivary gland histology, (vi) Ro and La autoantibodies. Four of the six criteria need to be fulfilled.
- In addition to anti-Ro and anti-La, other autoantibodies detected include rheumatoid factor, antinuclear antibodies, antithyroid and antigastric parietal cell antibodies.
- Autoantibodies to salivary duct antigens are detectable in about 50 per cent of patients but their clinical significance is doubtful.
- Autoantibodies to neurotransmitter receptors have been recently detected and may be associated with disturbance/loss of secretory function in exocrine glands.
- The lymphocytic infiltrate comprises about 20 per cent B cells and 80 per cent T cells. The majority of the T cells are CD4 positive, T-helper cells.
- Pathogenic mechanisms in Sjögren syndrome are complex and multifaceted, involving the interplay of T cell subsets, cell-mediated cytotoxicity, cytokine production, B cell hyperactivity, autoantibody effects, and disturbances in the control of apoptotic pathways.

glazed; lingual changes may be prominent, the dorsum of the tongue often appearing red and atrophic and showing varying degrees of fissuring and lobulation (see Fig. 14.9). Keratoconjunctivitis sicca manifests as dryness of the eyes with conjunctivitis, and causes a gritty, burning sensation (see Fig. 14.10).

Salivary gland enlargement is very variable. Although approximately 30 per cent of patients may give a history of such enlargement it is only clinically apparent in about half that number. The enlargement is usually bilateral, predominantly affects the parotid glands, and is seldom painful. Lacrimal gland enlargement is uncommon.

Histopathological examination of involved major glands shows lymphocytic infiltration, initially around intralobular ducts, which eventually replaces the whole of the affected lobules. The infiltration is accompanied by acinar atrophy but, in contrast, the ductal epithelium may show proliferation. The hyperplasia of ductal epithelium eventually obliterates the duct lumen leading to islands of epithelial tissue in a sea of lymphocytes, replacing entire salivary lobules. These appearances are described by the term 'benign lymphoepithelial lesion' (Fig. 14.12) (also referred to as myoepithelial sialadenitis). The benign lymphoepithelial lesion is characteristic but not pathognomic of Sjögren syndrome. For example, it also develops in the sialadenitis associated with hepatitis C virus infection, and in HIV-associated salivary gland disease (see later).

Clinical involvement of the minor salivary glands is uncommon but they are involved at a microscopic level. The glands

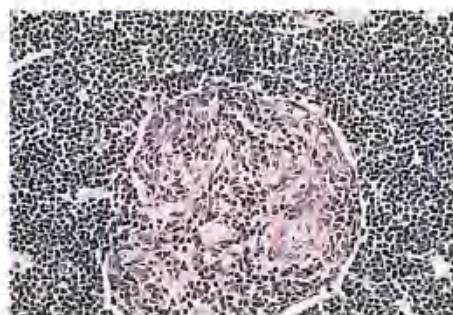

Fig. 14.12 Acinar destruction, dense lymphocytic infiltration and epimyoeptithelial islands in parotid gland in Sjögren syndrome.

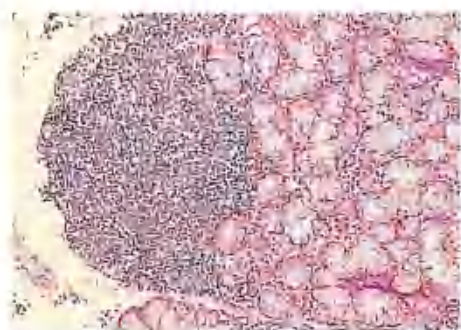


Fig. 14.13 Focal lymphocytic sialadenitis of minor glands in Sjögren syndrome.

Key point – Oral manifestations of Sjögren syndrome

- xerostomia predisposing to:
 - candidosis
 - caries
 - sialadenitis
 - oral dysfunction.

show focal collections of lymphoid cells, initially around the intralobular ducts, and the number of such foci reflects the overall severity of the disease. The semi-quantitative assessment of this focal lymphocytic sialadenitis in biopsies of labial minor salivary glands (Fig. 14.13) is an important investigation in establishing a diagnosis of Sjögren syndrome and forms one of the internationally agreed diagnostic criteria.

Other investigations useful in assessing the degree of salivary gland involvement include estimation of parotid salivary flow rates, which are usually reduced, and sialography, which shows varying degrees of sialectasis (Fig. 14.14), often producing a 'snowstorm' or 'cherry tree in blossom'-like appearance. Salivary scintiscanning using [99m Tc]pertechnetate is also of value. The radioisotope is concentrated in salivary glands and its uptake is reduced in patients with Sjögren syndrome.

A variety of circulating autoantibodies can also be detected (see Box 14.1) of which antibodies to the nuclear antigens known as Ro and La (also referred to as SS-A and SS-B, respectively) are the



Fig. 14.14 Cavitory sialectasia in Sjögren syndrome.

Key points – Sjögren syndrome – investigations

- labial gland biopsy to assess focal lymphocytic sialadenitis
- autoantibody screen, especially for anti-Ro and anti-La antibodies
- assessment of salivary gland involvement – sialography or scintiscanning
- assessment of salivary gland function – salivary flow rates, sialochemical studies
- ophthalmic opinion to assess ocular signs

most important diagnostically. Anti-Ro antibodies are found in about 75 per cent of patients with primary Sjögren syndrome and are also found in patients with secondary Sjögren syndrome. Anti-La can also be detected in 40 per cent (or more with sensitive assays) of patients with Sjögren syndrome. The detection of anti-Ro and anti-La antibodies is another important investigation in establishing a diagnosis of Sjögren syndrome.

Although the immunological and histopathological findings in Sjögren syndrome support an autoimmune pathogenesis, little is known about either the aetiological factors underlying the disturbance in immunoregulation or the mechanisms involved in the destruction of the salivary and lacrimal glands. However, genetic factors are thought to be important in increasing the susceptibility of an individual to external environmental factors, which then trigger the disease. Sjögren syndrome occurs with increased frequency in patients with particular combinations of

Key points – Sjögren syndrome – pathology

- non-organ-specific autoimmune disease – multisystem involvement
- destructive lymphocytic infiltration of exocrine glands, particularly the parotid and lacrimal glands
- hyperplasia of ductal epithelium – benign lymphoepithelial lesion
- may progress to B cell, malignant lymphoma

the HLA class II major histocompatibility genes, supporting a genetic role, and several viruses, especially Epstein–Barr virus, have been suggested as potential trigger factors. Immunological mechanisms leading to destruction of glandular tissue probably involve mainly T cells and their associated cytokines. The pathogenic significance of the range of autoantibodies that can be detected is uncertain but experimental studies suggest that some may be associated with functional disturbances in salivary secretion, exacerbating the xerostomia (see Box 14.1).

In both primary and secondary Sjögren syndrome there is a risk of B cell malignant lymphoma arising within an affected gland, estimated to be 44 times that of the general population. The level of risk varies in different series from less than 1 per cent to about 6 per cent of patients. Malignant change usually occurs late in the course of the disease and may be associated with increased swelling of the affected gland. The lymphomas share many similarities with those derived from MALT (see Chapter 8). They tend to pursue an indolent course and remain localized until late in their natural history. The development of lymphoma is associated with proliferation of atypical lymphoid cells around the epithelial islands. As the malignant population expands there is destruction of the islands, replacement of the inflammatory lymphoid infiltrate, and obliteration of interlobular septa leading to diffuse infiltration of the gland by neoplastic cells.

Sialadenosis

Sialadenosis (or sialosis) is a condition characterized by non-inflammatory, non-neoplastic, recurrent bilateral swelling of salivary glands. The parotid glands are most commonly affected. It is probably due to abnormalities of neurosecretory control and has been reported in association with diverse conditions such as hormonal disturbances, malnutrition, liver cirrhosis, chronic alcoholism, and following the administration of various drugs. The histology of sialadenosis is characterized by hypertrophy of serous acinar cells to about twice their normal size. The cytoplasm is often densely packed with secretory granules.

HIV-associated salivary gland disease

As mentioned in Chapter 11, salivary gland disease may be a feature in a small proportion of adults with HIV infection. The prevalence may be higher in infected children. HIV-associated salivary gland disease is characterized by xerostomia and/or swelling of the major glands, almost invariably the parotid. The xerostomia may be caused by a Sjögren syndrome-like disease associated with a benign lymphoepithelial lesion (myoepithelial sialadenitis), but the patients do not show the autoantibody profile commonly seen in Sjögren syndrome. Parotid swelling may be due to enlargement of intraparotid nodes as part of persistent glandular lymphadenopathy (PGL, see Chapter 11) or be due to the development of multiple lymphoepithelial cysts of varying size within the nodes, similar to those seen in non-HIV infected patients (see Chapter 6).

Salivary gland tumours

Salivary gland tumours are relatively uncommon with an annual incidence in the Western world of about 3 per 100 000 population. Tumours of the major glands are far more common than those of the minor glands which account for only about 15–20 per cent of all salivary tumours. Of the tumours in major glands about 90 per cent occur in the parotid gland and about 10 per cent in the submandibular gland, sublingual gland tumours being rare. About 55 per cent of minor salivary gland tumours arise in the palate and about 20 per cent of cases in the upper lip, with the remainder scattered throughout the mouth. Tumours of the lower lip are rare. Although the minority of salivary tumours occur in the minor glands the proportion of carcinomas in these glands is higher than in major glands. Exceptionally rare examples of salivary neoplasms arising as central intraosseous lesions of the jaws (mainly the mandible) have also been reported. They may be derived from ectopic entrapped salivary glands or from mucous metaplasia in the lining of odontogenic cysts.

Relatively little is known about the genetic alterations that occur in the development of salivary neoplasms. However, abnormalities of chromosome 8 are the commonest changes in pleomorphic adenoma and a variety of additional chromosomal abnormalities have been reported in malignant tumours.

Classification

About 40 different types of salivary gland tumours are now recognized, although some of them are very rare. The classification and nomenclature used in this chapter (Table 14.2) is based on that proposed by the WHO (1991). The tumours presented in Table 14.2 are all primary neoplasms of epithelial origin and account for the majority of salivary gland tumours. In addition to the primary tumours of epithelial origin other neoplasms, such as malignant lymphomas, connective tissue, and metastatic tumours, may occasionally involve salivary glands.

Table 14.2 Classification of salivary tumours

<i>Adenomas</i>
Pleomorphic adenoma
Warthin tumour (adenolymphoma)
Basal cell adenoma
Oncocytoma
Canalicular adenoma
Ductal papillomas
<i>Carcinomas</i>
Mucoepidermoid carcinoma
Acinic cell carcinoma
Adenoid cystic carcinoma
Carcinoma arising in pleomorphic adenoma
Polymorphous low-grade adenocarcinoma
Other carcinomas

Adenomas

Pleomorphic adenoma

The pleomorphic adenoma is by far the commonest type of salivary gland tumour and accounts for 60–65 per cent of all tumours of the parotid gland and for about 45 per cent of all tumours of the minor glands. Approximately 7 per cent of cases originate in minor glands, the palate being the site of predilection. The tumour can occur at all ages but the majority of patients are in the fifth and sixth decades of life and there is a preponderance of women (about 60 per cent of cases). The tumour is usually solitary, although recurrences may be multifocal, and presents as a slowly growing, painless, rubbery swelling that the patient may have been aware of for several years (Fig. 14.15). The overlying skin or mucosa is usually intact.

Pleomorphic adenomas show a great variety of histological appearances with complex intermingling of epithelial components and mesenchymal-like areas. The diversity and complexity of appearances account for the term pleomorphic; the term does not imply cellular pleomorphism. In the same way the term 'mixed tumours', which has been used as a synonym for pleomorphic adenoma, described the varied appearances of the lesion rather than implying a dual origin from epithelium and mesenchyme. The tumour is composed of cells of epithelial and myoepithelial origin.

The pleomorphic adenoma is a benign tumour, although a connective tissue capsule does not always envelop the lesion completely. The capsule may also show variation in thickness and density, but regardless of its completeness or not, the tumour is clearly demarcated (Fig. 14.16). Apparently isolated nodules of tumour may also be seen within or even outside the capsule giving the impression of invasive growth, but serial sections show that these are outgrowths of the main mass (Fig. 14.17) and should not be taken as an indicator of malignancy nor of malignant potential. An important aspect of the deficient encapsulation and of intra- and extracapsular nodules is that they influence the surgical management of the tumour. Simple enucleation could establish a plane of cleavage within or just below the capsule, leaving behind islands of neoplastic tissues in the tumour bed which could give rise to uni- or multifocal recurrence. For these reasons the tumour is usually excised with a margin of surrounding normal tissue.

Microscopically, there is considerable variation in the arrangement of the epithelial and stromal components between different tumours and within different areas of the same tumour. The epithelial component may be arranged in duct-like structures or as sheets, clumps, and interlacing strands (Fig. 14.18). Both epithelial-duct cells and myoepithelial-type cells are present. The epithelial-duct cells line the duct-like structures which vary in size, shape, number, and distribution. They often contain brightly eosinophilic mucin. The epithelial component consists of polygonal, spindle, or stellate-shaped cells, many of which are considered to be derived from myoepithelium. Occasionally, groups of ovoid cells with eccentric nuclei and abundant hyaline cytoplasm are

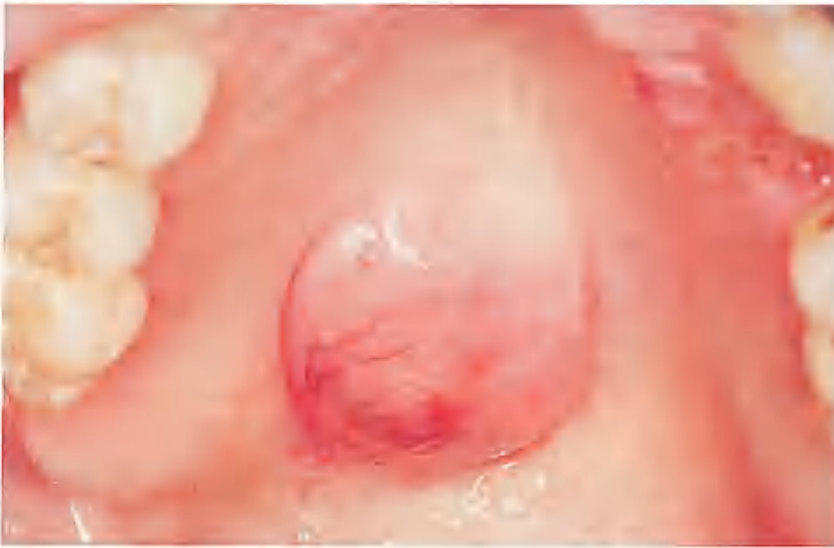

Fig. 14.15 Pleomorphic adenoma of the palate.

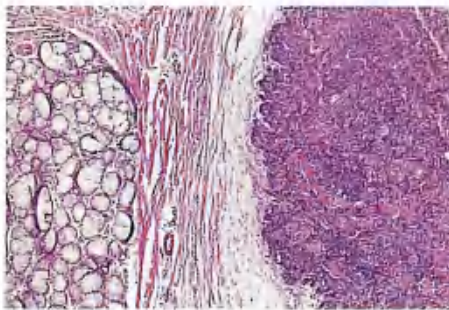


Fig. 14.16 Encapsulated pleomorphic adenoma (right) clearly demarcated from surrounding minor salivary glands.

seen. These plasmacytoid or hyaline cells are thought to represent modified myoepithelial cells. Areas of squamous metaplasia and epithelial pearl formations may also be present.

The intercellular material varies in quantity and quality but is generally abundant. It may be predominantly fibrous, but the most characteristic feature is the presence of myxoid and/or chondroid areas. These appearances are associated with the accumulation of abundant connective tissue mucins. In myxoid areas, epithelial cells are widely separated and surrounded by mucoid material. The separated epithelial cells have long stellate processes and often appear to melt into the mucinous background. In chondroid areas, isolated epithelial cells appear as rounded cells

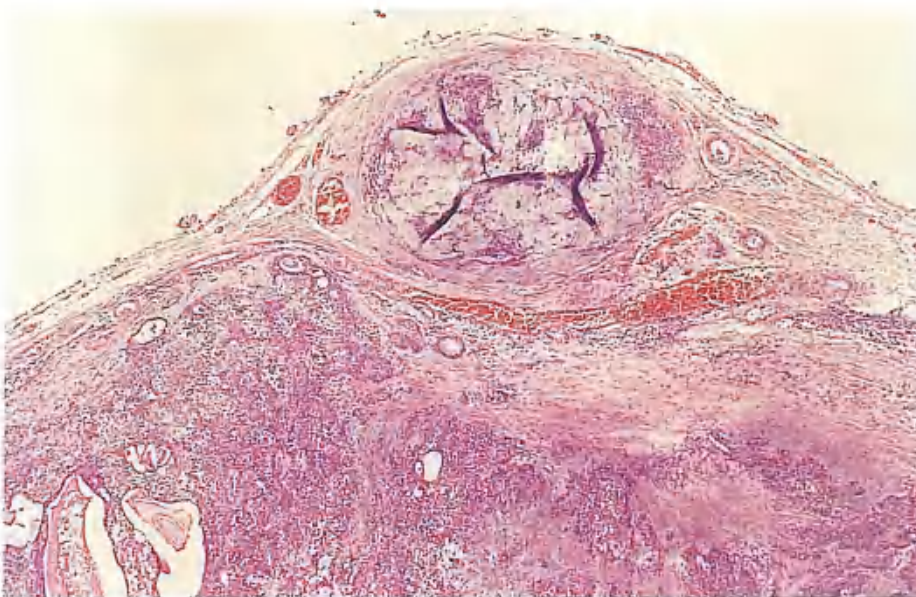


Fig. 14.17 Pleomorphic adenoma showing tumour nodule within the capsule.

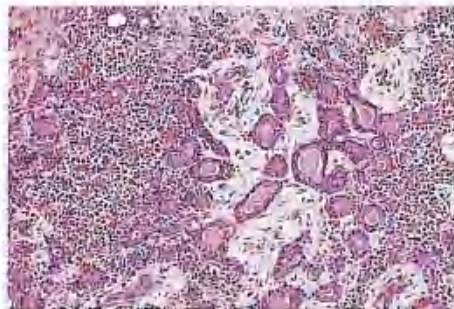


Fig. 14.18 Epithelial sheets and ductal structures in a pleomorphic adenoma.

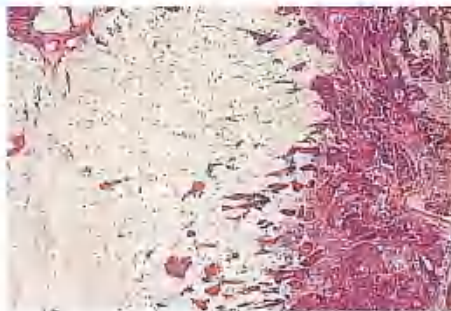


Fig. 14.19 Myxoid and chondroid areas (myxochondroid tissue) in a pleomorphic adenoma.

lying in lacunae within the mucoid material so that the tissue comes to resemble hyaline cartilage (Figs 14.19, 14.20). These components are usually referred to as myxochondroid. They are composed of glycosaminoglycans and consist mainly of chondroitin sulphates produced by the myoepithelial cells within the tumour. Tumours rich in mucoid material tend to rupture more readily during surgical removal allowing spillage and implantation of tumour into surrounding tissues, giving rise to multifocal recurrences.

Malignant transformation can occur, usually in tumours that have been present for many years (see later).

Warthin tumour (adenolymphoma, papillary cystadenoma lymphomatosum)

Warthin tumour occurs almost exclusively in the parotid gland and is a slow-growing lesion which may arise multifocally. Bilateral parotid tumours occur in 5–10 per cent of cases and most patients are over 50 years of age.

On section, the tumour characteristically has a papillary cystic structure and shows multiple, irregular cystic spaces containing mucoid material separated by papillary projections of tumour tissue (Fig. 14.21). Microscopically, the tumour consists of epithelial and lymphoid elements. The epithelial component which clothes the papillary processes is double-layered and comprises a basal layer of roughly cuboidal cells surmounted by columnar cells. The epithelial cells have markedly eosinophilic granular cytoplasm rich in abnormal mitochondria. They resem-

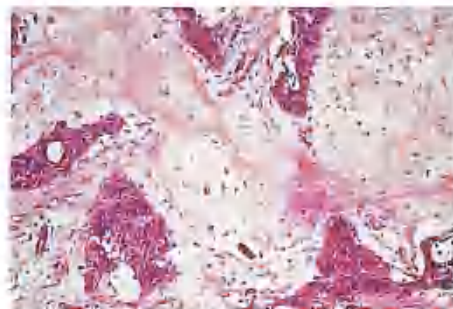


Fig. 14.20 High-power view of myxochondroid tissue in a pleomorphic adenoma.

Key points – Pleomorphic adenoma

- commonest of the salivary tumours
- architectural diversity of epithelial and stromal components
- ductal and myoepithelial cells forming ductal structures, sheets, and islands of cells
- myxochondroid stroma, connective tissue mucins secreted by myoepithelial cells
- circumscribed tumour but encapsulation variable

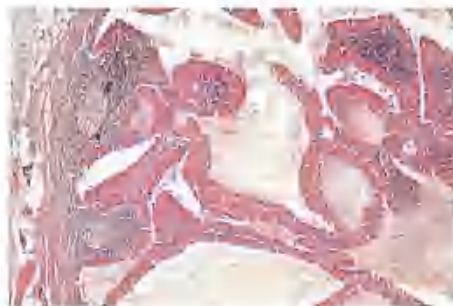


Fig. 14.21 Warthin tumour showing papillary-cystic pattern.

ble oncocytes (see Oncocytoma). The stroma contains a variable amount of lymphoid tissue which often includes numerous germinal centres (Fig. 14.22).

The histogenesis of the tumour is uncertain, but it most likely arises from residues of salivary duct epithelium entrapped within lymph nodes during development.

Basal cell adenoma

This tumour accounts for about 1–2 per cent of all salivary tumours, of which about 70 per cent occur in the parotid gland and 20 per cent in the upper lip. It consists of cytologically uniform basaloid cells arranged in a variety of patterns (Fig. 14.23). The tumour is well encapsulated and the peak incidence is in the 7th decade of life.

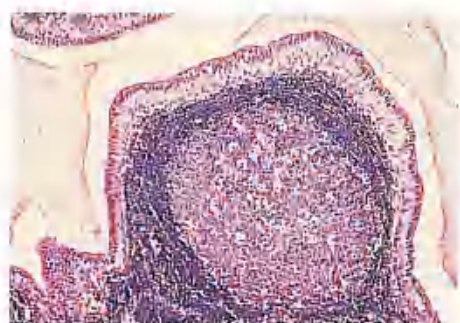

Fig. 14.22 Lymphoid tissue with germinal centres in Warthin tumour.

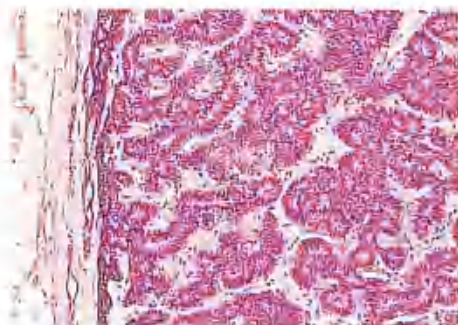


Fig. 14.23 Tubular/trabecular basal cell adenoma.

Oncocytoma

The oncocytoma is a rare tumour usually arising in the parotid gland and occurring in patients over 60 years of age. It is usually surrounded by a thin capsule and consists of oncocytes, the term used to describe large ductal and acinar cells with granular eosinophilic cytoplasm rich in mitochondria, many of which are abnormal. Hyperplasia of oncocytes also occurs and may be difficult to distinguish from oncocytoma.

Canalicular adenoma

This tumour occurs mainly in patients over 50 years of age and almost all cases are located in the upper lip. It consists of anastomosing strands of cytologically bland basaloid epithelial cells and may be partly or grossly cystic due to degeneration of its loose vascular stroma. In some cases multiple microscopic foci of adenomatous change may be seen in surrounding minor salivary glands. They do not appear to be of clinical significance and must not be interpreted as invasive growth.

Ductal papillomas

Ductal papillomas are rare tumours most of which have a papillary structure projecting into the ductal system. Several subtypes are recognized.

Carcinomas

Malignant tumours of the salivary glands are relatively uncommon, accounting for about 1 per cent or less of all malignancies and about

5 per cent of malignant tumours in the head and neck region. Although carcinomas of salivary glands arise most frequently in the major glands, especially the parotid, the proportion of malignant to benign tumours is higher in minor glands. There are also differences in the incidence of the various types of carcinomas between major and minor glands. For example, the adenoid cystic carcinoma accounts for between 10 and 15 per cent of tumours of the minor salivary glands but only for about 3 per cent of parotid neoplasms.

Mucoepidermoid carcinoma

Mucoepidermoid carcinoma is the commonest malignant salivary gland tumour, accounting for about 10% of all salivary tumours. The majority occur in the parotid gland; in the minor glands the palate is the most frequent site.

Mucoepidermoid carcinoma may occur at any age but the highest incidence is during the fourth and fifth decades of life. There is a slight female predominance. The tumour often presents clinically in a similar manner to a pleomorphic adenoma, but grossly cystic tumours may be fluctuant and the more aggressive ones may be accompanied by pain and ulceration.

Microscopically, the tumours are characterized by the presence of squamous cells, mucus-secreting cells, and cells of intermediate types which have the potential for further differentiation towards mucous or squamous cells (Fig. 14.24). The relative proportions of individual cell types and their arrangements vary from lesion to lesion, but it is customary to distinguish between well-

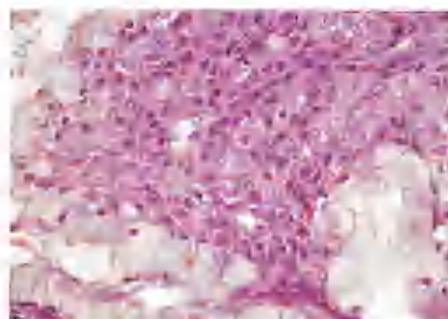


Fig. 14.24 Mucus-secreting (large pale cells), epidermoid, and intermediate cells in mucoepidermoid carcinoma.

Key points – Mucoepidermoid carcinoma

- commonest salivary malignancy
- comprises mucous, epidermoid, and intermediate cells in varying proportions
- well-differentiated tumour: mucous cells predominate; mucin-filled cysts common; usually good prognosis
- poorly differentiated tumour: epidermoid and intermediate cells predominate; solid rather than cystic pattern; usually poor prognosis

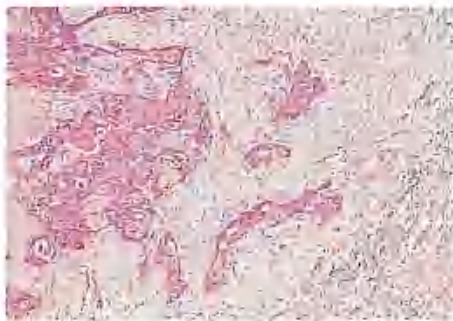


Fig. 14.25 Mucoepidermoid carcinoma showing infiltrative growth.

differentiated (low-grade) and poorly differentiated (high-grade) tumours, although they form a continuous spectrum. They are non-encapsulated and invasive. Some (mainly low-grade types) may appear to advance on a broad 'pushing' front, whilst others (mainly high-grade types) are ill-defined, highly infiltrative growths (Fig. 14.25).

In well-differentiated tumours, mucus-secreting and epidermoid cells predominate and there is no cellular pleomorphism. Such tumours are often cystic, either wholly or in part, the cysts being lined mainly by mucus-secreting cells (Fig. 14.26). The epidermoid cells are usually present in the form of clumps or strands which may show keratinization but may also partially line the cysts. Discharge of mucus into the cysts can lead to their distension, coalescence, or rupture, in which case the release of mucus into the stroma is accompanied by reactive inflammation.

In poorly differentiated tumours, epidermoid and intermediate cells predominate and there is nuclear and cellular pleomorphism, and nuclear hyperchromatism. Cystic spaces are not prominent and may be absent. In some cases differentiation from squamous cell carcinoma is difficult.

Although well-differentiated tumours rarely metastasize, the behaviour of a mucoepidermoid carcinoma cannot be predicted with any degree of certainty from its histology. The overall 5-year survival rate is about 70 per cent. However, well-differentiated, low-grade tumours have a local recurrence rate of less than 10 per cent and a 5-year survival of about 95 per cent. In contrast, poorly differentiated (high-grade) tumours have been reported to have local recurrence rates of 80 per cent and 5-year survival rates of only 30–40 per cent.

Acinic cell carcinoma

The acinic cell carcinoma is an uncommon neoplasm, the great majority arising in the parotid gland. It accounts for about 2–3 per cent of all parotid tumours and up to 20 per cent of malignant parotid neoplasms.

It presents a spectrum of histological appearances, but typically consists of sheets or acinar groupings of large, polyhedral cells which have basophilic, granular cytoplasm, similar in appearance to the serous acinar cells of salivary glands (Fig. 14.27). Other tumours may show a papillary cystic pattern and contain other cell types, including duct cells and clear cells. Less well-differentiated lesions may show obvious cytological features of malignancy.

As with the mucoepidermoid carcinoma it is difficult to predict the behaviour of acinic cell carcinomas on the basis of their histological features. However, acinic cell carcinoma is regarded as a low-grade malignancy. Five-year survival rates of 80–100 per cent have been reported for well-differentiated tumours and 65 per cent (or better) for poorly differentiated types.

Adenoid cystic carcinoma

Adenoid cystic carcinomas usually arise in middle-aged or elderly patients. They account for up to 30 per cent of minor salivary gland tumours but only for about 6 per cent of parotid tumours. Clinically, they may present as slowly enlarging tumours indis-

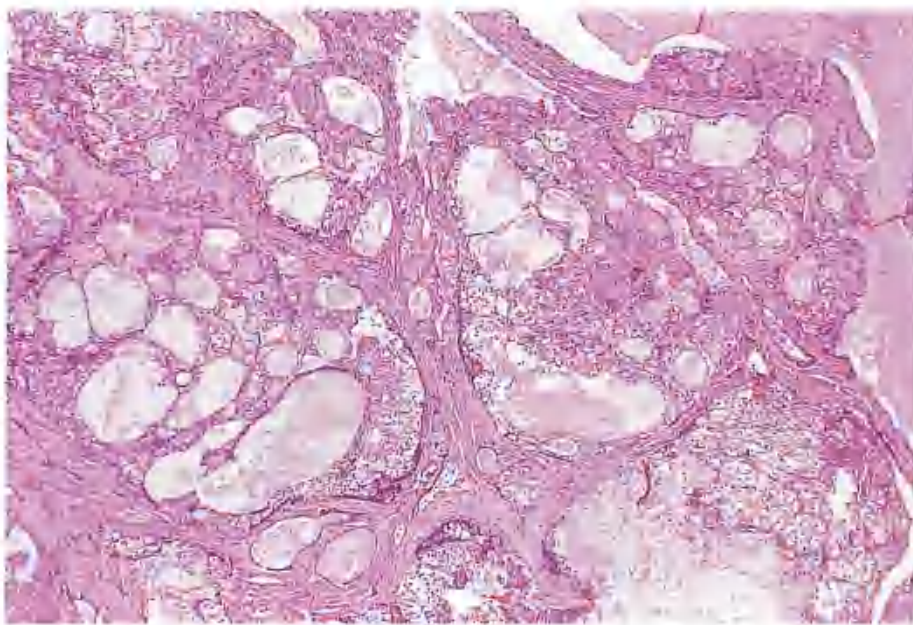


Fig. 14.26 Well-differentiated mucoepidermoid carcinoma showing multiple mucin-filled cysts.


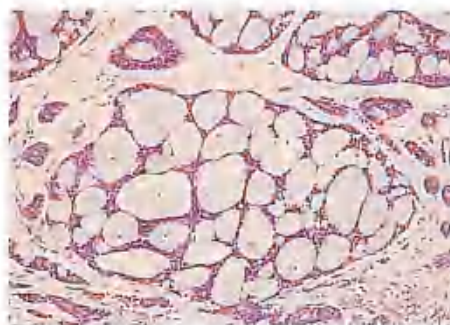
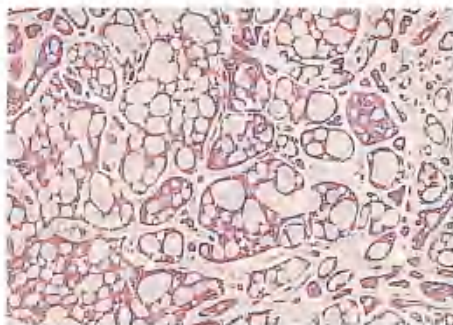


Fig. 14.27 Acinic cell carcinoma.

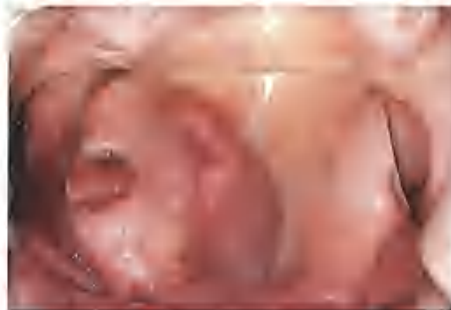

Fig. 14.28 Ulcerated adenoid cystic carcinoma of the palate (mirror view).



Figs 14.29, 14.30 Adenoid cystic carcinoma showing characteristic cribriform pattern and uniform small basaloid cells.

ringuishable from pleomorphic adenoma, but pain and ulceration of the overlying skin or mucosa are much more common than in pleomorphic adenoma (Fig. 14.28). Parotid tumours may also present with facial palsy. The neurological manifestations are a reflection of the predilection of the tumour to infiltrate and spread along nerve pathways.

The tumour has a wide spectrum of histological appearances, but most commonly the neoplastic epithelium is arranged as ovoid and irregularly shaped islands or as anastomosing strands lying in a scanty connective tissue stroma. The characteristic feature of the tumour is the presence of numerous microscopic cyst-like spaces within the epithelial islands, producing a cribriform, lace-like or 'Swiss-cheese' pattern (Figs 14.29, 14.30). The spaces are formed by partial enclavement of areas of stroma or

Key points – Adenoid cystic carcinoma

- proportionally more common in minor glands
- cribriform pattern is commonest type
- perineural invasion
- poor long-term prognosis
- metastatic spread tends to be via the bloodstream to the lungs

of mucoid materials produced by the tumour epithelium which are deposited adjacent to the stroma. They contain acellular basophilic or occasionally hyaline substances rich in glycosaminoglycans and basement membrane-like material.

In tumours showing the characteristic cribriform pattern the epithelial component consists predominantly of small, rather uniform polygonal cells with basophilic cytoplasm. Mitoses are rarely seen. Less frequently the tumour shows a tubular or solid pattern.

Infiltration of adjacent tissues and spread along and around nerves are often prominent features and may be extensive (Fig. 14.31). In addition, in the maxilla the tumour may infiltrate extensively along marrow spaces with little or no evidence of bone destruction, and these factors must be borne in mind in the surgical treatment of adenoid cystic carcinoma. Radiotherapy may be

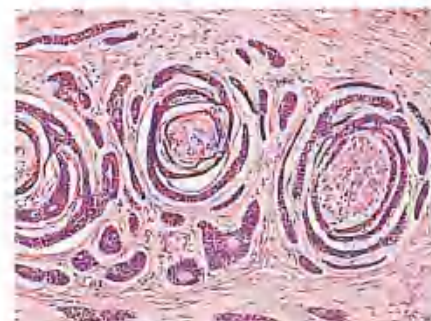


Fig. 14.31 Adenoid cystic carcinoma showing prominent perineural infiltration.

used to obtain palliation in inoperable cases, but does not result in a permanent cure. The disease runs a prolonged clinical course and metastases, usually via the bloodstream to the lungs, are a late finding. However, the long-term prognosis is poor and patients must be followed for much longer than 5 years before assuming that a permanent cure has been obtained. For example, survival rates for adenoid cystic carcinoma of the parotid are about 75 per cent at 5 years, about 40 per cent at 10 years, but less than 15 per cent at 20 years. Cribriform and tubular types have a better prognosis than the solid type. The prognostic outcome for patients with primary tumours of the minor salivary glands appears less favourable.

Carcinoma arising in pleomorphic adenoma

Carcinoma arising in pleomorphic adenoma is relatively uncommon and accounts for about 3 per cent of salivary tumours, although the true incidence is difficult to establish. Almost all arise in adenomas of the parotid or submandibular gland that have usually been present for many years. The diagnosis requires evidence of a pre-existing pleomorphic adenoma, but in many cases the adenoma has been overrun by the malignant tumour and all that remains is hyaline scar tissue. The malignant component is usually an adenocarcinoma or undifferentiated carcinoma but may assume the features of any of the types of salivary carcinomas. In some tumours more than one morphological type of carcinoma may be present. Whilst the malignant tumour is still confined by the capsule of the pre-existing adenoma (the *in situ* or 'non-invasive' stage) the tumour has an excellent prognosis, the same as for a pleomorphic adenoma. However, when there is infiltration of surrounding tissues the tumour carries a poor prognosis. Five-year survival rates of about 55 per cent falling to about 30 per cent at 10 years have been reported.

Polymorphous low-grade adenocarcinoma

This carcinoma occurs almost exclusively in minor salivary glands. Most have presented in the palate. As its name implies it is a tumour that shows a variety of growth patterns within the same lesion, including solid, tubular, and cribriform areas that may mimic adenoid cystic carcinoma. The tumour cells appear cytologically bland; mitoses are rare and nuclear atypia and hyperchromatism are lacking. The tumour has an infiltrative pattern of growth, and, like the adenoid cystic carcinoma, can show perineural invasion. However, generally the tumour has a good prognosis (hence the term 'low grade'), although it has an unpredictable potential to metastasize in about 15 per cent of cases.

Other carcinomas

A variety of other histological types of salivary gland carcinomas are described. Examples are given in Box 14.2.

Age changes in salivary glands

Age changes can be detected in both major and minor salivary glands.

Box 14.2 Other salivary carcinomas

- *Epithelial-myoepithelial carcinoma*: essentially confined to major glands, mainly parotid, low-grade adenocarcinoma, composed of duct-lining cells and myoepithelial cells
- *Basal cell adenocarcinoma*: mainly parotid gland, low-grade adenocarcinoma, histologically resembles basal cell adenoma but invasive growth
- *Adenocarcinoma (not otherwise specified)*: mainly parotid gland, a diagnosis by exclusion, an adenocarcinoma that does not fit into any of the other recognized types, may be well, moderately, or poorly differentiated.


Reduction in the weights of submandibular and parotid glands have been reported with increasing age associated in the submandibular gland with an age-dependent reduction in flow rates. In contrast, several studies have demonstrated that there is no significant reduction in parotid flow rates in the elderly. In both glands the reduction in weight is related to atrophy of secretory tissue and replacement by fibrofatty tissue. The adiposity of the glands tends to increase linearly with age, and in both there is a reduction in the volume of acinar tissue of about 30–35 per cent from approximately 20 years to 75 years of age. Similar changes, amounting to about 45 per cent loss of acinar tissue, have been reported in minor glands in the lower lip.

In both major and minor salivary glands oncocyctic change is a prominent feature in ductal epithelium with ageing.

Further reading

- Cannell, H., Kerawala, C., and Farthing, P. (1997). Stomatitis glandularis: two confirmed cases of a rare condition, *British Dental Journal*, 182, 222–5.
- Dardick, I., Byard, R. W., and Carnegie, J. A. (1990). A review of the proliferative capacity of major salivary glands and the relationship to current concepts of neoplasia in salivary glands. *Oral Surgery, Oral Medicine, Oral Pathology*, 69, 53–67.
- Eveson, J. W. and Cawson, R. A. (1985). Salivary gland tumours: a review of 2410 cases with particular reference to histological types, size, age and sex distribution. *Journal of Pathology*, 146, 51–8.
- Eveson, J. W. and Cawson, R. A. (1985). Tumours of the minor (oropharyngeal) salivary glands: a demographic study of 336 cases. *Journal of Oral Pathology*, 14, 500–9.
- Fox, R. I. (1996). Sjögren's syndrome: immunobiology of exocrine gland dysfunction. *Advances in Dental Research*, 10, 35–40.
- Jonsson, R., Moen, K., Vestheim, D., and Szodoray, P. (2002). Current issues in Sjögren's syndrome. *Oral Diseases*, 8, 130–40.
- Jordan, R. C. K. and Speight, P. M. (1996). Lymphoma in Sjögren's syndrome. *Oral Surgery, Oral Medicine, Oral Pathology, Oral Radiology and Endodontics*, 81, 308–20.

- Keogh, P. V., O'Regan, E. O., Toner, M., and Flint, S. (2004). Necrotizing sialometoplasia: an unusual bilateral presentation associated with antecedent anaesthesia and lack of response to intralesional steroids. Case report and review of the literature. *British Dental Journal*, 196, 79–81.
- Mandel, L. and Reich, R. (1992). HIV parotid gland lymphoepithelial cysts. *Oral Surgery, Oral Medicine, Oral Pathology*, 74, 273–8.
- Rhodus, N. L. (1999). Sjögren's syndrome. *Quintessence International*, 30, 689–99.
- Schiødt, M. (1992). HIV-associated salivary gland disease: a review. *Oral Surgery, Oral Medicine, Oral Pathology*, 73, 164–7.
- Seifert, G. (1992). Histopathology of malignant salivary gland tumours. *Oral Oncology, European Journal of Cancer*, 28B, 49–56.
- Seifert, G. and Sobin, L. H. (1991). *Histological typing of salivary gland tumours* (2nd edn). World Health Organization International Classification of Tumours. Springer-Verlag. Berlin.
- Speight, P. M. and Barrett, A. W. (2002). Salivary gland tumours. *Oral Diseases*, 8, 229–40.
- Vincent, S. D., Hammond, H. L., and Finkelstein, M. W. (1994). Clinical and therapeutic features of polymorphous low-grade adenocarcinoma. *Oral Surgery, Oral Medicine, Oral Pathology*, 77, 41–7.
- Waldron, C. A., El-Mofty, S. K., and Gnepp, D. R. (1988). Tumours of intraoral minor salivary glands: a demographic and histological study of 426 cases. *Oral Surgery, Oral Medicine, Oral Pathology*, 66, 323–33.



Odontomes and odontogenic tumours

CLASSIFICATION

ODONTOMES

- Invaginated odontome
- Evaginated odontome
- Enamel pearl (enameloma)
- Complex odontome
- Compound odontome


ODONTOGENIC TUMOURS

- Ameloblastoma
- Unicystic ameloblastoma
- Peripheral (extraosseous) ameloblastoma
- Squamous odontogenic tumour
- Calcifying epithelial odontogenic tumour
- Ameloblastic fibroma, ameloblastic fibrodentinoma, and ameloblastic fibro-odontoma
- Odontoameloblastoma
- Adenomatoid odontogenic tumour
- Calcifying cystic odontogenic tumours
- Calcifying odontogenic cyst and dentinogenic ghost cell tumour
- Odontogenic fibroma and odontogenic myxoma/myxofibroma
- Cementoblastoma (true cementoma)
- Malignant odontogenic tumours

TUMOURS OF DEBATABLE ORIGIN

- Melanotic neuroectodermal tumour of infancy
- Congenital gingival granular cell tumour (congenital epulis)

FURTHER READING



Odontomes and odontogenic tumours

Classification

Odontomes and odontogenic tumours form a complex group of lesions derived from the dental formative tissues. The term odontome is used to designate a non-neoplastic, developmental anomaly or malformation that contains enamel and dentine. However, there is no consensus as to which anomalies and malformations should be included under this heading, with the exception of the complex and compound odontomes. These are developmental tumour-like masses and can be considered as dental hamartomas. In addition, the term has also been used rather loosely to describe a variety of other developmental dental abnormalities which are discussed in this chapter. They are listed, in Table 15.1. Double teeth (see Chapter 1) may also be referred to as geminated odontomes and are included in Table 15.2 for completeness.

The odontogenic tumours are uncommon and some are exceedingly rare. The nomenclature and classification used in this chapter (Table 15.2) are based on those recommended by the World Health Organization (1992) and its Consensus Conference, 2003. The latter redesignated the odontogenic keratocyst as the keratinizing cystic odontogenic tumour and this is included, for completeness in Table 15.2. However, in this book the lesion is still referred to as the odontogenic keratocyst and is discussed with the other odontogenic cysts in Chapter 6. The calcifying odontogenic cyst has been redesignated as the calcifying cystic odontogenic tumour.

Odontomes

Invaginated odontome

Invaginated odontomes (*dens invaginatus*) arise as a result of invagination of a portion of the enamel organ into the dental papilla at an early stage in odontogenesis, before the formation of calcified dental

Table 15.1 Odontomes

Invaginated odontome (<i>dens invaginatus</i> , <i>dens-in-dente</i>)
Evaginated odontome
Enamel pearl (<i>enameloma</i>)
Double tooth/geminated odontome
Complex odontome
Compound odontome

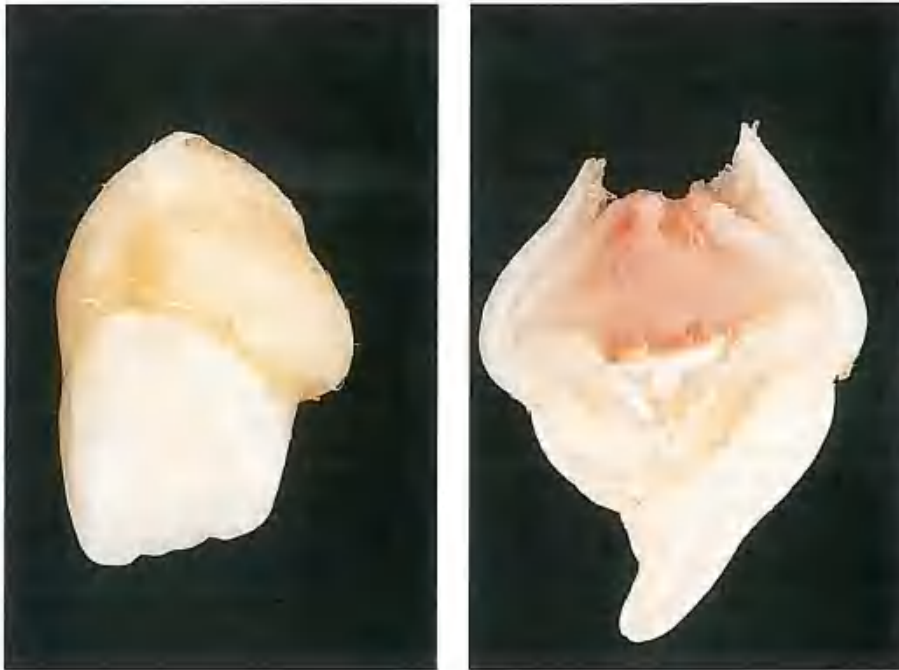tissues. The majority of invaginations originate in the coronal part of the tooth but radicular invaginations also occur (see later).

Clinical and radiological features

Although coronal invaginations may involve any type of tooth, including supernumerary teeth, the permanent maxillary lateral incisors are the teeth most frequently affected. The anomaly is often bilateral. The condition is uncommon in mandibular teeth

Table 15.2 Classification of odontogenic tumours

<i>Benign odontogenic tumours</i>
Epithelial lesions
(1) Without odontogenic mesenchyme
Ameloblastoma
Squamous odontogenic tumour
Calcifying epithelial odontogenic tumour
Adenomatoid odontogenic tumour
Keratinising cystic odontogenic tumour
(2) With odontogenic mesenchyme
Ameloblastic fibroma and fibrodentinoma
Ameloblastic fibro-odontoma
Odontoameloblastoma
Calcifying odontogenic cyst and dentinogenic ghost cell tumour
Calcifying cystic odontogenic tumour (calcifying odontogenic cyst) and dentinogenic ghost cell tumour
Complex odontome
Compound odontome
Mesenchymal lesions
Odontogenic fibroma
Myxoma
Cementoblastoma
<i>Malignant odontogenic tumours</i>
Odontogenic carcinomas
Malignant ameloblastoma/ameloblastic carcinoma
Primary intraosseous carcinoma
Clear cell odontogenic carcinoma
Malignant variants of other epithelial tumours
Malignant change in odontogenic cysts
Odontogenic sarcomas
Ameloblastic fibrosarcoma
Ameloblastic fibro-odontosarcoma
<i>Tumours of debatable origin</i>
Melanotic neuroectodermal tumour of infancy
Congenital gingival granular cell tumour (congenital epulis)



Figs 15.1 and 15.2 Dilated invaginated odontome involving a permanent maxillary incisor; macroscopic and bisected appearances.

and cases reported involving the primary dentition are exceedingly rare. The prevalence of dens invaginatus varies in different series from less than 1 to about 10 per cent, based on studies of extracted maxillary permanent lateral incisors, or on radiographic surveys.

The degree of invagination varies but three main types are identified: type 1, where the invagination is confined to the crown of the involved tooth; type 2, where the invagination extends into the root; and type 3, where the invagination extends through the root apex. In the permanent maxillary lateral incisor the invagination arises from the cingulum pit or, in the case of peg-shaped lateral incisors, from the incisal tip. Where the invagination is of a minor degree the tooth may be of normal appearance, but with the more extensive forms the crown, and particularly the root, may be considerably dilated. The terms 'dilated' or 'gestalt odontome' are sometimes applied to describe such anomalies (Figs 15.1, 15.2). Some invaginations may be discovered on clinical examination, particularly if there is gross disturbance in tooth morphology, or on routine radiographs, but many are undetected until the patient presents with symptoms of pulpitis and its sequelae which are common complications of invagination.

Radiographs reveal an invagination lined by enamel which is continuous with the normal enamel covering of the tooth (Fig. 15.3). The appearances may resemble a tooth within a tooth, hence the term 'dens-in-dente'.

Histopathology and pathogenesis

Ground sections show an invagination of enamel and dentine arising from the crown and sometimes extending into the root (Fig. 15.4). The invagination cavity opens on the surface of the tooth, and the enamel lining the invagination is continuous with

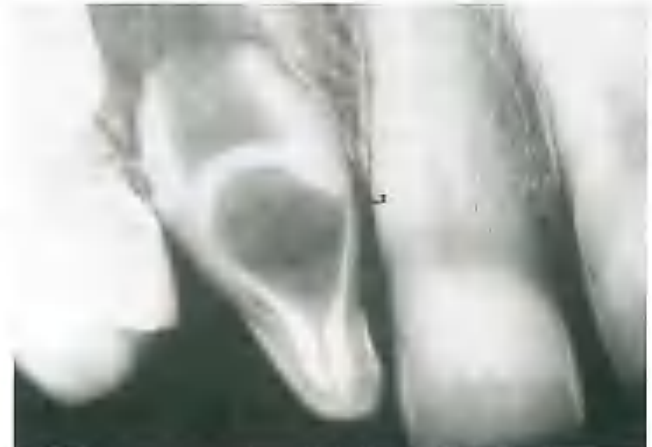

Fig. 15.3 Radiographic appearances of a dilated invaginated odontome associated with a peg-shaped lateral incisor.

that covering the external surfaces of the tooth. The enamel lining the invagination is often defective and may be poorly mineralized or absent in areas, particularly near the bottom of the cavity. The dentine of the invagination is also commonly defective and may show abnormalities in calcification and fine channels or cracks running between the invagination and the pulp. Because the invagination encroaches upon the pulp cavity the latter may be reduced to slit-like spaces around the sides of the invagination. Whilst the tooth is unerupted the invagination cavity contains connective tissue continuous with the dental follicle, within which islands of bone are occasionally formed. On eruption this

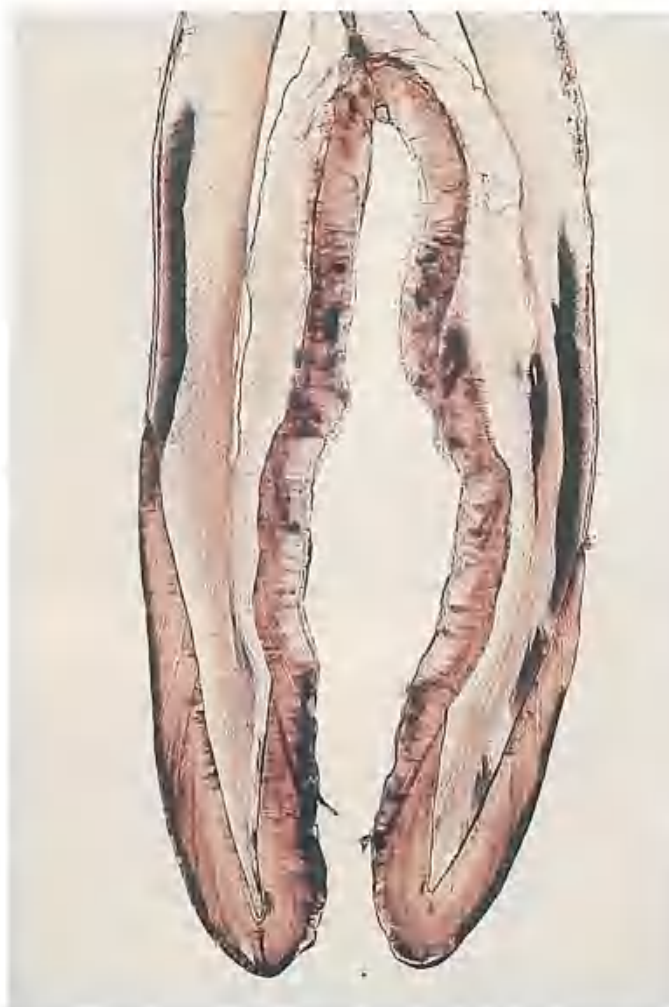

Fig. 15.4 Ground section of an invaginated odontome associated with a peg-shaped lateral incisor.

connective tissue undergoes necrosis. Once the invagination is exposed to the oral environment food debris and bacteria come to occupy the cavity and the various defects in the lining of the invagination may permit ready access of bacteria to the pulp. This accounts for the frequency with which the anomaly presents with pulpitis and its sequelae even though the tooth may appear clinically sound.

The pathogenesis of the invagination is unknown. The milder forms probably represent exaggeration of the normal process involved in the formation of the cingulum pit, and it may be that the more severe infoldings represent a more pronounced disturbance of the same process. Although the causes of such a disturbance have yet to be determined, invagination could be the result either of active proliferation of an area of the enamel organ with infolding of the proliferating cells into the dental papilla, or of displacement of part of the enamel organ into the papilla as a result of abnormal pressure from the surrounding tissue.

Key points – Invaginated odontome

- mainly permanent maxillary lateral incisors
- enamel-lined invagination on radiograph
- extent of invagination varies
- enamel and dentine in the base of the invagination often defective in quantity and/or quality
- pulpitis and sequelae common
- abnormalities of crown/root morphology

Radicular invaginations

Radicular invaginations are uncommon and are of two distinct types. The first type is represented as an axial infolding of the root, which is lined by cementum. It is an exaggeration of the grooving normally present on the roots of some teeth, notably mandibular first premolars, and indicates an incomplete attempt at root bifurcation.

The second type is rare and presents as an enamel-lined, sacular invagination originating from the surface of the root. Presumably this type arises as a result of invagination of the epithelial root sheath of Hertwig into the dental papilla followed by differentiation of ameloblasts and subsequent amelogenesis (cf. the formation of the enamel pearl).

Evaginated odontome

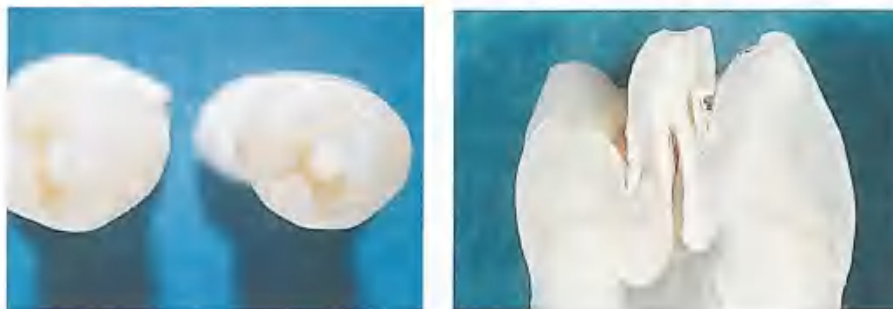Evaginated odontomes (*dens evaginatus*) are uncommon and are characterized by extra cusp-like tubercles which usually arise from the occlusal surfaces of premolars or the palatal surfaces of the maxillary central or lateral incisors. The anomaly presents as an enamel-covered, teat-like tubercle projecting from the occlusal surface of an otherwise normal premolar (Figs 15.5, 15.6). The evagination is easily fractured resulting in exposure of the pulp and its sequelae.

Evaginated odontomes involving the occlusal surfaces of premolars occur predominantly in people of Mongoloid stock. Those involving the anterior teeth, predominantly the permanent maxillary lateral incisors, originate from the palatal cingulum. They are usually referred to as talon cusps because of their resemblance to an eagle's talon.

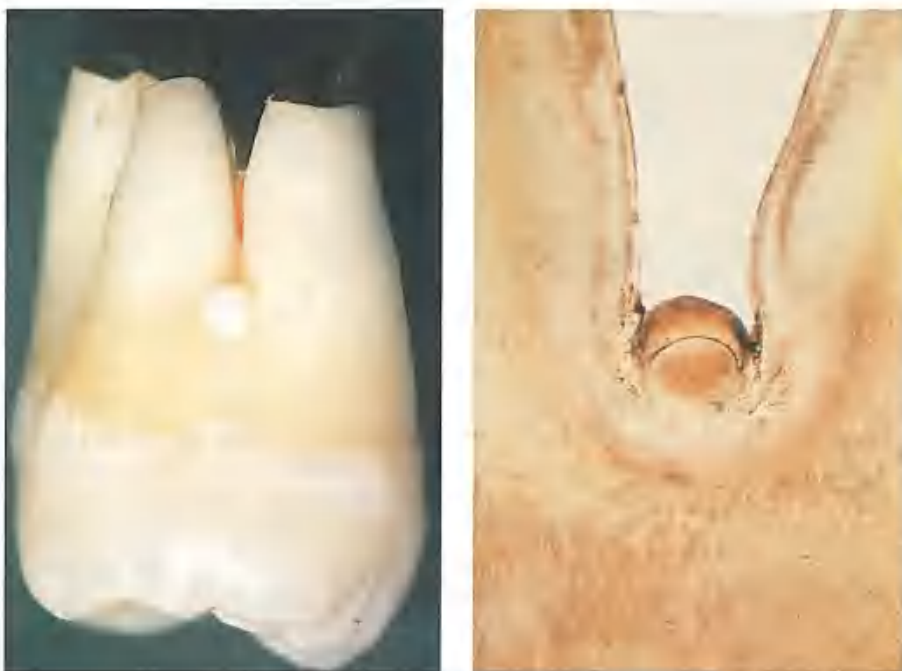Enamel pearl (enameloma)

The enamel pearl presents as a small droplet of enamel on the root of a tooth and is found most frequently near or in the furcation of the roots of maxillary permanent molar teeth. Most arise close to the amelocemental junction but they are occasionally found near the root apex.

The lesion is symptomless and is discovered as an incidental finding on radiographs or when the tooth is extracted. Microscopically, some consist entirely of enamel but others contain a core of dentine and even a small amount of pulp tissue (Figs 15.7,



Figs 15.5 and 15.6 Evaginated odontomes associated with premolar teeth; macroscopic and bisected appearances.



Figs 15.7 and 15.8 Enamel pearl; macroscopic appearance and ground section, respectively.

15.8). The anomaly is thought to arise as a result of a growth disturbance of Hertwig's sheath resulting in budding of the sheath followed by differentiation of ameloblasts and amelogenesis.

Complex odontome

The complex odontome is a developmental tumour-like mass consisting of disorderly arranged dental tissues. It has a limited growth potential and can be considered as a dental hamartoma. Although previously the complex and compound odontomes (see later) were considered to form a continuous spectrum, recent evidence suggests that they are distinct entities. The complex and compound odontomes are, by far, the commonest of the lesions classified as odontogenic tumours.

The complex odontome occurs predominantly in the second and third decades of life and the majority arise in the molar region of the mandible. They are often associated with the crowns of unerupted teeth (Fig. 15.9) and occasionally may take the place of a tooth. For these reasons they may be discovered, when small, as incidental findings when investigating a patient with a tooth missing from the dental arch. As the lesion enlarges it usually presents as a painless, slow-growing expansion of the jaw, but may

become infected and present with pain, particularly if it communicates with the mouth. Multiple odontomes are rare. In some cases complex odontomes develop in association with calcifying odontogenic cysts (see later).

Radiographically, a fully formed complex odontome appears as a radiopaque lesion, sometimes with a radiating structure (Fig. 15.9), but in the developing stages it shows as a well-defined radiolucent lesion in which there is progressive deposition of radiopaque material as calcification of the dental tissues proceeds. The mature lesion is surrounded by a narrow radiolucent zone analogous to the pericoronal space around unerupted teeth.

Histologically, the fully developed complex odontome consists of a mass of disorderly arranged, but well-formed enamel, dentine, and cementum (Fig. 15.10). Dentine forms the bulk of the lesion (Fig. 15.11) and, on surfaces not covered by enamel or cementum, is in contact with tissue resembling the normal pulp. In decalcified sections (Fig. 15.11) the areas occupied by enamel appear as empty spaces except where enamel maturation is incomplete when the spaces contain remnants of enamel matrix with a fibrillar appearance. The developing complex odontome will contain varying amounts of soft tissue which include odonto-

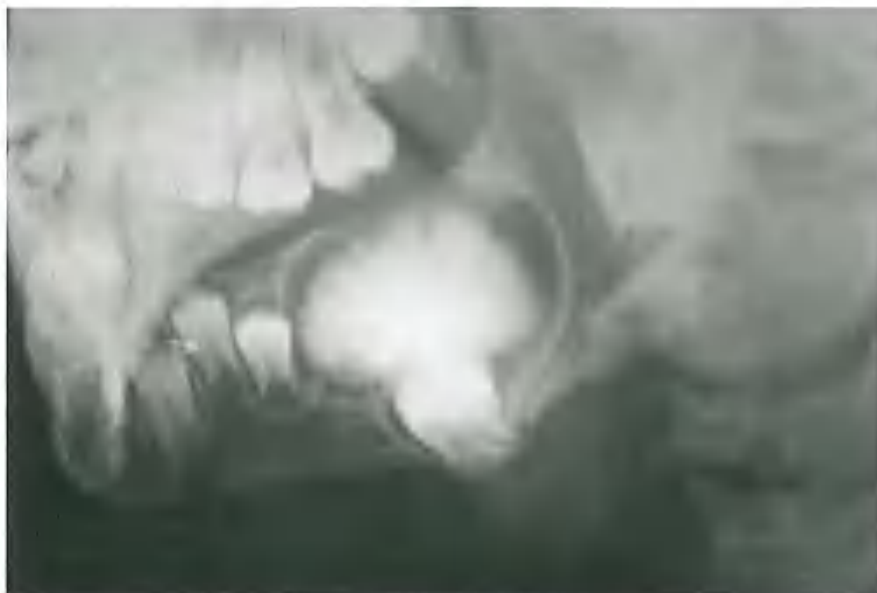

Fig. 15.9 Complex odontome overlying a first permanent molar showing radiolucent zone analogous to the pericoronal space and radiopaque mass with radiating structure.

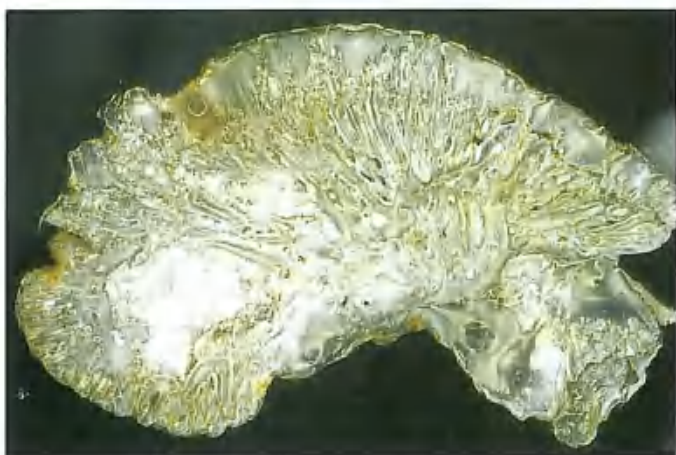


Fig. 15.10 Ground section of complex odontome showing a radiating structure in areas.

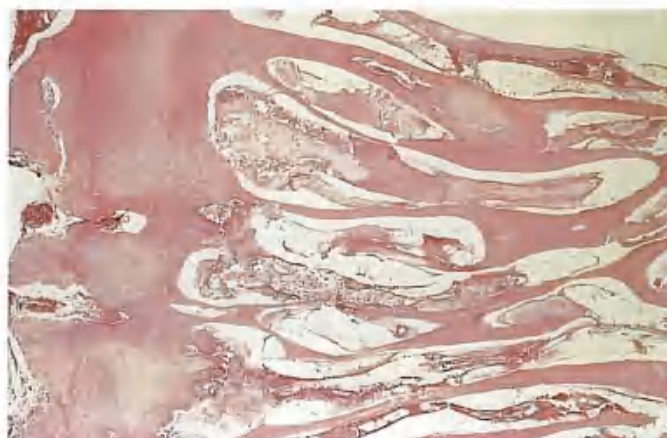


Fig. 15.11 Decalcified section of the complex odontome shown in Fig. 15.10. The areas occupied by enamel appear as empty spaces; some contain residual enamel matrix.

Key points – Complex odontome

- developmental lesion resulting in disorganized mass of dental tissues
- 2nd/3rd decade; predominantly molar region mandible
- may overlie/replace a tooth
- radiolucent/radiopaque depending on maturity
- dentine forms bulk of lesion

genic epithelium and mesenchyme, and structures resembling enamel organs (Fig. 15.12). Developing lesions show histological features of all stages in odontogenesis and may be difficult to

differentiate from ameloblastic fibroma and ameloblastic fibro-odontoma (see later).

Compound odontome

The compound odontome is a developmental tumour-like mass which, unlike the complex odontome, consists of numerous small, discrete, tooth-like structures called denticles. They do not resemble the teeth of the normal dentition but each one consists of normal enamel, dentine, cementum, and pulp arranged as in a normal tooth (Fig. 15.13). The compound odontome, therefore, shows a much higher degree of morphodifferentiation than the complex odontome.

The compound odontome occurs predominantly in the first two decades of life and the majority arise in the anterior maxilla. In

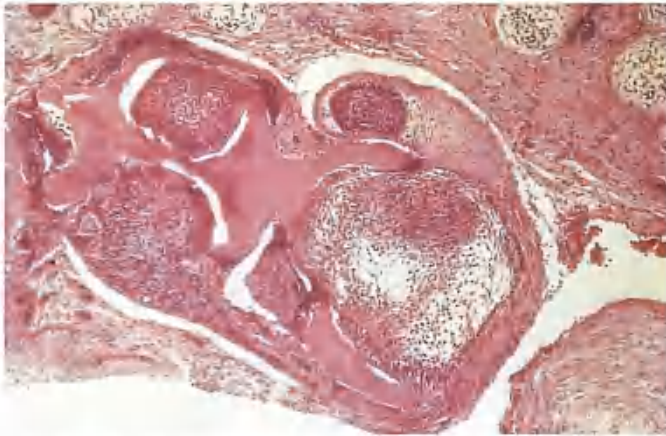


Fig. 15.12 Developing complex odontome showing structures resembling enamel organs and early dentine formation.



Fig. 15.13 Macroscopic appearances of the cut surface of a compound odontome showing separate denticles embedded in fibrous tissue.

many cases the lesion overlies the crown of an unerupted tooth and is discovered incidentally when investigating the cause of a missing tooth from the dental arch. It appears to have a more limited growth potential than the complex odontome and so expansion of bone is less prominent. The compound odontome may also, occasionally, be associated with a calcifying odontogenic cyst.

Radiographically, the developing compound odontome may appear as a radiolucent or mixed radiopaque/radiolucent lesion but, by the time most are detected, they contain recognizable distinct denticles (Fig. 15.14).

Odontogenic tumours

Ameloblastoma

The ameloblastoma is a benign but locally invasive neoplasm derived from odontogenic epithelium. It is rare and only accounts for about 1 per cent of all oral tumours and for about 11 per cent



Fig. 15.14 Compound odontome overlying the crown of an impacted maxillary canine.

Key points – Compound odontome

- developmental lesion resulting in the formation of a bag of discrete denticles
- 1st/2nd decade; predominantly anterior maxilla
- often overlies the crown of an unerupted tooth
- separate denticles identifiable on radiograph
- denticles comprise enamel, dentine, cementum, and pulp in their normal anatomical relationship

of odontogenic tumours in Caucasians. However, it is more common in black Americans, and in West Africans in particular, where it accounts for up to about 60 per cent of odontogenic tumours. Two variants, the unicystic ameloblastoma and the peripheral ameloblastoma, are sufficiently distinct to merit separate mention later in this chapter.

Clinical and radiographic features

Ameloblastomas present over a wide age range but in industrialized countries are usually diagnosed in the fourth and fifth decades of life, although they can occur in children or the elderly. In developing countries, ameloblastoma tends to present about 10–15 years earlier. About 80 per cent of tumours occur in the mandible, of which some 70 per cent arise in the molar region and ascending ramus, 20 per cent in the premolar region, and 10 per cent in the incisor region. In the maxilla, most also occur in the molar region but about 15 per cent involve the antrum.

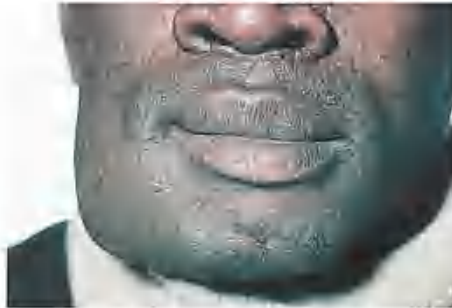

Fig. 15.15 Facial deformity associated with ameloblastoma at angle of mandible.



Fig. 15.16 Radiographic appearances of lesion in Fig. 15.15 showing multilocular radiolucency and root resorption.

The tumour is slow-growing and in the early stages may be asymptomatic and be discovered as an incidental finding. As the tumour enlarges the patient may become aware of a gradually increasing facial deformity and expansion of the jaw-bone (Fig. 15.15). The enlargement is usually bony hard, non-tender, and ovoid or fusiform in outline but in advanced cases, egg-shell crackling may be elicited due to thinning of the overlying bone. However, perforation of bone and extension of the tumour into soft tissues are late features. In the maxilla, even large tumours may produce little expansion as the lesion can extend into the sinus and beyond. Teeth in the area of the tumour may become loosened, but pain is seldom a feature.

Radiographically, the ameloblastoma appears most commonly as a multiloculated radiolucency. Roots of teeth involved by the tumour show varying degrees of resorption (Fig. 15.16). As the tumour enlarges it may become associated with an unerupted tooth, particularly an impacted third molar, and the appearances may mimic those of a dentigerous cyst. Less frequently, ameloblastomas present as a single unilocular radiolucency indistinguishable from an odontogenic cyst (Fig. 15.17). The unicystic ameloblastoma has distinct features and is considered separately in this chapter.

Histopathology

There is considerable variation in the histopathology of ameloblastomas but two main patterns, the follicular and plexiform, are described depending on the arrangement of the neoplastic epithelium. In some tumours both patterns coexist.



Fig. 15.17 Radiographic appearance of unilocular ameloblastoma showing resorption of roots of involved teeth.

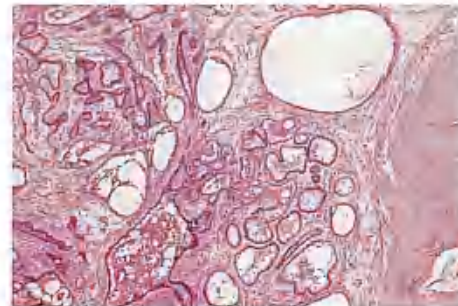


Fig. 15.18 Follicular ameloblastoma showing islands of neoplastic epithelium in mature fibrous stroma.

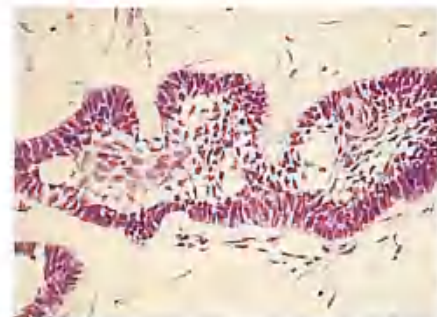


Fig. 15.19 Follicular ameloblastoma showing palisaded peripheral cuboidal/columnar cells and central stellate cells.

The tumour epithelium in the follicular pattern is arranged into more or less discrete, rounded islands or follicles, each one resembling the enamel organ of the developing tooth germ (Fig. 15.18). The follicles each consist of a central mass of loosely connected, angular cells resembling the stellate reticulum of the normal enamel organ, surrounded by a layer of cuboidal or columnar cells resembling ameloblasts. The nuclei of the latter are situated away from the basal ends of the cells, and this is described as reversed polarity (Figs 15.19, 15.24). The follicles are separated by varying amounts of fibrous connective tissue stroma.

A variety of changes can occur within the stellate area of the follicles and these include cystic breakdown, squamous metaplasia, and granular cell change (Figs 15.20–15.22). Microcyst formation is common and by coalescence of these small cysts

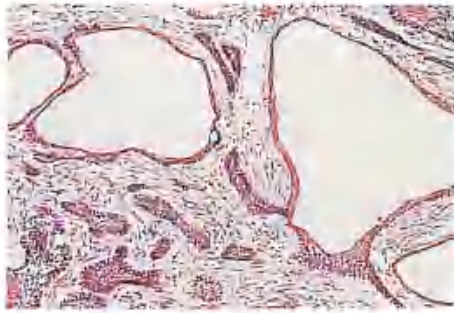


Fig. 15.20 Cystic degeneration in follicular ameloblastoma.

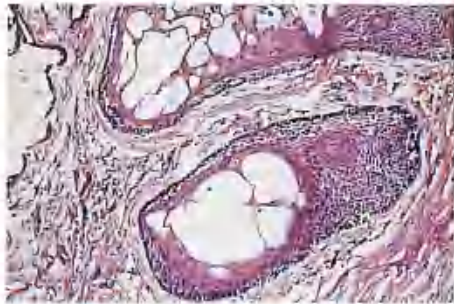


Fig. 15.21 Squamous metaplasia in follicular ameloblastoma.

larger areas of cystic change can occur within the tumour. Small areas of squamous metaplasia are not infrequent, although extensive change of this type is uncommon. In those tumours that show extensive squamous metaplasia the term acanthomatous ameloblastoma is usually applied. Granular cell change is uncommon. The cells are large, eosinophilic, and their cytoplasm contains prominent PAS-positive granules. Electron microscopy has shown that these represent complex lysosomes and residual bodies.

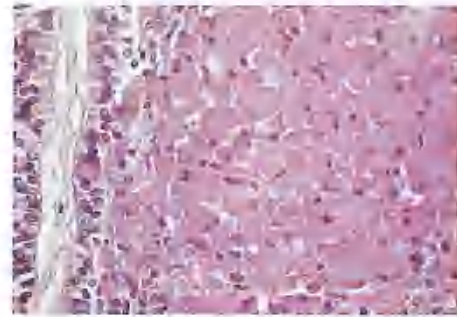


Fig. 15.22 Granular cell change in follicular ameloblastoma.

The tumour epithelium in the plexiform type is arranged as a tangled network of anastomosing strands and irregular masses, each of which shows the same cell layers as for the follicular pattern (Fig. 15.23). Thus each strand or mass is bounded by columnar or cuboidal cells resembling ameloblasts, whilst the central area is occupied by stellate reticulum-like cells (Fig. 15.24). Cyst formation is common but, in contrast to the follicular type, is usually due to stromal degeneration rather than to cystic change within the stellate areas of the epithelium. Again, large areas of cystic change can occur within the tumour by coalescence of stromal cysts.

Pathogenesis

The pathogenesis of the ameloblastoma is unknown but most are thought to arise from residues of the dental lamina. However, other sources of epithelium can give rise to the tumour, such as the lining of a dentigerous cyst in the case of the unicystic ameloblastoma, or the basal layer of the oral epithelium in the case of the peripheral ameloblastoma.

The ameloblast-like cells which characterize the tumour express amelogenin. However, enamel and dentine are not formed and the cells are considered to represent preameloblasts.

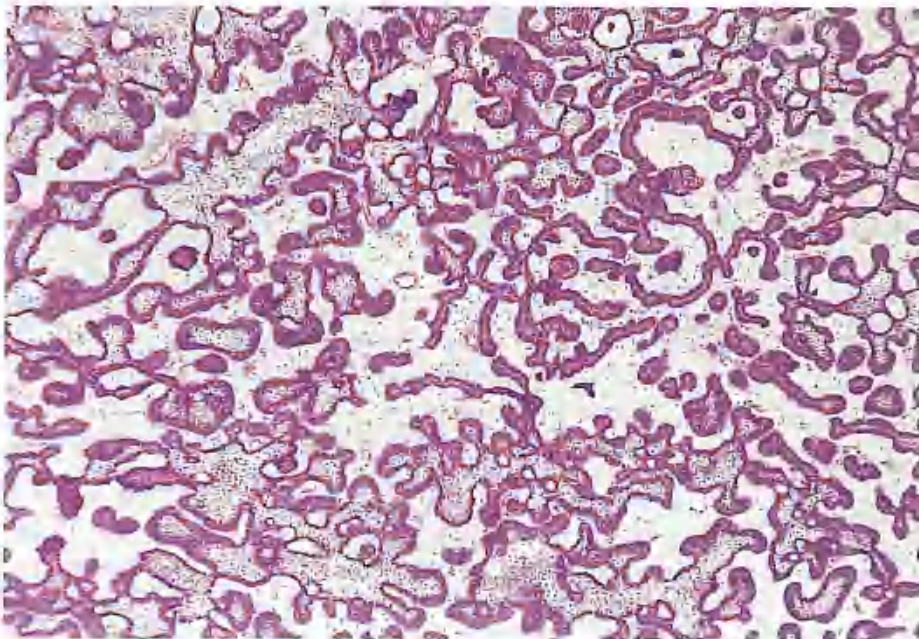


Fig. 15.23 Plexiform ameloblastoma showing complex pattern of interconnecting epithelial strands.

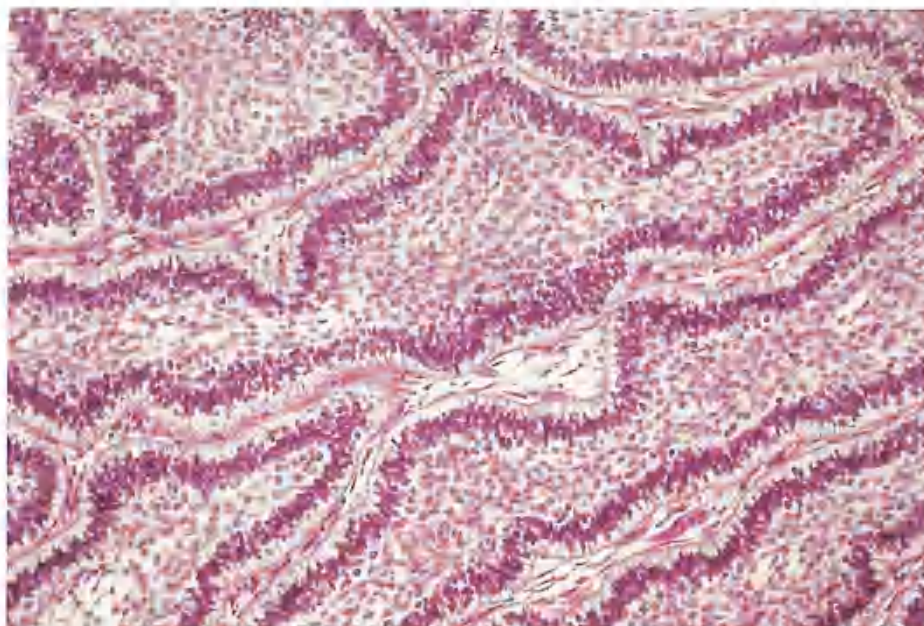


Fig. 15.24 Plexiform ameloblastoma showing peripheral palisaded columnar/cuboidal cells with reversed nuclear polarity, and central stellate cells.

Behaviour

The typical intraosseous ameloblastoma is locally invasive and islands of tumour may infiltrate the cancellous marrow spaces without initially causing bone destruction (Fig. 15.25). These would not be eliminated by simple curettage and such treatment of an ameloblastoma is associated with a high recurrence rate (50–90 per cent). Surgical resection with a margin of normal bone is the preferred treatment. Although it is generally accepted that there are no consistent differences in clinical behaviour between the two main histological types, significantly lower recurrence rates have been reported for some variants, for example the acanthomatous type. Rare reports of pulmonary metastases of typical ameloblastoma are probably the result of implantation of tumour cells into the blood or lymphatic system, or of aspiration of tumour cells, at the time of surgery. (Truly malignant tumours resembling ameloblastoma are designated as ameloblastic carcinoma (see Box 15.1).)

Key points – Ameloblastoma

- A benign but locally invasive neoplasm
- the molar region/ascending ramus of the mandible is commonest site
- typically multilocular on radiograph but may be unilocular
- follicular and plexiform types are the two main patterns
- columnar/cuboidal peripheral cells considered to be preameloblasts
- mature fibrous stroma; does not contain enamel or dentine

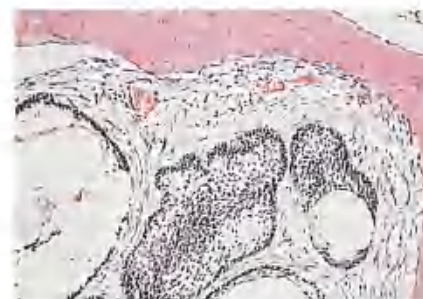


Fig. 15.25 Follicular ameloblastoma infiltrating mandibular marrow spaces.

Unicystic ameloblastoma

This type of ameloblastoma typically presents in a younger age group than other variants of ameloblastoma (second to third decade) and occurs predominantly in the mandibular third molar region. Radiographically, it appears as a well-defined unilocular radiolucency, usually associated with an unerupted tooth, and is indistinguishable from a dentigerous cyst (Fig. 15.26). The diagnosis is made only after histopathological examination.

Histologically, the lesion presents as a cyst lined by ameloblastomatous epithelium comprising a basal layer of columnar cells with polarization of their nuclei away from the basal lamina, covered by a loose, vacuolated layer of stellate epithelial cells. In some cases, there is a localized nodular proliferation of typical plexiform ameloblastomatous tissue into the cyst lumen (Fig. 15.27). A third pattern is identified where ameloblastomatous tissue infiltrates the wall of the cyst, with or without an intraluminal component. This type is important to distinguish since, whilst the first two variants may be treated by simple



Fig. 15.26 Radiographic appearances of a unicystic ameloblastoma presenting as a dentigerous cyst.

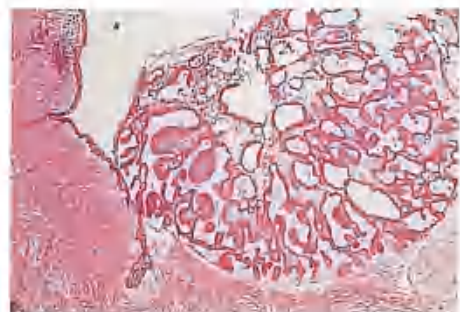


Fig. 15.27 Unicystic ameloblastoma with proliferation into the cyst lumen.

enucleation and curettage, the third is likely to behave as a typical intraosseous lesion and requires to be treated as such.

The pathogenesis of the lesion is unknown. Although it may represent ameloblastomatous change in a dentigerous, or other type of odontogenic cyst, the possibility that it was a grossly cystic ameloblastoma from the outset cannot be excluded.

Peripheral (extraosseous) ameloblastoma

Rarely, ameloblastomas present in the gingival or alveolar soft tissues without involving bone. Such lesions may arise from the basal cell layer of the oral epithelium or from extraosseous rests of the dental lamina. They are much less invasive than intraosseous tumours and less drastic surgery is required for their treatment. Histologically, they may resemble intraosseous types or consist mainly of basaloid cells.

Squamous odontogenic tumour

The squamous odontogenic tumour is rare. Radiographically, it usually presents as a well-circumscribed radiolucency with a sclerotic border associated with the roots of teeth.

Histologically, the tumour consists of irregularly-shaped islands of well-differentiated squamous epithelium in a stroma of mature fibrous tissue. It is thought to be derived from the rests of Malassez.

Calcifying epithelial odontogenic tumour

The calcifying epithelial odontogenic tumour is a rare, benign epithelial neoplasm. It occurs over a wide age range and is about

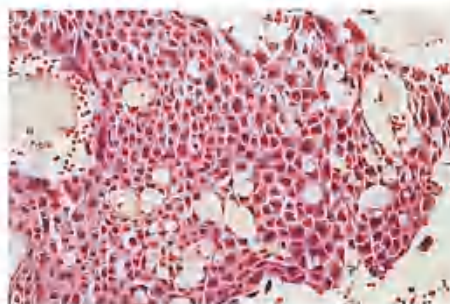


Fig. 15.28 Sheets of polyhedral epithelial cells with prominent intercellular bridges and nuclear pleomorphism in a calcifying epithelial odontogenic tumour.

twice as common in the mandible as in the maxilla. Most of the tumours arise in the molar or premolar area and about half are associated with the crown of an unerupted tooth. Although most tumours arise within bone, extraosseous lesions have been reported.

Radiographs of intraosseous tumours show an irregular radiolucent area which may or may not be clearly demarcated from the surrounding normal bone. The radiolucency contains varying amounts of radiopaque bodies due to calcification within the tumour.

Histologically, the tumour consists of sheets and strands of polyhedral epithelial cells with abundant eosinophilic cytoplasm lying in a fibrous stroma. The epithelial cells often show prominent intercellular bridges and marked nuclear pleomorphism but the latter is not indicative of malignancy (Fig. 15.28). A characteristic feature is the presence within the sheets of epithelial cells of homogeneous, amyloid-like material which may become calcified. The calcifications are concentric laminated structures that may fuse into complex masses. The nature of the amyloid-like material is uncertain but is probably derived from products synthesized by the epithelial cells.

Although the tumour is generally regarded to be locally invasive it appears to be less aggressive than the ameloblastoma.

Adenomatoid odontogenic tumour

The adenomatoid odontogenic tumour usually presents during the second and third decades of life. The majority of tumours arise in the anterior part of the maxilla, especially in the canine areas, and there are usually few symptoms apart from a slowly enlarging swelling. On radiographs it usually appears as a well-defined radiolucency but in some cases calcification within the tumour may produce faint radiopacities. The lesion is often associated with an unerupted tooth and may simulate a dentigerous cyst.

Histologically, the lesion is well encapsulated and may be solid or partly cystic; in some cases the tumour is almost entirely cystic. It consists of sheets, strands, and whorled masses of epithelium which in places differentiates into columnar, ameloblast-like cells. The columnar cells form duct or tubule-like structures (hence adenomatoid) with the central spaces containing homogeneous eosinophilic material (Fig. 15.29). They are thought to

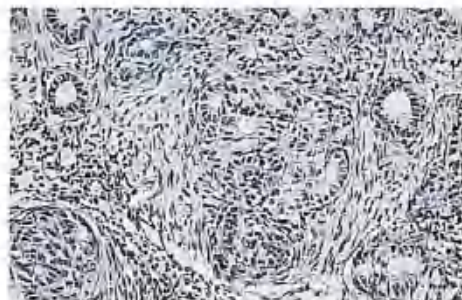


Fig. 15.29 Adenomatoid odontogenic tumour showing duct-like structures.

represent abortive attempts at enamel organ formation. There is very little supporting stroma. Small foci of calcification are scattered throughout the tumour and occasionally tubular dentine and enamel matrix may be seen.

The nature of the lesion is uncertain and it may be hamartomatous rather than truly neoplastic. It must be differentiated from ameloblastoma. The adenomatoid odontogenic tumour is readily enucleated and does not recur: it does not require radical excision.

Ameloblastic fibroma, ameloblastic fibrodentinoma, and ameloblastic fibro-odontoma

The ameloblastic fibroma is a rare benign tumour in which both the epithelial and mesenchymal elements are neoplastic. In ameloblastomas only the epithelium is neoplastic. It is important to differentiate the lesion from ameloblastoma since, unlike the latter, it does not exhibit a locally invasive growth pattern. It is a well-circumscribed lesion and does not require the radical excision that may be necessary to effect cure with the ameloblas-

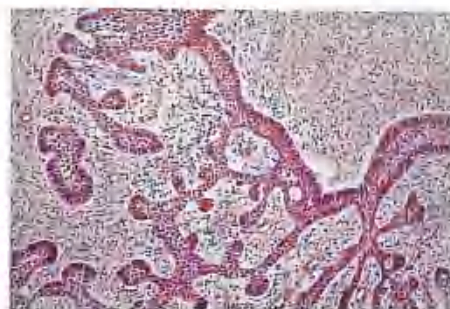

Fig. 15.30 Ameloblastic fibroma showing epithelial component resembling ameloblastoma and cellular mesenchymal component resembling dental papilla.

toma. However, recurrence rates of about 18 per cent have been reported.

The ameloblastic fibroma usually occurs in a younger age group than ameloblastoma and is uncommon over 21 years of age. It presents as a slowly enlarging painless swelling and arises most frequently in the premolar or molar region of the mandible. Radiographically, the tumour appears as a well-defined, usually unilocular, radiolucency. It may be associated with an unerupted tooth and mimic a dentigerous cyst.

Histologically, the tumour consists of proliferating strands and clumps of odontogenic epithelium lying in highly cellular fibroblastic tissue resembling the dental papilla of the developing tooth (Fig. 15.30). The epithelial component shows a peripheral layer of cuboidal or columnar cells which encloses a few stellate reticulum-like cells. The appearances are similar to ameloblastoma but the stellate cells are much less abundant and cyst formation is unusual. The richly cellular mesenchymal component is markedly different from the fibrous stroma of ameloblastoma. There may be a narrow cell-free zone of hyaline connective tissue bordering the epithelial component.

In some lesions dentine may be present and such tumours may be designated ameloblastic fibrodentinoma. The dentine is usually poorly formed and includes entrapped cells. Tubular dentine is rare. Tumours previously classified as dentinomas are now thought to be examples of the ameloblastic fibrodentinoma.

The ameloblastic fibro-odontoma is a tumour which shows further inductive changes leading to the formation of enamel. Although the ameloblastic fibroma and fibrodentinoma are benign neoplasms, it is probable that the ameloblastic fibro-odontoma is a hamartoma. Histologically, it is difficult to distinguish from a developing complex odontome, to which it is probably closely related.

Odontoameloblastoma

The odontoameloblastoma is an exceedingly rare tumour characterized by the combination of ameloblastoma-like tissue with enamel and dentine as irregular masses or small denticles. The lesion appears to behave as an ameloblastoma.

Key points – Ameloblastic fibroma and related lesions

- Ameloblastic fibroma and fibrodentinoma are benign neoplasms
- ameloblastic fibro-odontoma is probably a hamartoma
- all are well circumscribed and occur mainly in 1st and 2nd decade
- comprise odontogenic epithelium and richly cellular mesenchyme
- the fibrodentinoma contains dentine; the fibro-odontoma enamel and dentine
- these lesions must be distinguished from ameloblastoma

Calcifying cystic odontogenic tumour (Calcifying odontogenic cyst) and dentinogenic ghost cell tumour

The calcifying cystic odontogenic tumour is a grossly cystic odontogenic tumour and may be a hamartoma rather than a true benign neoplasm. The dentinogenic ghost cell tumour is histologically very similar except that it is a solid lesion. It was originally considered to represent the solid variant of the calcifying cystic odontogenic tumour. However, as more cases are reported there is increasing evidence that the dentinogenic ghost cell tumour is a distinct pathological entity and is a true benign neoplasm. Both present mainly as central lesions within the jaws but peripheral, gingival lesions also occur.

The calcifying cystic odontogenic tumour occurs over a wide age range but is usually seen below 40 years of age. About 75 per cent are intraosseous and either jaw may be involved. The majority, including those located in the gingival or alveolar soft tissues, arise anteriorly to the first permanent molar tooth. The lesion usually presents as a slowly enlarging but otherwise symptomless swelling.

Radiographically, the lesion appears as a well-defined unilocular or multilocular radiolucent area containing varying amounts of radiopaque, calcified material. It may be associated with the crown of an unerupted tooth.

Histologically, the cyst is lined by epithelium which shows a well-defined basal layer of columnar, ameloblast-like cells and overlying layers of more loosely arranged cells that may resemble stellate reticulum. A characteristic feature (Fig. 15.31) is the presence within the lining of masses of swollen and keratinized epithelial cells which are usually referred to as 'ghost' cells since the original cell outlines can still be discerned (Fig. 15.32). The

'ghost' epithelial cells may calcify. Breakdown of the epithelium may release keratinous debris into the supporting connective tissue resulting in a prominent foreign-body, giant-cell reaction. Irregular masses of dentine-like matrix material (dentinoid) are frequently found in the supporting fibrous tissue in direct contact with the basal layer of the epithelium (Fig. 15.33). Less commonly, more extensive formation of dental hard tissues is seen, including enamel, producing a structure similar to a complex or compound odontome as an integral part of the lesion. Calcifying cystic odontogenic tumour associated with odontomes tend to occur in a younger age group and most have presented in the anterior maxilla.

The dentinogenic ghost cell tumour is a predominantly solid lesion which comprises the same epithelial, keratinized ghost cells and dentinoid components as the calcifying cystic odontogenic tumour, but as a disorganized mass. It tends to occur in an older age group than the calcifying cystic odontogenic tumour. Like the calcifying cystic odontogenic tumour some respond well to conservative treatment. However, others pursue a more aggressive course and, like the ameloblastoma, are locally invasive neoplasms.

Odontogenic fibroma and odontogenic myxoma/myxofibroma

The odontogenic fibroma and myxoma of the jaws are derived from mesenchymal dental tissues. They may arise in relation to the root of a tooth, to the crown of an unerupted tooth, or may take the place of a tooth missing from the arch. These different presentations reflect the different mesenchymal tissues that may give rise to the tumours – periodontal ligament, dental follicle, and dental papilla.

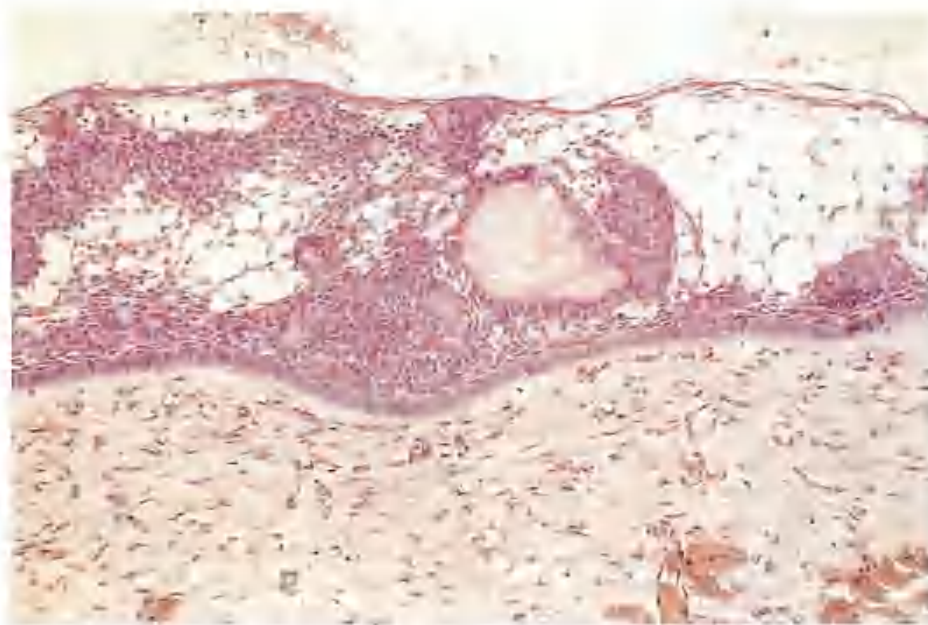


Fig. 15.31 Calcifying cystic odontogenic tumour showing palisaded basal layer, stellate cells, and keratinized ghost cells.

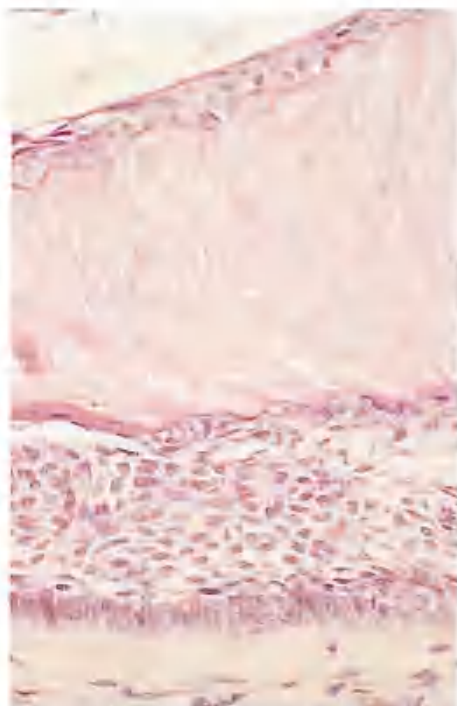


Fig. 15.32 High-power view of keratinized ghost cells in a calcifying cystic odontogenic tumour.

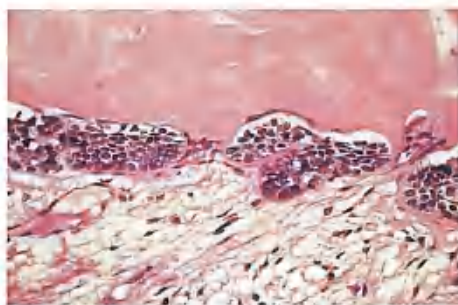


Fig. 15.33 Dentine-like matrix in a calcifying cystic odontogenic tumour

The central odontogenic fibroma is a relatively uncommon, well-demarcated, and readily enucleated benign fibroblastic neoplasm comprising cellular fibrous tissue containing varying amounts of apparently inactive odontogenic epithelium. Foci of cementum-like material and dentine-like matrix may also be present.

A peripheral odontogenic fibroma is also recognized which may present clinically as a fibrous epulis. Histologically, it comprises fibrous or fibromyxoid tissue containing varying amounts of odontogenic epithelium and sometimes cementum or dentinoid material.

The odontogenic myxoma is a benign but locally invasive neoplasm and is more common than the odontogenic fibroma. Radiographically, it appears typically as a multilocular radiolucency (soap-bubble appearance) often with a well-defined margin, although, histologically, the lesion is non-encapsulated and has an

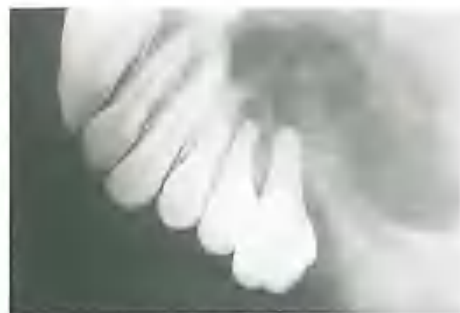

Fig. 15.34 Odontogenic myxoma presenting as a multilocular radiolucency.




Fig. 15.35 Odontogenic myxoma stained by Alcian blue to show abundance of glycosaminoglycans in the stroma.

infiltrative pattern of growth (Fig. 15.34). Roots of teeth involved by the tumour may show resorption.

Histologically, the tumour consists of stellate, fibroblast-like cells with long anastomosing processes, separated by abundant connective tissue ground substances, predominantly glycosaminoglycans (Fig. 15.35). Some cases contain a few strands of odontogenic epithelium. Variable amounts of collagen may be present and if this is prominent the tumour may be designated as myxofibroma and fibromyxoma.

Unlike the fibroma which is readily enucleated, the locally invasive growth of a myxoma predisposes to local recurrence. Recurrence rates vary from about 10–30 per cent in different series.

Cementoblastoma (true cementoma)

Cementum is a modified form of bone and, with the exception of the cementoblastoma, disorders of the jaws containing cementum-like tissue are now classified as lesions of bone. The cementoblastoma is still classified as an odontogenic tumour because of its unique association with the root of a tooth. It is this which distinguishes it, otherwise it is indistinguishable from osteoblastoma of bone.

The cementoblastoma is a rare benign neoplasm most frequently seen in patients under 25 years of age. It usually arises in the molar or premolar area of the mandible and is attached to the root of a tooth. Most cases involve the mandibular first permanent

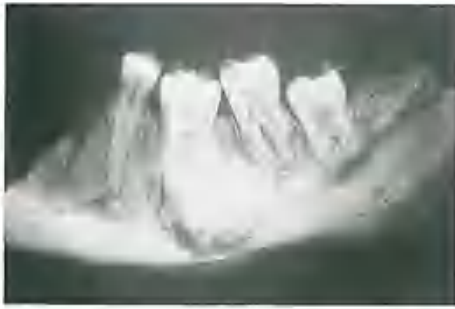

Fig. 15.36 Radiographic appearances of cementoblastoma.

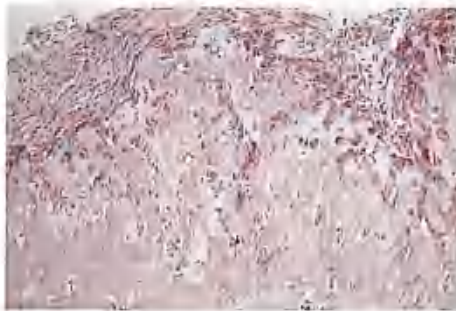


Fig. 15.37 Cementoblastoma showing central calcified material rimmed by cementoblasts.

molar. It presents as a slowly enlarging swelling which sometimes gives rise to pain, but the involved tooth is vital. Radiographs show a well-demarcated, mottled, or dense radiopaque mass with a radiolucent margin attached to the root of a tooth which usually shows resorption (Fig. 15.36). Histologically, the tumour consists of a mass of calcified cementum-like tissue containing scattered cells lying in lacunae. Around the periphery and in other actively growing parts of the lesion, extensive sheets of uncalcified matrix formed by plump, deeply staining cementoblasts may be seen (Fig. 15.37). Lesions which are incompletely removed may recur.

Malignant odontogenic tumours

Odontogenic carcinomas are rare and odontogenic sarcomas exceedingly rare. Examples are given in Box 15.1.

Tumours of debatable origin

Melanotic neuroectodermal tumour of infancy

This rare tumour occurs in infants usually in the first year of life. It arises much more frequently in the maxilla than the mandible or elsewhere in the body. It usually presents as an otherwise symptomless mass expanding the bone.

The histogenesis of the tumour is uncertain, but there is good evidence that the lesion is derived from cells of neural crest

Box 15.1 Malignant odontogenic tumours

- *Ameloblastic carcinoma*: a carcinoma with the pattern of a follicular or plexiform ameloblastoma, palisaded columnar basal cells, hypercellular stellate reticulum-like areas, mitotic figures, varying degrees of nuclear/cellular pleomorphism
- *Primary intraosseous squamous cell carcinoma*: rare, presumed to arise from residues of odontogenic epithelium
- *Clear cell odontogenic carcinoma*: sheets and islands of cells with clear cytoplasm rich in glycogen, separated by a fibrous stroma
- *Malignant change in odontogenic cysts*: a squamous cell carcinoma with clinical, radiological, or histological evidence consistent with an origin from an odontogenic cyst (e.g. radicular, dentigerous, keratocyst). Some cyst linings show dysplasia consistent with premalignant change
- *Odontogenic sarcomas*: malignant counterpart of ameloblastic fibroma and related lesions, fibrosarcomas containing non-neoplastic odontogenic epithelium and occasionally dental hard tissues, e.g. ameloblastic fibrosarcoma/fibrodentinosarcoma

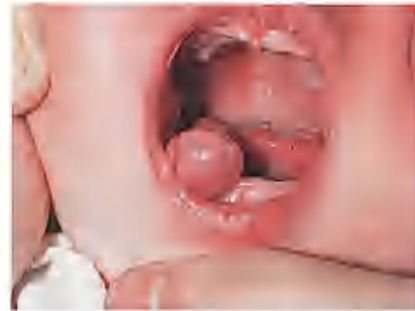

Fig. 15.38 Congenital gingival granular cell tumour (congenital epulis)

origin. Most are benign and recurrence is uncommon following conservative excision.


Congenital gingival granular cell tumour (congenital epulis)

This rare lesion occurs in newborn infants (Fig. 15.38) and is usually located in the incisor region of the maxilla. Females are affected about ten times more frequently than males.

Histologically, the lesion consists of large, closely packed granular cells covered by a flattened layer of squamous epithelium. Its nature and origin are unknown but it is probably reactive rather than truly neoplastic, and odontogenic, fibroblastic, neurogenic, and vascular origins have all been suggested. (It is not related to the granular cell tumour discussed in Chapter 8.) It is benign and does not recur following excision.

Further reading

- Brannon, R. B., Fowler, C. B., Carpenter, W. M., and Corio, R. L. (2002). Cementoblastoma: an innocuous neoplasm? A clinicopathological study of 44 cases and review of the literature with special emphasis on recurrence. *Oral Surgery, Oral Medicine, Oral Pathology, Oral Radiology and Endodontics*, 93, 311–20.
- Daley, T. D. and Wysocki, G. P. (1994). Peripheral odontogenic fibroma. *Oral Surgery, Oral Medicine, Oral Pathology*, 78, 329–36.
- Danker, E., Harari, D., and Rotstein, C. D. (1996). Dens evaginatus of anterior teeth: literature review and radiographic survey of 15 000 teeth. *Oral Surgery, Oral Medicine, Oral Pathology, Oral Radiology and Endodontics*, 81, 472–6.
- Fregnani, E. R., Fillipi, R. Z., Olivera, C. R. G. C. M., Vargas, P. A., and Almeida, O. P. (2002). Odontomas and ameloblastomas: variable prevalences around the world? *Oral Oncology*, 38, 807–8.
- Hirshberg, A., Kaplan, I., and Buchner, A. (1994). Calcifying odontogenic cyst associated with odontoma. *Journal of Oral and Maxillofacial Surgery*, 52, 555–8.
- Hulsmann, M. (1997). Dens invaginatus: aetiology, classification, prevalence, diagnosis, and treatment considerations. *International Endodontic Journal*, 30, 79–90.
- Kaplan, I., Buchner, A., Calderon, S., and Kaffe, I. (2001). Radiological and clinical features of calcifying epithelial odontogenic tumour. *Dento-Maxillo-Facial Radiology*, 30, 22–8.
- Kramer, I. R. H., Pindborg, J. J., and Shear, M. (1992). *Histological typing of odontogenic tumours* (2nd edn). World Health Organization International Classification of Tumours. Springer-Verlag, Berlin.
- Nelson, Z. L., Newman, L., Loukota, R. A., and Williams, D. M. (1995). Melanotic neuroectodermal tumour of infancy: an immunohistochemical and ultrastructural study. *British Journal of Oral and Maxillofacial Surgery*, 33, 375–80.
- Petola, J., Magnusson, B., Happonen, R.-P., and Borman, H. (1994). Odontogenic myxoma:—a radiographic study of 21 tumours. *British Journal of Oral and Maxillofacial Surgery*, 32, 298–302.
- Philipsen, H. P. and Reichart, P. A. (1998). Unicystic ameloblastoma: a review of 193 cases from the literature. *Oral Oncology*, 34, 317–25.
- Philipsen, H. P. and Reichart, P. A. (2000). Calcifying epithelial odontogenic tumour: biological profile based on 181 cases from the literature. *Oral Oncology*, 36, 17–26.
- Philipsen, H. P., Reichart, P. A., and Praetorius, F. (1997). Mixed odontogenic tumours and odontomas: considerations on interrelationship. Review of the literature and presentation of 134 new cases of odontomas. *Oral Oncology*, 32, 86–99.
- Philipsen, H. P., Samman, N., Ormiston, I. W., Wu, P. C., and Reichart, P. A. (1992). Variants of the adenomatoid odontogenic tumour with a note on tumour origin. *Journal of Oral Pathology and Medicine*, 21, 348–52.
- Reichart, P. A., Philipsen, H. P., and Sonner, S. (1995). Ameloblastoma: biological profile of 3677 cases. *Oral Oncology, European Journal of Cancer*, 31B, 86–99.
- Ulmansky, M., Hjørtting-Hansen, E., Praetorius, F., and Hague, E. (1994). Benign cementoblastoma. A review and five new cases. *Oral Surgery, Oral Medicine, Oral Pathology*, 77, 48–55.



Disorders of bone

INHERITED AND DEVELOPMENTAL DISORDERS OF BONE

Osteogenesis imperfecta
 Osteopetrosis (marble bone disease)
 Cleidocranial dysplasia (cleidocranial dysostosis)
 Achondroplasia
 Fibro-osseous lesions
 Fibrous dysplasia of bone
 Cemento-osseous dysplasia
 Cherubism

HEALING OF BONE

Healing of an extraction socket
 Osseointegrated implants

INFLAMMATORY DISEASES OF BONE

Alveolar osteitis (dry socket)
 Focal sclerosing (condensing) osteitis
 Osteomyelitis
 Chronic periostitis associated with hyaline bodies (pulse/vegetable granuloma)
 Radiation injury and osteoradionecrosis

METABOLIC AND ENDOCRINE DISORDERS OF BONE

Osteoporosis
 Primary hyperparathyroidism

Secondary hyperparathyroidism
 Rickets and osteomalacia
 Acromegaly

PAGET'S DISEASE OF BONE

CENTRAL GIANT CELL GRANULOMA

TORUS PALATINUS, TORUS MANDIBULARIS, AND OTHER EXOSTOSES

DENSE BONE ISLAND

TUMOURS OF BONE

Osteoma and osteoblastoma
 Osteosarcoma
 Chondroma and chondrosarcoma
 Myeloma
 Ossifying (cemento-ossifying) fibroma

LANGERHANS CELL HISTIOCYTOSIS

HAEMANGIOMA OF BONE

METASTATIC TUMOURS

FURTHER READING



Disorders of bone

Inherited and developmental disorders of bone

Patients with inherited or developmental disorders of bone are infrequently seen in dental practice, partly because the disorders are uncommon and partly because jaw involvement may only be a minor feature or be absent altogether. Four of the more common inherited developmental disorders of bone are described in this chapter together with the fibro-osseous lesions. In addition, there are many types of developmental malformations of the head and jaws in which the structure of the bone is normal, for example those associated with cleft palate.

Osteogenesis imperfecta

This hereditary disease consists of a heterogeneous group of related disorders caused by mutations in the genes that code for type-1 collagen. It is characterized by generalized osteoporosis with slender bones and a marked tendency for the bones to fracture on slight provocation. The slender long bones have narrow, poorly formed cortices composed of immature, woven bone, but fractures usually heal without trouble although exuberant callus may be formed. The sclerae may appear blue because they are so thin that the pigmented choroid shines through (Fig. 16.1), and there is sometimes a family history of deafness caused by distortion of the ossicles in the ears. Other abnormalities which may be present are joint hypermobility with lax ligaments, thin translucent skin, and heart valve defects. Osteogenesis imperfecta is often associated with dentinogenesis imperfecta (Fig. 16.2),

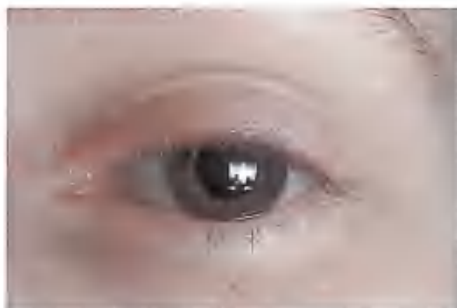

Fig. 16.1 Blue sclera in osteogenesis imperfecta type I.

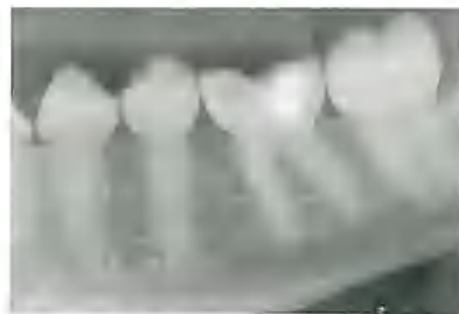

Fig. 16.2 Osteogenesis imperfecta with dentinogenesis imperfecta. Note delicate bone trabeculae and obliteration of pulp chambers.

especially in the deciduous dentition (see Chapter 1), and it is thought the two defects are carried by separate but related genes.

Four main types of osteogenesis imperfecta have been described (see Box 16.1).

Osteopetrosis (marble bone disease)

This is a rare disease characterized by excessive density of all bones with obliteration of marrow cavities and the development of a secondary anaemia. There appears to be a defect in osteoclastic activity and, as normal bone formation relies on the interdependence of deposition and resorption, there is a failure in the remodelling of the developing bone. There is, therefore, an excessive formation of bone which is mechanically weak and so fractures are common. The jaws are composed of dense bone with greatly reduced medullary spaces. Delayed eruption of teeth may occur and osteomyelitis is a common complication of tooth extraction.

Radiographic examination shows an increased density of the whole skeleton with no distinction between cortical and medullary bone. The base of the skull shows marked radiopacity whereas the vault is generally less dense. Jaw involvement is variable, the mandible being more frequently affected than the maxilla, and the density of the bone may render the roots of the teeth almost invisible on radiographs.

Cleidocranial dysplasia (cleidocranial dysostosis)

This disease is transmitted as an autosomal dominant trait (see Box 16.1). It is characterized by abnormalities of many bones, but

Box 16.1 Developmental disorders of bone

Osteogenesis imperfecta

- 80–90 per cent have mutations in one of the two type I collagen genes
- clinically heterogeneous disorder; four main types described:
 - type I (classic type): autosomal dominant, blue sclera, premature deafness, with or without dentinogenesis imperfecta
 - type II (perinatal lethal): autosomal dominant
 - type III (progressively deforming): autosomal dominant/recessive, severe osteoporotic bone, progressive deformity, dentinogenesis imperfecta
 - type IV: autosomal dominant. Similar to type I but more severe, white sclera, with or without dentinogenesis imperfecta

Cleidocranial dysplasia

- caused by mutations to the RUNX2 gene (previously CBFA1)
- gene encodes for a transcription factor needed for differentiation of osteoblasts from precursor cells.

Fibrous dysplasia

- occurs sporadically; not inherited
- caused by mutation occurring in somatic cells in either foetal or postnatal life
- mutation in foetal life may be associated with polyostotic disease; postnatal mutation may be associated with monostotic disease
- gene involved is the GNAS1 gene which encodes for a stimulatory protein
- mutation leads to inappropriate activation of cyclic AMP, resulting in alterations in gene expression/signalling pathways important in controlling growth and differentiation of osteoblasts

Cherubism

- gene mapped to area of chromosome 4p associated with the fibroblast growth factor receptor 3 (FGFR3) gene
- mutations in FGFR3 known to be associated with other developmental disorders of bone/cartilage and therefore a strong candidate gene for cherubism

particularly of the skull, jaws, and clavicle. Dental anomalies are also common. A variety of abnormalities of the skull may be present, the fontanelles and sutures tend to remain open and the skull appears flat with prominent frontal, parietal, and occipital bones. The nasal bridge is also depressed. Partial or complete

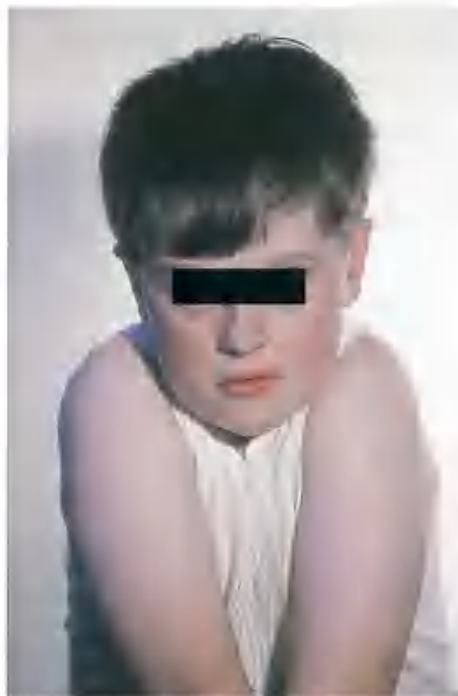

Fig. 16.3 Absence of clavicles in cleidocranial dysplasia allowing shoulders to be brought forwards.

absence of the clavicles allows the shoulders to be brought forwards until they meet in the midline (Fig. 16.3). The maxilla may be underdeveloped with a high, narrow arched palate. The deciduous dentition tends to be retained with delayed or non-eruption of the permanent dentition because of multiple impactions (Figs 16.4, 16.5). Supernumerary teeth and dentigerous cysts are also common. The roots of the teeth tend to be thinner than normal and secondary, cellular cementum is either absent or sparsely present on both deciduous and permanent teeth.

Achondroplasia

This disorder may be inherited as an autosomal dominant trait, but many cases have no family history and appear to be due to spontaneous mutations. It is the most common form of dwarfism and is associated with an abnormality in endochondral ossification. There is an absence or a defect in the zone of provisional calcification of the cartilage in the epiphyses and in the base of the

Key points – Inherited disorders of bone

- uncommon diseases
- jaw involvement variable
- orofacial manifestations include:
 - abnormalities in number, form, and structure of teeth
 - malocclusion
 - abnormal facial appearances

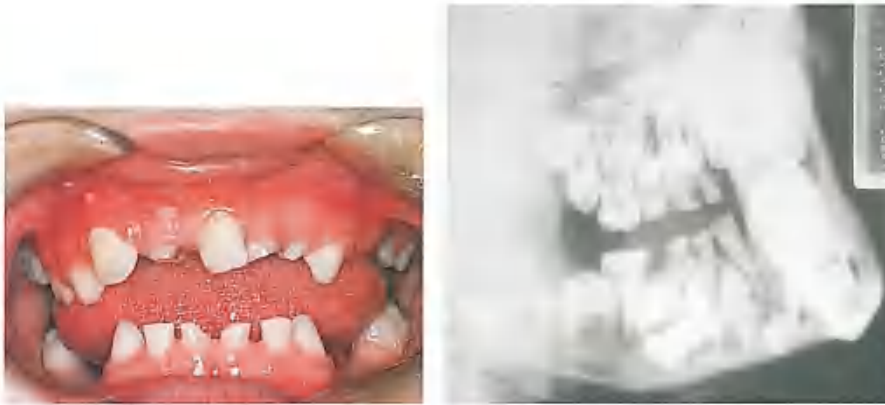


Fig. 16.4 and 16.5 Retention of deciduous teeth with multiple impactions of permanent teeth in cleidocranial dysplasia.

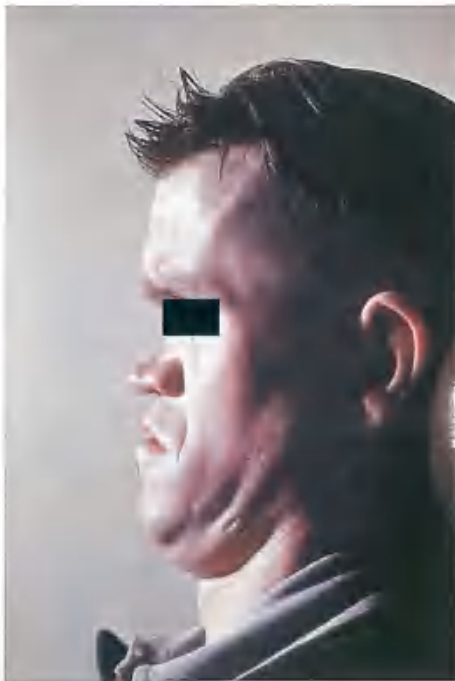

Fig. 16.6 Retrusive middle third of the face in achondroplasia.

skull. The trunk and head are of normal size but the limbs are excessively short. The middle third of the face is retrusive due to defective growth of the base of the skull (Fig. 16.6) and severe malocclusion is common.

Fibro-osseous lesions

The term fibro-osseous lesion is used to describe a variety of disorders which, histologically, are characterized by the replacement of normal bone by cellular fibrous tissue within which varying amounts of predominantly woven bone and acellular islands of mineralized tissue develop. They cannot be distinguished by histology alone and in their diagnosis the clinical and radiographic features must also be considered.

The diseases included in this group of lesions can be divided into those characterized by disorganized development of bone

Table 16.1 Fibro-osseous lesions

<i>A. Osseous dysplasia</i>
Fibrous dysplasia
– monostotic
– polyostotic
Cemento-osseous dysplasia
(periapical cemental dysplasia, focal cemento-osseous dysplasia, gigantiform dysplasia)
<i>B. Benign neoplasia</i>
Ossifying fibroma/cemento-ossifying fibroma

(osseous dysplasias), and benign fibro-osseous neoplasms of bone. Within the jaws they include lesions previously considered to be derived from cementum, but, since the latter is a modified form of bone, this distinction is somewhat artificial. Nevertheless, it is helpful for diagnostic purposes to distinguish between dysplasias of bone that are generalized skeletal disorders and those which appear localized to the jaws, particularly to the tooth-bearing areas. The term 'cemento-osseous dysplasia' has been retained for the latter. It incorporates several lesions previously thought to be distinct but now considered as variations of the same disorder. The main fibro-osseous lesions are listed in Table 16.1.

Fibrous dysplasia of bone

Fibrous dysplasia of bone may involve one or several bones in the body, and the terms 'monostotic' and 'polyostotic' are applied to these different forms of the disease.

Monostotic fibrous dysplasia

Monostotic fibrous dysplasia is much more common than polyostotic forms. Virtually any bone may be involved but the lesion arises most frequently in a limb bone, rib, or skull bone, particularly the jaws. Jaw lesions are more common in the maxilla than mandible. When the maxilla is affected, adjacent bones such as the zygoma and sphenoid may also be involved and the disease is then not strictly monostotic. However, since the distribution is restricted to contiguous bones within a defined anatomical area the pattern is not that typically associated with polyostotic disease.

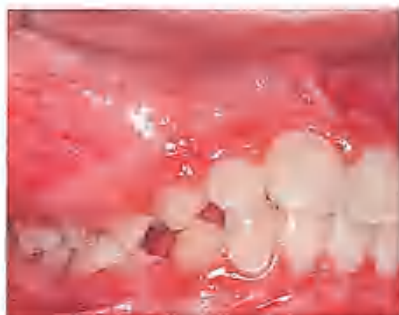

Fig. 16.7 Buccal expansion of the maxilla in fibrous dysplasia.

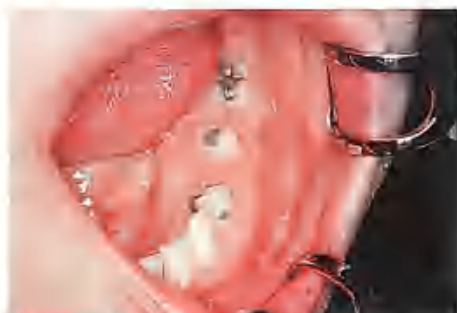

Fig. 16.8 Fibrous dysplasia of the mandible showing fusiform expansion and displacement of teeth.



Fig. 16.9 Radiograph of the mandible in Fig. 16.8 showing increase in depth of the jaw and ground-glass appearance of bone.

For these reasons, it has been suggested that the term 'craniofacial fibrous dysplasia' is appropriate in such circumstances.

The majority of patients with monostotic fibrous dysplasia present in childhood or adolescence, but occasionally the disease is not diagnosed until adult life. Patients presenting in adult life may have been aware of a quiescent bony enlargement for some years and may give a history of recent expansion of the lesion which has prompted them to seek advice. Reactivation of quiescent lesions may occur for unknown reasons and has been reported in pregnancy.

In either jaw the first sign of the disease is a gradually increasing painless swelling which is not well circumscribed and which causes a gradually increasing facial asymmetry. The enlargement is usually smooth, often fusiform in outline, and is more pronounced buccally than lingually or palatally. When the maxilla



Fig. 16.10 Intraoral radiograph of fibrous dysplasia of the maxilla showing ground-glass/orange-peel-stippling of bone.

is involved there is usually increased prominence of the cheek and buccal expansion distal to the canine, which may extend to involve the tuberosity (Fig. 16.7). The canine fossa is obliterated. Maxillary lesions commonly extend locally to involve the sinus, zygomatic process, and floor of orbit, and the orbital contents may be displaced. In some cases where growth is more rapid and extensive, there may be marked swelling of the cheek with exophthalmos and proptosis. Mandibular lesions occur most frequently in the molar and premolar regions and if the lower border is involved there may be an obvious protruberance and increase in depth of the jaw (Figs 16.8, 16.9). In either jaw there may be some malalignment, tipping, or displacement of teeth and in children any teeth involved by the lesion may fail to erupt.

Radiographically, the jaw lesions are variable in appearance and their borders are often difficult to define because of the gradual transition to a normal, uninvolved bone pattern. The variable appearances reflect differing amounts of bone formed within the fibrous tissue of the lesions. The lesions may be radiolucent initially but as the degree of trabeculation increases they become mottled and eventually opaque, the many delicate trabeculae giving a ground-glass or orange-peel-stippling effect on intraoral radiographs (Fig. 16.10). In the maxilla, lesions may extend up to and distort, but do not cross, the suture lines.

Roots of teeth in the involved areas may be separated and the teeth may be displaced.

Polyostotic fibrous dysplasia

Polyostotic fibrous dysplasia is two to three times as common in females as males and the distribution of lesions is very variable. They frequently occur in the bones of one limb, especially the lower, but the skull, vertebrae, ribs, and pelvis are also often involved. Although almost any combination can occur there is a tendency for the lesions to arise segmentally and to be localized in one limb or on one side of the body.

Patients with severe polyostotic disease are usually diagnosed in childhood because of the associated bony deformities and pathological fractures. The polyostotic form may also present as McCune-Albright syndrome, a rare and severe form of the disorder, in which the bone lesions are accompanied by skin pigmentation, precocious puberty in females, and occasionally other endocrine abnormalities.

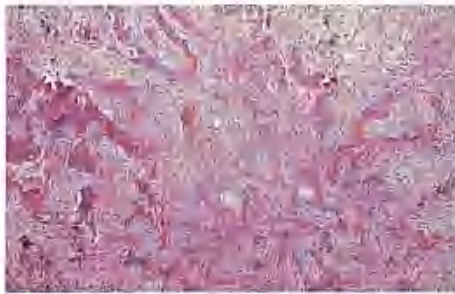


Fig. 16.11 Delicate trabeculae of woven bone forming in fibrous tissue in fibrous dysplasia. The pattern of the trabeculae may resemble Chinese characters.

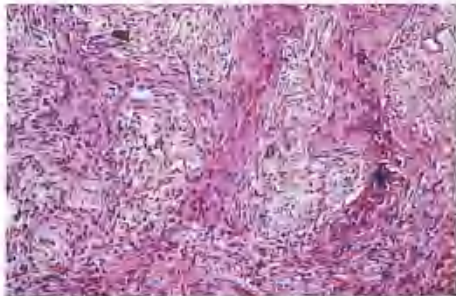


Fig. 16.12 Trabeculae of coarse-fibred woven bone forming in cellular fibrous tissue in fibrous dysplasia.

Key points – Fibrous dysplasia of the jaws

- more common in maxilla than mandible
- fusiform bony expansion; maxillary lesions also expand into sinus
- radiographic features vary depending on amount of bone formed within lesion
- margins of lesion merge with surrounding normal bone
- delicate trabeculae of woven bone in cellular or collagenous fibrous tissue
- expansion usually stops with skeletal maturation
- remodelling of woven to lamellar bone may occur with increasing age

Pathology

Microscopically, the lesions show replacement of normal bone by fibrous tissue containing islands and trabeculae of metaplastic woven bone (Fig. 16.11). However, foci of lamellar bone and of osteoblastic rimming of trabeculae may also be seen in jaw lesions, as may spheroidal areas of relatively acellular calcified tissue. The fibrous tissue may be richly cellular or consist mainly of interlacing collagen bundles.

Typically, the newly formed trabeculae of bone are delicate and of irregular shape, resembling Chinese characters, and consist of

immature, coarse-fibred woven bone (Figs 16.11, 16.12). In jaw lesions the trabeculae may be thicker and blunter than in long bones. At the margins of the lesion the lesional bone fuses with that of the surrounding normal bone and it is this feature in particular which distinguishes the lesion from ossifying fibroma. It is suggested that with increasing age of the lesions the amount and cellularity of the fibrous tissue decreases whilst the amount of bone increases, although these are not constant features. As the lesion matures there is progressive remodelling of the woven bone to lamellar bone. Occasionally, the lesion may also be associated with the development of aneurysmal bone cyst (see Chapter 6).

Aetiology and behaviour

The pathogenesis of fibrous dysplasia is complex but the genetic mutations and signalling pathways involved are beginning to be unravelled (see Box 16.1). It is a developmental disorder but it is not inherited.

A few cases of malignant transformation of fibrous dysplasia have been reported, usually to fibrosarcoma, some of which have followed radiotherapy. However, the lesions of fibrous dysplasia are not radiosensitive and radiotherapy, which may increase the risk of malignant change, is not an acceptable treatment. The majority of cases are treated by conservative surgical removal of sufficient of the lesion to reduce deformity. The lesions tend to expand mainly during the period of active skeletal growth and become quiescent in adult life.

Cemento-osseous dysplasia

As discussed previously, this term has been retained to identify osseous dysplasia which is localized to the jaws and which predominantly involves the tooth-bearing areas. It incorporates the lesions previously described as periapical cemental dysplasia, its localized variant – focal cemento-osseous dysplasia, and a more widespread disorder – florid cemento-osseous dysplasia. These are now considered to be different clinical presentations of the same disorder.

Cemento-osseous dysplasia shows the characteristic features of a fibro-osseous lesion, comprising fibrous tissue within which varying amounts of bone/calcified acellular tissue develops (Fig. 16.13). The radiographic features of the lesion (or lesions if multiple) reflect the extent of mineralization and may be radiolucent,

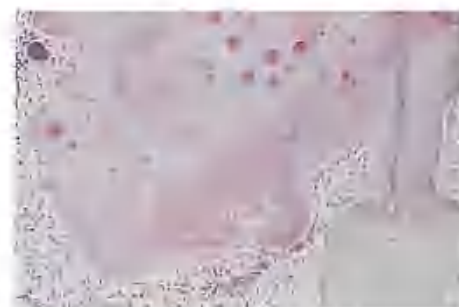

Fig. 16.13 Cemento-osseous dysplasia comprising mainly dense, relatively acellular masses of calcified tissue, from a patient with multiple (florid) lesions (see Fig. 16.14).



Fig. 16.14 Multiple lesions of cemento-ossous dysplasia involving the mandible, showing varying degrees of mineralization.

mixed, or radiopaque. Cemento-ossifying dysplasia is more prevalent in women than in men, and occurs predominantly in the mandible. The majority of patients are over 30 years of age.

Clinically, cemento-ossous dysplasia presents a range of appearances. They may be multiple and small (less than 1 cm diameter) and be associated, particularly, with the apical areas of the mandibular incisors (previously designated as periapical cemental dysplasia). At the other extreme, the lesions are multiple, large, and involve one or more quadrants in one or both jaws (Fig. 16.14) (previously designated as florid cemento-ossous dysplasia). They may be associated with expansion of the jaws.

Cherubism

Cherubism is a rare disorder of bone inherited as an autosomal dominant character with variable expressivity (see Box 16.1). Males are affected about twice as frequently as females. The descriptive term 'cherubism' relates to the unusual clinical appearance and facial deformity of patients with this disease.

Clinical and radiographic features

Children with cherubism appear normal at birth but painless swellings of the jaws appear between the ages of 2 and 4 years. The swellings are usually symmetrical and always involve the mandible either alone or in combination with the maxilla. They enlarge rather rapidly up to the age of about 7 years but then become static and begin to regress, with progressive reduction in the facial deformity, as the patient passes from puberty into adult life. The characteristic facial deformity is a fullness of the cheeks and jaws producing a typical chubby face (Fig. 16.15). There is often a rim of sclera visible beneath the iris due to stretching of

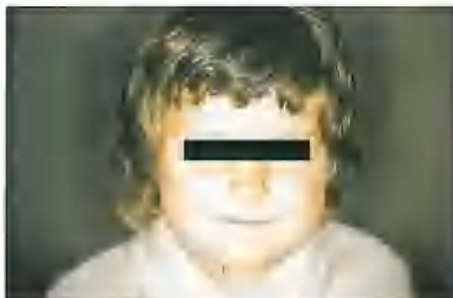

Fig. 16.15 Chubby face of cherubism.



Fig. 16.16 Bilateral multilocular radiolucencies involving the angles of the mandible in a patient with cherubism.

the skin over the swellings or to upward displacement of the orbit by maxillary lesions, so that the eyes appear upturned to heaven. The chubby face and upturned eyes produce a cherubic appearance and the chubbiness is enhanced by fullness of the submandibular space due to enlargement of the submandibular lymph nodes. (Histologically, the nodes show reactive hyperplasia; they subside completely during adolescence.) Abnormalities of the dentition include premature loss of deciduous teeth and displacement, lack of eruption, and failure of development of many permanent teeth.

Radiological examination shows sharply defined, multilocular radiolucencies (Fig. 16.16) with expansion and severe thinning of the cortical plates which may even be perforated. Mandibular lesions appear to begin near the angle and then spread to involve the body and ramus of the bone, although the condyle is spared. Maxillary lesions are often confined to the tuberosities but the sinus may be obliterated.

Pathology and behaviour

Microscopically, the lesions consist mainly of cellular and vascular fibrous tissue containing varying numbers of multinucleate giant cells (Fig. 16.17). The giant cells resemble those found in other giant cell lesions of bone and these conditions cannot be differentiated on the basis of histology alone. However, cherubism is unlikely to be confused with the others when the characteristic history and clinical features are taken into consideration. The giant cells are distributed as focal collections, often around thin-walled vascular channels. In addition, many vessels are surrounded by a cuff of hyaline, eosinophilic collagen. Extravasated red blood cells and deposits of haemosiderin are common in the intercellular stroma. As the activity of the lesions decreases they become progressively more fibrous, the number of giant cells diminishes, and varying amounts of metaplastic bone are laid down.

Key points – Cherubism

- family history
- distinct clinical features
- bilateral, symmetrical, multilocular radiolucencies
- one of the giant cell lesions of bone

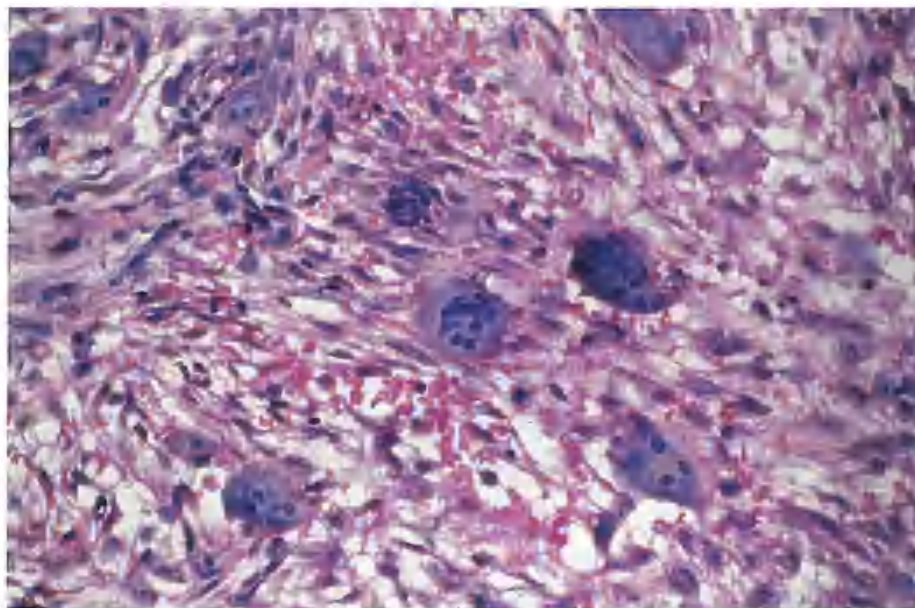


Fig. 16.17 Multinucleated giant cells in a vascular spindle cell stroma in cherubism.

As noted above, cherubism is a self-limiting condition and there is progressive improvement in facial appearance from about puberty onwards, but conservative cosmetic surgery is often required. Radiographically, the improvement in appearance may be accompanied by some bony infilling of the lesions but residual radiolucent areas can remain into old age.

Healing of bone

Healing of an extraction socket

Following extraction of a tooth, the socket rapidly fills with extravasated blood which then clots. The blood clot is organized to form granulation tissue which consists of proliferating fibroblasts and endothelial cells derived from remnants of the periodontal membrane, the surrounding alveolar bone, and the gingival mucosa. Osteoclastic resorption of the crestal bone and small spicules of bone detached during the extraction also commences at this time. Gingival epithelial migration and regeneration occur across the defect, the epithelium migrating between the blood clot and the proliferating granulation tissue (Fig. 16.18). Epithelial continuity is restored 10–14 days after the extraction, the epithelium at first being thin with an irregular surface. Osteoblasts usually first appear in the granulation tissue towards the base of the socket and the granulation tissue is gradually replaced by woven bone (Fig. 16.19). After approximately 6 weeks the regenerated epithelium over the socket appears normal, the supra-alveolar connective tissues have healed by repair, and the socket is filled with woven bone. However, the outline of the socket can still be discerned both histologically and radiologically (Fig. 16.20). Subsequently, this woven bone is remodelled with the formation of cortical and cancellous bone and disappearance of the lamina dura. Remodelling also includes a reduction in the height of the alveolar

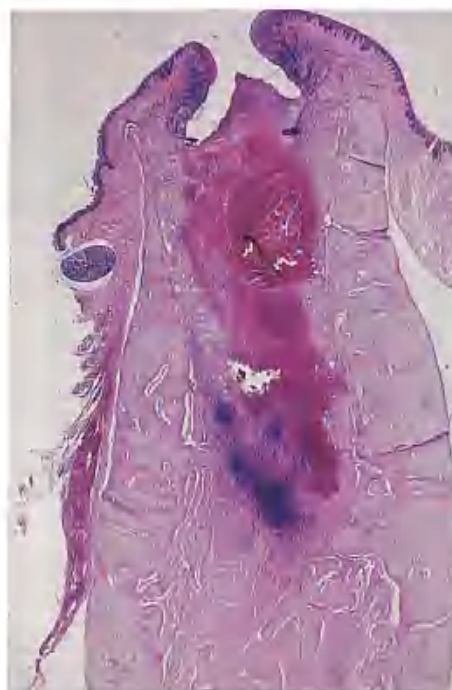


Fig. 16.18 Healing socket 7 days after extraction.

bone in the area of the extraction. Radiographically, the socket is generally obliterated between 20 and 30 weeks after the extraction.

Osseointegrated implants

Osseointegration is the term used to describe the healing of bone around an endosseous implant which results in an intimate interface between the bone and the implant. The healing process is essentially similar to that seen in a healing socket and involves

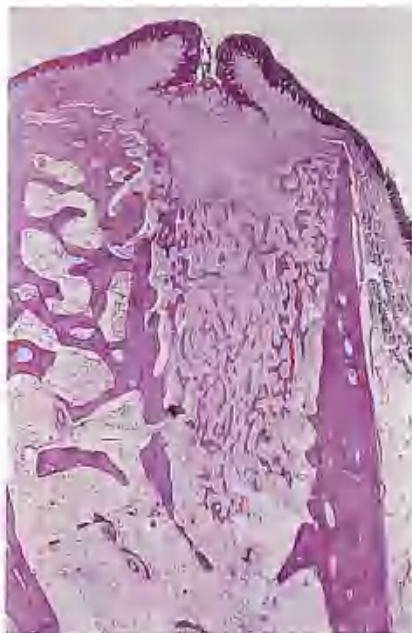

Fig. 16.19 Healing socket 4 weeks after extraction. The surface is epithelialized and the socket contains multiple trabeculae of actively forming woven bone.

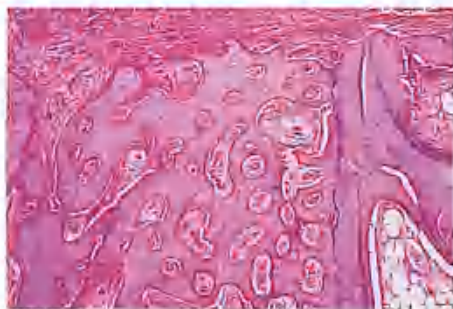


Fig. 16.20 Healing socket 6 weeks after extraction. The socket is filled with woven bone; the wall of the socket is visible on the right of the figure.

osteogenesis and bone remodelling. A healing period of several months is required, during which no load should be applied to the implant if an intimate interface is to be established. Repeated small amounts of movement of the implant are likely to interfere with formation of the interface and result in a zone of fibrous tissue being interposed between the implant and the bone. Ultrastructural studies have shown that in successful osseointegration the bone is separated from the implant only by an interfacial matrix zone, up to about 100 nm thick. This probably corresponds to the cement lines seen in normal bone.

Osseointegrated implants penetrate the alveolar mucosa, and the interface between the implant and the soft tissues serves a similar barrier function to the dentogingival tissues around a tooth. In a successful implant, the alveolar connective tissue is in

intimate contact with the implant post. Dense bundles of collagen fibres run predominantly parallel to the long axis of the implant. The gingival epithelium is arranged as a collar around the implant post, and is attached to the implant surface by a basal lamina and hemidesmosomes similar to that seen in normal junctional epithelium. The epithelium does not migrate apically along the post surface.

Plaque accumulation can lead both to inflammatory changes around the implant and to alveolar bone loss similar to that seen in chronic periodontal disease, especially if there is excessive implant load. Microbiological examination of plaque associated with implants shows a similar range of organisms to that found in plaque associated with chronic periodontal disease.

Inflammatory diseases of bone

Inflammatory diseases of bone can be divided into three broad but overlapping categories depending largely on the extent of involvement of the bone. The term 'osteitis' is generally used to describe a localized inflammation of bone with no progression through the marrow spaces, particularly that associated with infected sockets following removal of teeth (dry socket, see later). Osteomyelitis is a more extensive inflammation of the interior of the bone involving, and typically spreading through, the marrow spaces. Periostitis means inflammation of the periosteal surface of the bone and may or may not be associated with osteomyelitis.

Alveolar osteitis (dry socket)

This unpredictable complication in the healing of extraction wounds follows between 1 and 3 per cent of all extractions. It occurs most commonly following the extraction of a molar, particularly a lower molar, the incidence then decreasing when premolar and incisor teeth are extracted. It also occurs more commonly with difficult extractions, and the highest incidence of dry socket follows the extraction of impacted lower third molars. Tobacco use by the patient has also been identified as a risk factor.

A dry socket is a localized inflammation of the bone following either the failure of a blood clot to form in the socket, or the premature loss or disintegration of the clot. Failure of a clot to form may be due to a relatively poor blood supply to the bone such as that found in osteopetrosis, Paget's disease of bone, or following radiotherapy, or it might result from the excessive use of vasoconstrictors

Key points – Alveolar osteitis

- occurs mainly in the mandible
- incidence after surgical removal of impacted third molars up to 20–30 per cent
- loss of protection by blood clot
 - failure to form clot
 - dislodgement of clot
 - breakdown of clot

in local anaesthetics. In cases where an adequate blood clot forms, the latter may be washed away by excessive mouth rinsing, or may disintegrate prematurely due to fibrinolysis of the clot most likely as a result of infection by proteolytic bacteria. No specific bacteria have been implicated, the infection being of mixed type.

Food debris, saliva, and bacteria collect in the empty socket, the bone of which becomes infected and necrotic. The inflammatory reaction in the adjacent marrow localizes the infection to the walls of the socket, as otherwise osteomyelitis would ensue. The dead bone is gradually separated by osteoclasts and a number of tiny sequestra may be formed. Healing is extremely slow and follows the proliferation of granulation tissue from the surrounding vital bone.

A dry socket is associated with severe pain developing a few days after the extraction. The socket often contains foul tasting and smelling decomposing food debris which can be washed away to reveal the denuded bone lining the cavity.

Focal sclerosing (condensing) osteitis

As discussed in Chapter 5, osteosclerosis is one of the sequelae of periapical inflammation and may result from low-grade irritation and/or high tissue resistance. It is generally seen at the apex of a tooth, most commonly the first permanent molar (see Fig. 5.9), and may remain as a sclerotic area of bone following extraction. It is usually asymptomatic. Histologically, a localized increase in the number and thickness of the bone trabeculae is seen and there may be scattered lymphocytes and plasma cells in the surrounding scanty fibrosed marrow.

Osteomyelitis

Although osteomyelitis of the jaws was a common complication of dental sepsis before the advent of antibiotics, it is now a rare disease. Various clinical subtypes may be recognized, but the pathological features of osteomyelitis are best considered as comprising a spectrum of inflammatory and reactive changes in bone and periosteum. These reflect the balance between the nature and severity of the irritant, the host defences, and local and systemic

predisposing factors. The latter are listed in Table 16.2 and relate mainly to local factors which compromise the vascularity and vitality of bone and to systemic conditions that compromise the defence systems of the host. Nevertheless, it is usual to distinguish between suppurative and sclerotic forms of osteomyelitis.

Suppurative osteomyelitis

Suppurative osteomyelitis is usually divided clinically into acute and chronic types depending on the severity of symptoms and on the course of the disease over time. Disease persisting for longer than a month is usually referred to as chronic suppurative osteomyelitis.

The source of the infection is usually an adjacent focus of infection associated with teeth (for example a dental abscess) or with local trauma (for example fractures, penetrating wounds, and extractions). A wide range of organisms may be involved and osteomyelitis of the jaws is usually a polymicrobial infection. Anaerobic organisms predominate. The mandible is much more frequently involved than the maxilla because the vascular supply is readily compromised. Thrombosis of the mandibular artery or of its branching loops can lead to extensive necrosis of bone. In contrast, there is a rich collateral circulation in the mid-face area and osteomyelitis of the maxilla is rare.

Following entry into the bone the organisms proliferate in the marrow spaces giving rise to an acute inflammatory reaction. Tissue necrosis and suppuration rapidly ensue and the necrosis may be widespread because of thrombosis of neighbouring vessels. Inflammation, suppuration, and necrosis continue and the marrow spaces become filled with pus. The suppurative inflammation tends to spread through the adjacent marrow spaces and may extend through the cortical bone to involve the periosteum. Stripping of the periosteum compromises the blood supply to the cortical plate and predisposes to further bone necrosis. Eventually a mass of necrotic bone (a sequestrum) which is bathed in pus becomes separated by osteoclastic activity from the surrounding vital bone (Fig. 16.21). The sequestrum may be spontaneously exfoliated through a sinus or have to be surgically removed before healing can take place. Radiographic examination may be normal in the early stages of the disease, but after 10–14 days sufficient bone resorption may have occurred to produce irregular, moth-eaten areas of radiolucency (Fig. 16.22).

Table 16.2 Factors predisposing to osteomyelitis of the jaws

<i>Local factors</i>	
Decreased vascularity/vitality of bone	
–	trauma
–	radiation injury
–	Paget's disease
–	osteopetrosis
–	major vessel disease
<i>Systemic factors</i>	
Impaired host defence	
–	immune deficiency states
–	immunosuppression
–	diabetes mellitus
–	malnutrition
–	extremes of age



Fig. 16.21 Acute osteomyelitis showing osteoclastic resorption of necrotic bone and surrounding suppurative inflammation.



Fig. 16.22 Extensive destruction and moth-eaten appearance of bone in acute osteomyelitis of the mandible.

Clinically, acute suppurative osteomyelitis presents with pain, swelling, pyrexia, and malaise. Trismus is frequent and there may be paraesthesia of the lip and mobility of teeth if they are involved. Disease of more chronic nature also presents with swelling and pain associated with chronic suppuration and discharge of pus through one or more intraoral or extraoral sinuses.

Sclerosing osteomyelitis

Chronic sclerosing osteomyelitis is a controversial condition whose existence has been questioned. Localized lesions are identical to focal sclerosing osteitis and some previously reported diffuse types are probably examples of infected cemento-osseous dysplasia. However, diffuse sclerosing lesions of the mandible have occasionally been reported as a complication of spread from a periapical granuloma or pulse granuloma (see later).

So-called Garré's osteomyelitis is a distinct clinicopathological entity characterized by a proliferative subperiosteal reaction rather than inflammation of the interior of the bone. It is essentially a periostitis rather than osteomyelitis and is considered separately below.

Chronic osteomyelitis with proliferative periostitis (Garré's osteomyelitis, periostitis ossificans)

This type of sclerosing osteomyelitis is seen almost exclusively in the mandible in children and young adults. As discussed above, it is essentially a periosteal osteosclerosis presenting clinically as a bony hard swelling on the outer surface of the mandible. The periosteal reaction is thought to result from the spread of a low-grade, chronic apical inflammation through the cortical bone,

stimulating a proliferative reaction of the periosteum. Occlusal radiographs show a focal subperiosteal overgrowth of bone with a smooth surface on the outer cortical plate. The subperiosteal mass consists of irregular trabeculae of actively forming woven bone with scattered chronic inflammatory cells in the fibrous marrow.

Chronic periostitis associated with hyaline bodies (pulse granuloma, vegetable granuloma)

An unusual form of chronic periostitis in the jaws is associated histologically with hyaline ring-shaped bodies accompanied by a foreign-body, giant-cell reaction (Fig. 16.23). The nature and origin of these bodies is still debated, but there is now considerable evidence that they represent, at least in part, vegetable material, especially pulses, that has been implanted in the tissues. The type of inflammatory reaction is variable. In most cases it is associated with fibrous thickening of the periosteum, a proliferative periostitis, but in others there is chronic suppuration.

The vegetable material could gain access to the tissues via a tooth socket (when it may also cause delayed healing), a surgical flap, open root canal, or through some other breach in the mucosa, such as traumatic ulceration associated with ill-fitting dentures. Similar hyaline bodies are occasionally seen in association with apical granulomas and the capsules of odontogenic cysts following impaction of food debris down a root canal.

Radiation injury and osteoradionecrosis

Radiation, as part of the therapy of oral malignancy, affects the vascularity of the bone by causing a proliferation of the intima of the blood vessels (endarteritis obliterans). This can have serious consequences in the mandible with its end-artery supply, and the inferior dental artery or its branches may become thrombosed. The non-vital bone which results from the reduction in blood

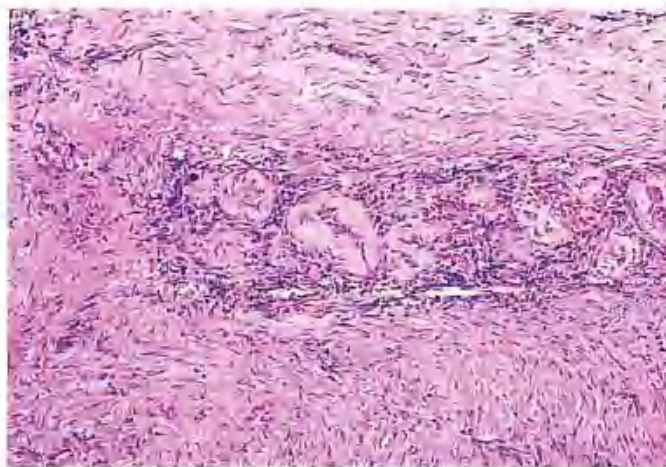


Fig. 16.23 Chronic periostitis associated with hyaline bodies showing chronic inflammation and fibrosis. The hyaline ring or doughnut-shaped bodies are probably of vegetable origin.

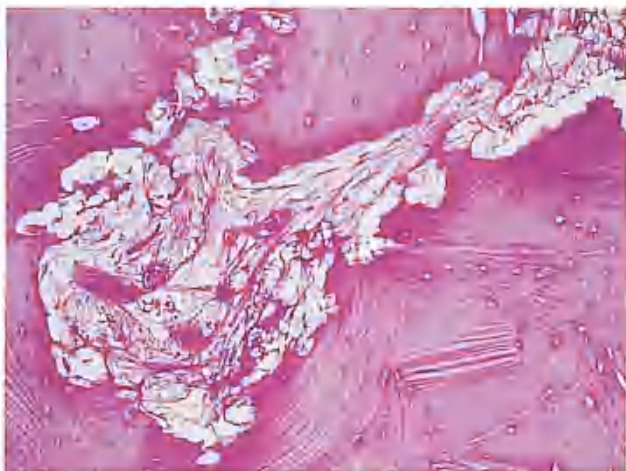


Fig. 16.24 Partly resorbed osteoradionecrotic mandibular bone.

supply is sterile and asymptomatic (Fig. 16.24) but is very susceptible to infection and to trauma from a denture. Infection may spread rapidly through the irradiated bone, resulting in extensive osteomyelitis and painful necrosis of the bone, often associated with sloughing of the overlying oral and occasionally facial soft tissues. Modern methods of radiotherapy have greatly reduced the incidence of this condition.

Metabolic and endocrine disorders of bone

The normal process of osteogenesis may be affected by a variety of metabolic diseases or unknown factors as in idiopathic osteoporosis. An inadequate supply of bone salts such as in vitamin D deficiency (rickets) may affect the normal process of calcification. Homeostasis of calcium and phosphate metabolism is affected by the activity of the parathyroid glands, disturbances of which are associated with changes in bone.

Osteoporosis

Bone is in a state of constant turnover and in adult life bone loss gradually predominates over bone apposition. Osteoporosis results either when the bone loss is excessive or when the apposition of bone is reduced. A variety of risk factors have been identified, but the disease presents most commonly in postmenopausal women. The rate of loss of bone mineral is variable but in most postmenopausal women is about 1–2 per cent per year. In about a quarter of cases more rapid loss, up to 5–8 per cent per year, may occur. The rate of loss is about twice as fast in women as in men. Osteoporosis is also accentuated in several other diseases, particularly Cushing syndrome, thyrotoxicosis, and primary hyperparathyroidism.

Osteoporotic bone is of normal composition but it is reduced in quantity. There is an increased radiolucency of bone, the cortex is thinned, and there are more marrow spaces in the cancellous bone associated with thin trabeculae.

The jaws may be involved. Osteoporosis occurring in edentulous patients may result in the mandible being reduced to a thin fragile strip of bone. It has been suggested that osteoporosis is a risk factor in chronic periodontal disease, but there is little supporting evidence.

Primary hyperparathyroidism

This relatively common disease is seen predominantly in middle-aged women and results from excessive parathormone secretion, usually from an adenoma but occasionally from carcinoma or idiopathic hyperplasia of a parathyroid gland. The effects of parathormone include stimulation of intestinal absorption of calcium, reabsorption of calcium by the renal tubules, and bone resorption by osteoclasts. Thus, excess secretion of the hormone results in hypercalcaemia and hypercalciuria. Pathological metastatic calcification may occur, commonly as urinary calculi but also in blood vessel walls and lungs.

Histologically, osteoclastic activity is increased throughout the skeleton. On occasions, focal areas of bone resorption result in the formation of lesions called brown tumours which consist of large numbers of multinucleate, osteoclast-like giant cells scattered in a highly cellular, vascular fibroblastic connective tissue stroma. There is much haemosiderin pigment present, hence the brown colour of these lesions seen macroscopically (Figs 16.25, 16.26). Histologically, it is impossible to distinguish a brown tumour of hyperparathyroidism from other giant cell lesions of bone. Very rarely a focal collection of osteoclasts (brown tumour) may occur in relation to the periosteum and be indistinguishable from a peripheral giant cell granuloma (giant cell epulis, see Chapter 8). The possibility of hyperparathyroidism should be considered in patients with recurrent or multiple giant cell epulides.

Radiographic examination may show no detectable changes or a generalized osteoporosis. Partial loss of the lamina dura around the teeth may occur but it is not a constant feature. If focal lesions (brown tumours) develop, they present as sharply defined, round

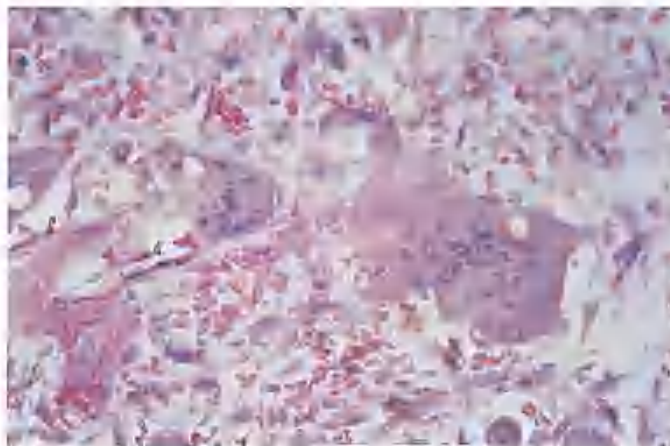


Fig. 16.25 Brown tumour of hyperparathyroidism showing multinucleated, osteoclast-like giant cells.

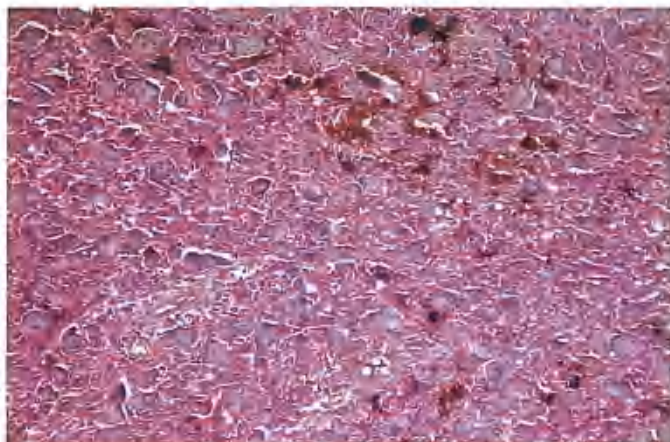


Fig. 16.26 Brown tumour of hyperparathyroidism showing deposits of haemosiderin (brown).

or oval radiolucent areas which may appear multilocular. Such lesions occur more frequently in the mandible than in the maxilla.

Secondary hyperparathyroidism

Secondary hyperparathyroidism occurs in response to chronic hypocalcaemia, most frequently as a result of chronic renal failure but also in association with rickets and osteomalacia. The bone changes are complex and are a mixture of those associated with osteomalacia (see below) and hyperparathyroidism. Involvement of the jaws has been reported.

Rickets and osteomalacia

Classically, rickets and its adult counterpart osteomalacia are due to deficiency of, or resistance to the action of, vitamin D. Deficiency may be due to lack of exposure to sunlight or dietary causes. In the UK, dietary deficiency is seen mainly among the Asian immigrant population. In addition, the high cereal content of their diet and the use of wholemeal grains containing phytates impairs calcium absorption. Other causes of hypocalcaemia, such as renal failure or malabsorption, may also be associated with osteomalacia.

The radiographic changes are similar to those seen in osteoporosis, but in contrast to the latter, where the bone present is normally mineralized, in rickets and osteomalacia there is a failure of mineralization of osteoid and of cartilage. Histologically, the

Key points – Metabolic bone disease

- osteoporosis may be associated with enhanced atrophy of the mandible
- hyperparathyroidism may present as a central giant cell lesion of the jaws
- rickets is associated with dental abnormalities

bony trabeculae in rickets and osteomalacia are characterized by wide seams of uncalcified osteoid.

Dental abnormalities in rickets include enamel hypoplasia, increased width of the preentine, and large amounts of interglobular dentine similar to the changes seen in vitamin D-resistant rickets – hypophosphataemia (see Chapter 1).

Acromegaly

This disease is caused by prolonged and excessive secretion of growth hormone, usually due to a secreting adenoma of the anterior lobe of the pituitary developing after the epiphyses have closed. There is renewed growth of the bones of the jaws, hands, and feet with overgrowth of some soft tissues. Activation of the condylar growth centre of the mandible causes the jaw to become enlarged and protrusive and if teeth are present they become spaced. The soft tissues of the face, particularly the lips and nose, become thickened and enlarged (Figs 16.27, 16.28).

Paget's disease of bone

Paget's disease of bone is a form of osteodystrophy characterized by disorganized formation and remodelling of bone, unrelated to functional requirements. The aetiology of the disease remains unclear, but it is thought to be due to a primary dysfunction of osteoclasts. Several studies have suggested that infection with paramyxoviruses, such as measles or respiratory syncytial virus, is implicated. Following childhood infection the virus may remain latent in osteoclast progenitor cells. Various other factors, including genetic predisposition, may then be involved before the

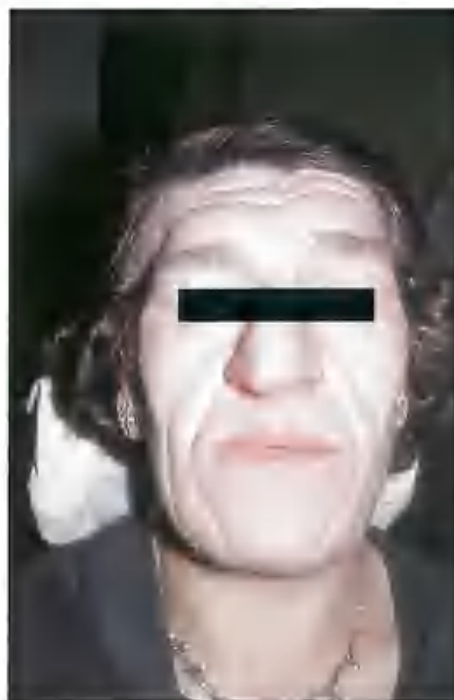

Fig. 16.27 Acromegaly showing coarsening of facial features.

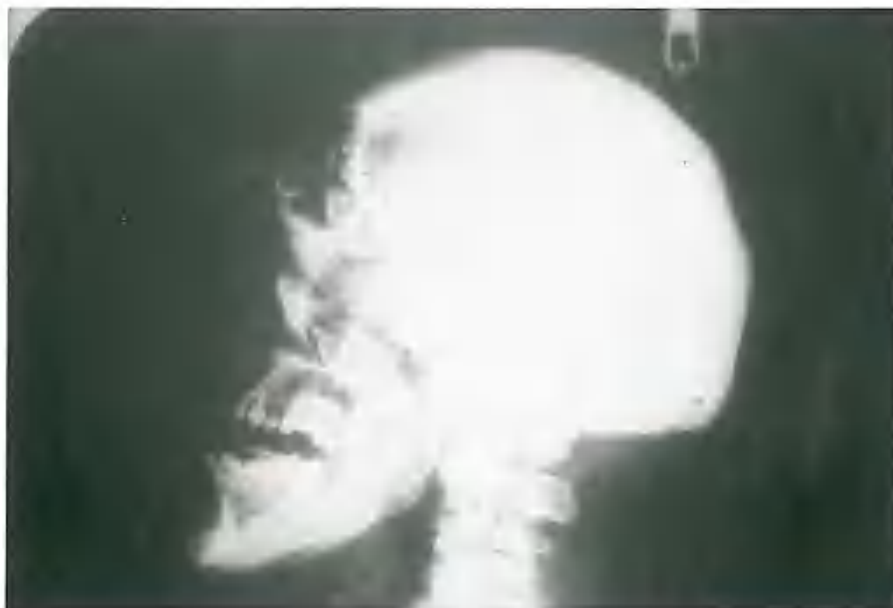

Fig. 16.28 Mandibular prognathism associated with acromegaly.

disease manifests in adult life. A familial pattern strongly suggests an hereditary component, and a genetic locus which predisposes to Paget's disease has been identified on chromosome 18q.

The natural history of the disease can be divided into three progressive and overlapping phases:

- (1) an initial predominantly osteolytic phase;
- (2) an active stage of mixed osteolysis and osteogenesis;
- (3) a predominantly osteoblastic or sclerotic phase.

In the first two phases the bones become softened and distorted and their overall size may be markedly increased. In the sclerotic phase, the distorted bones become fixed in their deformed state.

Clinical and radiographic features

Paget's disease occurs predominantly in patients over 40 years of age. Subclinical disease is not uncommon and radiological surveys and autopsy studies have demonstrated an incidence of about 3 per cent in all persons over 40 years of age. However, there are differences in geographical incidence; it is rare in Russia, Asia, and parts of Europe compared to the United Kingdom, Australasia, and North America, although the incidence is decreasing. The lesions may involve a single or small number of bones or, less commonly, may be disseminated widely throughout the skeleton. They are commonest in the weight-bearing bones of the axial skeleton, particularly the sacrum, followed by lumbar, thoracic, and cervical vertebrae. The skull and femur are the next most frequent sites. Jaw lesions are more common in the maxilla than mandible and although monostotic lesions have been reported, when the jaws are involved the skull is almost invariably affected.

Clinically, patients with Paget's disease show varying degrees of bony deformity and distortion of the weight-bearing portions

of the skeleton and of the skull and facial bones. However, most cases are mild, and the disease may be discovered incidentally on radiographs, or the patient may complain of bone pain. When the skull is involved patients may also present with signs and symptoms of sensory or motor disturbances related to cranial nerve compression. With progressive enlargement of the maxilla, the alveolar ridge becomes thickened and widened, the palate flattened (Fig. 16.29), and there is increasing facial deformity. The bony enlargement may lead to incompetence of the lips. In dentate patients, derangement of the occlusion, spacing of the teeth, and retroclination of incisors and palatoversion of posterior teeth may be striking. Edentulous patients may complain of difficulties in wearing dentures and the need to have these remade periodically as the jaws increase in size. Other important oral manifestations are related to involvement of the teeth which often show hypercementosis and may become ankylosed, leading to difficulty in extraction. Root resorption may also occur in the osteolytic phase. In the active stages of the disease, postextraction haemorrhage may be a problem because of the highly vascular marrow which contains extensive arteriovenous communications.

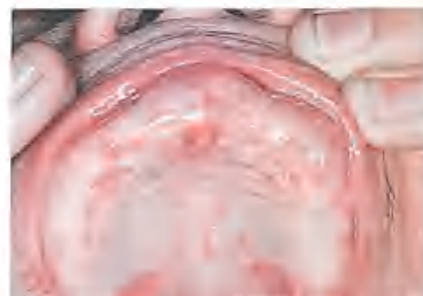


Fig. 16.29 Enlargement of the maxilla in Paget's disease of bone.



Fig. 16.30 Cotton-wool appearance of bone in Paget's disease.



Fig. 16.31 Paget's disease of the skull showing thickening of the calvarium, with loss of distinction between the tables and the diploe, and maxillary lesions.

Key points – Paget's disease of bone – clinical

- aetiology involves genetic and environmental factors, particularly paramyxovirus infection
- presents in patients over 40 years of age
- may be symptomless and an incidental radiographic finding
- may cause bone pain and varying degrees of bony deformity
- jaw lesions more common in maxilla
- tooth extraction complicated by hypercementosis, ankylosis, bone sclerosis

In contrast, in the later sclerotic phase the bone is relatively dense and avascular and extraction sockets are prone to infection.

The radiographic features are variable but reflect the different stages of the disease. Osteoporosis is the earliest change, followed by patchy osteosclerosis and the appearance of ill-defined and irregular radiopaque areas producing a characteristic cotton-wool appearance (Fig. 16.30). In the skull, thickening of the outer table of the vault and loss of distinction between the tables and

diploe are also typical features (Fig. 16.31). In the jaws, loss of the lamina dura, hypercementosis, and ankylosis may be noted.

Pathology

The microscopic features of Paget's disease reflect the disorganized bone remodelling which is a feature of the disease, and the lesions show combinations of osteoclastic and osteoblastic activity unrelated to normal function. During the early osteoporotic phase, osteoclastic resorption predominates. The resorbed areas are filled by cellular and vascular fibrous marrow within which new bone forms and this in turn is remodelled and replaced by further new bone. This disorganized remodelling activity is repeated and in fully developed active lesions there is simultaneous osteoclastic and osteoblastic activity involving most of the trabeculae (Fig. 16.32). As a result of the remodelling activity the bone trabeculae show numerous criss-crossing, resting, and scalloped reversal lines which stain deeply with haematoxylin. These criss-crossing lines give the bone a characteristic mosaic appearance (Fig. 16.33). Reversal lines indicate junctions where there has been reversal of osteoclastic resorption to osteoblastic deposition. Their scalloped outlines represent the margins of the previously existing Howship's lacunae. As more and more bone is formed within the lesion, the disjointed trabeculae fuse to form dense sclerotic masses of mosaic bone. As the disease becomes less active so the marrow becomes less vascular, and osteoclastic and osteoblastic activity is decreased. In the jaws, the new bone may be in the form of acellular globular deposits which enlarge and fuse to form dense sclerotic masses (Fig. 16.34). The cementum

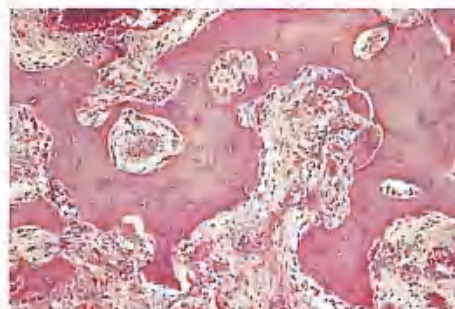


Fig. 16.32 Disorganized remodelling of bone in Paget's disease with simultaneous osteoclastic and osteoblastic activity.

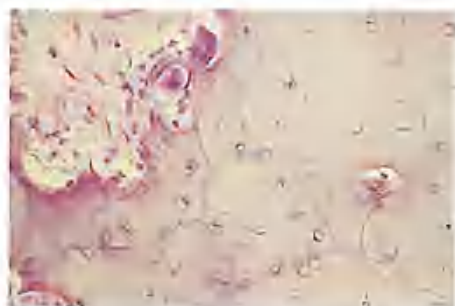

Fig. 16.33 Mosaic appearance of bone in Paget's disease.

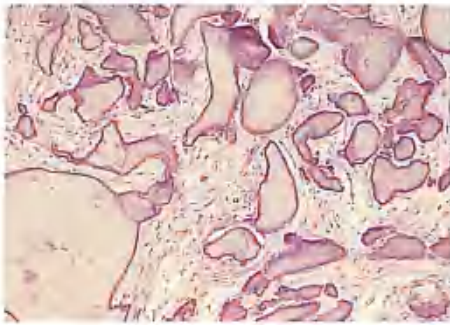


Fig. 16.34 Acellular globular masses of cementum-like tissue in Paget's disease of the jaws.

Key points – Paget's disease of bone – pathology

- osteolytic, mixed, and osteosclerotic phases
- disorganized remodelling of bone
- criss-crossing reversal lines; mosaic bone
- radiographic appearances reflect the main phases; osteoporotic progressing to osteosclerotic

may also undergo disorganized remodelling, resulting in hypercementosis, and may fuse with the disorganized remodelling alveolar bone leading to ankylosis (Fig. 16.35).

Osteosarcoma and other bone tumours are rare complications that can arise, mainly in patients with widespread disease.

Investigation of the blood chemistry is important in the diagnosis of Paget's disease. The serum calcium and serum phosphorus levels are usually within normal limits but the serum alkaline phosphatase level is often raised, sometimes markedly so in patients with widespread active disease.

Central giant cell granuloma

This condition may occur at any age but presents most frequently in the second and third decades. There is a female predominance. It involves the mandible more frequently than the maxilla and most arise in the anterior part of the jaws. The lesion usually presents clinically as a swelling of the bone, and growth may some-

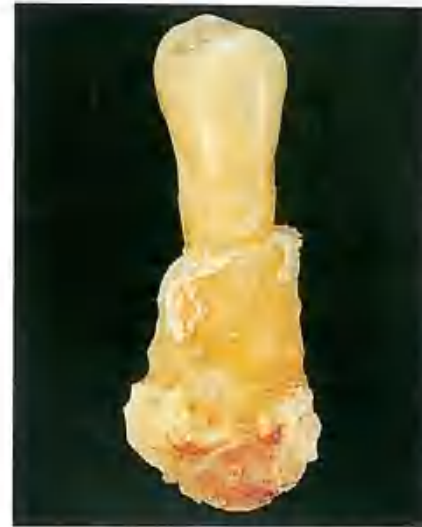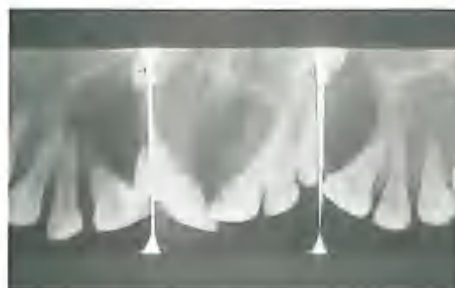

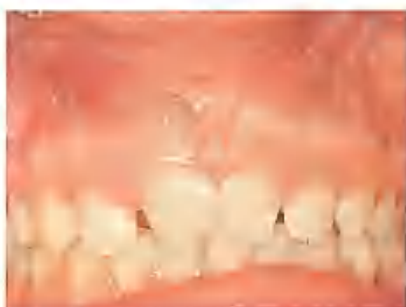
Fig. 16.35 Hypercementosis with ankylosis to alveolar bone in Paget's disease of the jaws.

times be rapid. Some cases are symptomless and are first detected on routine radiological examination. Radiographically, the lesion appears as a well-defined radiolucent area with thinning, expansion, and, occasionally, perforation of the cortex. Some are characteristically multilocular but the appearances are not specific and cannot be distinguished from other causes of multilocular radiolucent areas. Involved teeth may be displaced and their roots may show resorption (Figs 16.36, 16.37).

Histological examination shows large numbers of multinucleate, osteoclast-like giant cells lying in a vascular stroma which is rich in small, spindle-shaped cells (Fig. 16.38). The giant cells may be arranged in focal aggregates or be scattered throughout the lesion, although they are often related to vascular channels. The spindle cell component probably consists predominantly of mononuclear precursors of the giant cells, but includes fibroblasts and endothelial cells. Foci of extravasated erythrocytes and granules of haemosiderin pigment are common in the stroma. The lesion may also contain a few trabeculae of osteoid or bone (Fig. 16.39).

Central giant cell granuloma is a condition of unknown aetiology. It has been suggested that it could be a reaction to some form of haemodynamic disturbance in bone marrow perhaps



Figs 16.36, 16.37 Central giant cell granuloma presenting with displacement of the central incisors associated with well-defined radiolucent lesion.

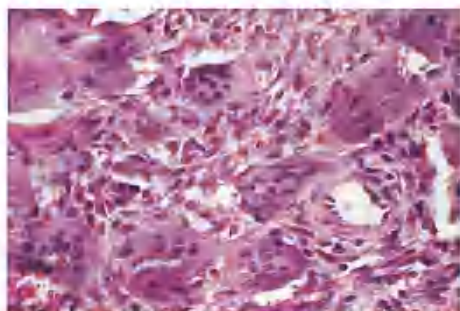


Fig. 16.38 Central giant cell granuloma showing collections of multinucleated osteoclast-like giant cells in a vascular spindle cell stroma.

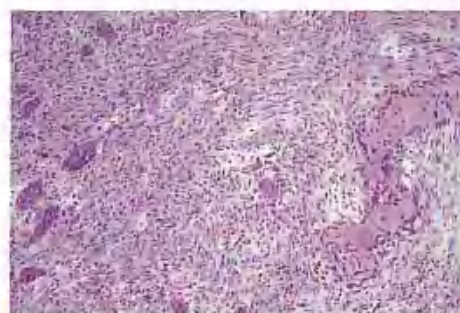


Fig. 16.39 Trabeculae of newly forming bone in a central giant cell granuloma.

Key points – Central giant cell granuloma

- most patients less than 30 years of age
- more common in the mandible than maxilla
- most lesions arise in the interpremolar region
- histologically indistinguishable from other giant cell lesions of bone
- hyperparathyroidism needs to be excluded

associated with trauma and haemorrhage. The majority respond well to simple enucleation and curettage, but some pursue a more aggressive course and have a tendency to recur. In such cases some authors have reported the lesions as giant cell tumour of bone, a tumour which occurs elsewhere in the skeleton. However, there is controversy as to whether or not true giant cell tumour occurs in the jaws and the term is best avoided. The central giant cell granuloma is impossible to distinguish histologically from a focal lesion of hyperparathyroidism which must be excluded by biochemical investigations.

Torus palatinus, torus mandibularis, and other exostoses

The term 'exostosis' is used clinically to describe a variety of bony outgrowths. It implies a non-neoplastic lesion that may be of

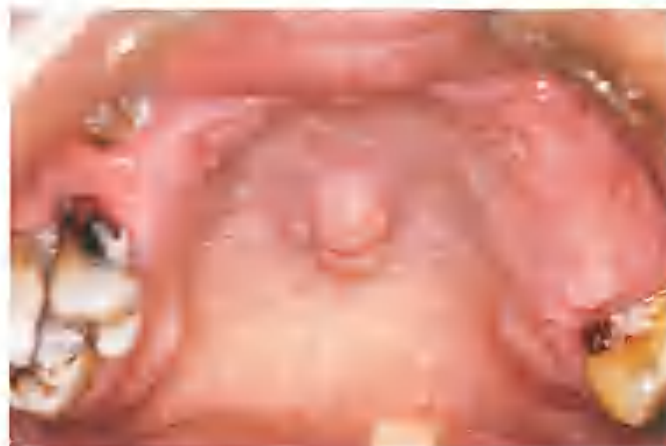

Fig. 16.40 Torus palatinus.

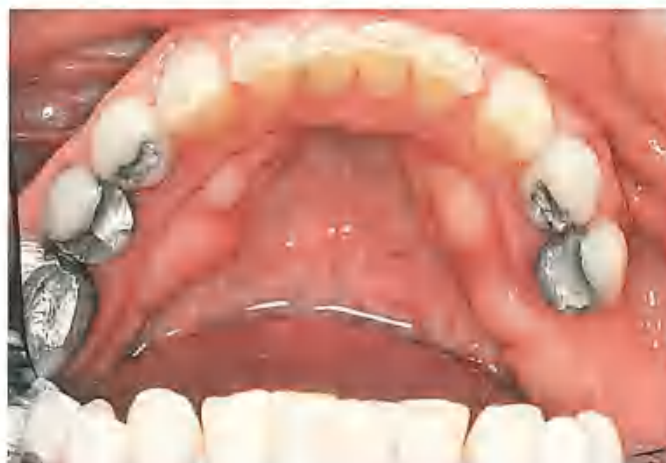

Fig. 16.41 Torus mandibularis.

developmental origin or that may have arisen in response to a stimulus such as a chronic trauma (a reactive exostosis) or following surgery, for example after a free gingival graft.

A torus is an exostosis which occurs at a characteristic site, either in the midline of the palate (torus palatinus) (Fig. 16.40) or on the lingual surface of the mandible, usually in the premolar region above the mylohyoid line (torus mandibularis) (Fig. 16.41). Mandibular tori are frequently bilateral. Palatal tori are more common than mandibular tori. Their aetiology is unknown and the two conditions do not appear to be related except for evidence suggesting hereditary factors, an autosomal dominant pattern of inheritance being reported in some patients.

Tori are rarely seen in childhood and have a slow growth. They may vary considerably in size and shape, ranging from flat and small elevations to large, nodular growths. They may be composed entirely of dense, cortical bone or consist of cancellous bone with a shell of cortical bone. The lesions are entirely benign and need to be removed only for cosmetic reasons or before the construction of a denture.

Exostoses are seen occasionally in other parts of the jaw and may be multiple and symmetrical particularly on the buccal

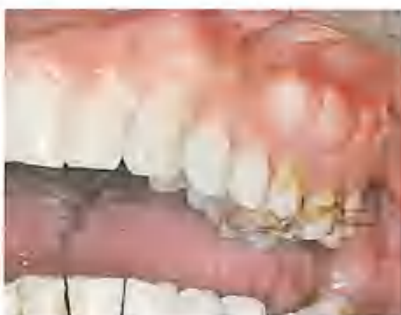

Fig. 16.42 Multiple exostoses of the maxilla.

alveolus in the molar region of the maxilla (Fig. 16.42). Irregularities of the alveolus following tooth extraction are also often described clinically as exostoses, as is enlargement of the genial tubercle in edentulous patients. The distinction between an exostosis and an osteoma is often difficult to determine.

Dense bone island

A dense bone island is a localized area of sclerotic bone, also referred to as idiopathic osteosclerosis. It is usually symptomless and discovered as a chance finding on a radiograph.

Dense bone islands occur predominantly in the premolar-molar region of the mandible and most are detected in the third and fourth decades of life. Radiographically, they are well-defined, dense, sclerotic areas, not surrounded by a radiolucent space. They may be separated from or associated with a root apex (Fig. 16.43). Their aetiology is unknown and they are of no clinical significance, except for the need to distinguish them from other sclerotic masses such as those occurring as a consequence of periapical inflammation (see Chapter 5) or as cemento-osseous dysplasia.

Tumours of bone

Primary tumours of bone are uncommon lesions in the jaws. They may arise from any of the number of different cells and tissues present in bone, including cartilage, marrow, vascular, and fibrous tissues. Their classification is complex, and while many lesions are recognized not all have been recorded in the jaws. The abridged classification used in this chapter is given in Table 16.3. It is based on that recommended by the World Health Organization,



Fig. 16.43 Idiopathic dense bone island.

Table 16.3 Classification of tumours of bone

<i>Bone-forming tumours</i>	
(a) Benign:	osteoma osteoblastoma
(b) Malignant:	osteosarcoma
<i>Cartilage-forming tumours</i>	
(a) Benign:	chondroma
(b) Malignant:	chondrosarcoma
<i>Marrow tumours</i>	
(a) Myeloma	
(b) Other types	
<i>Fibrous tumours</i>	
Benign:	ossifying (cemento-ossifying) fibroma
<i>Tumour-like lesions in bone</i>	
(a) Langerhans cell histiocytosis	
(b) Haemangioma of bone	
<i>Metastatic tumours</i>	

which seeks to define the tumours in terms of the type of differentiation of the tumour cells and especially the differentiation of the intercellular material (if any) formed by them. For convenience, the Langerhans cell histiocytosis group has been included in the classification since destructive lesions in the jaws are a feature of these disorders.

Osteoma and osteoblastoma

An osteoma is a benign, slow-growing tumour consisting of well-differentiated mature bone. It may arise as a central or subperiosteal lesion and is more frequent in the mandible than maxilla. The majority of tumours are diagnosed in adult life. Differentiation of a subperiosteal osteoma from a reactive exostosis and of a central lesion from some examples of a dense bone island is difficult, but persistent slow growth and radiographic evidence of a clearly circumscribed lesion suggest a benign neoplasm (Figs 16.44, 16.45, 16.46). Histologically, osteomas can be divided into compact (or ivory) and cancellous types. The compact osteoma (Fig. 16.47) consists of a mass of dense lamellar bone with few marrow spaces; the cancellous type is made up of interconnecting trabeculae enclosing fatty or fibrous marrow (Fig. 16.48).

Although usually solitary, multiple osteomas of the jaws occur as a feature of Gardner syndrome. The latter is a rare familial disorder transmitted as an autosomal dominant trait. Other

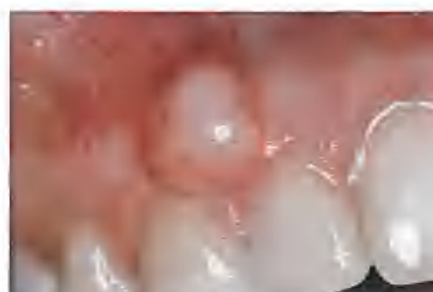
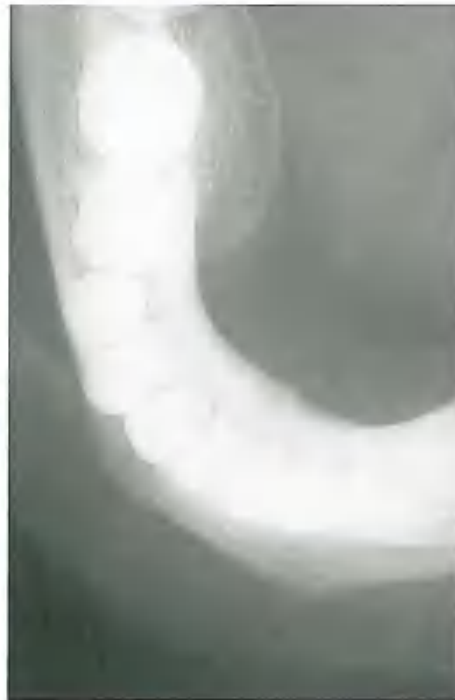
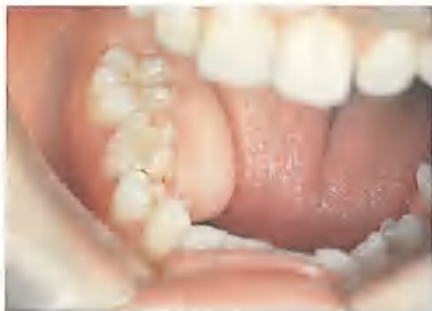Fig. 16.44 Osteoma of the maxilla.



Figs 16.45, 16.46 Clinical and radiographic appearance of a subperiosteal osteoma of the mandible.

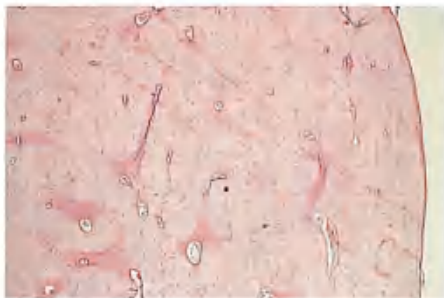


Fig. 16.47 Compact (ivory) osteoma.

components of the syndrome include polyposis coli, which shows a marked tendency to undergo malignant change, and multiple fibrous tumours and epidermal/sebacaceous cysts of the skin. Multiple impacted supernumerary and permanent teeth may be found.

Osteoblastoma is a rare tumour in the jaws. Histologically and radiographically it resembles the cementoblastoma (see Chapter 15), but it is not related to the roots of the teeth.

Osteosarcoma

Osteosarcoma is the commonest primary malignant tumour of bone but is relatively rare in the jaws. Most patients with jaw tumours are around 30 years of age at diagnosis and this is about a decade later than for osteosarcoma elsewhere in the skeleton. Occasionally, the tumour presents in older patients.

In the jaws the tumour usually presents with swelling, which may be accompanied by pain or paraesthesia, and radiographically it may appear as a radiolucent, radiopaque, or mixed lesion (Fig. 16.49).

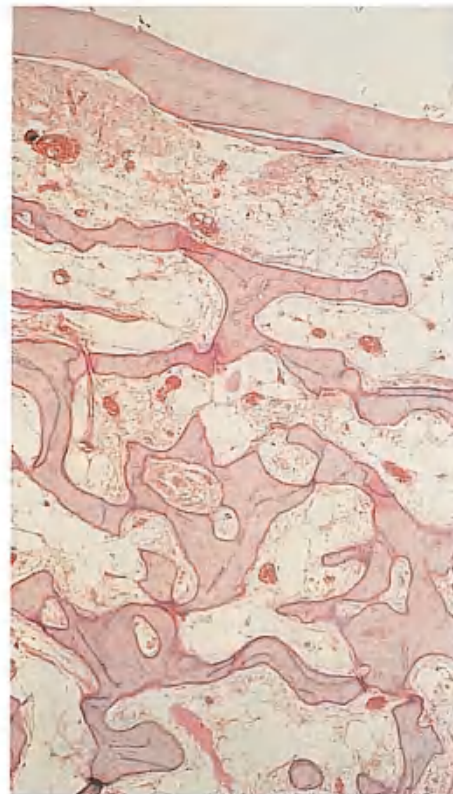


Fig. 16.48 Cancellous osteoma.

Histologically, several subtypes are recognized but they are all characterized by direct formation of abnormal osteoid or bone by malignant osteoblasts (Fig. 16.50). They may arise centrally within the jaws (intramedullary types) or peripherally, in relation




Fig. 16.49 Radiographic appearances of osteosarcoma of the mandible.

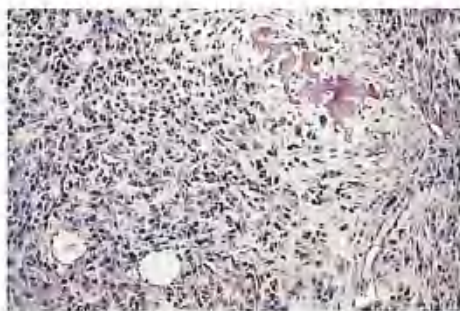


Fig. 16.50 Cytologically malignant cells associated with direct formation of malignant bone (top right) in osteosarcoma.

to the periosteum (juxtacortical types). Generally, the juxtacortical types have a better prognosis than the intramedullary types, although in the jaws some central osteosarcomas are low-grade tumours and histologically may be difficult to distinguish from benign lesions.

Chondroma and chondrosarcoma

Chondroma and chondrosarcoma are rare tumours in the jaws. The anterior part of the maxilla and posterior part of the mandible are the most common sites of occurrence, but mandibular tumours may also originate in the condylar processes.

Histologically, a chondroma is a benign tumour characterized by the formation of mature cartilage. However, the presence of a high degree of cellularity and of plump, often binucleate cells should alert suspicion that the tumour is a well-differentiated chondrosarcoma. Less well-differentiated chondrosarcomas may show obvious cytological features of malignancy (Fig. 16.51). Calcification and endochondral ossification may occur in both benign and malignant tumours and this is reflected in their variable radiographic appearances.

The prognosis for chondrosarcoma of the jaws is better for mandibular compared to maxillary lesions (reflecting the problems of achieving clearance by radical surgery) and for well-differentiated compared to poorly differentiated neoplasms.

Myeloma

Myeloma is a neoplasm composed of plasma cells and generally occurs as a disseminated disease involving many bones (multiple

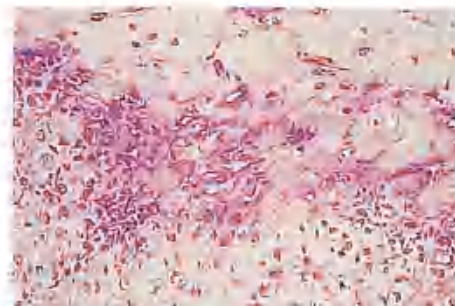


Fig. 16.51 Chondrosarcoma.

myeloma or myelomatosis). Less commonly the condition occurs as a solitary lesion within bone or, more rarely, soft tissue (solitary myeloma or plasmacytoma). Some, but not all, patients with solitary lesions eventually develop multiple myeloma.

Jaw lesions may occur as part of multiple myeloma or as a solitary lesion, and extramedullary plasmacytoma may also occur in the oral soft tissues, presenting as diffuse or polypoid swellings.

Multiple myeloma is the result of neoplastic proliferation of a single clone of immunoglobulin-producing cells and is characterized, therefore, by the production of large amounts of a single homogeneous type of immunoglobulin, most commonly IgG. Abnormally high levels of the homogeneous immunoglobulin and/or its constituent polypeptide chains appear in serum, and are termed paraproteins or 'M' components (in reference to myeloma).

Clinically, multiple myeloma occurs most frequently in patients between 50 and 70 years of age. Although any bone may be involved the skull, vertebrae, sternum, ribs, and pelvic bones are most commonly affected. These are sites where red marrow is normally present. Jaw lesions may be the initial manifestation of disease, but more commonly they are purely incidental to the overall picture. The classical radiographic feature is of sharply demarcated, round or oval osteolytic lesions with a characteristic punched-out appearance (Fig. 16.52).

Microscopically, the lesions are densely cellular and consist of sheets of myeloma cells which bear a striking resemblance to mature plasma cells or their immediate precursors (Fig. 16.53). Binucleate, and occasionally multinucleated, forms are present.

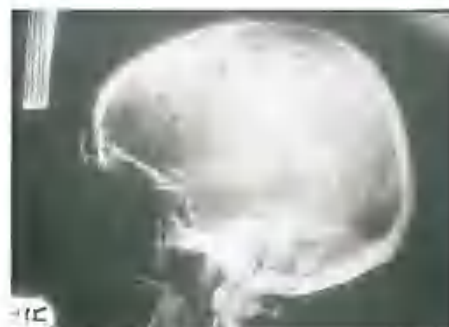

Fig. 16.52 Radiograph of the skull in multiple myeloma showing punched-out radiolucencies.

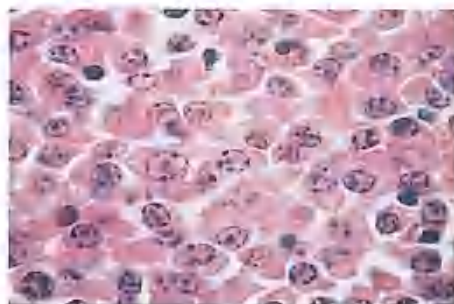


Fig. 16.53 A well-differentiated myeloma showing resemblance of neoplastic cells to mature plasma cells.

Ossifying (cemento-ossifying) fibroma

The ossifying (cemento-ossifying) fibroma is, typically, a well-demarcated, occasionally encapsulated, benign neoplasm. It consists of fibrous tissue containing varying amounts of bony trabeculae and rounded calcified bodies. (The supposed resemblance of the latter to cementum accounts for the alternative term of cemento-ossifying fibroma to describe this tumour). Its demarcated nature is an important feature distinguishing it from fibrous dysplasia.

Clinically, it presents as a slowly enlarging and progressive swelling (Fig. 16.54) most often in the premolar–molar region of the mandible, and can occur over a wide age range. Some authors have reported a female predilection. Radiologically, the appearances vary with the stage of development of the lesion. Initially there is a well-demarcated radiolucent area within which, as the lesion matures, varying amounts of calcified tissue are deposited (Fig. 16.55). The tumour also occurs in other craniofacial bones, particularly of the sino-nasal complex, and orbit.

Histologically, the lesion is well circumscribed (Fig. 16.56). It consists of cellular fibrous tissue containing trabeculae of bone, some of which may show osteoblastic rimming, and spherical/rounded deposits of relatively acellular calcified material (Figs 16.56, 16.57). (Although this may resemble cementum, similar tissue is found in tumours arising in other craniofacial bones. In some cases it is the predominant calcified tissue produced and such lesions may be designated as psammomatoid ossifying fibromas – from the Greek *psammos*, sand). The histological features of ossifying fibroma cannot reliably be distinguished from those of fibrous dysplasia, and the clinical and

radiographic features need to be taken into consideration to establish the diagnosis.

The majority of ossifying fibromas are slow growing but some, mainly in children and adolescents, show rapid growth. Histologically, they are characterized by richly cellular, mitotically active fibrous tissue with trabeculae of immature-looking woven bone and must be distinguished from osteosarcomas. The term 'juvenile ossifying fibroma' has been applied to such lesions. In contrast to the more usual type of cemento-ossifying fibroma above, which has a negligible recurrence rate, juvenile ossifying fibroma has a recurrence rate of about 30–60 per cent.

In rare cases, ossifying fibroma of the jaws is associated with hereditary hyperparathyroidism as part of the hyperparathyroidism–jaw tumour syndrome.

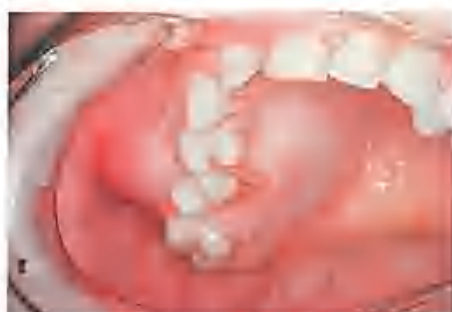Langerhans cell histiocytosis

Langerhans cell histiocytosis comprises a spectrum of disease with a wide range of clinical manifestations. However, it presents in one of three main ways:

- (1) as a solitary lesion in bone, referred to as unifocal eosinophilic granuloma;
- (2) as multifocal eosinophilic granuloma involving bone and other organs;
- (3) as disseminated multiorgan disease.

Patients with multifocal eosinophilic granulomas involving the craniofacial bones, orbit, and posterior pituitary present with the classical triad of Hand–Schuller–Christian syndrome – skull defects, exophthalmus, and diabetes insipidus. The disseminated form of Langerhans cell histiocytosis is referred to as Letterer–Siwe disease. It occurs mainly in infants and children under 2 years of age and has a high mortality.

Unifocal and multifocal eosinophilic granulomas occur in older children and, less commonly, in adults. The majority of patients are under 20 years of age, and males are affected about twice as commonly as females. Any bone may be involved but the cranium and jaws are common sites. Jaw lesions are more common in the mandible. Radiographs show either a solitary or multiple osteolytic lesions. Multiple eosinophilic granuloma involving the jaws can result in extensive destruction and loss or loosening of teeth which on radiographs may appear to be floating in air (Fig. 16.58).



Figs 16.54, 16.55 Clinical and radiographic appearances of ossifying fibroma. The tumour is well demarcated and contains varying amounts of mineralized tissue.

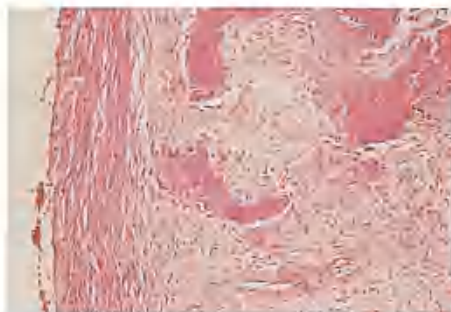


Fig. 16.56 Ossifying fibroma showing circumscribed/encapsulated margin and trabeculae of bone forming in fibrous tissue.

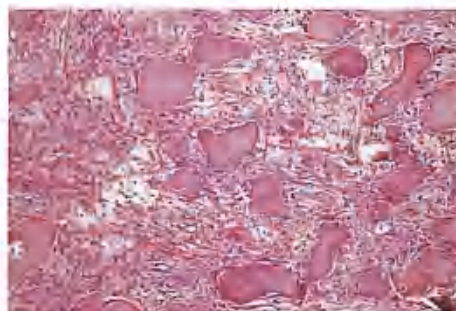


Fig. 16.57 Relatively acellular rounded calcified bodies forming in fibrous tissue in an ossifying fibroma.

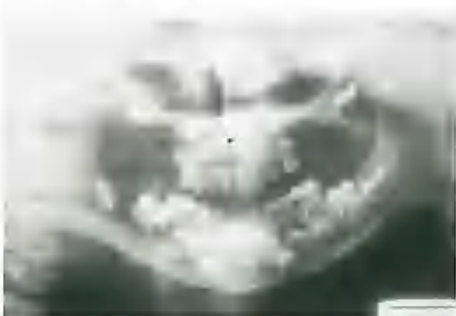

Fig. 16.58 Osteolytic lesion associated with developing first permanent molar in the right mandible of a five-year-old child with multifocal eosinophilic granuloma. Similar lesions resulted in exfoliation of both maxillary first permanent molars at age three years.

Histologically, the lesions of Langerhans cell histiocytosis are characterized by poorly defined collections of histiocytes mixed with variable numbers of eosinophils (Fig. 16.59). Ultrastructural examination shows that some contain rod or racquet-shaped granules, similar to those found in normal Langerhans cells (Birbeck granules). The cells also express surface antigens shared by normal Langerhans cells, which can be demonstrated by immunohistochemistry.

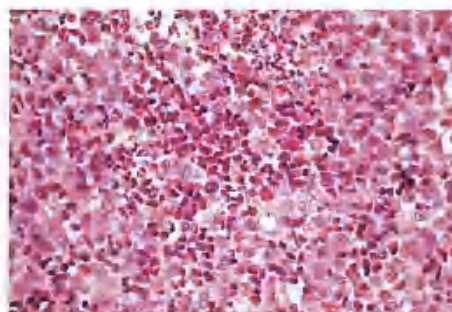


Fig. 16.59 Eosinophilic granuloma showing sheets of histiocytes with scattered eosinophils and neutrophils.

Haemangioma of bone

Haemangioma of bone is a rare lesion of the jaws which is more common in the mandible than in the maxilla. Radiographically, it appears as osteolytic defects that may have a multilocular honeycomb appearance. Aspiration will reveal fresh blood. Microscopically, most haemangiomas of bone are of the cavernous type.

Metastatic tumours

It has been estimated that metastatic tumours in the oral soft tissues and jaws account for about 1 per cent of malignant tumours occurring in the oral cavity. Metastasis to bone is more common than to the soft tissues, the mandible being much more frequently affected than the maxilla. The most common primary tumours reported as metastasizing to the jaws are carcinomas of the breast, bronchus, and kidney. Presenting features of metastatic tumours may be pain, loose teeth, swelling, and paraesthesia or anaesthesia of the lip due to involvement of the inferior dental nerve, but many lesions are asymptomatic.

Most metastatic tumours are osteolytic but some, such as carcinomas of breast and prostate, may be osteoblastic and appear radiographically as an area of radiopacity rather than radiolucency.

The most common sites for metastases to the oral mucosa are the gingiva or alveolar mucosa, followed by the tongue.

Further reading

- Bennett, J., Thomas, G., Evans, A. W., and Speight, P. M. (2000). Osteosarcoma of the jaws: a 30-year retrospective review. *Oral Surgery, Oral Medicine, Oral Pathology, Oral Radiology and Endodontics*, 90, 323–33.
- Chindia, M. L. (2001). Osteosarcoma of the jaw bones. *Oral Oncology*, 37, 545–7.
- Cleveland, D. B., Goldberg, K. M., Greenspan, J. S., Seitz, T. E., and Miller, A. S. (1996). Langerhans' cell histiocytosis. *Oral Surgery, Oral Medicine, Oral Pathology, Oral Radiology and Endodontics*, 82, 541–8.

- Cole, W. G. (2002). Advances in osteogenesis imperfecta. *Clinical Orthopaedics and Related Research*, 401, 6–16.
- Davies, J. E. (1998). Mechanisms of endosseous integration. *International Journal of Prosthodontics*, 11, 391–401.
- Devlin, H. and Ferguson, M. W. J. (1991). Alveolar ridge resorption and mandibular atrophy: a review of the role of local and systemic factors. *British Dental Journal*, 170, 101–4.
- Eckardt, A. and Schultze, A. (2003). Maxillofacial manifestations of Langerhans cell histiocytosis: a clinical and therapeutic analysis of 10 patients. *Oral Oncology*, 39, 687–94.
- Hudson, J. W. (1993). Osteomyelitis of the jaws: a 50-year perspective. *Journal of Oral and Maxillofacial Surgery*, 51, 1294–301.
- Hullar, T. E. and Lustig, L. R. (2003). Paget's disease and fibrous dysplasia. *Otolaryngologic Clinics of North America*, 36, 707–32.
- Lockington, T. J. and Bennett, G. C. (1994). Osteoporosis and the jaws: questions remain to be answered. *Gerodontology*, 11, 67–75.
- MacDonald-Jankowski, D. S. (2004). Fibro-osseous lesions of the face and jaws. *Clinical Radiology*, 59, 11–25.
- Mangion, J., Rahman, N., Edkins, S., Barfoot, R., Nguyen, T., Sigurdsson, A., et al. (1999). The gene for cherubism maps to chromosome 4p16.3. *American Journal of Human Genetics*, 65, 151–7.
- Marie, P. J. (2001). Cellular and molecular basis of fibrous dysplasia. *Histology and Histopathology*, 16, 981–8.
- McDonnell, D. (1993). Dense bone island: a review of 107 patients. *Oral Surgery, Oral Medicine, Oral Pathology*, 76, 124–8.
- Richardson, A. and Deussen, F. F. (1994). Facial and dental anomalies in cleidocranial dysplasia: a study of 17 cases. *International Journal of Paediatric Dentistry*, 4, 225–31.
- Saito, K., Unni, K. K., Wollan, P. C., and Lund, B. A. (1995). Chondrosarcoma of the jaw and facial bones. *Cancer*, 76, 1550–8.
- Steflik, D. E., Corpe, R. S., Young, T. R., Sisk, A. L., and Parr, G. R. (1999). The biological tissue response to uncoated and coated implanted biomaterials. *Advances in Dental Research*, 13, 27–33.
- Su, L., Weathers, D. R., and Waldron, C. A. (1997). Distinguishing features of focal cemento-osseous dysplasias and cemento-ossifying fibromas. I. A pathological spectrum of 316 cases. *Oral Surgery, Oral Medicine, Oral Pathology, Oral Radiology and Endodontics*, 84, 301–9.
- Su, L., Weathers, D. R., and Waldron, C. A. (1997). Distinguishing features of focal cemento-osseous dysplasias and cemento-ossifying fibromas. II. A clinical and radiological spectrum of 316 cases. *Oral Surgery, Oral Medicine, Oral Pathology, Oral Radiology and Endodontics*, 84, 540–9.
- Thesleff, I. (2003). Developmental biology and building a tooth. *Quintessence International*, 34, 613–20.
- Waldron, C. A. (1993). Fibro-osseous lesions of the jaws. *Journal of Oral and Maxillofacial Surgery*, 51, 828–35.
- Whitaker, S. B. and Waldron, A. (1993). Central giant cell lesions of the jaws. *Oral Surgery, Oral Medicine, Oral Pathology*, 75, 199–208.

Diseases of the temporomandibular joint

DEVELOPMENTAL DISORDERS

INFLAMMATORY DISORDERS

Traumatic arthritis

Infective arthritis

Rheumatoid arthritis

OSTEOARTHROSIS (OSTEOARTHRITIS)

FUNCTIONAL DISORDERS

Myofascial pain–dysfunction syndrome

Disc displacement


LOOSE BODIES

NEOPLASMS

AGE CHANGES IN THE JAWS AND TEMPOROMANDIBULAR JOINT

TRISMUS AND DISLOCATION

FURTHER READING



Diseases of the temporomandibular joint

Many of the diseases affecting other joints in the body can involve the temporomandibular joint (TMJ) but they may be modified by particular structural and functional features of this joint. Some aspects of the structure of the joint are discussed below.

Three distinct cell zones can be distinguished in the articular surface of the mandibular condyle during growth:

- (1) the articular zone of dense fibrous tissue covering the surface;
- (2) the proliferative or cellular zone which is the main centre for growth and chondrogenesis;
- (3) the hypertrophic zone, where the differentiated chondrocytes and cartilage matrix undergo endochondral ossification.

In adults the proliferative zone is reduced to a narrow band of cells and the hypertrophic zone is replaced by fibrocartilage with few hypertrophied cells. With advancing age the articular surface becomes increasingly fibrous. Remodelling of the articular surface takes place throughout life to compensate for occlusal wear or the loss of teeth.

The articular fossa is covered by a thin layer of fibrous tissue which thickens over the articular eminence, but pathological changes involve the surface of the fossa much less frequently than the condyle.

The articular disc is composed of fibrocartilage, comprising compact collagen fibres, small elastic fibres, and glycosaminoglycans, arranged in anterior and posterior bands connected by a

narrower and thinner intermediate zone. The components of the disc result in a viscoelastic structure that may be important in absorbing stress. The lateral pterygoid muscle is attached to the medial part of the anterior band, the lateral part being related to masseter and temporalis muscles. The posterior attachment of the disc is formed by the retrodiscal tissue which comprises a loosely organized meshwork of collagen fibres and large branching elastic fibres with fat, numerous blood vessels, and nerves. This connects the posterior band to the temporal bone, auditory meatus, and condyle. The stiff articular disc contrasts with the easily deformable posterior attachment. In normal joints the posterior band of the disc covers the summit of the condyle when the mouth is in a closed position. As the mouth is opened the posterior attachment expands to fill the joint space.

Developmental disorders

Aplasia of the condyle is extremely rare and may be unilateral or bilateral. Most of the reported cases have occurred in association with other facial anomalies.

Hypoplasia or underdevelopment of the condyle may be congenital or acquired. The cause of congenital hypoplasia is not known, but either one or both condyles may be involved. Acquired hypoplasia is due to an agent which interferes with the normal development of the condyle, such as trauma (from birth injury or fracture), radiation, or infection, usually resulting from extension of infection in the middle ear. The earlier the damage, the more severe is the resulting facial deformity (Fig. 17.1).

Hyperplasia of the mandibular condyle is a rare and self-limiting condition, the cause of which is not known. It is generally unilateral and results in facial asymmetry, deviation of the mandible to the opposite side, and malocclusion. It usually becomes apparent during the second decade of life, when one condyle continues to grow while the other is no longer active.

Inflammatory disorders

Traumatic arthritis

Damage to the condyle or to the ligaments and capsule of the joint following acute trauma may lead to a traumatic arthritis or haemarthrosis. Examples of acute trauma include condylar

Key points – Components of the temporomandibular joint

- mandibular condyle
 - articular zone
 - proliferative or cellular zone
 - hypertrophic zone
- articular fossa
- articular disc
 - anterior band
 - intermediate zone
 - posterior band
 - retrodiscal tissues

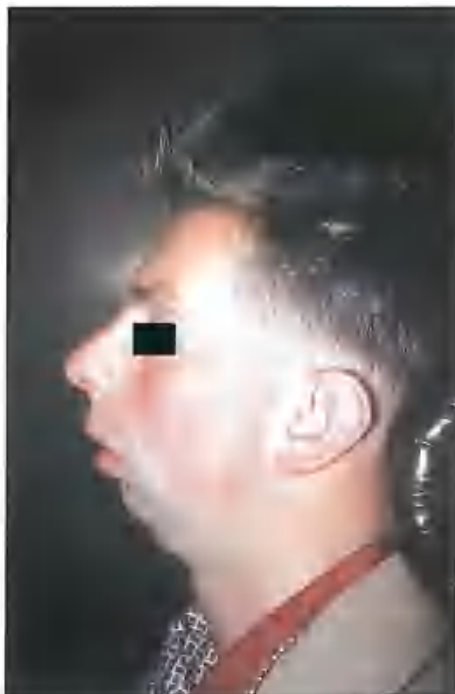

Fig. 17.1 Facial deformity associated with bilateral condylar hypoplasia.

fractures, dislocation, and hyperextension sprains. Traumatic arthritis usually resolves if the tissue damage is not severe, otherwise scar tissue formation may lead to ankylosis.

Infective arthritis

Infective arthritis of the temporomandibular joint is rare. Microorganisms may reach the joint by various routes:

- (1) direct spread from an adjacent focus of infection, for example from the middle ear or from a surrounding cellulitis;
- (2) haematogenous spread from a distant focus of infection;
- (3) facial trauma.

A variety of organisms has been implicated but *Staphylococcus aureus* is the most common isolate. The joint may also be involved in patients who develop a widespread infective polyarthritis such as in gonococcal arthritis or viral arthritis.

Patients usually present with pain, trismus, deviation on opening, and signs of acute infection. Complications include fibrous and occasionally bony ankylosis.

Rheumatoid arthritis

This is a non-organ-specific autoimmune disease with articular and diverse extra-articular manifestations. The disease commonly begins in early adult life and affects women more frequently than men. About 10 per cent of patients may show features of Sjögren syndrome (see Chapter 14). The smaller joints are mainly affected, particularly those of the hand (see Fig. 14.11), and the distribution tends to be symmetrical.

Although few patients with rheumatoid arthritis spontaneously complain of pain from their temporomandibular joints, 20–70 per cent will have TMJ involvement at some time. Limitation of opening, stiffness, crepitus, referred pain, and tenderness on biting are the usual symptoms, but severe disability is unusual.

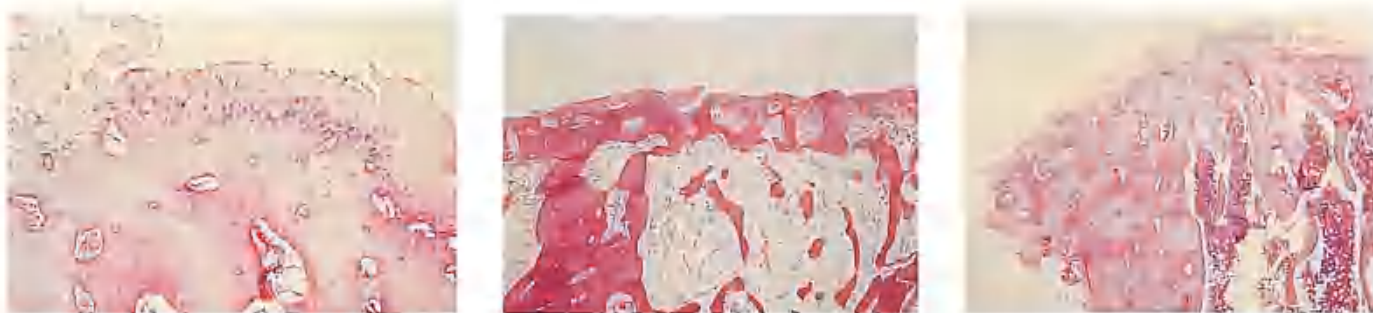
Joint involvement starts as a synovitis with an intense infiltration of lymphocytes and plasma cells in the hyperaemic synovial tissues. The synovial tissues proliferate and the hyperplastic and inflamed synovial membrane is thrown into folds which extend over the articular surfaces, clothing them in a vascular pannus. The articular surfaces become eroded by the pannus which may also extend into and cause resorption of the adjacent bone. Erosion of the condyle may be seen on radiographs. The articular surfaces become very irregular and fibrous ankylosis may result, either involving the lower joint compartment only or with total destruction of the articular disc and complete ankylosis.

Rheumatoid factor is mainly an IgM-class autoantibody against chemical groups on IgG molecules. It can be demonstrated in 85 per cent of patients with rheumatoid arthritis. Although its significance in the pathogenesis of the disease is not known, many of the features of rheumatoid arthritis are thought to be attributable to immune-complex deposition.

Osteoarthritis (osteoarthritis)

This is primarily a degenerative rather than inflammatory disease, although it is often referred to as osteoarthritis. It mainly affects weight-bearing joints. The disease in the temporomandibular joint differs in some respects from that elsewhere, probably because the joint is not weight-bearing and the articular surface is covered with a layer of mature fibrous tissue and not hyaline cartilage. Histologically, the disease is rare in the temporomandibular joint before the beginning of the fifth decade of life, but then increases proportionately with age. It may present clinically with pain, crepitus, limitation of jaw movement, and deviation on opening, but as in other joints many cases are clinically silent. Clinical studies have suggested a relationship in some cases between untreated myofascial pain–dysfunction syndrome, loss of molar support, or disc displacement and the later development of osteoarthritis. Spontaneous resolution of symptoms is common.

The earliest histological changes in the temporomandibular joint are uneven distribution of the cells in the articular covering of the condyle which may be associated with some osteoclastic resorption of the subarticular bony end-plate. Vertical splits (fibrillation) develop in the articular layer (Fig. 17.2), followed by fragmentation and loss of the articular surface with eventual exposure (denudation) of the underlying bone (Fig. 17.3). Reactive changes in the exposed subarticular bone lead to thickening of trabeculae and the formation of a dense surface layer, referred to as eburnation. Osteophytic lipping on the anterior surface also occurs, but this is seldom prominent (Fig. 17.4). The rough exposed bone on the condylar surface may lead to disruption and eventual perforation of the articular disc. Studies of synovial fluid



Figs 17.2–17.4 Osteoarthritic changes in the temporomandibular joint showing fibrillation and fragmentation of articular cartilage (Fig. 17.2), denudation and exposure of underlying bony end-plate (Fig. 17.3), and osteophytic lipping of the condyle (Fig. 17.4).

Key points – Arthritic conditions of TMJ

- traumatic
 - damage to condyle
 - damage to ligaments/capsule
- infective
 - rare
 - acute symptoms
 - bacterial access: direct spread/blood spread/trauma
- rheumatoid arthritis
 - common in patients with generalized rheumatoid arthritis
 - stiffness, limitation of movement
 - erosion of condyle by vascular pannus
- osteoarthrosis
 - increasing incidence after 50 years
 - pain, crepitus, limitation of movement, or symptomless
 - may be a previous history of TMJ dysfunction in some patients
 - degenerative changes, denudation, and eburnation of condyle

from patients with a range of temporomandibular joint disorders have shown elevated levels of pro-inflammatory cytokines in some cases. These cytokines could contribute to the degenerative changes seen in osteoarthrosis, and to the symptoms of pain.

The radiographic changes are variable and not pathognomonic. They include focal or diffuse areas of bone loss on the articular surface of the condyle, flattening and reduction in the total bony size of the condyle, and reduction in the joint space. Osteophytes may be seen at the anterior edge of the condyle. If large, they may fracture off and present on radiographs as loose bodies (see later).

Functional disorders

Myofascial pain–dysfunction syndrome

This is the commonest cause of complaint involving the temporomandibular joint and it has three cardinal symptoms: pain associated with the joint or its musculature, clicking of the joint, and limitation of jaw movement. Symptoms vary in intensity during

the day and are most common in the morning. Tenderness to palpation of the origins and insertions of the masticatory muscles is usual. The condition is seen more frequently in women than in men, and the mean age of presentation is about 30 years. Unilateral tooth loss or other dental irregularities are very common, but there is no consistent relationship between the side of such occlusal disharmony and the side of joint symptoms. The incidence of the condition is said to decrease if more than six teeth are missing. There is a strong clinical impression that the syndrome has a relationship with various types of emotional stress. Bruxism is common and many sufferers have nocturnal tooth-grinding habits. No consistent radiological changes have been described, and examination of the condylar surface by light microscopy shows no abnormal features. It is now thought that the principal factor responsible for the symptoms in this condition is masticatory muscle spasm, which may be precipitated by muscular overextension, contraction, or fatigue. Little is known about the subsequent histories of patients with this syndrome.

Disc displacement

Disc displacement, defined as an abnormal positional relationship between the articular disc, the head of the condyle, and the articular fossa of the temporal bone has been reported in from about 25 to 65 per cent of elderly patients. It is also prevalent in patients with pain–dysfunction syndrome and/or osteoarthritic changes in the joint, but whether the displacement precedes or follows such changes is unclear. However, not all patients with displacements have or develop signs or symptoms of disease.

The displacement may initially be an adaptive change and reflect remodelling of the disc to prevent tissue injury. Remodelling is associated with changes in the external shape and proportions of the disc and its posterior attachment, and with reactive changes in the tissues, such as increasing fibrosis and hyalinization in the retrodiscal tissues (see also the discussion on age changes below). In patients where remodelling has been unable to prevent tissue injury various pathological changes may also be seen. These include haemorrhage, myxomatous change, thickening of blood vessel walls, cartilage formation, and perforation of the posterior attachment, usually at its junction with the remodelled posterior band. Disc displacement generally appears necessary for the development of perforations.



Fig. 17.5 Loose body, probably a fractured osteophyte, within the right temporomandibular joint.

Loose bodies

Radiopaque bodies apparently lying free within the joint space are relatively common in major joints but are rare in the temporomandibular joint. They may give rise to discomfort, crepitus, and limitation of opening. Although a variety of diseases may be associated with intra-articular loose bodies in other joints, the main causes within the temporomandibular joint are intracapsular fractures, fractured osteophytes in osteoarthritis (Fig. 17.5), and synovial chondromatosis. The latter is a disease of unknown aetiology characterized by the formation of multiple nodules of metaplastic cartilage, which may calcify and ossify, scattered throughout the synovium. As the disease progresses they are released into the joint space as multiple loose bodies.

Neoplasms

Primary neoplasms arising from the structures of the temporomandibular joint are extremely rare. Benign tumours such as chondromas and osteomas are more frequent than sarcomas arising from bone or synovial tissues.

Age changes in the jaws and temporomandibular joint

As discussed in Chapter 16, increasing age is associated with progressive reduction in bone mass, resulting in osteoporosis. Age-related osteoporosis is common, and in edentulous patients could play a role in atrophy of alveolar and possibly basal bone, although no clear relationship has been established. Atrophy of alveolar bone is related mainly to the loss of teeth, and its extent increases with age, resulting, in the absence of dentures, in loss of facial height and upwards and forwards posturing of the mandible. Loss of alveolar bone is more extensive and occurs more rapidly in the mandible than in the maxilla.

With regard to the temporomandibular joint, it is difficult to distinguish changes due to ageing from those related to osteoarthritis. If the latter are excluded the main age changes in the joint are related to remodelling of the articular surfaces and disc in response to functional changes following tooth loss. As dis-

Table 17.1 Causes of trismus

<i>Intra-articular</i>	<ul style="list-style-type: none"> – Traumatic arthritis – Infective arthritis – Rheumatoid arthritis – Dislocation – Intracapsular fracture – Fibrous or bony ankylosis following trauma or infection
<i>Extra-articular</i>	<ul style="list-style-type: none"> – Adjacent infection, inflammation, and abscesses (e.g. mumps, pericoronitis, submasseteric abscess) – Extracapsular fractures (mandible, zygoma, middle third) – Overgrowth (neoplasia) of the coronoid process – Fibrosis from burns or irradiation – Haematoma/fibrosis of medial pterygoid (e.g. following inferior dental block) – Myofascial pain-dysfunction syndrome – Drug-associated dyskinesia and psychotic disturbances – Tetanus – Tetany

cussed above, remodelling may result in disc displacement, particularly anterior displacement. The posterior band of the disc may then lie anterior to the condyle when the mouth is closed, the posterior attachment being drawn in between the bearing surfaces of the condyle and articular eminence. The retrodiscal tissues may show adaptive changes associated with decreased cellularity and vascularity, and increased density of collagen, and may eventually function as an articular disc. However, in some cases the displacement may lead to perforation of the disc, particularly of its posterior attachment, resulting in progressive joint damage and osteoarthritis.

Trismus and dislocation


Trismus means limitation of movement, which in the temporomandibular joint may be due either to factors within the joint (intra-articular) or outside the joint (extra-articular). Temporary trismus is much more common than permanent trismus. The main causes of trismus are listed in Table 17.1.

Dislocation of the temporomandibular joint is uncommon and is the result of displacement of the condyle out of the glenoid fossa, beyond the articular eminence. The causes of instability of the joint are unclear but may involve abnormal neuromuscular activity, weakness of the capsule and lateral ligament, or anatomical factors related to the contour of the glenoid fossa or disc. Rarely, in some patients, dislocations may be recurrent or habitual.

Further reading

- Bjornland, T. and Refsum, S. B. (1994). Histopathologic changes in the temporomandibular joint disk in patients with chronic arthritic disease. A comparison with internal derangement. *Oral Surgery, Oral Medicine, Oral Pathology*, 77, 572–8.

- Dolwick, M. F. (1995). Intra-articular disc displacement. Part 1: its questionable role in temporomandibular joint pathology. *Journal of Oral and Maxillofacial Surgery*, 53, 1069-72.
- Hall, D. H. (1995). Intra-articular disc displacement. Part II: its significant role in temporomandibular joint pathology. *Journal of Oral and Maxillofacial Surgery*, 53, 1073-9.
- Holmlund, A. B., Gynther, G., and Reinholt, F. P. (1992). Rheumatoid arthritis and disk derangement of the temporomandibular joint. A comparative arthroscopic study. *Oral Surgery, Oral Medicine, Oral Pathology*, 73, 273-7.
- Kaneyama, K., Segami, N., Nishimura, M., Suzuki, T., and Sato, J. (2002). Importance of proinflammatory cytokines in synovial fluid from 121 joints with temporomandibular disorders. *British Journal of Oral and Maxillofacial Surgery*, 40, 418-23.
- Leighty, S. M., Spach, D. H., Myall, R. W., and Burns, J. L. (1993). Septic arthritis of the temporomandibular joint: review of the literature and report of two cases in children. *International Journal of Oral and Maxillofacial Surgery*, 22, 292-7.
- Luder, H.-U. (2002). Factors affecting degeneration in human temporomandibular joints as assessed histologically. *European Journal of Oral Science*, 110, 106-13.
- Pereira, F. J. Jr, Lundh, H., Eriksson, L., and Westesson, P.-L. (1996). Microscopic changes in retrodiscal tissues of painful temporomandibular joints. *Journal of Oral and Maxillofacial Surgery*, 54, 461-8.
- Pereira, F. J. Jr, Lundh, H., and Westesson, P.-L. (1994). Morphologic changes in the temporomandibular joint in different age groups. An autopsy investigation. *Oral Surgery, Oral Medicine, Oral Pathology*, 78, 279-87.
- Pereira, F. J. Jr, Lundh, H., and Westesson, P.-L. (1996). Age-related changes in retrodiscal tissues in the temporomandibular joint. *Journal of Oral and Maxillofacial Surgery*, 54, 55-61.
- Shorey, C. W. and Campbell, J. H. (2000). Dislocation of the temporomandibular joint. *Oral Surgery, Oral Medicine, Oral Pathology, Oral Radiology and Endodontics*, 89, 662-8.
- Widmalm, S. E., Westesson, P.-L., Kim, I. K., Pereira, F. J. Jr, Lundh, H., and Tsaki, M. M. (1994). Temporomandibular joint pathosis related to sex, age, and dentition in autopsy material. *Oral Surgery, Oral Medicine, Oral Pathology*, 78, 416-25.



Index

- abscess
 acute periapical (alveolar) 60–3
 aetiology 60
 routes of spread 61–3
 lateral periodontal 98
 pulp 49
acantholysis 181–2
achondroplasia 242–3
acinic cell carcinoma 216
acquired immunodeficiency syndrome 166–71
 HIV infection 140, 166–7
 oral manifestations 167–71, 211
acromegaly 252
actinomyces in dental caries 23, 31
actinomycosis 158–9
acute (necrotizing) ulcerative gingivitis 157–8,
 158 (*table*), 168
Addison's disease 200
adenoid cystic carcinoma 216–17
adenolymphoma 214–15
adenoma
 basal cell 214–15
 canalicular 215
 pleomorphic 212–14
 pleomorphic, carcinoma in 218
adenomatoid odontogenic tumour 233
aerodontalgia 48
age changes
 jaws 268
 oral mucosa 201
 periodontium 99
 pulp 53
 salivary glands 218
 teeth 43–4
 temporomandibular joint 268
agranulocytosis 96 (*table*)
AIDS *see* acquired immunodeficiency syndrome
Albright syndrome *see* McCune–Albright
 syndrome
alcohol
 and leukoplakia 124
 and squamous cell carcinoma 137, 139
amalgam
 in lichenoid lesions 129, 130
 tattoo 198–9, 200
ameloblastic carcinoma 231, 236
ameloblastic fibrodentinoma 232s–3
ameloblastic fibroma 232–3
ameloblastic fibro-odontoma 232–3
ameloblastoma 228–32
 behaviour 231
 clinical and radiographic features 228–9
 extraosseous *see* peripheral
 histopathology 229–30
 pathogenesis 230
 peripheral 232
 unicystic 231–2
amelogenesis 8
amelogenesis imperfecta 11–12
amelogenin 8, 11
amyloidosis 197
aneurysmal bone cyst 80–1
angina bullosa haemorrhagica 186
angiomyoma 113
angular cheilitis 165
ankylosis
 of teeth
 in hypercementosis 15
 in Paget's disease 16, 254, 255
 in reimpaction 36
 in reimplantation 42
 in resorption 39, 41
 of temporomandibular joint 266
anodontia 3, 5
antibiotic sore tongue 163
aphthous ulceration 176–80
apical abscess *see* abscess, acute periapical
apical granuloma *see* granuloma, periapical
 58–60
areca nut *see* betel
arthritis
 infective 266
 rheumatoid 209, 266
 traumatic 265–6
aspirin burn 121, 122, 175–6
attrition 36
 in amelogenesis imperfecta 12, 36
 in dentinogenesis imperfecta 13, 36
AUG *see* acute (necrotizing) ulcerative gingivitis
- bacterial infections
 oral mucosa 157–61
 actinomycosis 23, 31
 necrotizing ulcerative gingivitis 157–8, 168
 gonorrhoea 161
 leprosy 161
 noma 158, 159
 syphilis *see* syphilis
 tuberculosis 160–1
 salivary glands 205–6
barotrauma 48
basal cell carcinoma 147–8
 multiple, in basal cell naevus syndrome 74–5
Behçet's disease 180
benign lymphoepithelial lesion 210, 211
benign mucous membrane pemphigoid 183,
 184–5, 185 (*table*)
betel
 chemical insult 124, 138–9
 chewing 36, 124, 138–9, 197, 198
bidi smoking 124
Birbeck granules 261
black hairy tongue 198
Bohn's nodules 77
bone
 cysts 79–81
 developmental disorders 241–7
 fibro-osseous lesions 243, 243 (*table*)
 haemangioma 261
 healing 247–8
 inflammatory diseases 248–51
 Langerhans cell histiocytosis 260–1
 metabolic and endocrine disorders 251–2
 resorption
 and cyst expansion 71, 77
 in periodontal disease 94–5, 95 (*table*)
branchial (lymphoepithelial) cyst 83, 170
bruxism 36, 57, 267
bullous pemphigoid 183, 185, 185 (*table*)
Burkitt's lymphoma 113, 114
- café-au-lait* spots 111, 199
calcifying cystic odontogenic tumour 223
 (*table*), 234
calcifying epithelial odontogenic tumour 232
calcifying odontogenic cyst 234, 235
calculi, salivary 207–8
cancer, oral *see* squamous cell carcinoma
cancerum oris 158, 159
Candida species 161–2
 in angular cheilitis 165
 in denture stomatitis 164–5
 in leukoplakia 124, 127, 140–1, 163–4
 opportunistic infection 161–2
 in squamous cell carcinoma 140–1
candidosis
 in acquired immune deficiency syndrome 167
 chronic atrophic 107, 164–5
 chronic hyperplastic 124, 140–1, 163–4
 chronic mucocutaneous 166
 classification 162, 162 (*table*)
 erythematous 163
 and HIV infection 167
 multifocal 163, 165
 in palatal papillary hyperplasia 107
 predisposing factors 161 (*table*)
 pseudomembranous 162–3

- carbohydrate and dental caries 23-4
- carcinoma
- acinic cell 216
 - adenoid cystic 216-17
 - ameloblastic 231, 232
 - arising in pleomorphic adenoma 218
 - basal cell 147-8
 - multiple, in basal cell naevus syndrome 74-5
 - medullary of thyroid 111, 112
 - mucoepidermoid 215-16
 - odontogenic 223 (table), 231, 232, 236
 - in odontogenic cysts 236
 - polymorphous low grade adenocarcinoma 218
 - primary intraosseous 232
 - salivary 215-18
 - squamous cell 135-46
 - verrucous 146-7
- carcinoma *in situ* 123, 127, 147
- caries *see* dental caries
- cellulitis 62, 63
- cementifying fibroma 260-1
- cementoblastoma, benign 236
- cementoma
- gigantiform (florid cemento-osseous dysplasia) 245
 - true 235-6
- cemento-osseous dysplasia 243, 245-6, 250, 257
- florid 245
- cemento-ossifying fibroma 260
- cementum
- age changes 44
 - aplasia 16
 - caries 30-1
 - disturbances in structure 15-16
 - dysplasia of 245-6, 250
 - hyperplasia *see* hypercementosis
 - hypoplasia 16
 - tumours containing 235-6
- chancres 159
- Chediak-Higashi syndrome 96 (table)
- cheilitis
- angular 165
 - granulomatosa 193
- cherubism 242, 246-7
- chickenpox 155
- cholesterol clefts 59, 71, 74
- chondroectodermal dysplasia (Ellis-van Creveld syndrome) 4 (table)
- chondroma 259
- chondromatosis, synovial 268
- chondrosarcoma 259
- cicatricial pemphigoid *see* benign mucous membrane pemphigoid
- Civatte bodies 129
- clear cell odontogenic tumour 232
- cleft lip/palate 4 (table), 16
- cleidocranial dysostosis *see* dysplasia, cleidocranial
- coeliac disease 179
- collagenase
- in cyst expansion 71
 - in periodontal disease 92
- conrescence of teeth 7-8, 15
- condensing osteitis 249
- condyle
- aplasia 265
 - hyperplasia 265
 - hypoplasia 265, 266
- condyloma acuminatum 136, 137
- congenital
- epulis *see* gingival granular cell tumour
 - gingival granular cell tumour 236
 - heart disease, microdontia in 6
 - hyperbilirubinaemia, teeth in 41
 - porphyria, teeth in 41
 - syphilis 9-10, 160
- connation of teeth (double teeth) 7, 8
- connective tissue
- hyperplasia 103 (table), 103-7
 - neoplasia 107-14
- coxsackie viral infections 156
- craniofacial anomalies 16
- Crohn's disease 179, 193-4
- and orofacial granulomatosis 193, 194
- Crouzon syndrome 4 (table), 16
- cyclic neutropenia 89, 96 (table)
- cyclosporin 89 (table), 97, 97 (table)
- cystadenoma lymphomatousum, papillary 214-15
- cysts
- aneurysmal bone 80-1
 - botryoid odontogenic 78
 - branchial *see* lymphoepithelial
 - calcifying odontogenic 234-5
 - classification 67, 67 (table), 81 (table)
 - dentigerous 72-4, 242
 - dermoid 83
 - developmental lateral periodontal 77-8
 - epidermoid 83
 - eruption 72, 73, 74
 - gingival 77
 - glandular odontogenic 76
 - incidence 67, 67 (table)
 - incisive canal 78-9
 - inflammatory lateral periodontal 69
 - keratinous metaplasia in 77
 - lateral periodontal 69, 77-8
 - lymphoepithelial 83, 170
 - malignant change in 232
 - median 79
 - mucous extravasation 82
 - mucous retention 82
 - nasolabial 79
 - nasopalatine duct 78-9
 - non-epithelialized primary bone 79-81
 - non-odontogenic 67, 78-9
 - odontogenic 67-78
 - odontogenic keratocyst 74-7
 - papilla palatina 79
 - paradental 78
 - primordial *see* odontogenic keratocyst
 - radicular 60, 68-72
 - residual 69
 - salivary mucoceles 81-3
 - satellite 76
 - soft tissue 81-4
 - solitary bone 80
 - thyroglossal 83-4
 - traumatic bone 80
- cytology, exfoliative 181
- cytomegalic inclusion disease 207
- cytomegalovirus 157, 168, 170, 207
- Darier's disease 121 (table)
- dead tracts in dentine 28, 36, 37
- dense bone island 257
- dens evaginatus 225, 226
- dens-in-dente 224
- dens invaginatus 223-5
- dental caries 21-32
- aetiological variables 24
 - aetiology 21-4
 - arrested 25, 31
 - cementum *see* root
 - classification 24-5
 - dentine 28-30
 - enamel 25-8
 - histopathogenesis 27
 - immunological aspects 31
 - pathology of 24-31
 - pit and fissure 24, 27
 - pulpitis and 47
 - rampant 25, 31
 - role of bacteria in 21-3
 - role of carbohydrates in 23-4
 - root 25, 30-1
 - smooth surfaces 24-5
 - Streptococcus mutans* and 22, 23 (table)
- dental plaque
- in chronic periodontal disease 87-8, 88 (table)
 - in dental caries 21-4
- dentigerous cyst 72-4, 242
- clinical and radiographic features 72-3
 - macroscopic features and histopathology 73-4
 - pathogenesis and expansion 73
- dental dysplasia 14
- dentine
- age changes 43-4
 - caries 23, 28-30
 - lactobacilli and 22-3, 29
 - dead tracts 28, 36, 37
 - disturbances in structure 13-15
 - causes 12 (table)
 - reactionary/tertiary 28, 30, 36, 37, 48
 - sclerosis 28, 36, 37, 43, 51
- dentinogenesis imperfecta 13-14
- Brandywine isolate 14
 - and osteogenesis imperfecta 13, 14, 241
- dentinogenic ghost cell tumour 234
- dentinitis *see* ameloblastic fibrodentinitis
- denture stomatitis 164-5
- dermatitis herpetiformis 185, 185 (table)
- dermoid cyst 83
- diabetes mellitus, and periodontal disease 89, 96 (table)
- dilaceration 6
- disc displacement temporomandibular joint 266, 267
- distomolar 5
- double teeth 7, 8
- Down syndrome 4 (table), 6, 35, 96 (table)
- drug eruptions
- erythema multiforme 182-3
 - lichenoid 129
 - dry socket 248-9
- dyskeratosis congenita 121 (table)
- dysphagia, sideropenic 124, 139, 147
- dysplasia
- cemento-osseous 243, 245-6, 250, 257
 - florid 245
 - cleidocranial 4 (table), 16, 35, 36, 241-2, 244

- dentinal 14
 ectodermal 3–5
 epithelial 125–6, 147
 fibrous 242
 florid cemento-osseous 245
 osseous 243
 periapical cemental 245–6
 periapical fibrous *see* periapical cemental
- ectodermal dysplasia 3–5
 Ehlers–Danlos syndrome 96 (*table*)
 elephantitis neuromatosa 111
 Ellis–van Creveld syndrome 4 (*table*)
 enamel
 age changes 43
 caries 25–8
 chronological hypoplasia 9, 10
 disturbances in structure 8–12
 aetiology 9 (*table*)
 hypomineralization 8, 9, 10, 12
 hypoplasia 8–12
 chronological 9, 10
 opacities 9
 pearl 225–6
 enameloma *see* enamel, pearl
 endodontic treatment, periapical periodontitis and 58
 eosinophilic granuloma
 bone, unifocal, multifocal 260
 soft tissue *see* granuloma, traumatic
 epanutin 97 (*table*)
 ephelis 200
 epidermoid cyst 83
 epidermolysis bullosa 185 (*table*), 186
 aquisita 186
 epithelium
 acanthosis 120
 antigenic changes 129
 atrophy 120, 124, 196
 cellular atypia 120, 125
 dysplasia 120, 125–6, 126 (*table*), 147
 keratosis 119–31
 tumours, oral mucosa 135–47
 Epstein–Barr virus (EBV) 113, 114, 124, 140, 156, 168, 170, 211
 Epstein's pearls 77
 epulis 103 (*table*), 103–6, 108 (*table*)
 congenital 236
 fibrous 103 (*table*), 103–4, 235
 giant cell 103 (*table*), 105–6, 251
 in pregnancy 103 (*table*), 104
 pyogenic granuloma 103 (*table*), 104–5, 108 (*table*)
 vascular 103 (*table*), 104
 erosion 37
 eruption
 cyst *see* dentigerous cyst
 disorders 35–6
 premature 35
 retarded 35, 241, 242
 erythema migrans 192
 erythema multiforme 182–3
 recurrent 182
 erythematous candidosis 163
 erythroplakia 123, 124, 126, 127, 142, 147
 exfoliative cytology 181
- exostosis 256–7
 extraosseous ameloblastoma 232
- fasciitis, nodular 108 (*table*), 111
 fibroepithelial polyp 106–7, 108 (*table*)
 fibrolipoma 108
 fibroma
 ameloblastic 232–3
 cementifying *see* cemento-ossifying
 cemento-ossifying 260
 giant cell 106, 108 (*table*)
 juvenile ossifying 260
 leaf 106
 odontogenic 234–5
 ossifying 245
 psammomatoid 260
 of soft tissue 107–8, 108 (*table*)
 ossifying *see* cemento-ossifying
 fibromatoses 108 (*table*), 111
 fibromatosis, gingival 97, 97 (*table*), 103–7, 108, 195
 fibromyxoma 236
 fibro-odontoma, ameloblastic 232–3
 fibro-osseous lesions of bone 243, 243 (*table*)
 fibrosarcoma 108 (*table*)
 of bone 245
 of soft tissue 108
 fibrosis, oral submucous 124, 147, 197
 fibrous dysplasia 242, 243
 aetiology and behaviour 245
 craniofacial 243
 monostotic 243–4
 pathology 245
 periapical 245–6
 polyostotic 243, 244
 fibrous histiocytoma 108 (*table*), 111
 malignant 108 (*table*)
 fibrous overgrowths 107, 108 (*table*)
 fissured tongue 192
 florid cemento-osseous dysplasia 245
 fluoride ion
 in dental caries 22
 and enamel formation 10–11
 fluorosis, teeth in 10–11
 focal epithelial hyperplasia 136
 foliate papillitis 191
 follicular keratosis 121 (*table*)
 Fordyce's granules or spots 191, 201
 fungal infections 161–6, 162 (*table*)
 acute atrophic candidosis 163
 angular cheilitis 165
 Candida-associated denture stomatitis 164–5
 chronic hyperplastic candidosis 163–4
 chronic mucocutaneous candidosis 166
 deep visceral mycoses 166
 erythematous candidosis 163
 HIV-associated 167
 pseudomembranous candidosis 162–3
 fusion of teeth 7
 fusospirochaetal complex in AUG 157, 158
- Gardner syndrome 4 (*table*), 257–8
 Garré's osteomyelitis 250
 gemination of teeth 7
 genodermatoses 120, 121 (*table*)
- genokeratoses 120
 geographic tongue 192
 ghost teeth 14–15
 giant cell granuloma
 central 255–6
 peripheral 103 (*table*), 105–6, 251
 gingival cyst 77
 gingival enlargement 96–7, 97 (*table*)
 gingival fibromatosis 97, 97 (*table*), 103–7, 108, 195
 gingival hyperplasia 96–7, 97 (*table*), 103–7, 195
 gingivitis 87 (*table*)
 acquired immune deficiency and *see* HIV associated
 acute necrotizing ulcerative 157–8, 158 (*table*), 168
 chronic 87 (*table*), 87–95
 hyperplastic 96–7, 97 (*table*), 195
 pathology 90–4
 collagen breakdown in 92
 desquamative 97–8, 128, 184
 drugs, effects of 89, 96–7, 97 (*table*)
 early 91
 established 91–2
 HIV associated 168
 initial 90–1
 pathogenic mechanisms 95
 'plasma-cell' 98
 pregnancy and 89
 in sarcoidosis 194
 'strawberry' *see* Wegener's granulomatosis
 systemic factors and 88–9
 in Wegener's granulomatosis 97 (*table*), 195
 gingivostomatitis, primary herpetic 153–5
 glandular fever 156
 glandular odontogenic cyst 76
 glossitis
 benign migratory 192
 median rhomboid 165
 syphilitic 159
 glucans in dental plaque 22
 gonorrhoea 161
 Gorlin syndrome 74–5
 graft-versus-host reaction 130
 granular cell myoblastoma *see* granular cell tumour
 granular cell tumour 112
 congenital gingival 236
 granuloma
 candida 166
 central giant cell 255–6
 eosinophilic
 of bone 260
 of soft tissue *see* granuloma, traumatic
 mid-line 114
 periapical 58–60
 peripheral giant cell 103 (*table*), 105–6, 251
 pulse 250
 pyogenic 103 (*table*), 104–5, 106, 108 (*table*)
 Stewart's 114
 traumatic 176, 177
 vegetable 250
 granulomatosis, Wegener's 97 (*table*), 194–5, 196
 'gumboil' 61
 gumma, in tertiary syphilis 159, 160

- haemangioma
of bone 261
capillary 108–9
cavernous 108–9
juvenile 109
of salivary glands 109
of soft tissue 108–10
- haemochromatosis 201
- haemolytic disease of newborn 41
- hairy leukoplakia 124, 168, 169
- hand, foot, and mouth disease 156, 157
- Hand–Schuller–Christian syndrome 260
- healing
extraction socket 247, 248
osseointegrated implants 247–8
- Heck's disease 136
- Heerfordt syndrome 194, 207
- hereditary benign intraepithelial genodermatoses 121 (*table*)
- hereditary opalescent dentine 13–14
- herniation, buccal pad of fat 108
- herpangina 156
- herpes labialis 155
- herpes simplex virus 140, 153, 154, 155 (*table*), 168, 182
recurrent infection 154–5
herpesvirus-6 (HHV-6) 168
- herpes zoster 155–6
- herpetic stomatitis 153–5
- histiocytosis
idiopathic *see* Langerhans cell
Langerhans cell 96 (*table*), 260–1
-X *see* Langerhans cell
- HIV *see* acquired immune deficiency syndrome
- Hodgkin's disease 113, 114
- human immunodeficiency virus (HIV) *see*
acquired immune deficiency syndrome
- human papilloma virus (HPV) 124, 135, 136, 140, 168
- Hutchinson's incisors 10, 160
- hygroma, cystic 110
- hyperbilirubinaemia, teeth in 41
- hypercementosis 15–16, 44
in Pager's disease of bone 16, 253, 254, 255
- hyperkeratosis *see* keratosis
- hyperparathyroidism 251–2, 260
primary 251–2
secondary 252
- hyperplasia
connective tissue 103 (*table*), 103–7
denture irritation 107
drugs and 89, 96–7
focal epithelial 136
gingival 96–7, 97 (*table*), 103–7, 195
papillary of palate 107
- hypocementosis 16
- hypodontia 3, 4 (*table*), 5 (*table*), 6
- hypohidrotic ectodermal dysplasia 3–4, 4 (*table*), 5 (*table*)
- hypoparathyroidism, teeth in 14
- hypophosphataemia, teeth in 14
- hypophosphatasia, teeth in 14, 16, 96 (*table*)
- idiopathic histiocytoses *see* Langerhans cell, histiocytosis
- infections, oral mucosa 153–71
bacterial 157–61
fungal 161–6
viral 153 (*table*), 153–7
- infectious mononucleosis 156
- ionic exchanges in plaque 22, 23
- iron deficiency 124, 139, 165, 179
- jaundice, neonatal 41
- Job syndrome 96 (*table*)
- juvenile ossifying fibroma 260
- Kaposi's sarcoma 109, 169–70
herpesvirus in 170
- keratinising cystic odontogenic tumour 77, 223 (*table*)
- keratoconjunctivitis sicca 209, 210
- keratosis 119–31
aetiology and classification 119, 119 (*table*)
chemical trauma 121–2
definitions of histopathological terms 120
dermatological causes 128–31
frictional 121
hereditary conditions 120
leukoplakia 122–8
mechanical trauma 121
smokers 123
solar 140
sublingual 127
thermal trauma 122
traumatic 121–2
- Klinefelter syndrome 7
- Koplik's spots 157
- lactobacilli, in dental caries 22–3, 29
- lateral periodontal cyst
developmental 77–8
inflammatory 69
- Langerhans cell 169, 260, 261
histiocytosis 96 (*table*), 260–1
- leiomyoma 113
- leiomyosarcoma 113
- leprosy 161
- Letterer–Siwe disease 260
- leukaemia, oral manifestations 89, 97, 97 (*table*)
- leukoedema 120
- leukoplakia
aetiological factors 124–5
candidal 124, 127, 163–4
clinical features 123
epithelial dysplasia in 125–6, 127
hairy 124, 168, 169
homogeneous 123, 126, 127
idiopathic 119 (*table*), 122–8
incidence 123
malignant transformation 126–7
pathology 125–6
prognosis 126–8
speckled and non-homogeneous 123, 126, 127, 140, 163, 164
syphilitic 141, 159–60
verrucous 123, 147
- lichen planus 128–30
aetiology 129 (*table*), 129–30
clinical features 128, 128 (*table*)
malignant transformation 129
- pathogenesis 129–30
pathology 128–9
- lichenoid reactions (lesions) 129, 130
- linear IgA disease 185 (*table*), 185–6
- lingual tonsil 191
- lipoma 108
- liposarcoma 108
- liquefaction foci, in dentine caries 29–30
- loose bodies, temporomandibular joint 268
- Ludwig's angina 63
- lupus band 130
- lupus erythematosus 130–1
- lymphangioma 110
- lymphoepithelial cyst 83, 170
- lymphoma, malignant 113–14
in AIDS 170
Burkitt's 113, 114
Hodgkin's disease 113, 114
of mucosal-associated lymphoid tissue, MALT 114, 211
nasal NK/T-cell 114
non-Hodgkin's 113, 114, 170
in Sjögren syndrome 114, 121
lymphomatous, papillary cystadenoma 214–15
- macrodontia 5–6
- macroglossia 110, 197
- malignant lymphoma *see* lymphoma, malignant
- MALT (mucosal-associated lymphoid tissue) 114
- marble bone disease 241
- McCune–Albright syndrome 244
- measles 157
- median cysts 79
- melanin
incontinence 125, 200
pigmentation 125, 170, 199–201
- melanocytic naevi 148–9, 199
- melanoma, malignant 148–9
- melanosis, acquired 199–201
- melanotic macule, idiopathic oral 200, 201
- melanotic neuro-ectodermal tumour of infancy 236
- Melkersson–Rosenthal syndrome 193
- mesiodens 5
- metalloproteinases in periodontal disease 94
tissue inhibitors of (TIMP) 94
- microdontia 5–6
- midline granuloma (nasal NK/T-cell lymphoma) 114
- Moon's molars 10, 160
- 'mottling' of enamel 11
- mucocoeles
extravasation 82
retention 82
- mucopidermoid carcinoma 215–16
- mucosal-associated lymphoid tissue (MALT) 114
- mucous patches in syphilis 159
- mulberry (Moon's) molars 10, 160
- multiple endocrine neoplasia syndrome 111, 112
- mumps 206–7
- mycoses, deep visceral 166
- myeloma 259–60
multiple 197, 259
solitary 259
- myelomatous 259
- myoblastoma, granular cell 112

- myofascial pain dysfunction syndrome 266, 267
 myxochondroid tissue 214–15
 myxoma 234–5
- naevus
 blue 148–9
 junctional, compound, intramucosal 148
 melanocytic 148–9, 199
 multiple basal-cell syndrome 74–5
 oral epithelial 120
 pigmented *see* melanocytic
 white sponge 120
- nasal NK/T-cell lymphoma 114
 nasolabial cyst 79
 nasopalatine duct cyst 78–9
 necrotizing sialometaplasia 208–9
 neonatal jaundice, teeth in 41
 neurilemmoma 110, 111–12
 neurological disturbances and HIV 170
 neurofibroma 110–11
 plexiform 111
 neurofibromatosis 111
 neuroma
 multiple in endocrine neoplasia syndrome 111
 traumatic 110, 112
 nicotinic stomatitis 122
 nifedipine, gingival hyperplasia 89 (*table*), 97, 97 (*table*)
 Nikolsky's sign 181
 noma 158, 159
 non-Hodgkin's lymphoma 113, 114, 170
 nutrition and diet
 in dental caries 23–4
 in periodontal disease 89
 in squamous cell carcinoma 139–40
- odontoameloblastoma 233
 odontogenic keratocyst 74–7
 clinical and radiographic features 74–5
 growth 77
 histopathology 76–7
 odontogenic fibroma 234–5
 peripheral 235
 odontogenic myxoma 234–5
 odontogenic tumours 228–36
 classification 223, 223 (*table*)
 odontomes 223 (*table*), 223–8
 complex 226–7
 compound 227–8
 dilated 224
 enamel pearl 225–6
 evaginated 225, 226
 geminated 223
 gestant 224
 invaginated 47, 223–5
 clinical, radiological features 223–4
 histopathology, pathogenesis 224–5
 radicular invaginations 225
 oncocytes 214, 218
 oncocytoma 215
 oncogenes
 in Burkitt's lymphoma 114
 in squamous cell carcinoma 141–2
 oral blood blister 186
 oral epithelial naevus 120
- oral–facial–digital syndrome 4 (*table*)
 oral mucosa, age changes 201
 oral pigmentation 197–201, 198 (*table*)
 oral ulceration 175, 175 (*table*)
 orofacial granulomatosis 192–3
 osseointegrated implants, healing 247–8
 osseous dysplasia 243
 ossifying fibroma 245
 psammomatoid 260
 osteitis 248
 alveolar 248–9
 condensing *see* focal sclerosing
 focal sclerosing 249, 250
 osteoarthritis 266–7
 osteoblastoma 235, 257–8
 osteochondroma 259
 osteogenesis imperfecta 241, 242
 dentinogenesis imperfecta and 241
 osteoma 257–8
 osteomalacia 252
 osteomyelitis 248, 249–50
 Garré's 250
 infantile 250
 newborn and infants *see* infantile
 predisposing factors 249 (*table*)
 radiation 251
 sclerosing 250
 suppurative 249–50
 osteopetrosis 241, 248
 osteophytes 266
 osteoporosis 251
 in osteogenesis imperfecta 241
 in Paget's disease 254
 osteoradionecrosis 250–1
 osteosarcoma 255, 258–9
 intramedullary 258–9
 juxtacortical 259
 osteosclerosis 249, 257
- p53
 in leukoplakia 124–5
 in squamous cell carcinoma 140, 141–2
 pachyonychia congenita 121 (*table*)
 Paget's disease of bone 16, 248, 252–5
 clinical, radiographic features 253–4
 complications 254–5
 pathology 254–5
 viruses in 252
 palmar–plantar hyperkeratosis 35, 96
 pan chewing 124, 138–9
 papillary cystadenoma lymphomatosum 214–15
 papillary hyperplasia of palate 107
 papilloma, squamous cell 135, 136
 ductal 215
 Papillon–Lefèvre syndrome 96, 96 (*table*)
 paradental cyst 78
 paramolar 5
 parotitis
 acute 205
 epidemic 206–7
 Patterson–Kelly syndrome 124, 139
 pemphigoid 183–5, 185 (*table*)
 antigen 185
 pemphigus 180–2
 acantholysis, mechanisms 181–2
 foliaceous 220
- paraneoplastic 181
 vegetans 181
 vulgaris 180–2
- periapical
 abscess 60–3
 cemental dysplasia 245–6
 granuloma 58–60
 periodontitis 57–63
 acute 58
 aetiology 57–8
 chronic 58–60
 pericoronitis 98–9
 periodontal abscess 98
 periodontal disease
 acquired immune deficiency syndrome and *see*
 HIV-associated
 aetiology 87–8
 bone resorption in 94–5, 95 (*table*)
 chronic 87–95
 degradation of extracellular matrix 94–5
 dental plaque in 87–8, 88 (*table*)
 epidemiology 87
 HIV-associated 89, 167–8
 pathogenesis 89–94
 mechanisms 95
 systemic factors in 88–9
 acute leukaemia and 89, 97 (*table*)
 blood diseases and 89, 96 (*table*)
 diabetes mellitus and 89, 96 (*table*)
 drugs and 89 (*table*)
 smoking and 89
 periodontal pocket 94
 periodontitis
 adult type 95
 aggressive 87 (*table*), 96
 chronic, pathology 95, 96 (*table*)
 clinical forms 95–6
 juvenile 96, 121 (*table*)
 periapical 57–63
 prepubertal 96, 96 (*table*)
 rapidly progressive 96
 in systemic disease 87 (*table*), 96
 periodontium, diseases of 87–99
 age changes 99
 periostitis 248
 chronic with hyaline bodies 250
 ossificans 250
 proliferative 250
 Peutz–Jeghers syndrome 199, 200
 phenytoin hyperplasia 89 (*table*), 96
 phlebotomias 108
 pigmentation
 drug induced 200
 foreign material 198
 heavy metal salts 199
 HIV-associated 170–1
 iron 201
 jaundice 201
 melanin 199–201
 minocycline 200
 oral 197–201
 racial 199, 200
 staining, mucosa 198
 tattoos 198–9, 200
 tetracycline, teeth 41–2, 200
 plasmacytoma 259
 Plummer–Vinson syndrome 124, 139

- polymorphous low-grade adenocarcinoma 218
 polyostotic fibrous dysplasia 243, 244
 polyp
 fibroepithelial 106–7
 pulp 50
 polymorphic reticulosis (nasal NK/T-cell lymphoma) 114
 polyposis
 coli 258
 gastrointestinal 199
 poly-X syndrome 7
 porphyria, congenital, teeth in 41
 pregnancy
 and periodontal disease 89, 97 (*table*)
 epulis 103 (*table*), 104
 gingivitis 89
 premalignant lesions and conditions 147
 psammomatoid ossifying fibromas 260
 primordial cyst *see* odontogenic keratocyst
 pulp
 age changes 53
 calcification 52
 capping 51
 disorders of 47–53
 effects of cavity preparation and filling materials 50–1
 healing 51–2
 necrosis 41, 49, 52, 57
 obliteration 52
 polyp 50
 stones 52
 pulpitis 47–50
 aetiology 47–8
 chronic hyperplastic 50
 clinical features 47
 histopathology 48–50
 internal resorption and 40
 periapical periodontitis and 57
 purpura, HIV-associated 170
 pyostomatitis vegetans 194
- radiation injury 176, 207, 250–1, 265
 radicular cyst 60, 68–72
 clinical and radiographic features 68–9
 contents 71
 expansion 71–2
 histopathology 70–1
 pathogenesis 69–70
 Ramsay–Hunt syndrome 156
 ranula 83
 Rb gene 140
 recurrent aphthous stomatitis (RAS) 176–80
 aetiology 178 (*table*), 178–9
 allergies and 178–9
 gastrointestinal diseases and 179
 haematological disorders and 179
 hereditary predisposition 178
 hormonal disturbance 179
 infective agents and 178
 stress and 178
 trauma and 178
 clinical features 177 (*table*), 177–8
 herpetiform 178
 major aphthae 177–8
 minor aphthae 177
- immunological, histopathological features 179–80
 pathogenesis 179–80
 Reed–Sternberg cells 113
 regional odontodysplasia 14–15
 residual cyst *see* radicular cyst
 resorption of teeth 38–41, 42–3, 60, 236, 253
 external 38–9, 40, 60
 internal 40–1
 retinoblastoma gene 140
 reverse smoking 124, 138
 rhabdomyosarcoma 113
 rheumatoid factor 266
 rickets 252
 dental changes in 14, 252
 vitamin D resistant 14, 252
 rodent ulcer 147–8
 root
 caries 30–1
 fracture 43
 invagination 225
 resorption *see* resorption of teeth
 Rushton bodies 70
- salivary calculi 207–8
 salivary gland
 accessory 205
 adenomas 212–15
 age changes 218
 aplasia 205
 atresia 205
 calculi 207–8
 carcinomas 215–18
 diseases 205–18
 ductal papillomas 215
 duct obstruction 207–8
 heteropia 205
 HIV-associated disease 170, 211
 inclusion disease 207
 tumours 212–18
 classification 212, 212 (*table*), 218 (*table*)
 salivary mucoceles
 mucous extravasation 82
 mucous retention 82
 salivary scintiscanning 210
 sarcoidosis 193, 194, 207
 and orofacial granulomatosis 193
 sarcoma
 chondrosarcoma 259
 fibrosarcoma 108, 245
 Kaposi's 109, 169–70
 leiomyosarcoma 113
 liposarcoma 108
 odontogenic 223 (*table*), 232
 osteosarcoma 255, 258–9
 in Paget's disease 255
 schwannoma 11–12
 scleroderma 195–6
 sclerosis
 dentine 28, 36, 37, 43, 51
 progressive systemic 195–6
 scurvy 89, 97 (*table*)
 sebaceous glands 191
 Serres, glands of 67
 sex hormones, and periodontal disease 89, 89 (*table*), 97 (*table*)
- shell-teeth 13
 shingles (herpes zoster) 155–6
 sialadenitis 205–7
 acute bacterial 205–6
 acute parotitis 205
 chronic bacterial 206
 chronic sclerosing 206
 minor glands 207
 myoepithelial 210, 211
 postirradiation 207
 recurrent parotitis 206
 viral 206–7
 sialadenosis 211
 sialolithiasis 207–8
 sialometaplasia, necrotizing 208–9
 sialosis *see* sialadenosis
 sicca syndrome 209
 Sjögren syndrome 205, 209–11
 aetiology 210–11
 autoantibodies 210–11
 clinicopathology 209 (*table*), 209–10
 malignant lymphoma in 211
 primary 209, 211
 secondary 209, 211
 snail track ulcers 159
 snuff dipping 124, 138
 solitary bone cyst 80
 squamous cell carcinoma 135–47
 aetiology 138 (*table*), 138–41
 alcohol 139
 betel (pan) chewing 138–9
 chronic infections 140–1
 dental factors 140
 diet and nutrition 139–40
 immunosuppression 140
 occupation 140
 tobacco 138, 139
 ultraviolet light 140
 viruses 140
 clinical presentation 142–3
 epidemiology 136–8
 oncogenes and 141–2
 pathology 143–6
 prognosis and staging 146, 146 (*table*)
 tumour-suppressor genes and 141–2
 squamous odontogenic tumour 232
 Stafne's idiopathic bone cavity 81
 staining
 extrinsic, of teeth 41
 of mucosa 198
 Stephan's curves 22
 Stevens–Johnson syndrome 182
 stomatitis
 denture 164–5
 glandularis 207
 herpetic 153–5
 migratory (geographic) 176–80
 nicotina 122
 recurrent aphthous 176–80
Streptococcus mutans in dental caries 22, 23 (*table*), 31
 Sturge–Weber syndrome 109
 'sulphur' granules in actinomycosis 159
 supernumerary teeth 4 (*table*), 5, 242
 syndrome
 acquired immunodeficiency (AIDS) 166–71
 Albright 244

- angiomatous 109–10
 basal cell naevus 74–5
 Behçet 180
 Chediak–Higashi 96 (*table*)
 Crouzon 4 (*table*), 16
 Down 4 (*table*), 6, 35, 96 (*table*)
 Ehlers–Danlos 96 (*table*)
 Ellis–van Creveld 4 (*table*)
 Gardner 4 (*table*), 257–8
 Gorlin 74–5
 Hand–Schuller–Christian 260
 Heerfordt 194, 207
 Job 96 (*table*)
 Klinefelter 7
 McCune–Albright syndrome 244
 Melkersson–Rosenthal 193
 multiple endocrine neoplasia 111, 112
 myofascial pain dysfunction 266, 267
 oral–facial–digital 4 (*table*)
 Papillon–Lefèvre 96, 96 (*table*)
 Patterson–Kelly 124, 139
 Peutz–Jeghers 199, 200
 Plummer–Vinson 124, 139
 poly-X 7
 Ramsay–Hunt 156
 sicca 209
 Sjögren 205, 209–11
 Stevens–Johnson 182
 Surge–Weber 109
 syphilis 141, 147, 159–60
 and enamel hypoplasia 9–10
 oral epithelial atrophy in 141, 159
 squamous cell carcinoma in 141, 160
- tattoo
 amalgam 198–9, 200
 mucosal 198
- taurodontism 6–7
- teeth
 age changes 43–4
 conescence 7–8, 15
 connation (double) 7, 8
 cracked and pulpitis 47
 discoloration 40 (*table*), 41–2, 200
 disorders of eruption 35–6
 of shedding 35–6
 disturbances
 in form 6–8
 in number 3–5, 4 (*table*)
 in size 5–6
 in structure 8–16
 double 7, 8
 fractured 43
 ghost 14–15
 impaction 35–6, 242
 natal 35
 neonatal 35
 persistence of deciduous 35
 pink spot 40
 premature eruption 35
 premature loss 35
 and prepubertal periodontitis 35, 96
 reimpaction 36
 reimplantation 42, 43
 resorption *see* resorption of teeth
 retarded eruption 35, 241, 242
- ‘root-less’ 14
 shell 13
 socket healing 247, 248
 supernumerary 4 (*table*), 5, 242
 supplemental 5
 taurodont 6–7
 transplantation 42–3
 Turner 9
 wear of 36–7, 38
 abrasion and 36–7
 attrition and 36
 erosion and 37
- telangiectasia, hereditary haemorrhagic 110
- temporomandibular joint
 age changes 268
 developmental disorders 265
 disc displacement 267
 diseases 265–8
 inflammatory disorders 265–6
 loose bodies 268
 neoplasms 268
 osteoarthritis 266–7
 structure 265
- tetracycline pigmentation 41–2, 200
- thrush 162–3
- thyroid, lingual (thyroglossal cyst) 83–4
- TNM, clinical staging 146, 146 (*table*)
- tobacco
 chemical insult 121, 124, 138–9
 chewing 36, 121, 124, 138–9
 and leukoplakia 119, 124
 and periodontal disease 89
 smokeless 124, 138
 smoking 121–2, 124, 138, 163, 178, 198, 200
 and squamous cell carcinoma 138, 139
 thermal insult 122
- tongue
 antibiotic sore 163
 black hairy 198
 fissured 192
 geographic 192
 scrotal 192
- torus
 mandibularis 256–7
 palatinus 256–7
- transverse clefts in dentine caries 30
- trismus 268, 268 (*table*)
- trisomy 21 *see* Down syndrome
- true cementoma 235–6
- tuberculosis 160–1
- tumours
 adenomatoid odontogenic 233
 adipose tissue 108
 bone 257 (*table*), 257–60
 brown, of hyperparathyroidism 251, 252, 256
 calcifying epithelial odontogenic 232
 clear cell odontogenic 232
 congenital gingival granular cell 236
 dentinogenic ghost cell 234
 fibrous tissue 107–8
 in Gardner syndrome 257–8
 granular cell 112
 melanotic neuro-ectodermal of infancy 236
 metastatic 261
 muscle 113
- odontogenic 228–36
 peripheral nerves 110–12
 salivary gland 212–18
 squamous odontogenic 232
 suppressor genes 124–5, 141–2
 vascular tissue 108–10
 Warthin 214, 215
 Turner teeth 9
 tylosis 121 (*table*)
 Tzanck cell 181
- ulceration
 aphthous 176–80
 atypical, in HIV 170
 classification and causes 175, 175 (*table*)
 oral 175–86
 recurrent 176–80
 traumatic 175–6
 ulcerative colitis 179, 194
- ulcers
 eosinophilic 176, 177
 factitious 176
 herpetiform 178
 major aphthous 177–8
 minor aphthous 177
 radionecrotic 176
 snail track 159
 uveoparotid fever 194
- varicella-zoster virus 155–6, 168
- varicosities
 ranine 109
 sublingual 109, 191, 201
- vegetable granuloma 250
- verapamil, gingival hyperplasia 89 (*table*), 97, 97 (*table*)
- verruca vulgaris 135–6
- verruciform xanthoma 196
- verrucous carcinoma 146–7
- verrucous hyperplasia 147
- ‘verrucous’ leukoplakia 123, 147
- vesiculobullous diseases 180–6
 classification 180, 180 (*table*)
 immunological findings, subepithelial bullae 185 (*table*)
- Vincent’s gingivitis *see* gingivitis, acute necrotizing ulcerative
- viral infections
 HIV-associated 168, 169, 170
 oral mucosa 153 (*table*), 153–7, 168
 chickenpox 155
 cytomegalovirus 157, 168, 170, 207
 hand, foot, and mouth disease 156, 157
 herpangina 156
 herpes zoster 155–6
 herpetic stomatitis 153–5
 infectious mononucleosis 156
 measles 157
 salivary glands 206–7
- viruses in leukoplakia 124
- Warthin tumour 214, 215
- warts, viral 135–6
 HIV-associated 168

Wegener's granulomatosis 97 (*table*), 194–5,
196
wheat-sheaving of odontoblasts 51
white patches 119, 119 (*table*)
 definition of histopathological terms 120
 dermatological causes 122

hereditary conditions 120
leukoplakia 122–8
 traumatic keratosis 121–2
white sponge naevus 120
white spot lesion (enamel caries) 25–8
Wickham's striae 128

xerophthalmia 209
xerostomia 170, 197, 205, 209–10, 211
zones
 in dentine caries 28–30
 in enamel caries 26–7