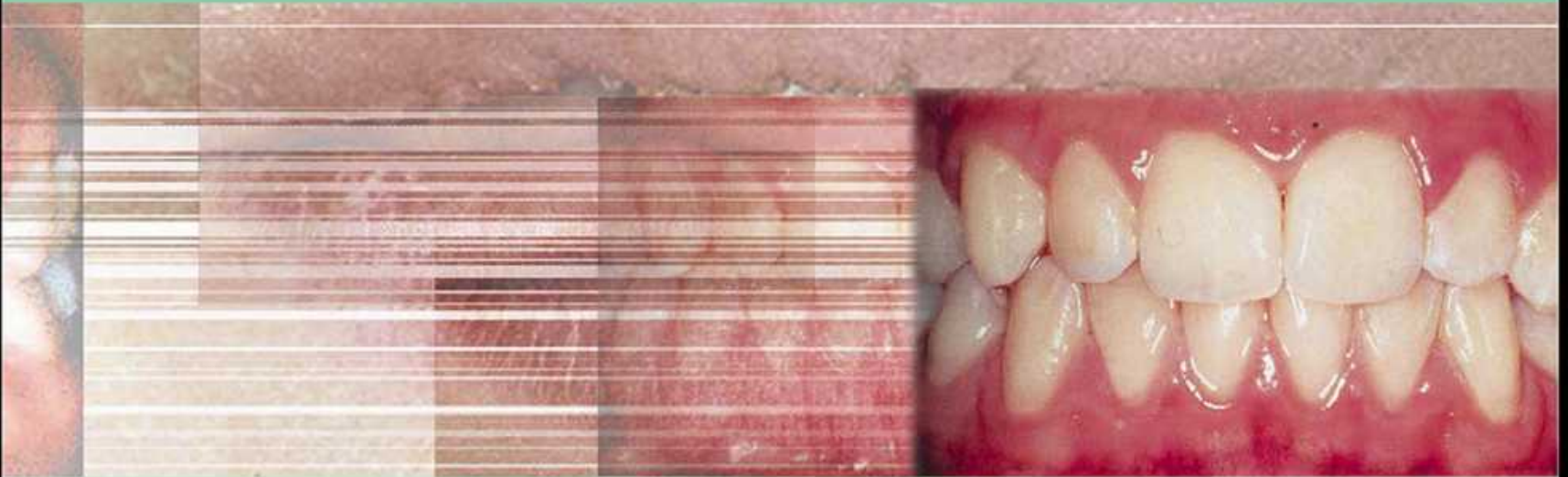
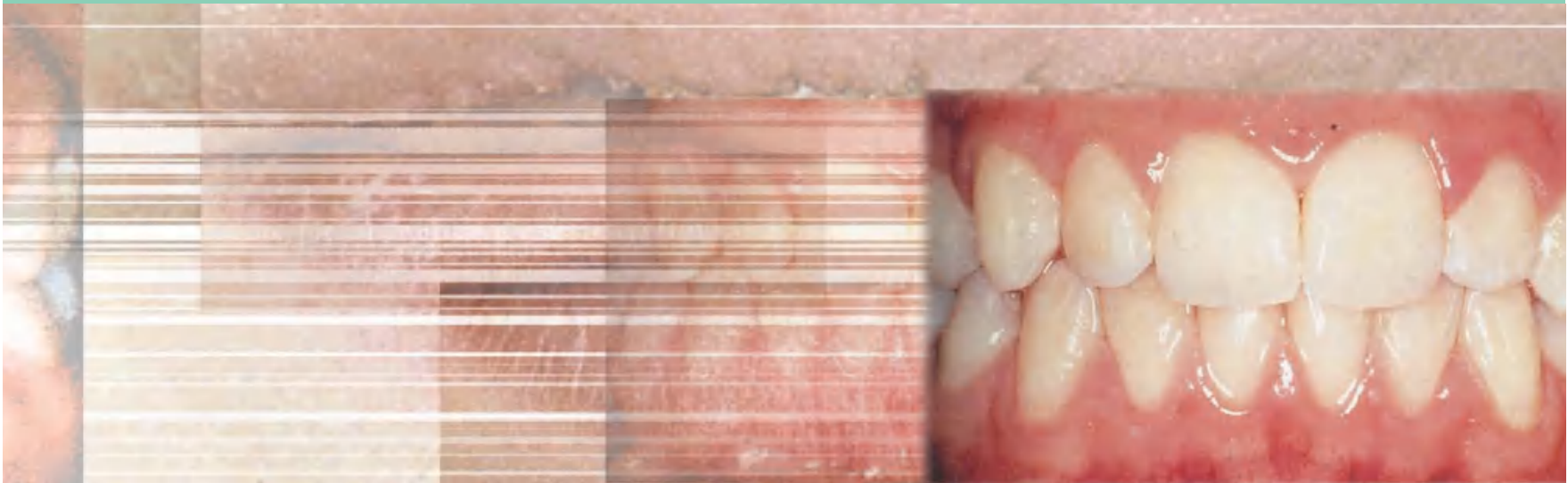


A COLOR ATLAS OF
OROFACIAL HEALTH AND DISEASE
IN CHILDREN AND ADOLESCENTS



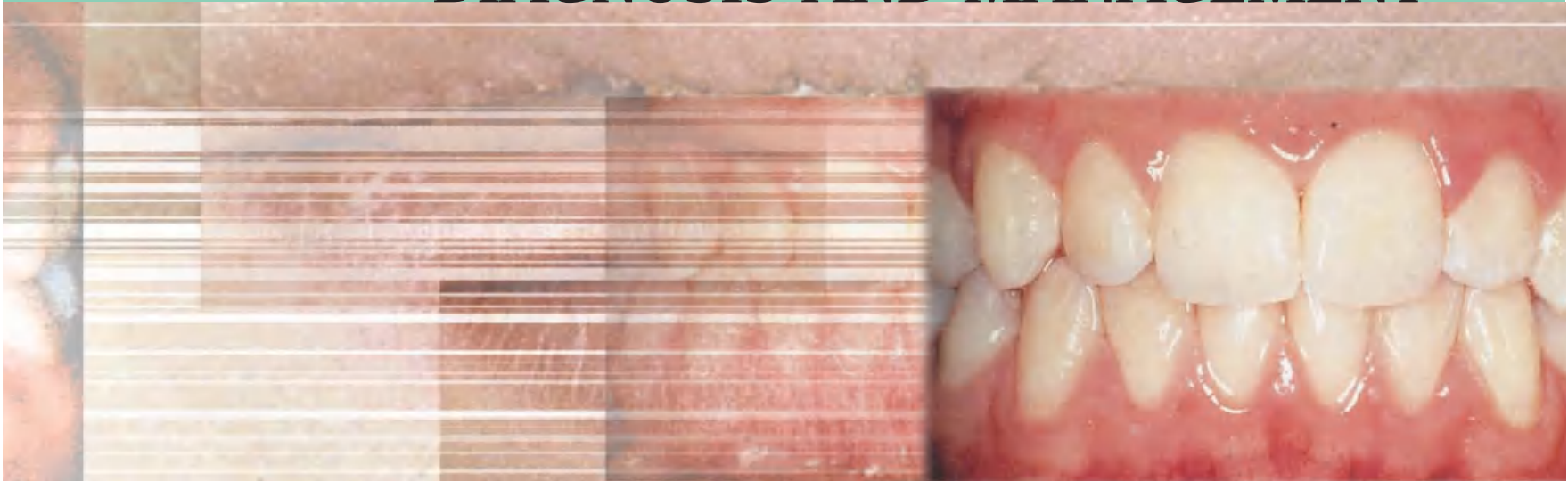
Also available as a printed book
see title verso for ISBN details

**A COLOR ATLAS OF
OROFACIAL HEALTH AND DISEASE
IN CHILDREN AND ADOLESCENTS**





A COLOR ATLAS OF OROFACIAL HEALTH AND DISEASE IN CHILDREN AND ADOLESCENTS DIAGNOSIS AND MANAGEMENT



Professor Crispian Scully CBE, MD, PhD, MDS, MRCS, FDSRCS, FDSRCSE, FDSRCPS, FFDRCSI, FRCPath, FMedSci
Eastman Dental Institute, University College London and Great Ormond Street Hospital for Children, University of London, London, Nuffield Orthopaedic Centre and John Radcliffe Hospitals Oxford, WHO Collaborating Centre for Oral Health, Disability and Culture, UK

Professor Richard Welbury PhD, MB BS, FDSRCS, FDSRCPS
Dental School, University of Glasgow, Glasgow, UK

Professor Catherine Flaitz DDS, MS
The University of Texas at Houston Health Science Center Dental Branch, Houston, Texas, USA

Professor Oslei Paes de Almeida PhD, DDS
University of Campinas Faculty of Odontology at Piracicaba, Piracicaba-SP, Brasil

I S I S
MEDICAL
M E D I A

This edition published in the Taylor & Francis e-Library, 2005.

“To purchase your own copy of this or any of Taylor & Francis or Routledge’s collection of thousands of eBooks please go to www.eBookstore.tandf.co.uk.”

First edition published 1994 by Mosby–Yearbook, St. Louis, Missouri, USA

Second edition © 2002, Isis Medical Media, a member of the Taylor & Francis group

Second edition published in the United Kingdom in 2002 by Isis Medical Media, The Livery House, 7–9 Pratt Street, London NW1 0AE

Tel.: +44 (0) 20 74822202
Fax.: +44 (0) 20 72670159
E-mail: info@dunitz.co.uk
Website: <http://www.dunitz.co.uk>

All rights reserved. No part of this publication may be reproduced, stored in a retrieval system, or transmitted, in any form or by any means, electronic, mechanical, photocopying, recording, or otherwise, without the prior permission of the publisher or in accordance with the provisions of the Copyright, Designs and Patents Act 1988 or under the terms of any licence permitting limited copying issued by the Copyright Licensing Agency, 90 Tottenham Court Road, London W1P 0LP.

Although every effort has been made to ensure that all owners of copyright material have been acknowledged in this publication, we would be glad to acknowledge in subsequent reprints or editions any omissions brought to our attention.

Crispian Scully, Richard Welbury, Catherine Flaitz and Oslei Paes De Aleida have asserted their right under the Copyright, Designs and Patents Act 1988 to be identified as the Authors of this Work.

ISBN 0-203-21555-9 Master e-book ISBN

ISBN 0-203-27189-0 (Adobe eReader Format)

Although every effort has been made to ensure that drug doses and other information are presented accurately in this publication, the ultimate responsibility rests with the prescribing physician. Neither the publishers nor the authors can be held responsible for errors or for any consequences arising from the use of information contained herein. For detailed prescribing information or instructions on the use of any product or procedure discussed herein, please consult the prescribing information or instructional material issued by the manufacturer.

A CIP record for this book is available from the British Library.

ISBN 1-84184-102-1 (Print Edition)

Distributed in the United States and Canada by:

Thieme New York
333 Seventh Avenue
New York, NY 10001
USA
Tel. 212 760 0888, ext 10

Distributed in the rest of the world by:

ITPS Limited
Cheriton House
North Way
Andover, Hampshire SP10 5BE, UK
Tel.: +44 (0)1264 332424
E-mail: reception@itps.co.uk

Composition by Inperspective

Printed and bound in Singapore

C

ontents

Preface	vii
1. The healthy mouth and normal variants	1
2. Congenital and hereditary disorders with sole or prominent orofacial involvement	15
3. Congenital and hereditary disorders with lesser orofacial involvement	43
4. Acquired disorders affecting the teeth	71
5. Acquired gingival and periodontal disease	105
6. Acquired mucosal disorders	123
7. Acquired salivary gland disorders	175
8. Acquired musculoskeletal disorders	183
9. Pain and neurological disorders	193
10. Orofacial lesions in major medical conditions	201
Further reading	224
Index	225



Preface

Pediatricians, general medical practitioners, general dental practitioners, dental specialists, dermatologists, oncologists, otorhinolaryngologists and many others are called upon to diagnose and treat children who have oral problems. The first edition of the Atlas, aimed at these practitioners, was extremely well received. We have improved, updated and expanded this second edition of Color Atlas of Orofacial Health and Disease in Children and Adolescents and hope that it will continue to be a useful source of assistance to health care professionals.

This edition, like the successful first edition, covers the presentation of the common orofacial disorders and a wide range of less common and some rare disorders. However, the number of authors has been increased with the inclusion of Professors Catherine Flaitz and Oslei Almeida, to geographically broaden the expertise, and a wider range of examples as well as new conditions have been added, increasing the pictorial content by over 20%. The text has also been updated and strengthened, with sections highlighting the common complaints, and now with a synopsis of diagnosis and management given under each condition.

Additions include choristoma, cocaine use, Coffin–Lowry syndrome, dentine dysplasia type II, foreign bodies, fragile X syndrome, graft versus host disease (GVHD), granular cell tumor, hypophosphatasia, Kabuki make-up syndrome, leukedema, lymphoepithelial cyst, median rhomboid glossitis, Morquio's syndrome, papillary hyperplasia, peripheral ossifying fibroma, plasminogen deficiency, Prader-Willi syndrome, retrocuspid papilla, severe combined immunodeficiency syndrome (SCID), superficial mucoceles, vitamin D resistant rickets and whistling face syndrome.

The layout has also been improved with separation of the congenital and hereditary disorders into those with sole or prominent orofacial involvement from those where orofacial lesions are a less marked feature. Pain and neurological conditions have been added, together with more background, and a new chapter highlights the orofacial diseases found in major medical conditions – in children these are mainly the hematological disorders including immunodeficiencies, and iatrogenic disease resulting from medical and surgical therapy.

We have arranged material by first considering the healthy mouth and normal variants and then discussing the obviously congenital and heritable disorders though, of course, few other conditions affecting the orofacial region do not have some genetic basis. These other conditions are covered in the remainder of the Atlas, which outlines diseases of teeth and their sequelae, gingival and periodontal disease, mucosal disorders, salivary gland disorders, musculoskeletal disorders, pain and neurological disorders, and oral lesions in medical conditions such as hematological disorders, immunodeficiencies and other patients with special needs.

With a few exceptions we have restricted the Atlas to intraoral photographs and radiographs though, of course, not only must the whole mouth, head and neck always be examined, but the patient treated as a whole person. Because there is no reliably logical classification available

we elected to present common complaints first and then to arrange material alphabetically within each of these sections. The number of illustrations of any particular condition is not necessarily a reflection of the importance of the disorder. Occasional illustrations show the fingers of ungloved hands often of the patient or carer; clinicians must of course now always wear gloves during patient care.

This Atlas provides treatment recommendations for the most common oral diseases tailored to the pediatric age group (Flaitz CM, Baker KA. *Dent Clin N. Amer* 2000; 44: 671–696). When possible, more than one drug alternative is given for each of the different oral conditions for an improved success rate. It is essential for the clinician to understand that this should be used as a guide for managing oral and perioral lesions in children and adolescents. Specific dosages and formularies of drugs may require modification in the young child and always must be checked with a pharmacopeia. Consultation with a primary care physician and pharmacist is often needed to ensure the best possible outcome, especially when immunosuppressive drugs are indicated. Most importantly, patients with oral lesions that do not respond to therapeutic protocols should be referred to the appropriate specialist for definitive diagnosis and/or treatment. Management may be a challenge for a variety of reasons. Compliance issues are affected by dosing schedules, ease of administration, taste and texture of the agent, cooperation of the child and unpleasant side-effects. Other important issues concerning the child patient include a paucity of drug studies demonstrating the effectiveness of the therapeutic protocols and the appropriate dosing of medications based on the weight and age and health of the child.

We are grateful to our patients and to colleagues who have helped us with some material, particularly Mr Brian Avery (Middlesborough, UK), Professor Robert Berkowitz (Washington, USA), Mr NE Carter (Newcastle, UK), Professor A Craft (Newcastle, UK), Dr John Eveson (Bristol, UK), Dr PH Gordon (Newcastle, UK), Dr Mark Griffiths (Bristol, UK), Dr John Jandinski (New Jersey, USA), Dr Jane Luker (Bristol, UK), Dr RI Macleod (Edinburgh, UK), Professor John Murray (Newcastle, UK), Dr Anita Nolan (Newcastle, UK), Dr June Nunn (Newcastle, UK), Professor Stephen Porter (London, UK), Professor Stephen Prime (Bristol, UK) and Miss CA Reid (Newcastle, UK). A few of the illustrations have also appeared in *A Colour Atlas of Stomatology* (C Scully and S Flint) or *Colour Atlas of Oral Disease* (C Scully, S Flint, SR Porter) and in this respect we are particularly grateful to Martin Dunitz (London), Dr Stephen Flint (Dublin) and Professor Stephen Porter (London).

June 2001
Crispian Scully
Richard Welbury
Catherine Flaitz
Oslei Paes de Almeida

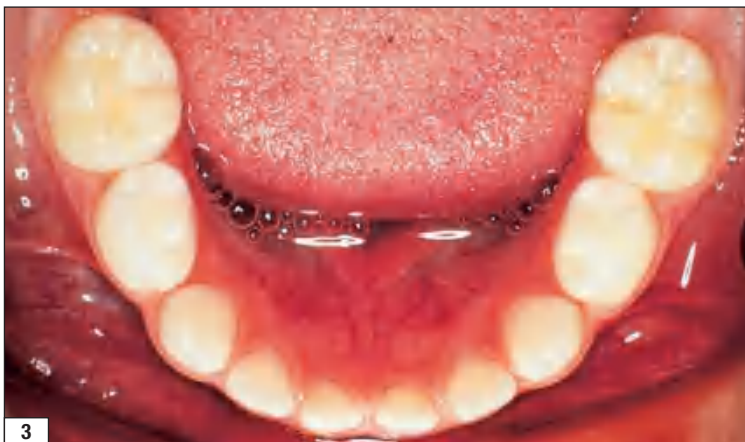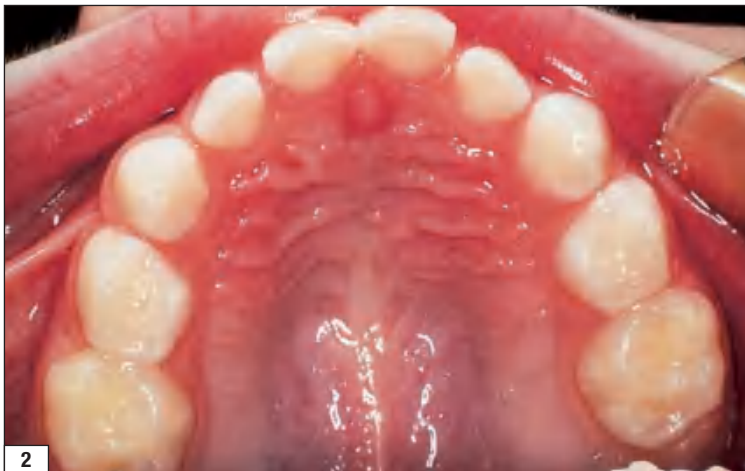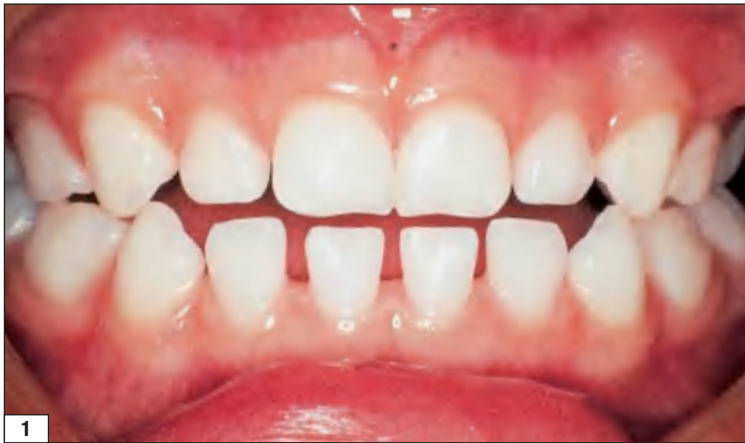1

The healthy mouth and normal variants

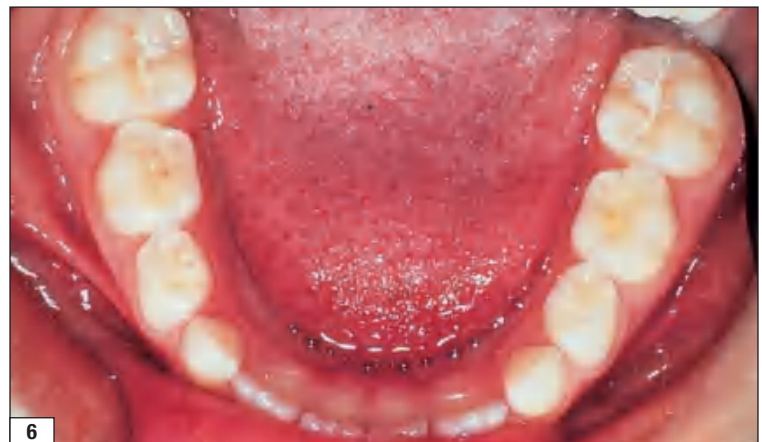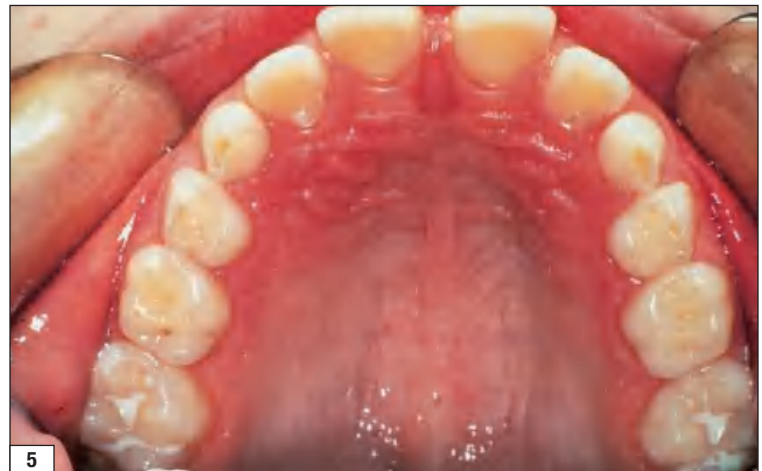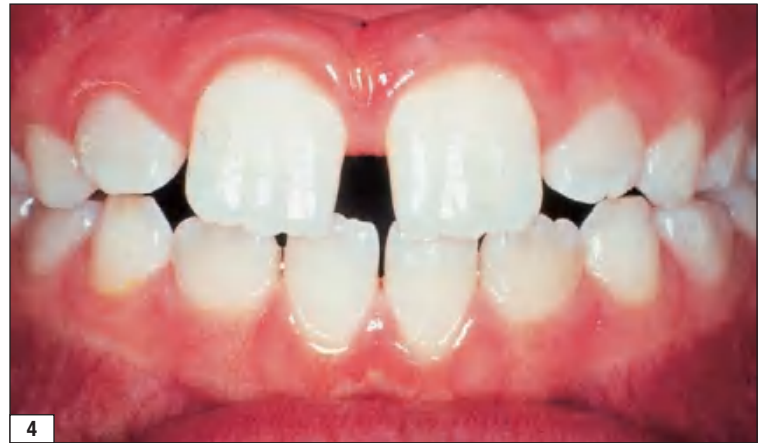TEETH

The teeth (Figs 1–9) develop from ectoderm. At about the sixth week of intrauterine life the oral epithelium proliferates over the maxillary and mandibular ridge areas to form *primary epithelial bands*, which project into the mesoderm, and produce a *dental lamina* in which discrete swellings appear – the *enamel organs* of developing teeth. Each enamel organ even-

tually produces tooth enamel, and the mesenchyme, which condenses beneath the enamel organ (actually neuroectoderm), forms a dental papilla, which produces the dentine and pulp of the tooth. Tooth development begins in the fetus at about 28 days *in utero*. Indeed, all the deciduous and some of the permanent teeth commence development in the fetus. The enamel organ together with the dental papilla constitute the *tooth germ*, and this becomes surrounded by a mesenchymal dental follicle, from

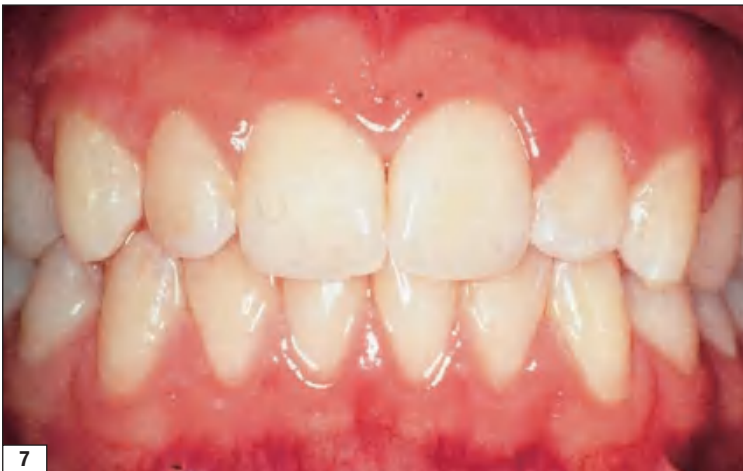

Figures 1–3. The primary dentition. Primary teeth are whiter, smaller and more bulbous than permanent teeth. Except in severely crowded mouths there is normally some spacing between primary anterior teeth.

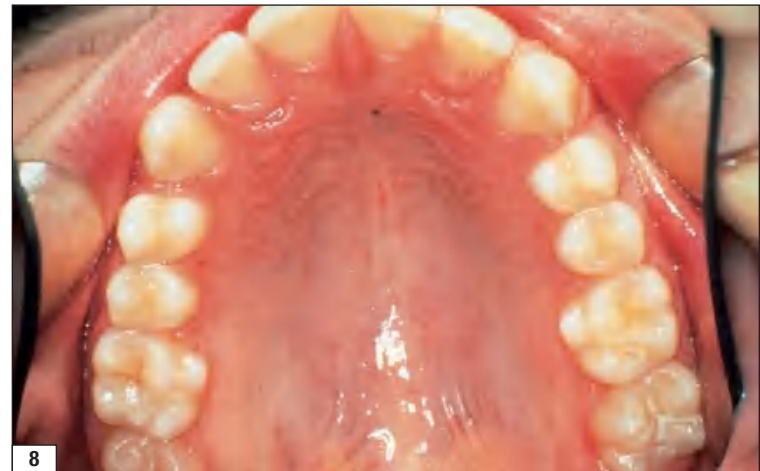

Figures 4–6. The mixed dentition. Permanent incisors have succeeded primary incisors. The permanent molar teeth (fissure-sealed) have erupted behind the primary molar teeth.

4 OROFACIAL HEALTH AND DISEASE IN CHILDREN AND ADOLESCENTS



Figures 7–9. The permanent dentition. Permanent canine teeth have succeeded primary canines and permanent premolars have



succeeded the primary molars.

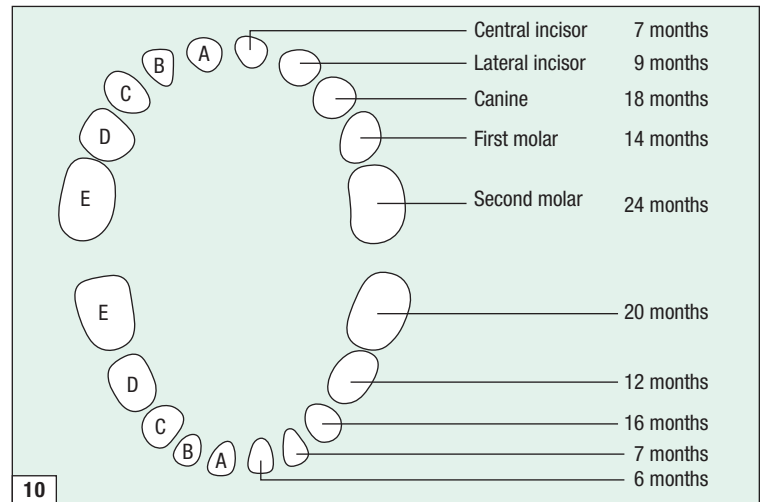
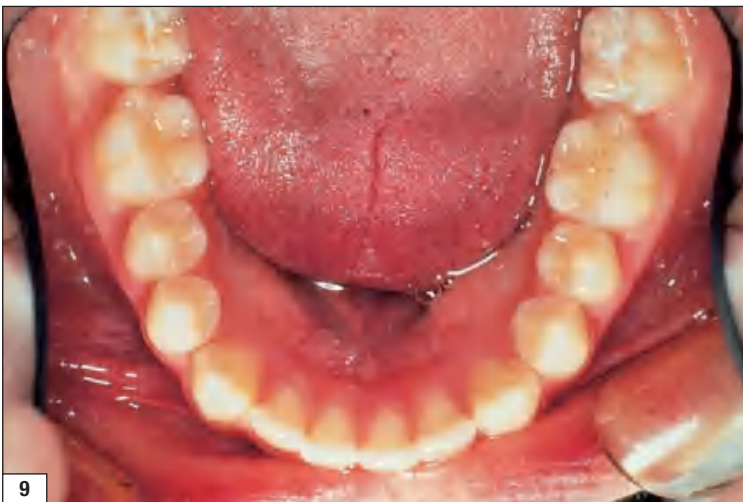


Figure 10. Average eruption times: primary dentition.

which the periodontium forms – ultimately to anchor the tooth in its bony socket. Mineralization of the primary dentition commences at about 14 weeks *in utero* and all primary teeth are mineralizing by birth. Permanent incisor and first molar teeth begin to mineralize at, or close to, the time of birth, mineralization of other permanent teeth starting later. Tooth eruption occurs after crown formation and mineralization are largely complete but before the roots are fully formed (see Figs 10, 11 and Table 3).

There are ten deciduous (primary or milk) teeth in each jaw: all are fully erupted by the age of about 3 years (Figs 10, 11). The secondary or permanent teeth begin to erupt at about the age 6–7 years and the primary teeth begin to be slowly lost by normal root resorption. However, some primary teeth may still be present at the age of 12–13 years. The full permanent dentition consists of 16 teeth in each jaw: normally most have erupted by about 12–14 years of age, but the last molars (third molars or wisdom teeth), if present, often erupt later or may impact and/or never appear in the mouth.

Common sensation from the teeth is conveyed by the trigeminal nerve. The upper teeth are supplied by the superior alveolar nerves (branches of the maxillary division of the trigeminal nerve) while the lower teeth are supplied by the inferior alveolar branch of the mandibular division of the trigeminal nerve.

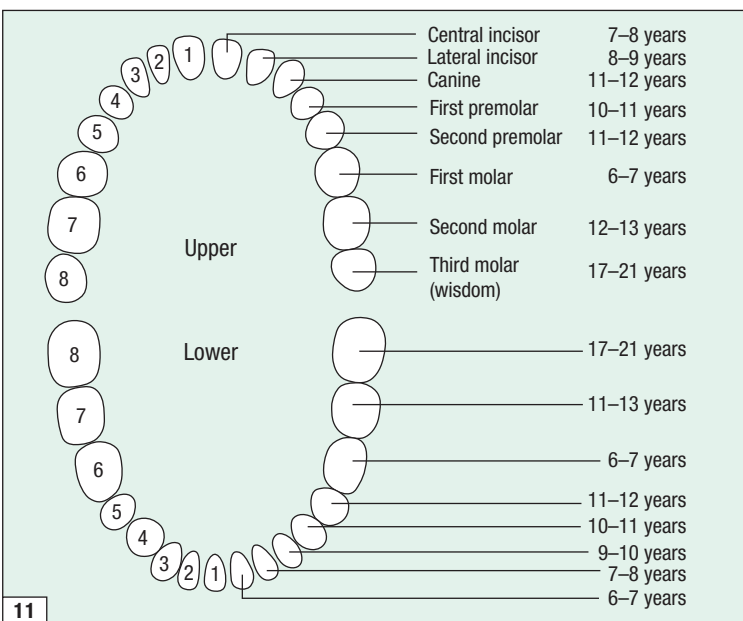


Figure 11. Eruption times: permanent dentition.

Variation in tooth eruption times

A delay in eruption of up to 12 months may be of little or no significance in an otherwise healthy child. Localized variations often result from local factors, such as impaction against a tooth in the path of eruption caused, for example, by insufficient space in the dental arch. Impaction and ectopic positioning most often occur in the permanent dentition, especially in the third molar, second premolar and canine regions, because these are the last teeth to erupt.

Teething

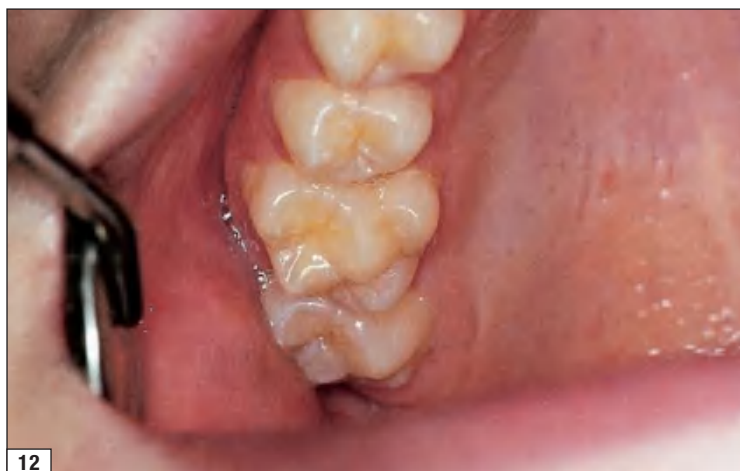Eruption of primary teeth may be preceded by a bluish gingival swelling, usually caused by a transient hematoma, rarely an eruption cyst, which usually ruptures spontaneously (see p. 85). 'Teething' describes tooth eruption associated with localized swelling and erythema of the alveolar ridge. Less frequently, irritability, disturbed sleep, cheek flushing, drooling, mild pyrexia and/or a circumoral rash may develop. Teething does not cause mouth ulcers, diarrhea, otitis media or respiratory infections, such as bronchitis; however, these diseases may occur coincidentally.

Diagnosis

Diagnosis is clinical.

Management

Reassurance only is required. Systemic analgesics, such as acetaminophen/paracetamol, and teething gels may offer some relief. The child should be evaluated for other medical causes if marked or prolonged constitutional signs and symptoms are present.



12

Figure 12. Prominent palatal cusp on a first maxillary permanent molar (cusp of Carabelli).

Cusp of Carabelli

Cusp of Carabelli (Fig. 12) is an anatomical variant with an accessory palatal cusp on the upper deciduous or permanent molars.

Diagnosis

Diagnosis is clinical.

Management

Reassurance only is required.

6 OROFACIAL HEALTH AND DISEASE IN CHILDREN AND ADOLESCENTS

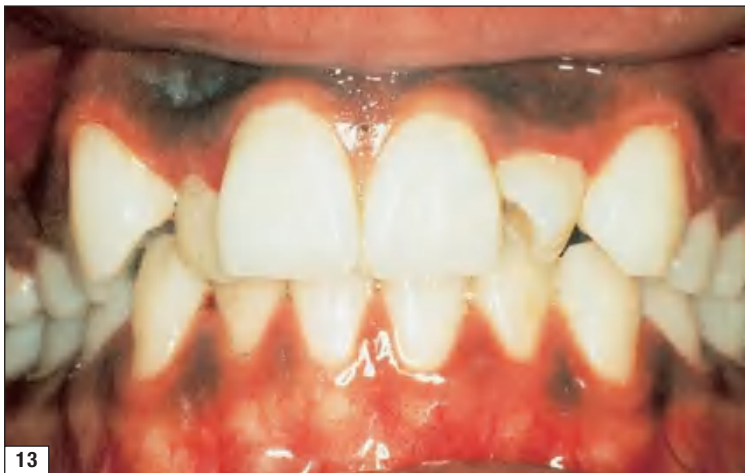MUCOSA

Racial pigmentation of mucosa

There is no direct correlation between skin color and oral pigmentation (Figs 13, 14), which may be seen in races with increased melanin pigmentation and others – such as those of southern European descent. Although any site may be affected, the attached gingiva and buccal mucosa are the most common sites of involvement. The intensity of the oral pigmentation often increases with age and local irritation.

Diagnosis

Diagnosis is clinical.



Figures 13, 14. Racial pigmentation.

Management

Reassurance only is required.

Lining mucosa

Lining mucosa (buccal, labial and alveolar mucosa, floor of mouth, ventral surface of tongue, soft palate, lips) is nonkeratinized with broad rete ridges and connective tissue papillae and abundant elastic fibers in the lamina propria and is fairly mobile. Depending on the race/ethnicity of the child, the pink mucosal coloring may be interspersed with patches of tan, brown, gray or black.

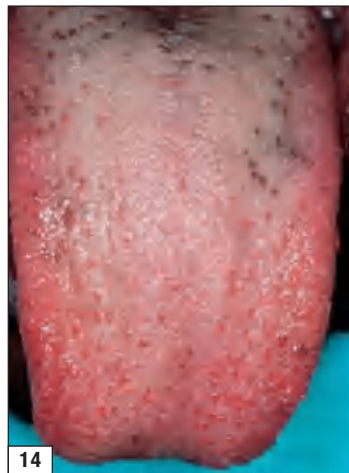

Figure 14. Scattered pigmented fungiform papillae and mild coating of the dorsal tongue are observed in this young black child.

Leukoedema

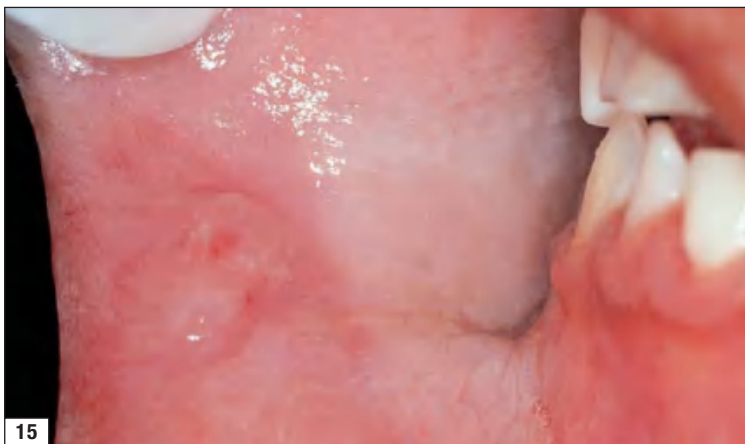Leukoedema (Figs 15, 16) is a benign congenital condition resulting in a filmy white and wrinkled appearance of the mucosa. Considered to be a variant of normal, this common entity is more prominent in children of color. It is most obvious on the buccal and labial mucosa with a bilateral distribution and tends to fade or disappear when the mucosa is stretched.

Diagnosis

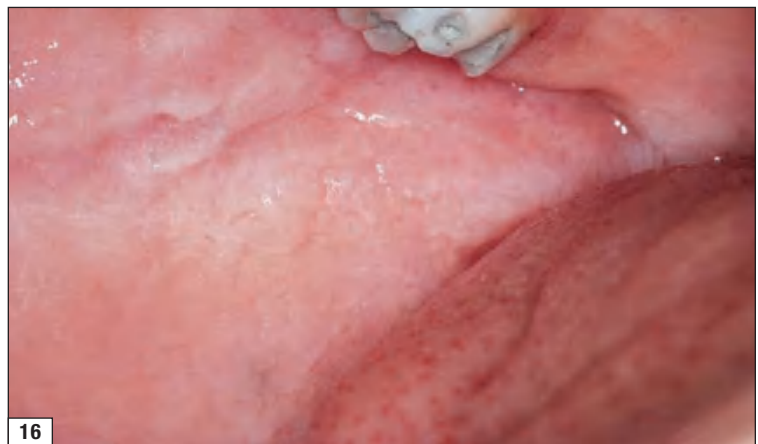Diagnosis is clinical.

Management

Reassurance only is required.



Figures 15, 16. Leukoedema.



Sebaceous glands (Fordyce granules or spots)

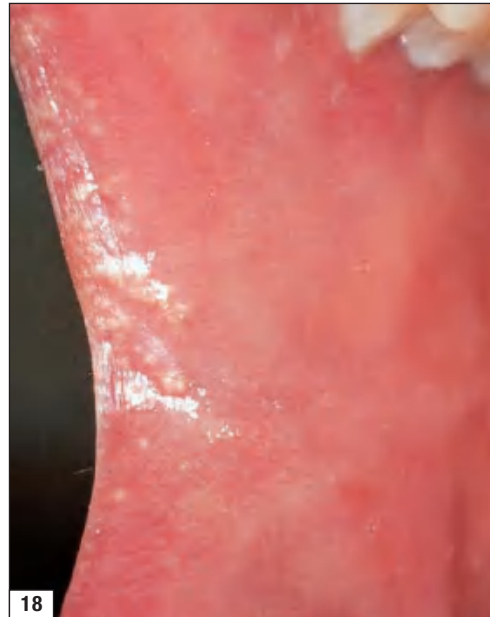
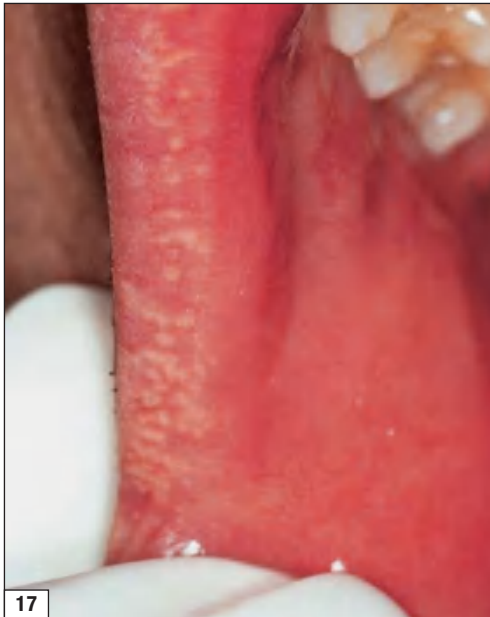Fordyce granules or spots (Figs 17, 18) may be seen as creamy-yellow dots along the border between the lip vermilion and the oral mucosa or in the buccal mucosa, and are not associated with hair follicles. They are not usually clinically evident until after the age of 3 years, increasing during puberty and then again in later adult life. Probably 50–80% of the adult population have them, but they are often invisible in the young child. They are totally benign, although they may be confused with thrush in a child.

Diagnosis

Diagnosis is clinical.

Management

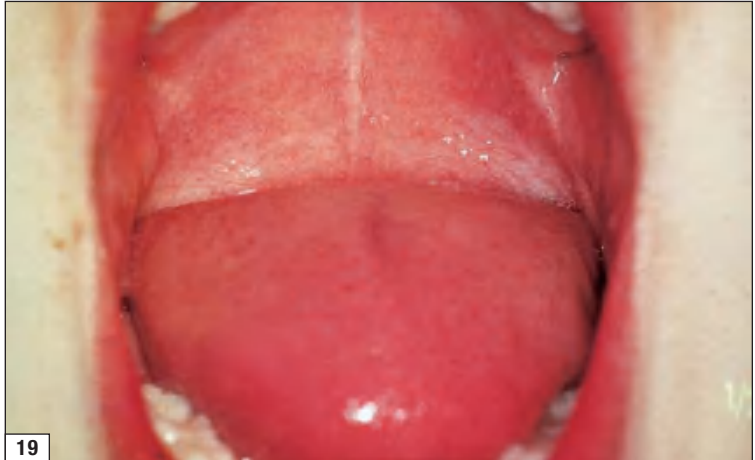Reassurance only is required.



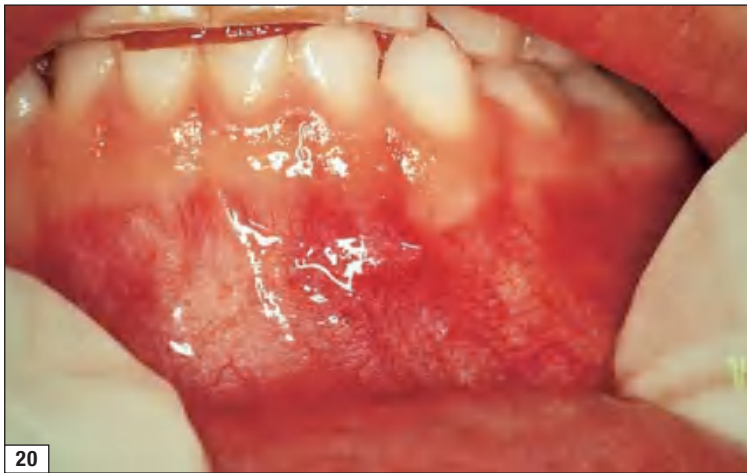Figures 17, 18. Fordyce granules.

Masticatory mucosa

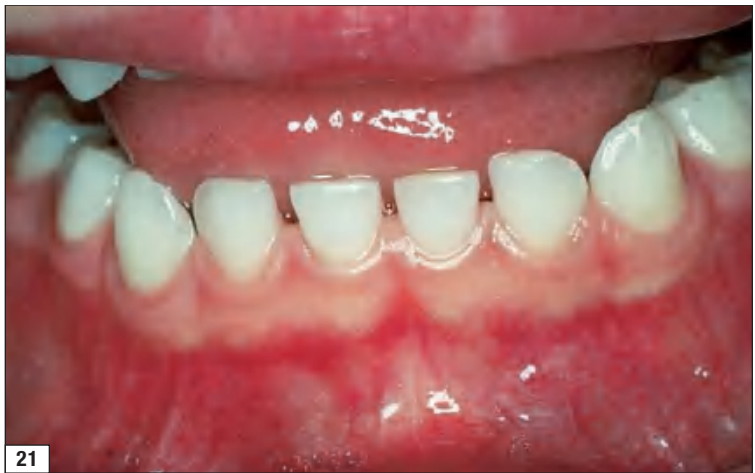Masticatory mucosa (hard palate, gingivae; Figs 19–23), is adapted to pressure forces and friction and keratinized with numerous tall rete ridges and connective tissue papillae and little submucosa; it is tightly bound down. The alveolar bone, which bears the teeth, is covered by the gingivae, or gum which, in health are pink, stippled and tightly bound down, and form a close fitting cuff, with a small sulcus (gingival crevice) around the neck of each tooth. Depending on the race/ethnicity of the child, the pink mucosal coloring may be interspersed with patches of tan, brown, gray or black.



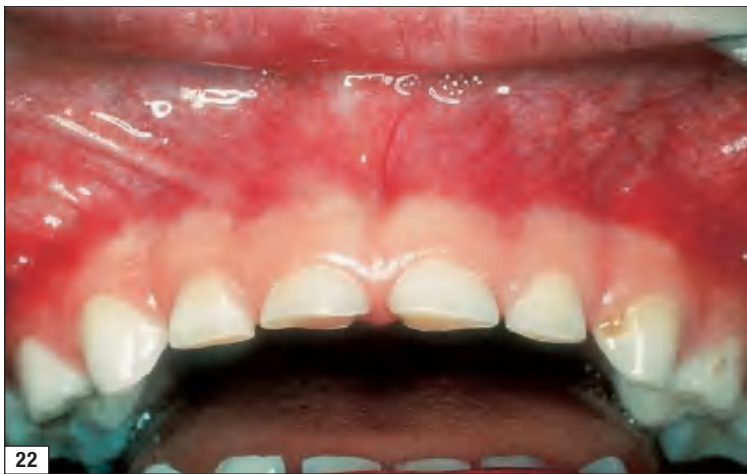19
Figure 19. Normal palate.



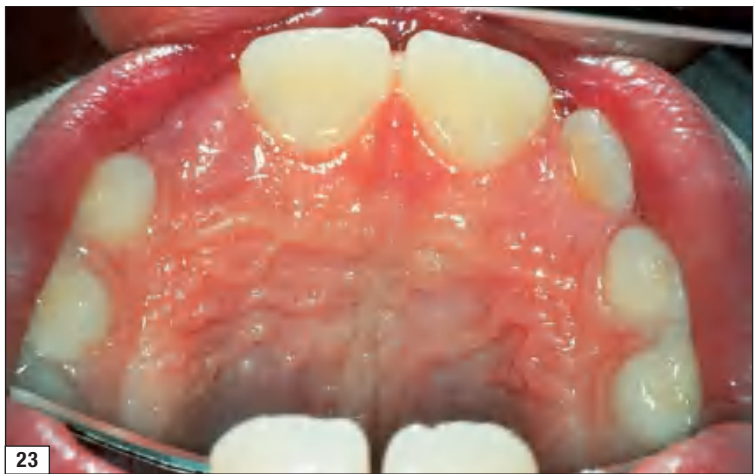20
Figure 20. Normal vestibular and gingival mucosa.



21
Figure 21. Normal mandibular labial gingivae.



22
Figure 22. Normal maxillary labial gingivae.



23
Figure 23. Normal palatal gingivae.

Retrocuspid papilla

A retrocuspid papilla is a sessile nodule (Fig. 24) with a smooth or stippled surface that occurs bilaterally on the lingual attached gingiva, adjacent to the mandibular canines. Occurring in 50% of children, this normal gingival variant typically regresses with age.

Diagnosis

Diagnosis is clinical.

Management

Reassurance only is required.

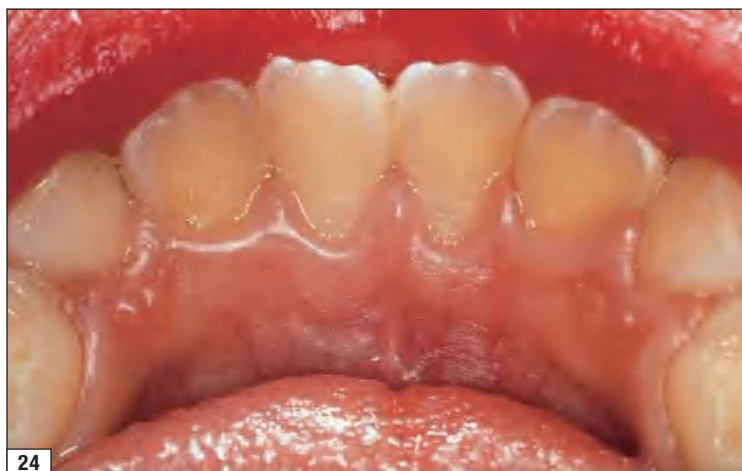

Figure 24. Retrocuspid papillae are an anatomical variation of the lingual gingiva, adjacent to the mandibular canines.

Specialized mucosa

Specialized mucosa on the dorsum of the tongue, adapted for taste and mastication, is keratinized, with numerous rete ridges and connective tissue papillae, abundant elastic and collagen fibers in the lamina propria and no submucosa (Fig. 25). The tongue is divided by a V-shaped groove, the sulcus terminalis, into an anterior two-thirds and a posterior one-third. Various papillae on the dorsum include the *filiform* papillae, which cover the entire anterior surface and form an abrasive surface to control the food bolus as it is pressed against the palate, and the *fungiform* papillae. The latter are mushroom-shaped, pink or red structures covered by nonkeratinized epithelium. In children of color, these papillae may be tan or brown (Fig. 14). They are scattered among the filiform papillae and have taste buds on their surface. Adjacent and

anterior to the sulcus terminalis are eight to twelve large *circumvallate* papillae, each surrounded by a deep groove into which open the ducts of serous minor salivary glands. The lateral walls of these papillae contain taste buds.

The *foliate* papillae consist of four to eleven parallel ridges, alternating with deep grooves in the mucosa, on the lateral margins on the posterior part of the tongue. There are taste buds on their lateral walls. These papillae may become inflamed (foliate papillitis; Fig. 26)

The lingual tonsils are found as oval prominences with intervening lingual crypts lined by nonkeratinized epithelium. They are part of *Waldeyer's oropharyngeal ring* of lymphoid tissue. Frequently it is not possible to distinguish between the lingual tonsils and foliate papillae.

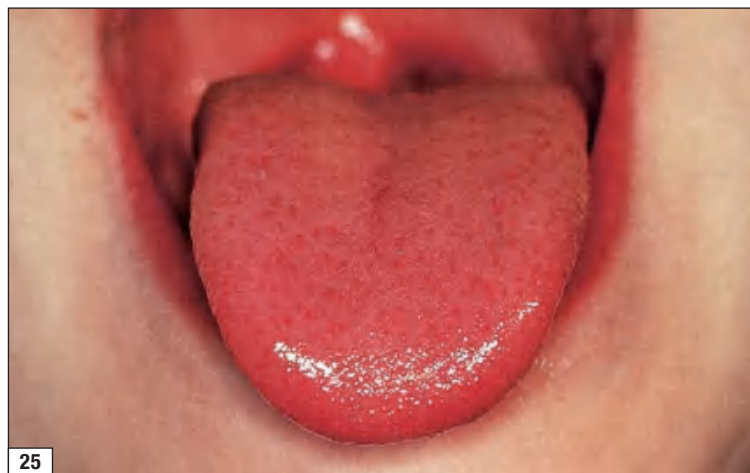


Figure 25. Normal tongue.

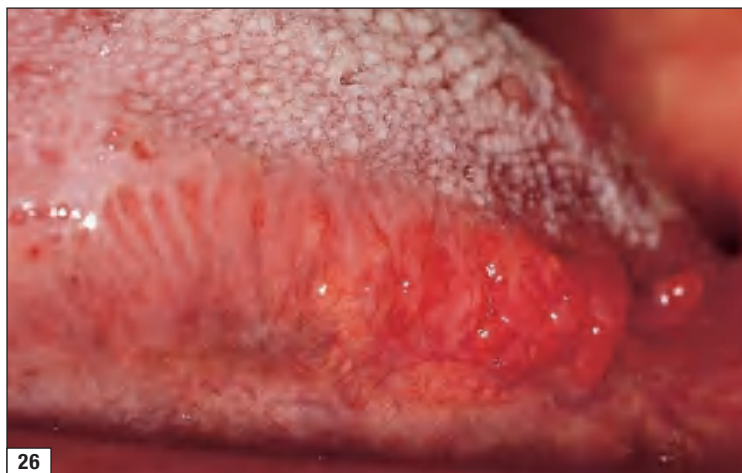


Figure 26. Enlarged foliate papillae (papillitis).

BONE

The jaw bones (mandible and maxilla) underlie alveolar bone, which is essential support for the teeth. The fibers of the periodontal ligament attach at one end to the alveolus and at the other through cementum to the dentine surface of the tooth root. In the absence of teeth, the alveolar bone fails to develop or atrophies.

Torus mandibularis and torus palatinus

Tori (Fig. 27) are common benign bony enlargements of developmental origin, especially seen in the Asian population. There may be some association with parafunction, such as bruxism.

Mandibular tori are uni- or bilateral bony enlargements lingual to the lower premolars. Palatal tori are common bony masses, typically in the midline vault of the hard palate.

Diagnosis

Diagnosis is clinical.

Management

Reassurance only is required.

Temporomandibular joints

The temporomandibular joints (TMJs) are diarthrodial joints between the condylar fossa in the temporal bone, and the mandibular condyle. Masticatory movements are controlled by the medial and lateral pterygoid muscles, the masseter, the temporalis and the mylohyoid and digastric muscles.

MUSCLES

The masticatory muscles include the masseters, temporalis, and pterygoid muscles, with a lesser contribution from digastric and mylohyoid

SALIVARY GLANDS

The major salivary glands are the parotid, submandibular and sublingual glands, but minor glands are scattered throughout the oral cavity, particularly in the lower lip and palate. The secretions from the different glands differ – for example the submandibular saliva contains far

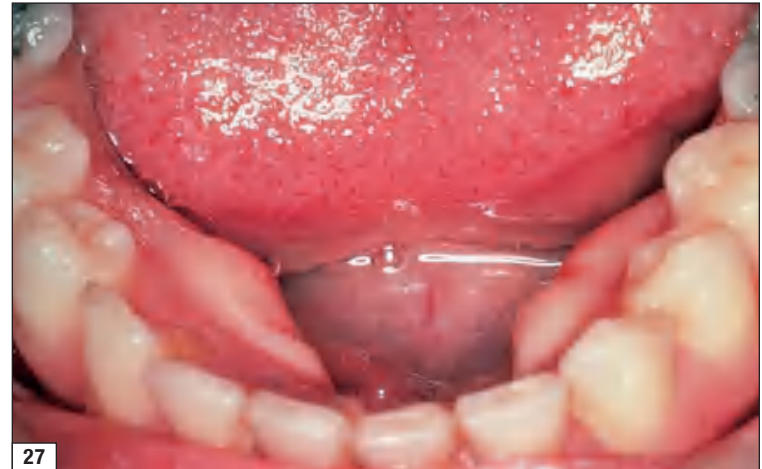

Figure 27. Pronounced bilateral mandibular tori on the lingual side of the premolars in a Caucasian adolescent.

more mucus than parotid saliva, which is serous. Secretion is controlled via the glossopharyngeal (parotid) or chorda tympani (submandibular/sublingual) nerves. Normally clear saliva can be expressed from the major ducts or stimulated with citric acid and at rest there is a pool of clear saliva in the floor of the mouth. A 'dental' mirror slides easily over the oral mucosa when salivation is normal.

NERVE SUPPLY

Trigeminal nerve

Common sensation from the orofacial region is conveyed by the trigeminal nerve. This nerve supplies sensation to most of the scalp, face and mouth. The two roots of the trigeminal nerve emerge at the pons and enter Meckel's cave at the tip of the petrous temporal bone and the foramen lacerum, where the ganglion (Gasserian ganglion) of the sensory root lies. Motor fibers run only with the mandibular division.

Maxillary division

The maxillary division of the trigeminal nerve runs for a short distance in the base of the cavernous sinus, giving off a meningeal branch to the dura mater of the middle cranial fossa. It leaves the middle cranial fossa through the foramen rotundum in the great wing of the sphenoid bone to enter the pterygopalatine fossa, which it crosses to leave through the inferior orbital fissure as the infraorbital nerve.

The branches of the maxillary division in the pterygopalatine fossa are the:

- posterior superior alveolar nerve (to the upper molars and part of the maxillary antrum)
- palatine nerves (to the palate)
- nasal nerves (sphenopalatine nerves)
- pharyngeal nerves to the mucous membrane of the upper pharynx
- zygomatic nerve.

The zygomatic nerve enters the orbit by the inferior orbital fissure and divides into a posterior (temporal) branch, which enters the front of the temporal fossa behind the orbital cavity and then pierces the temporal fascia at the anterior margin of the temporal muscle to supply the skin between the eye and the ear. The other anterior (facial) branch appears through foramina on the facial surface of the zygomatic bone and supplies the overlying area of the skin. Parasympathetic fibers derived from the pterygopalatine ganglion run with the zygomatic nerve and join the lacrimal nerve as secretomotor fibers to the lacrimal gland.

The branches of the infraorbital nerve are:

- the middle and anterior superior dental nerves to the maxillary antrum, upper incisor, canine and premolar, teeth and buccal gingiva
- three terminal branches, the labial, nasal and palpebral nerves, which supply the upper lip, cheek and lower eyelid.

Mandibular division

The mandibular division of the trigeminal nerve contains sensory and motor fibers. It leaves the middle cranial fossa through the foramen ovale in the greater wing of the sphenoid bone to give off branches to the tensor palati and tensor tympani muscles, the otic ganglion, the medial pterygoid muscle and a recurrent sensory branch (nervus spinosus), which passes through the foramen spinosum to supply dura mater in the middle cranial fossa. The mandibular division lies on the outer surface of the tensor palati muscle with the otic ganglion between the nerve trunk and the muscle. Behind it lies the middle meningeal artery and laterally is the upper head of the lateral pterygoid muscle. The auditory (eustachian) tube lies close to the nerve trunk as it emerges from the foramen ovale.

The mandibular nerve trunk then divides into:

- a larger posterior division, giving off the auriculotemporal, inferior alveolar and lingual branches. The inferior alveolar nerves provides sensation to the lower teeth and associated structures.

- a smaller anterior division, which provides motor supply to the temporal, lateral pterygoid and masseter muscles and continues on as the sensory buccal nerve (long buccal nerve).

Taste sensation

The special sense of taste is mediated by specialized cells related to various supporting or sustentacular cells. Taste buds are found in the mucous membrane of the tongue, soft palate, fauces and pharynx, and in the newborn, on the lips and cheeks. Taste buds are oval bodies made up of groups of neuroepithelial and supporting cells. The neuroepithelial cells are rod-shaped with a peripheral hairlike process projecting into the taste pores at the surface of the overlying mucous membrane. The terminal branches of the nerve fibers subserving taste end in close relationship to these special cells. Studies of taste thresholds in human subjects commonly use sucrose for the sweet taste, vinegar or citric acid to produce sour taste sensations, and sodium chloride for the taste of salt. Detection and recognition thresholds can be measured by applying the selected solution to precise regions of the oral mucosa. The tongue is most sensitive for salt and sweet tastes. Sour and bitter tastes can be recognized on the tongue, but not as well as by the palatal mucosa. Salt and sweet tastes can also be appreciated on the palate, but higher solution concentrations are required.

Taste buds on the tongue are on the fungiform, circumvallate and foliate, but not filiform, papillae. The four fundamental varieties of taste sensation (sweet, bitter, sour and salt) do not appear to be detected by structurally different taste buds. The cells of the taste buds undergo continual renewal, with a life span of about 10 days. Renewal is altered by nutrition, hormonal status, age, drugs, radiation and other factors.

Taste sensation from the anterior two-thirds of the tongue and the palate is mediated by the lingual and palatine nerves, respectively. Taste fibers from the anterior two-thirds of tongue and secretomotor parasympathetic fibers to the submandibular and sublingual salivary glands pass with the lingual nerve for part of its distal course. Taste from the anterior two-thirds of the tongue is mediated via the chorda tympani nerve and runs with the facial nerve.

Taste fibers from the posterior one-third of the tongue pass in the glossopharyngeal nerve and to the nucleus solitarius. The taste fibers pass into the brain stem along the chorda tympani and greater superficial petrosal branches of the facial nerve, respectively. The central processes of the chorda tympani nerve bringing taste impulses from the anterior two-thirds of the tongue pass, as the nervus intermedius, to the solitary tract, through which the taste impulses are carried to the nucleus solitarius.

The taste buds of the epiglottis are innervated by the vagal nerve fibers whose cell bodies are situated in the nodose ganglion and whose central processes terminate once again in the nucleus solitarius.

These various 'taste' fibers passing to the nucleus solitarius form the solitary tract (tractus solitarius). The secondary neurones of the pathway for taste (from the nucleus solitarius to the thalamus) cross to be included in the medial lemniscus of the opposite side and, on reaching the level of the thalamus, end along with other secondary fibers from the head region. Tertiary, or third order taste fibers, project to the inferior part of the postcentral gyrus and the adjacent cortex of the insula. Pontine neurones also project to the 'feeding area' in the hypothalamus.

The flavor of food results from chemical stimulation of both taste buds and olfactory neurones. Free nerve endings in the nose, mouth and throat also contribute to an appreciation of food and there is a strong element from higher centers.

Motor supply to the orofacial region

Motor supply to the orofacial region is complex. The masticatory muscles are innervated mainly by the trigeminal nerve, the palatal musculature mainly by the glossopharyngeal and vagal nerves and the tongue muscles mainly by the hypoglossal nerve. The muscles of facial expression receive motor innervation from the facial nerve.

Speaking

The act of speaking is a highly coordinated sequence of movements of the muscles of respiration, larynx, pharynx, palate, tongue and lips. Articulation and phonation are therefore under direct control of the vagus (and adjacent nerves), facial nerve and hypoglossal nerves. As with all muscle activity, phonation and articulation are under higher control from pyramidal and extrapyramidal influences.

Swallowing

In normal swallowing, the activities of the striated muscle of the pharynx and upper esophagus are integrated with those of the smooth muscle of the lower esophagus.

The initial phase of swallowing is voluntary, under the control particularly of the glossopharyngeal nerve, with the vagus controlling further phases of swallowing. Normal swallowing is dependent on adequate mastication of large food masses, lubrication with fluids and saliva, unobstructed lumens of the pharynx and esophagus, and normal coordinated neuromuscular mechanisms of swallowing.

A sphincter formed by the cricopharyngeus prevents air from filling the esophagus during respiration while a lower esophageal sphincter stops gastric reflux.

Glossopharyngeal (IX) cranial nerve

The glossopharyngeal cranial nerve is attached to the medulla and passes through the jugular foramen where it has the jugular and petrosal ganglia. It then runs in the carotid sheath between the internal carotid artery and internal jugular vein. It leaves the carotid sheath and runs on the stylopharyngeus muscle deep to the external carotid and ascending palatine arteries to the upper border of the middle constrictor muscle, where it enters the oropharynx.

The chief branches of the glossopharyngeal nerve are:

- The tympanic branch, which joins with a branch of the facial nerve to form the tympanic plexus from which arises sensory branches to the mucous membrane of the middle ear, the tympanic antrum and the eustachian tube, and the lesser superficial petrosal nerve, which contains secretomotor fibers derived from the glossopharyngeal nerve and destined for the otic ganglion and the parotid salivary gland.
- The carotid branch, which descends to the carotid sinus and carotid body, carrying autonomic fibers involved in blood pressure regulation.
- The motor branch to the stylopharyngeus muscle.
- Pharyngeal (sensory) branches to the pharyngeal mucous membrane.
- Tonsillar branches, which ascend to the upper part of the pharynx and eustachian tube.
- Lingual branches, which pass to the posterior one-third of the tongue.

Vagus (X) and accessory (XI) cranial nerves

The vagus cranial nerve arises at the medulla and passes through the jugular foramen where it has a superior ganglion and lower down a large

inferior ganglion. The cranial part of the accessory nerve joins the vagus at the inferior ganglion and fibers are distributed with the pharyngeal and laryngeal branches of the vagus. The ganglia also communicate with the facial, glossopharyngeal, hypoglossal and sympathetic nerves. The vagus enters the carotid sheath between the internal jugular vein and the internal carotid artery to descend through the neck. On the right side the vagus enters the thoracic cavity after crossing the first part of the subclavian artery; on the left side after descending between the left common carotid and subclavian arteries it crosses in front of the aortic arch. On the right side the recurrent laryngeal branch loops around the subclavian artery; on the left side it passes around the arch of the aorta.

In the thorax, the vagus passes behind the hilum of the lung to form the esophageal plexus, from which trunks pass through the diaphragm in front of (left vagus) and behind (right vagus) the esophagus. The left vagus is distributed chiefly to the anterior surface and lesser curvature of the stomach, to the liver and to the gall bladder. The right vagus is distributed mainly to the stomach and midgut derivatives with branches to the celiac, splenic and renal plexuses.

The branches of the vagus nerve in the neck are:

- A recurrent meningeal branch to the dura mater of the posterior cranial fossa.
- The auricular nerve (of Arnold), which supplies the mucous membrane of the external auditory canal and the outer surface of the tympanic membrane.
- The pharyngeal branch, which contains motor fibers, mainly from the cranial part of the accessory nerve, to the constrictor muscles of the pharynx, and the palatopharyngeus, levator palati, palatoglossus and uvular muscles.
- The superior laryngeal nerve, which consists chiefly of fibers derived from the cranial part of the accessory nerve and gives an internal laryngeal (sensory) branch, and a motor branch (the external laryngeal) to the cricothyroid and inferior constrictor muscles.
- Upper and lower cardiac branches supplying autonomic (parasympathetic) control to the heart.
- Recurrent laryngeal nerves, which are motor to the muscles of the larynx (except for the cricothyroid) and sensory to the laryngeal mucous membrane below the vocal folds and the mucous membrane of the trachea. Some motor fibers to the lower part of the inferior pharyngeal constrictor may run in the recurrent laryngeal nerves.

The cranial part of the accessory nerve arises from the medulla and the spinal part from the spinal cord as far down as the attachment of the fifth cervical nerve. The spinal portion enters the foramen magnum and unites with the cranial part to form a common trunk, which passes through the jugular foramen between the internal jugular vein and the internal carotid artery. The cranial part then separates to join the vagus and is distributed through the pharyngeal and laryngeal branches of the vagus to pharyngeal, soft palatal and laryngeal muscles. The spinal part passes backwards to supply sternomastoid and trapezius muscles.

Hypoglossal (XII) cranial nerve

The hypoglossal nerve arises from the medulla and leaves the cranial cavity through the anterior condylar canal to enter the carotid sheath where it is joined by branches from the first and second cervical nerves and from the superior cervical sympathetic ganglion. The nerve turns forwards, hooking around the origin of the occipital artery and lying superficial to the external carotid, facial and lingual arteries in the carotid triangle. It leaves the carotid triangle deep to the digastric and stylohyoid muscles and enters the floor of the mouth between the mylohyoid and

hyoglossus muscles, communicating with the lingual nerve and penetrating the genioglossus muscle to enter the tongue below the sublingual gland. Within the tongue it supplies all muscles, except the palatoglossus.

Facial (VII) cranial nerve

The nerve controlling movements of the facial musculature is the facial cranial nerve. Lesions of this nerve (lower motor neurone lesions) or its central connections (upper motor neurone lesions) or muscle disease, can lead to facial weakness. The facial nerve is attached to the brain stem at the upper end of the medulla by a motor and sensory root, which cross the subarachnoid space above the vestibulocochlear (VIII) cranial nerve and enter the internal auditory meatus where they unite and enter the facial canal, winding through the petrous temporal bone between the semicircular canals of the inner ear behind and the cochlear in front, to reach the medial wall of the middle ear. Here it takes a sharp turn backward (the genu) and runs along the wall of the middle ear cavity.

At the genu is the sensory nucleus (geniculate ganglion) from where a branch containing secretomotor sympathetic fibers, the greater superficial petrosal nerve, joins the internal carotid or deep petrosal nerve (sympathetic fibers from the superior cervical ganglion) to form the nerve of the pterygoid canal (vidian nerve). In the pterygopalatine fossa this nerve joins the pterygopalatine (sphenopalatine) parasympathetic ganglion. In its course through the tympanic plexus, to which the glossopharyngeal nerve also contributes, the facial nerve gives off the

chorda tympani branch, which enters the middle ear cavity, crosses the tympanic membrane and leaves through the squamotympanic fissure to join the lingual nerve. The chorda tympani nerve contains taste fibers (sensory) from the anterior two-thirds of the tongue and secretomotor parasympathetic fibers destined for the submandibular ganglion – which supplies submandibular and sublingual salivary glands.

The facial nerve passes back down the stylomastoid canal to exit at the stylomastoid foramen where it gives off motor branches to:

- the posterior auricular and occipitalis muscles;
- the posterior belly of the digastric;
- the stylohyoid muscle.

The facial nerve then pierces the fascial sheath of the parotid gland and divides into:

- an upper branch giving rise to temporal, zygomatic and upper buccal branches;
- a lower branch giving rise to lower buccal, mandibular and cervical branches.

The temporal branch supplies the anterior and superior auricular, frontalis, upper part of orbicularis oculi and corrugator supercilii muscles. The zygomatic branch supplies the orbicularis oculi. The buccal branches supply buccinator, muscles of the upper lip, risorius and muscles of the nose. The mandibular branch supplies the lower lip and mentalis muscles. The cervical branch supplies the platysma and may send a branch to join the mandibular branch.

2

**Congenital and heritable disorders
with sole or prominent orofacial involvement**

ABNORMAL LABIAL FRENUM

A maxillary labial frenum (Fig. 28) may occasionally be associated with spacing between the central incisors – a maxillary median diastema. A thick, broad frenum may need to be removed before the diastema can be closed by orthodontic means. An abnormally thickened frenum may decrease mobility of the upper lip and promote plaque accumulation and subsequent caries formation of adjacent incisors. Multiple frena may be seen in Ellis–van Creveld syndrome (see p. 46), William’s syndrome and several oral–facial–digital syndromes (see pp. 35, 70).

Diagnosis

Diagnosis is clinical.

Management

Reassurance only is usually required, but surgery may be indicated.

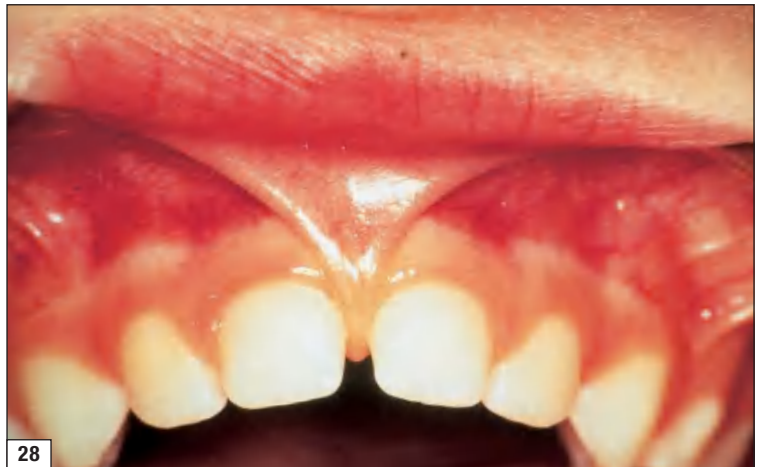

Figure 28. Fleshy labial frenum with a broad attachment extending to the gingival margin.

AMELOGENESIS IMPERFECTA

Amelogenesis imperfecta (Figs 29–33) is the term applied to a number of rare genetically determined disorders of enamel formation, which affect both primary and permanent dentitions. Multiple inheritance patterns are recognized and the incidence is of the order of 1 in 14,000.

Three major categories exist:

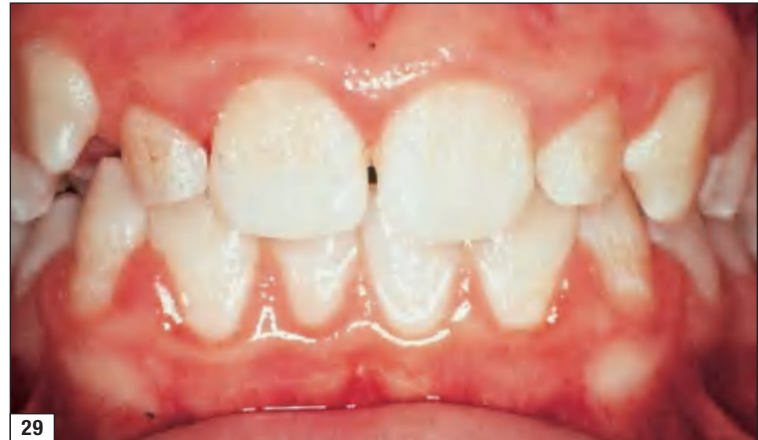- *Hypoplastic type* – in these types there is thin enamel of normal calcification. This spectrum of disorders ranges from a localized pitting defect in enamel to a general diminution of enamel formation in which the teeth are smaller with lack of interproximal contacts.
- *Hypocalcified type* – in these, the enamel is of normal thickness, but of low radiodensity and low mineral content and is therefore soft and quickly lost, exposing the dentine. This shows great variability and the enamel of the cervical portion of the teeth is often more highly mineralized.
- *Hypomaturational type* – in these types, the enamel is about as radiodense as the dentine, has a characteristic mottled brown-yellow-white appearance and easily chips away from the dentine. One fairly common subtype is known as ‘snow-capped teeth’, in which varying proportions of enamel in the incisal or occlusal aspects of the crowns have an opaque white appearance.

Diagnosis

Diagnosis is clinical, supported by radiographic assessment.

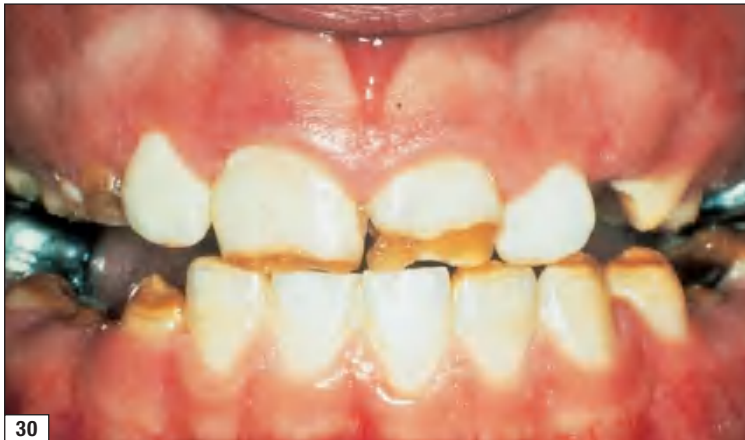Management

Restorative dentistry is usually indicated, and genetic counseling.



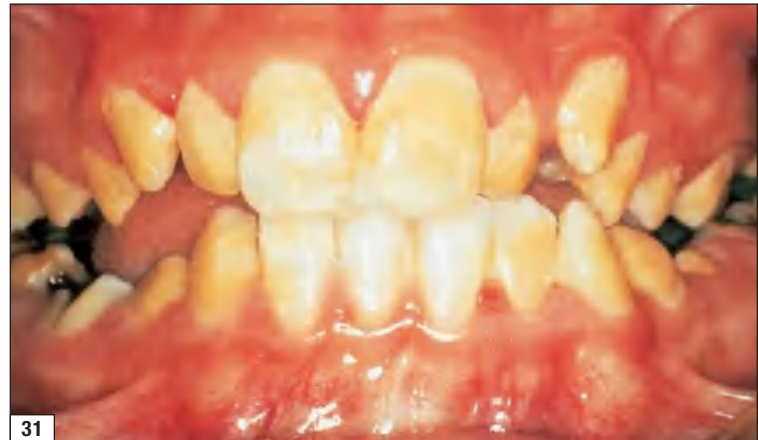29

Figure 29. Random pitted autosomal dominant type of amelogenesis imperfecta.



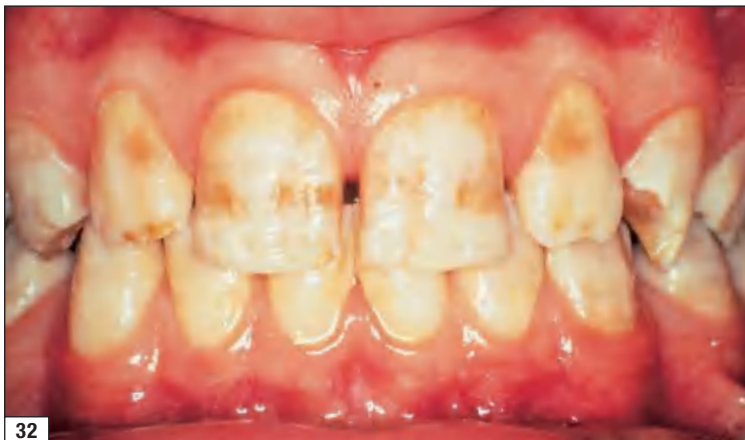30

Figure 30. Hypocalcified autosomal dominant type of amelogenesis imperfecta.



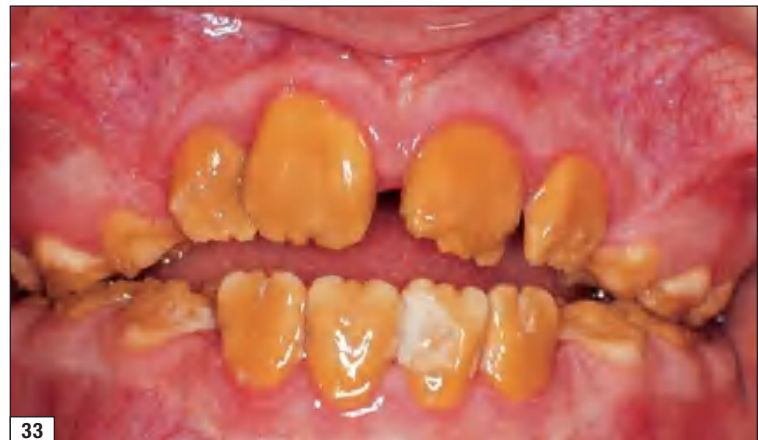31

Figure 31. Pigmented hypomaturational autosomal recessive type of amelogenesis imperfecta.



32

Figure 32. Hypomaturational autosomal recessive type of amelogenesis imperfecta.



33

Figure 33. Pronounced cosmetic defect in amelogenesis imperfecta.

ANKYLOGLOSSIA (TONGUE TIE)

Partial ankyloglossia (tongue tie; Figs 34, 35) affects up to 1.7% of children and represents an abnormal lingual frenum attachment. It is usually a congenital anomaly of little consequence and does not interfere with speech or feeding. The main consequence is difficulty in using the tongue to cleanse food away from the teeth and vestibules. True ankyloglossia with the ventral surface of the tongue bound to the floor of the mouth is extremely rare. Syndromes commonly associated with abnormal lingual

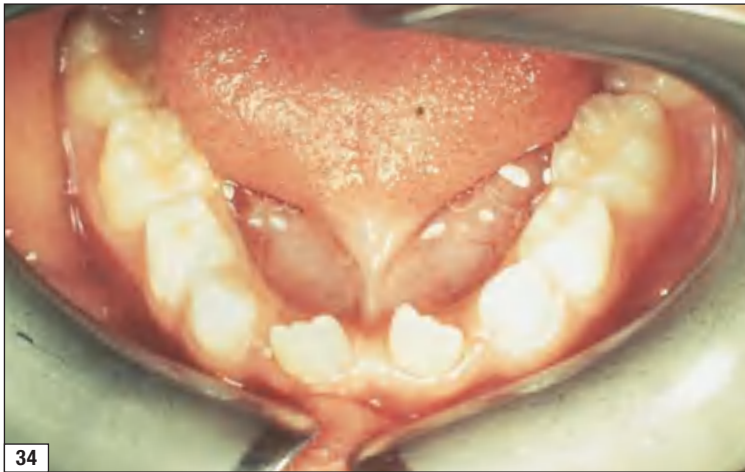


Figure 34. Tongue tie showing the lingual frenal attachment extending to the tip of the tongue preventing significant tongue protrusion.

frenum attachment include Pierre Robin sequence (see p. 36), trisomy 13 and oral–facial–digital syndrome II (see p. 35). A recent report shows an increased incidence in the babies of cocaine-addicted mothers.

Diagnosis

Diagnosis is clinical.

Management

Reassurance only is usually required, but surgery may be indicated.

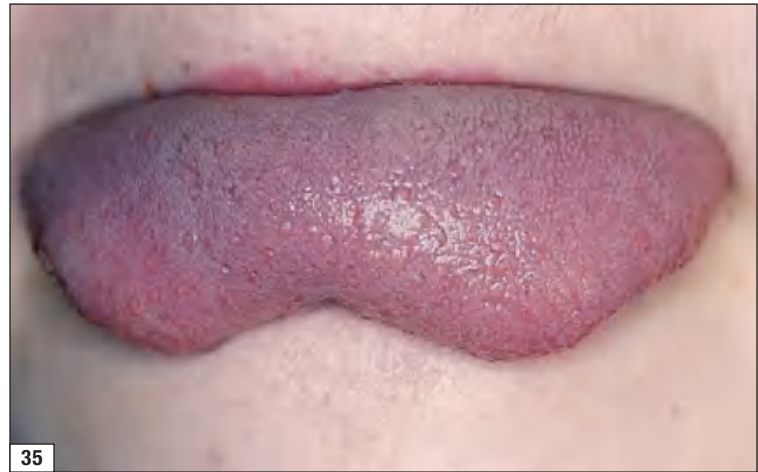

Figure 35. Ankyloglossia showing impaired ability to protrude the tongue.

CHERUBISM

Cherubism (Figs 36, 37) is a rare developmental condition of the jaws that typically affects the angles of the mandible to produce a cherubic facial appearance. It is an autosomal dominant trait and presents particularly in males, usually after the age of 4–5 years. Plain radiographs show multilocular radiolucencies with expansion of the mandible and to a lesser degree the maxilla. The swellings increase in size and then usually regress, at least partially, at puberty. Submandibular lymph node enlargement can occasionally occur. Besides facial deformity, there is

displacement of the developing teeth, resulting in malocclusion or failure of tooth eruption.

Diagnosis

Diagnosis is clinical, supported by imaging.

Management

Reassurance only is usually required, but surgery, orthodontic treatment and genetic counseling may be indicated.



Figure 36. Cherubism, showing mandibular swellings especially prominent on the right.

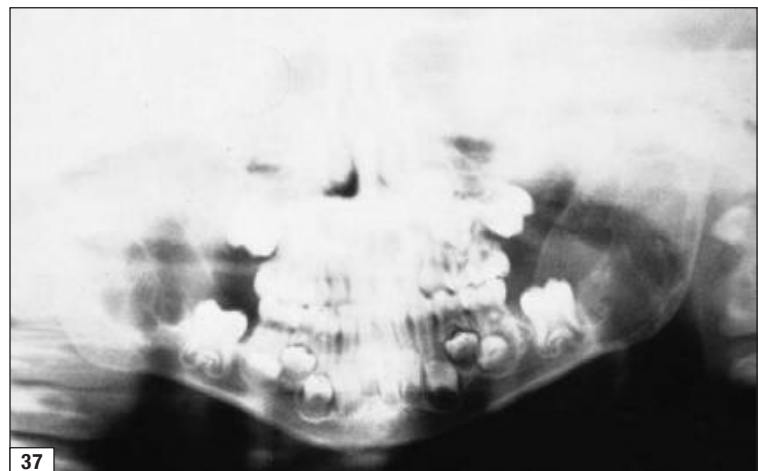


Figure 37. Panoramic view demonstrating multilocular radiolucencies in the angles and ascending rami of the mandible of a patient with cherubism.

CLEFTING DISORDERS

Cleft lip and palate (Figs 38–41) are the most common congenital deformities in the craniofacial region. The incidence is around 1 in 700 live births. The presentation may range from a bifid uvula, often associated with a submucous cleft, to a complete bilateral cleft of the lip and palate. Bifid or cleft uvula is a fairly common minor manifestation of cleft palate of little consequence, though an associated submucous cleft may cause speech impairment.

Cleft lip and palate are more common together than cleft lip alone. The cleft is on the left in over 60% of cases. There is a familial tendency when one parent is affected and the risk to a child is about 10%. Cleft lip and palate are associated with anomalies of the head and neck, extremities, genitalia or heart in about 20% of cases, and many cases are associated with various syndromes. Isolated cleft palate is especially associated with Down syndrome, Pierre Robin syndrome, Treacher Collins syndrome and Klippel–Feil anomaly.

Diagnosis

Diagnosis is clinical, supported by imaging.

Management

Surgery, orthodontics and restorative dentistry are usually indicated, and genetic counseling.

The main times when treatment is required are:

- Following birth, a palatal coverage appliance is fabricated for molding and partial closure of the cleft, in addition to improved feeding.
- Soft tissue repair by age 1 year.
- Orthodontic treatment may begin at age 4 years with a palatal expander appliance, if required.
- Before grafting of the palatal defect (at approximately 10 years of age).
- When the permanent teeth have erupted comprehensive orthodontic treatment is often indicated, often with restorative care (at approximately 12 years of age)
- If, as is common, there are facial growth defects and the maxilla is recessive relative to the mandible, orthognathic surgery may be indicated when growth has ceased.

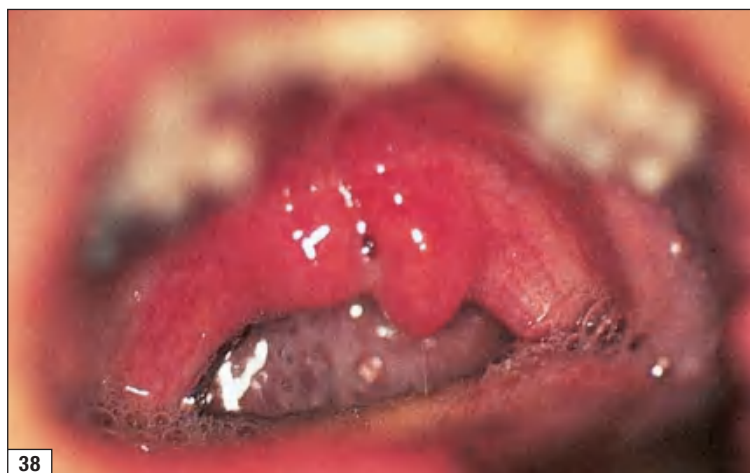

Figure 38. Bifid uvula – which may be associated with a submucous cleft.

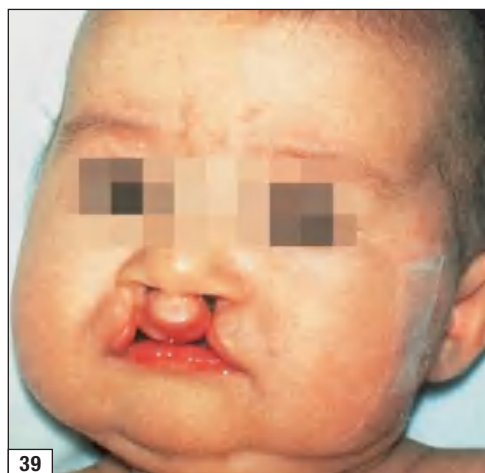

Figure 39. Bilateral cleft lip.

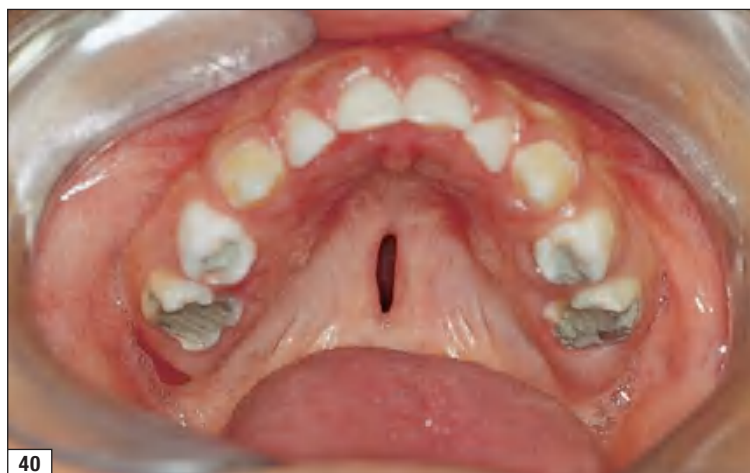

Figure 40. Isolated cleft of the posterior palate (and carious molars).

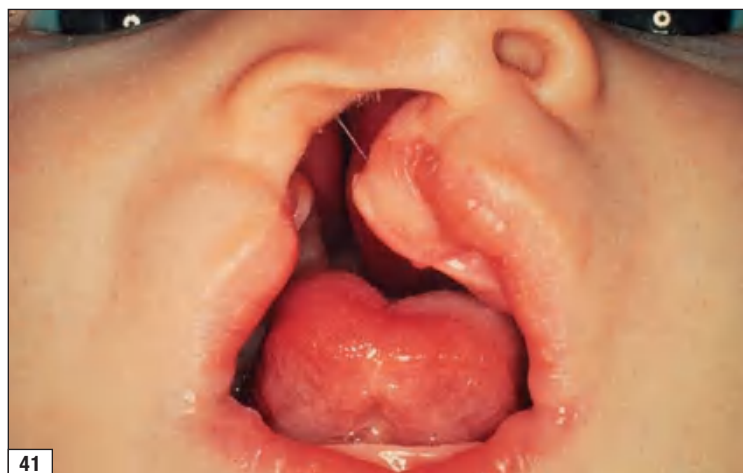

Figure 41. Cleft lip and palate.

CONGENITAL EPULIS

Congenital epulis (Fig. 42) is a rare benign swelling on the alveolar ridge in an infant. The maxilla is most frequently involved and there is a female predominance. It is probably a reactive mesenchymal lesion, usually presenting as a pedunculated firm pink or red nodule. Although these lesions may be large, they stop growing at birth and decrease in size. Some may resolve spontaneously.

Diagnosis

Diagnosis is clinical, supported by imaging and surgical biopsy.

Management

Although some cases resolve spontaneously, surgery is usually indicated, especially if there are feeding or breathing difficulties. Most cases are excised because they are easily traumatized and may bleed, and to exclude other entities.

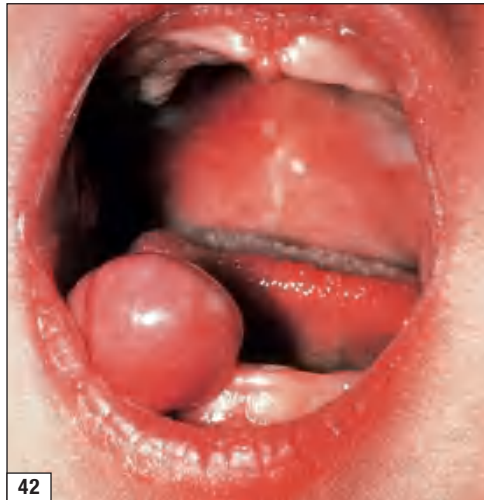

Figure 42. Congenital epulis arising from the mandibular ridge in a 7-day-old child (and gingival cyst on the mandibular anterior alveolar mucosa) together with Epstein's pearls.

DENTINE DYSPLASIA TYPE II

Dentine dysplasia type II (Fig. 43) is an autosomal dominant disorder that affects both primary and permanent dentitions and exhibits similarities to both dentine dysplasia type I and dentinogenesis imperfecta. Primary teeth are of normal size and shape, but are discolored and resemble dentinogenesis imperfecta.

Permanent teeth may appear clinically normal. The characteristic feature is the radiographic appearance of abnormal pulpal morphology. Pulpals have been described as 'thistle-tubed' or 'balloon on a string' shaped and radiopaque pulp stones are seen in the pulp chambers. This unusual appearance is caused by radicular extension of the pulp chamber and hypertrophy of the dentine around the pulp. The hypertrophy causes the pulp to become obliterated with age.

Diagnosis

Diagnosis is clinical, supported by imaging.

Management

Restorative dentistry is usually indicated and genetic counseling. Preservation of the primary dentition is important. Many pediatric dentists place stainless steel crowns or bond composite resin to the occlusal surface of the primary molars to prevent excessive occlusal wear and pulpal involvement.

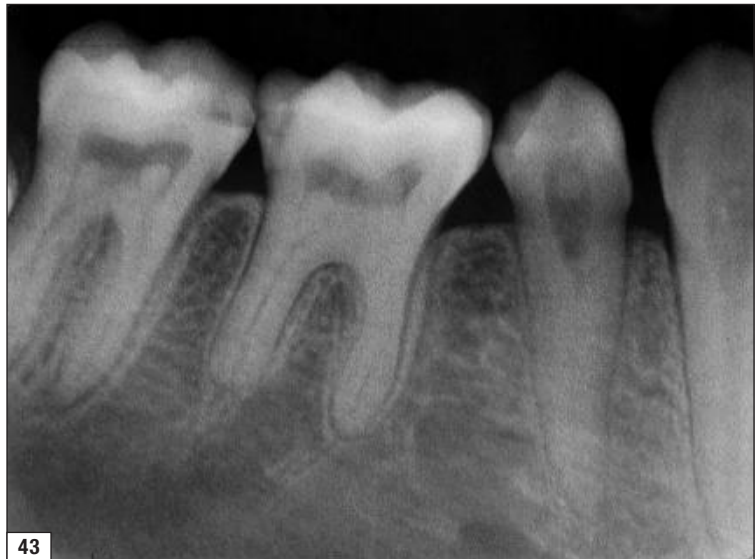

Figure 43. Dentine dysplasia Type II.

DENTINOGENESIS IMPERFECTA

Dentinogenesis imperfecta (Figs 44–49) is an autosomal dominant condition (incidence 1 in 8000) in which the dentine is abnormal in structure and hence translucent. There are three types:

- *Type I* (associated with osteogenesis imperfecta). The dental findings in types I and II are similar: primary teeth are more severely affected than permanent. In the permanent dentition the teeth that develop first are generally more severely affected than those that develop later. The teeth are translucent and may vary in color from gray to blue or brown. The enamel is poorly adherent to the abnormal underlying dentine and easily chips and wears. The crowns of the teeth are bulbous with pronounced cervical constriction and the roots are short and fracture easily. There is progressive obliteration of pulp chambers and root canals with secondary dentine.

Periapical radiolucencies are not uncommon.

- *Type II* (hereditary opalescent dentine).
- *Type III* (Brandywine type). This extreme variation is recognized in the primary dentition where the teeth have a 'shell-tooth' appearance and multiple pulpal exposures are common.

Diagnosis

Diagnosis is clinical, supported by imaging.

Management

Restorative dentistry is usually indicated and genetic counseling. Preservation of the primary dentition is important. Many pediatric dentists place stainless steel crowns or bond composite resin to the occlusal surface of the primary molars to prevent excessive occlusal wear and pulpal involvement.

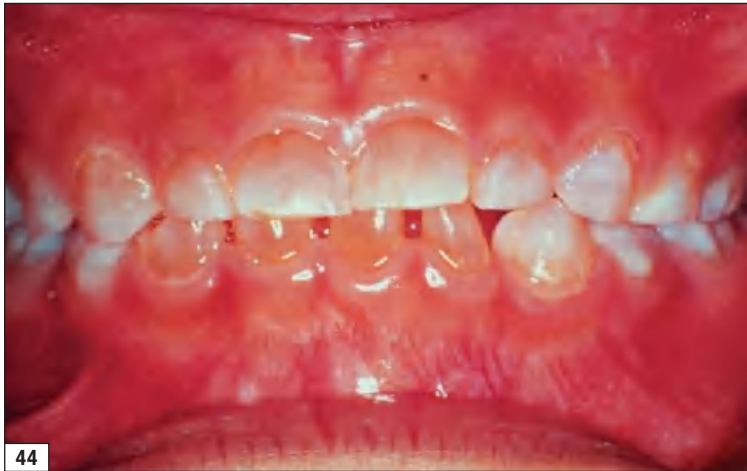

Figure 44. Dentinogenesis imperfecta at age 4.5 years. There has been loss of enamel from the primary incisors, canines and first molars.

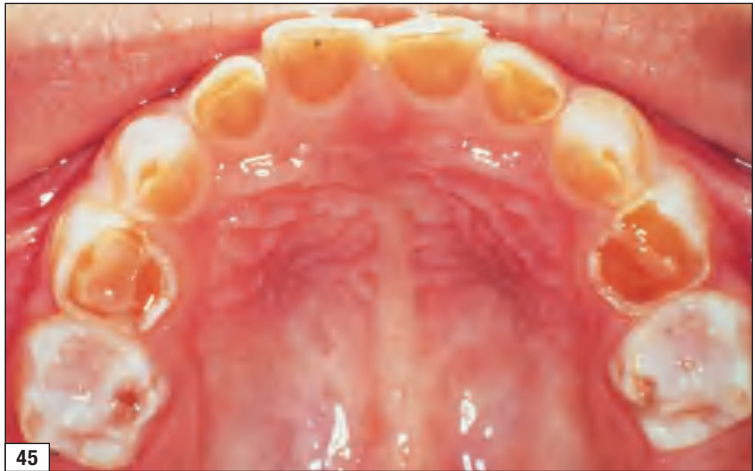

Figure 45. Dentinogenesis imperfecta. There is early loss of enamel on the second primary molars.

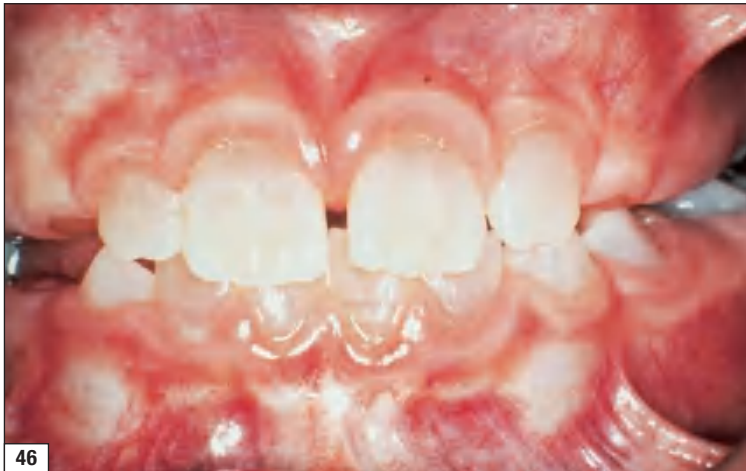

Figure 46. Dentinogenesis imperfecta. When the permanent incisors erupt they are of normal length and contour.

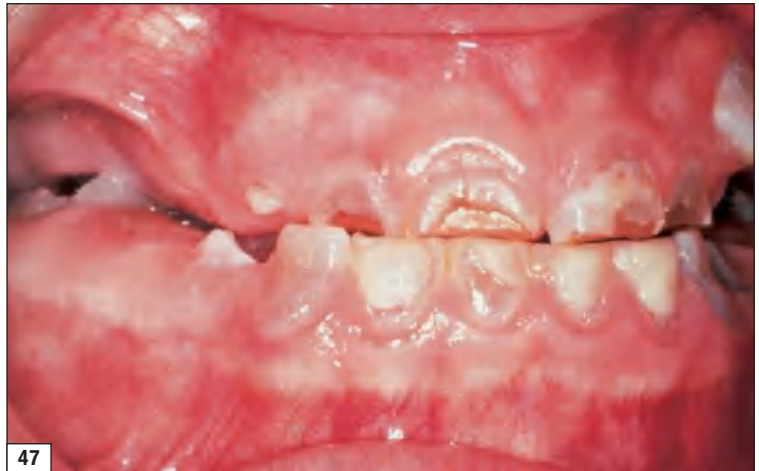

Figure 47. Dentinogenesis imperfecta. With unprotected posterior occlusion there is rapid loss of face height and attrition of permanent incisors.

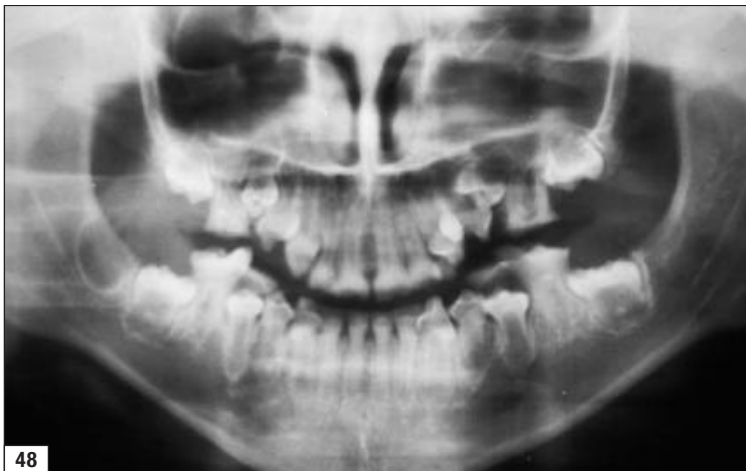

Figure 48. These panoramic views taken 3 years apart demonstrate the progressive obliteration of pulp chambers and root canals characteristic of dentinogenesis imperfecta.

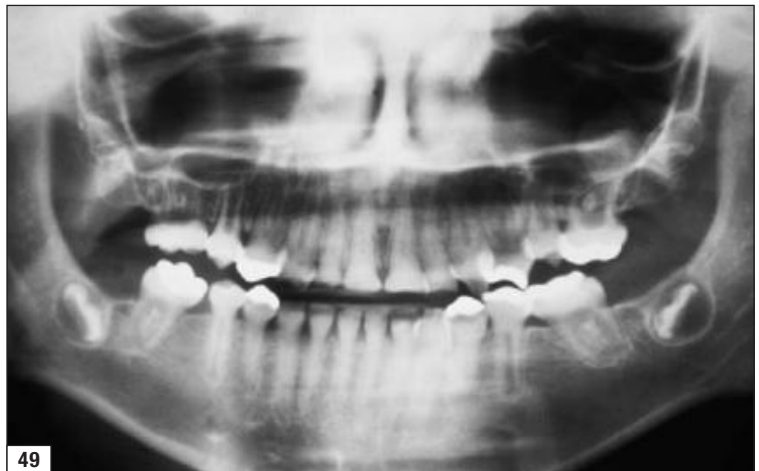


Figure 49. Dentinogenesis imperfecta. Onlays have been placed on the premolars and molars to prevent loss of tooth substance.

ERYTHEMA MIGRANS (GEOGRAPHIC TONGUE, BENIGN MIGRATORY GLOSSITIS)

Erythema migrans (Figs 50–53) is a common benign condition affecting up to 1.5% of the general population, of unknown etiology, in which the filiform papillae desquamate to form oval to irregular patches. A burning sensation may be experienced, especially when ingesting acidic or spicy foods or beverages. The characteristic lesions include well-demarcated patches of erythema that have a predilection for the anterior two-thirds of the tongue. These somewhat circular patches are devoid of filiform papillae and often surrounded by a yellowish-white scalloped border.

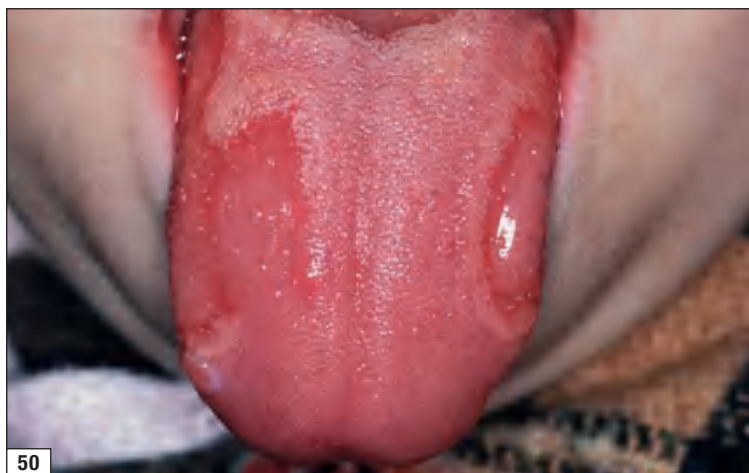
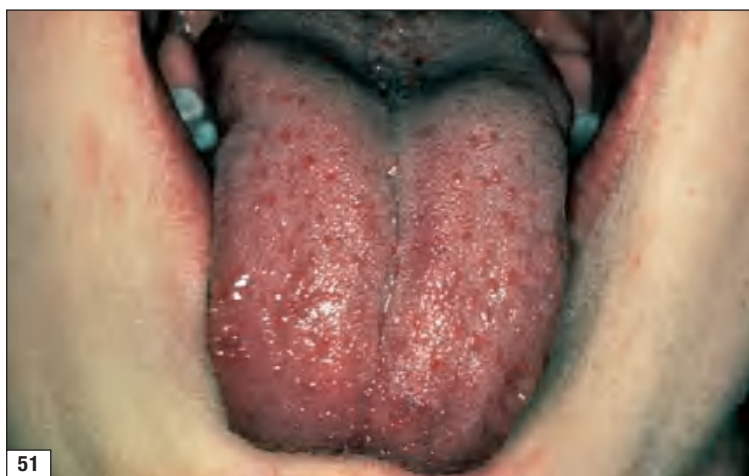
Figure 50. Erythema migrans (geographic tongue: benign migratory glossitis).



Figures 51, 52. Fissured tongues, also showing erythema migrans.

Many lesions are asymptomatic, although complaints about tenderness or sensitivity are not uncommon. In some children, it may be a reason for finicky eating habits. Oral hygiene products containing alcohol, certain flavoring agents or pH levels that are either acidic or alkaline can aggravate the condition. The pattern is frequently changing, with lesions resolving and recurring at various times. Occasionally, other oral mucosal sites may be affected. An erythematous blush of the palatal mucosa and/or angular cheilitis are signs that support a superimposed candidal infection, which may intensify the discomfort.

Patients who have a fissured (scrotal) tongue often have erythema migrans. Rarely there is an association with pustular psoriasis. HLA findings have been equivocal, with reports of associations with B15 and DR7. In children, a history of atopy is frequently reported.

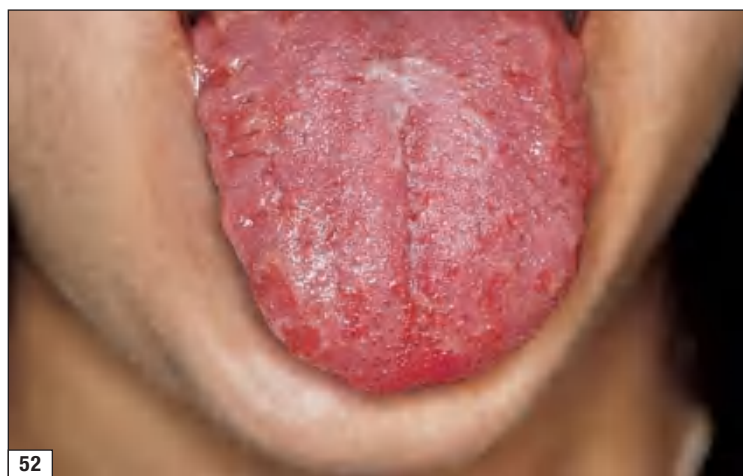Diagnosis

Diagnosis is clinical, and it needs to be differentiated from similar oral lesions seen in Reiter's syndrome, generalized pustular psoriasis, ulcerative colitis, and in some tropical countries, larva migrans.

Management

Reassurance only is usually required. Palliative management, avoidance of aggravating factors and judicious use of topical anti-inflammatory agents help to decrease the symptoms. There is no predictably successful therapy for most children. Topical anesthetics, coating agents and topical corticosteroids may be required for symptomatic cases. Antifungal agents are recommended when a superimposed candidal infection is present (see Candidosis, p. 128). Treatment options are given in Table 1.

No treatment is indicated if the condition is asymptomatic, although cosmetic concerns during adolescence may prompt the use of topical corticosteroids, despite the lack of symptoms.



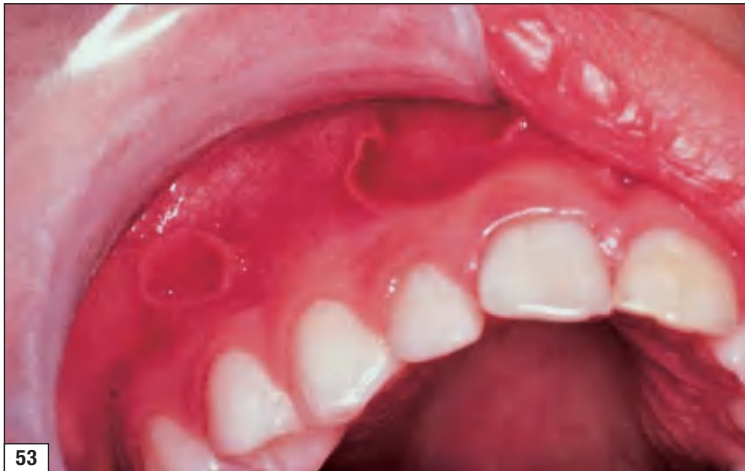

Figure 53. Erythema migrans occasionally affects sites other than the tongue.

Table 1. Treatment options for erythema migrans

Topical anesthetics and coating agents

Drug mixture Diphenhydramine hydrochloride 12.5 mg/5 mL syrup and Maalox (OTC), mix in a 1:1 ratio
Dispense 200 mL
Directions for use Rinse with one teaspoonful (5 mL) before meals and before bed for 2 minutes and expectorate. Use only when the tongue is tender. Shake well before use. Store suspension at room temperature. It is stable for 60 days.
Pediatric significance The suspension can be swabbed onto the tongue with a Toothette or cotton-tipped applicator to avoid coating the entire mouth (see herpetic gingivostomatitis, p. 153, for product substitutions).

Topical antifungal/corticosteroid oral rinse for painful cases

Drug mixture Triamcinolone acetonide 0.1% in nystatin suspension
Dispense 400 mL
Directions for use Rinse with 1 teaspoonful (5 mL) for 2 minutes, four times daily, after meals and before bed and expectorate. Do not eat or drink for 30 minutes after use.
Compounding instructions Directions to pharmacist for formulating are as follows: With a syringe, place 5 mL of triamcinolone acetonide 40 mg/mL injectable in an 8-oz plastic oval bottle. Quantity sufficient to make 200 mL with nystatin oral suspension. Shake well before using. The formulation expires in 6 months.
Pediatric Significance Do not use this mouthrinse in children who are unable to expectorate. In addition, topical corticosteroid agents (gels or ointments) may be beneficial in some cases (see Aphthae, p. 132). Topical corticosteroids should not be used for longer than 7 days in children without appropriate follow-up because of the risk of adrenocortical suppression.

FISSURED TONGUE (SCROTAL OR PLICATED TONGUE)

Fissured tongue (see Figs 51, 52) is a common developmental anomaly affecting about 1% of children that may appear after puberty.

Fissured tongue is of little significance, though often associated with erythema migrans, but it is a feature of Melkersson–Rosenthal syndrome (see pp. 33, 168) and is found more frequently than normal in Down syndrome (see p. 214) and psoriasis. The deep fissures may harbor oral flora and contribute to halitosis.

Diagnosis

Diagnosis is clinical.

Management

Reassurance only is usually required, along with routine brushing of the tongue.

FOCAL DERMAL HYPOPLASIA (GOLTZ SYNDROME)

Focal dermal hypoplasia is a rare, presumably X-linked, genodermatosis. Papillomas, usually of the lips and oral mucosa, occasional cleft lip and palate and dental anomalies (hypodontia and enamel defects) are the main oral features. The papillomas resemble warts clinically and fibromas microscopically, and occasionally recur after excision.

FOCAL EPITHELIAL HYPERPLASIA (HECK'S DISEASE)

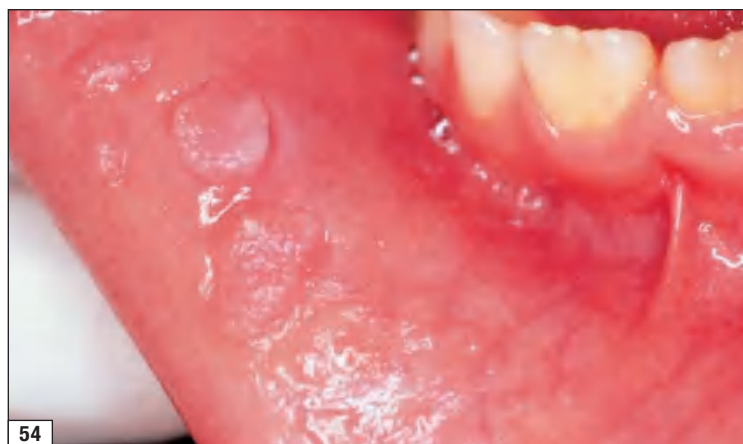Focal epithelial hyperplasia (Heck's disease; Figs 54, 55) is found in all ethnicities – most frequently in Inuits and American natives, and presents as multiple painless, sessile, soft papules, generally whitish in color, usually in the buccal or lower labial mucosa. Multiple, widespread papules and plaques of the oral mucosa are characteristic of this childhood disease, which is caused by the human papillomavirus (HPV), types 13 and 32. Lesions that occur along the occlusal plane may have a papillary surface as a result of repeated trauma. The buccal and labial mucosae are the main sites of involvement. These oral warts do not have a malignant potential.

Diagnosis

Diagnosis is clinical, supported by biopsy. These oral warts may be confused with condyloma acuminatum, a sexually transmitted disease. For this reason HPV typing may be indicated to exclude child abuse.

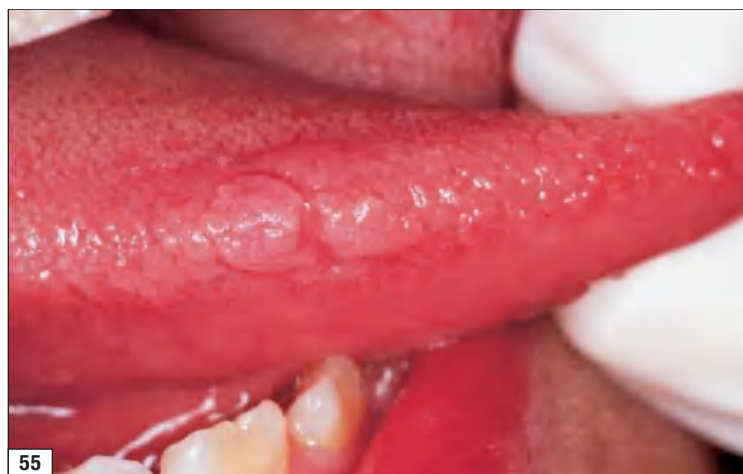Management

Reassurance only is usually required, but surgery or laser ablation may be indicated. Spontaneous resolution is common, but the lesions often persist for up to several years.



54

Figure 54. Focal epithelial hyperplasia. Multiple, flat topped nodules with a stippled surface were observed on the lateral tongue and labial mucosa in this child.



55

Figure 55. Focal epithelial hyperplasia.

GINGIVAL AND PALATAL CYSTS OF THE NEWBORN

Small white nodules are extremely common on the alveolar ridge and palate of the newborn. Gingival cysts (Figs 42, 56) are also known as dental lamina cysts when they occur on the alveolar ridge. Palatal cysts are sometimes termed Epstein's pearls (Fig. 42) when they are found on the midline of the hard palate and Bohn's nodules when they are located at the junction of the hard and soft palate. These small cysts usually disappear spontaneously by rupturing or involution within a month or so. There may be an association of gingival cysts with milia (superficial epidermal inclusion cysts).

Oral cysts are otherwise rare in neonates, although cysts may present at the base of the tongue where they can cause airway obstruction.

Diagnosis

Diagnosis is clinical.

Management

Reassurance only is usually required.

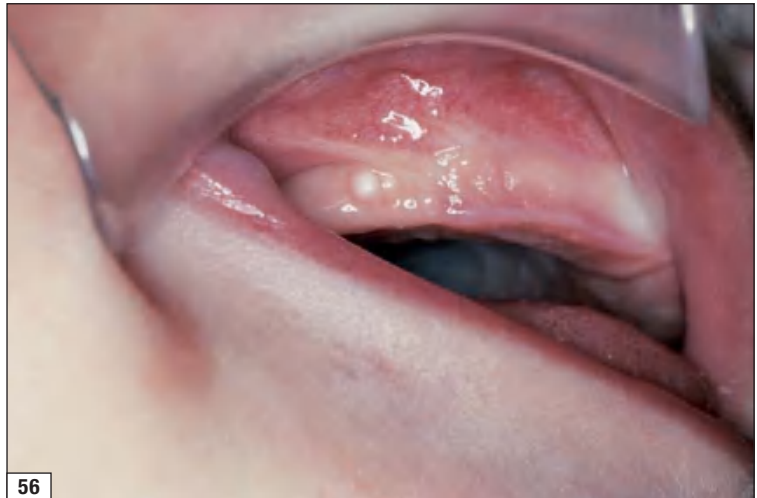

Figure 56. Gingival cysts in a young infant.

GINGIVAL FIBROMATOSES

Hereditary gingival fibromatosis is a familial condition, in which generalized gingival fibromatosis (Fig. 57) is often associated with hirsutism, and usually becomes most apparent at the time teeth are erupting. Although more commonly seen in the permanent dentition, it may occur with the eruption of deciduous teeth. There are occasional associations with epilepsy, sensorineural deafness and some rare syndromes such as Laband syndrome (in which there are skeletal anomalies; Figs 58, 59), Murray-Puretic-Drescher syndrome (with juvenile hyaline fibromatosis), Rutherford syndrome (with corneal dystrophy) and Winchester syndrome (with severe osteoporosis, corneal opacity and carpal and tarsal osteolyses). Some cases appear to be idiopathic.

Diagnosis

Diagnosis is clinical, supported by imaging.

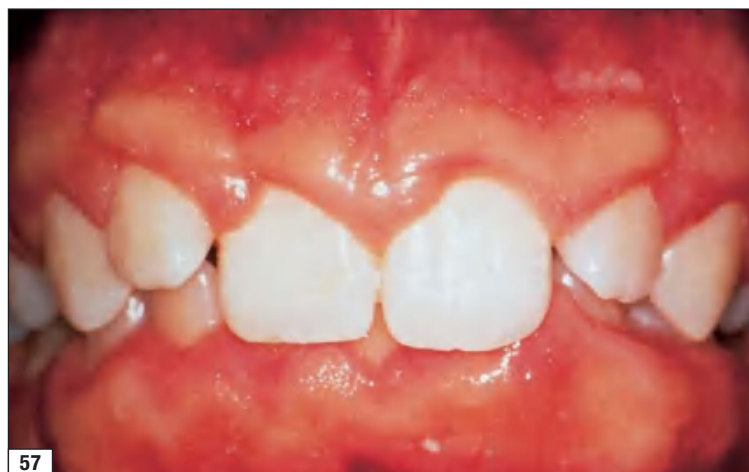

Figure 57. A mild form of hereditary gingival fibromatosis.

Management

Surgery may be indicated, especially where the swelling is unsightly or interferes with occlusion, and genetic counseling.

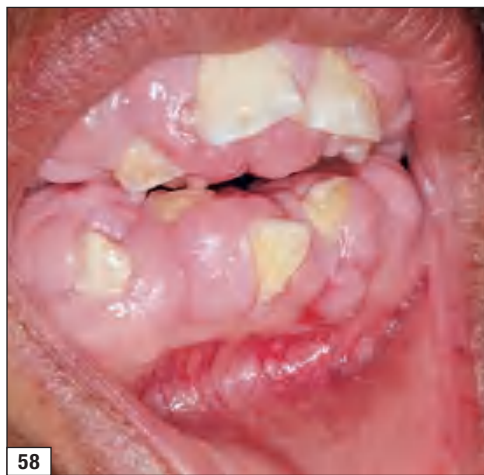

Figure 58. Pronounced gingival fibrous hyperplasia in Laband syndrome.

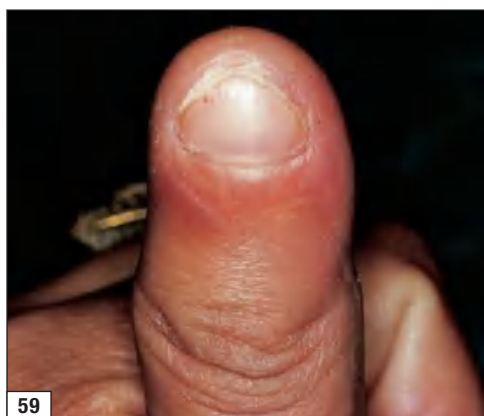

Figure 59. Digital anomalies in Laband syndrome.

HEMANGIOMA

Hemangiomas (Figs 60–64) are fairly common hamartomas in the mouth, especially on the lip and, less commonly, the tongue. These red or blue lesions may be flat or elevated and typically blanch when palpated. It is not uncommon for children to have more than one vascular lesion. Cosmetic concerns and bleeding are the primary problems associated with these vascular birthmarks. Examples of syndromes associated with vascular anomalies include ataxia–telangiectasia, Beckwith–Wiedemann syndrome, hereditary hemorrhagic telangiectasia (Osler–Weber–Rendu syndrome), Klippel–Trénaunay–Weber syndrome, Maffucci’s syndrome and Sturge–Weber syndrome.

Diagnosis

Diagnosis is clinical, supported by aspiration and imaging (sometimes angiography) to determine the extent of the lesion.

Management

Reassurance only is usually required, but surgery may be indicated – usually laser or cryosurgery, or the injection of sclerosant solutions such as sodium tetradecyl sulfate or, rarely surgery to ligate a feeding blood vessel or remove the angioma. Spontaneous regression is common and usually occurs by the first decade.

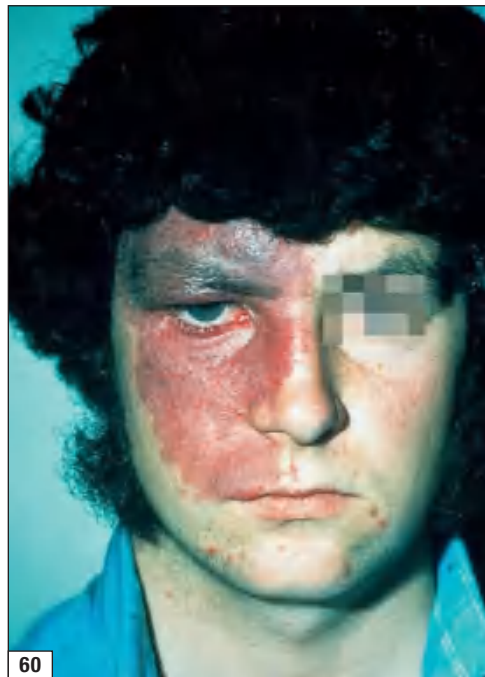

Figure 60.

Hemangiomas affecting the skin may also affect the intraoral tissues and the alveolar bone. Dental instrumentation and tooth extraction can cause appreciable hemorrhage.

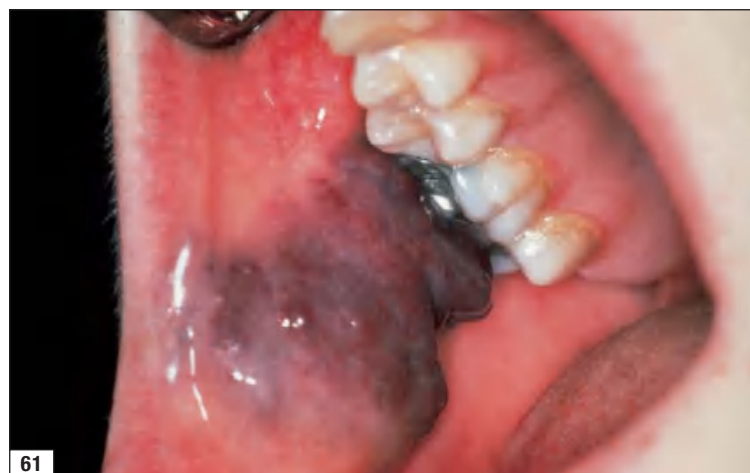

Figure 61. Hemangioma of the buccal mucosa and sulcus in the patient shown in Figure 60.

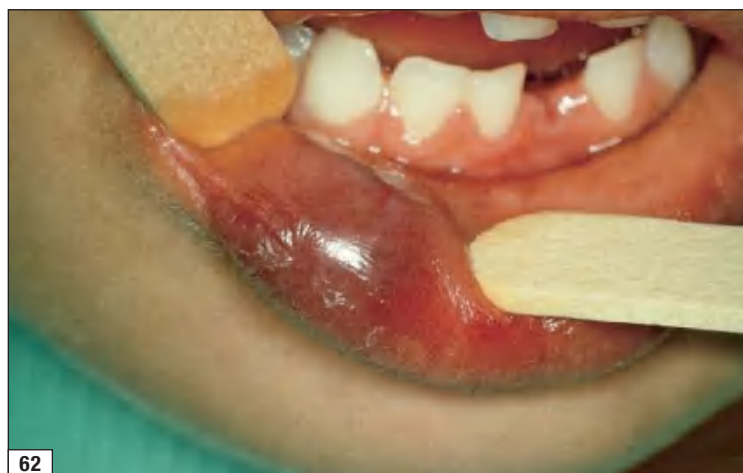

Figure 62. Hemangioma in the lower lip.

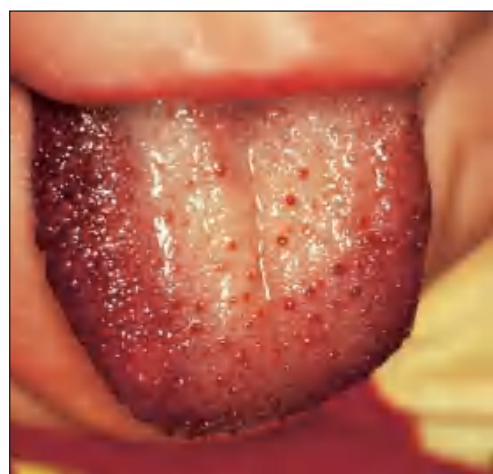

Figure 63.

Hemangioma infiltrating the whole tongue.

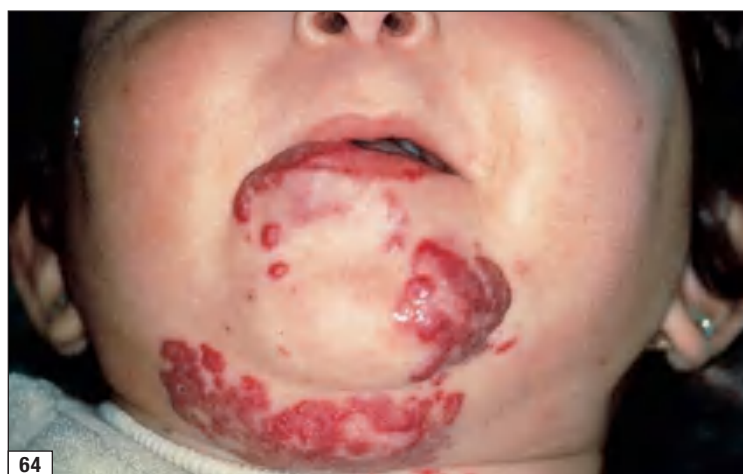

Figure 64. Hemangioma involving lip and skin.

HEREDITARY ANGIOEDEMA (C1-ESTERASE INHIBITOR DEFICIENCY)

Hereditary angioedema (HANE; Fig. 65) mimics allergic angioedema (see p. 131), although it produces a more severe reaction. Despite its hereditary nature, usually as an autosomal dominant trait, the disease may not present until later childhood or adolescence and nearly 20% of cases are caused by spontaneous mutation. Rare cases of C1-esterase inhibitor or deficiency are acquired.

Hereditary angioedema is caused by continued complement activation resulting from a genetically determined deficiency of an inhibitor

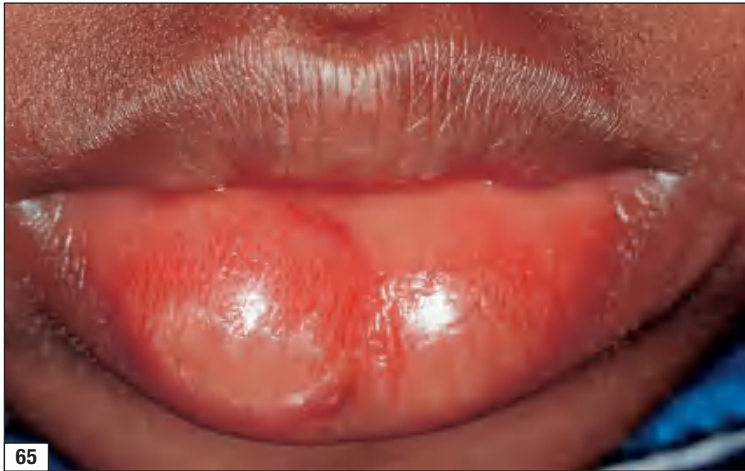

Figure 65. Hereditary angioedema.

of the enzyme C1 esterase rather than an allergic reaction. Activation of kinin-like substances are the probable cause of the sudden increase in capillary permeability.

Hereditary angioedema typically produces edema affecting the lips, mouth, face and neck region, the extremities and gastrointestinal tract after minor trauma and may persist for up to 4 days. Blunt injury is the most consistent precipitating event. The trauma of dental treatment is a potent trigger of attacks, and some attacks follow emotional stress. Abdominal pain, nausea or vomiting, diarrhea, rashes and peripheral edema sometimes herald an attack.

Edema may persist for many hours and even up to 4 days. Involvement of the airway is a constant threat. The mortality rate may be as high as 30% in some families, but the disease is compatible with prolonged survival if emergencies are avoided or effectively treated.

Diagnosis

In 85% of cases the plasma C1 esterase levels are reduced (type 1 HANE), but in 15% the enzyme is present but dysfunctional (type 2 HANE). In both types, C4 is consumed and its plasma level falls. The level of C3, however, is usually normal.

Management

Plasminogen inhibitors such as tranexamic acid have been used to mitigate attacks, but currently the most effective agents are the androgenic corticosteroids, danazol and, stanozolol, which raise plasma C1-esterase inhibitor levels to normal. C1-esterase concentrates are now becoming available and preferred for replacement of the missing factor.

HYPOPHOSPHATASIA

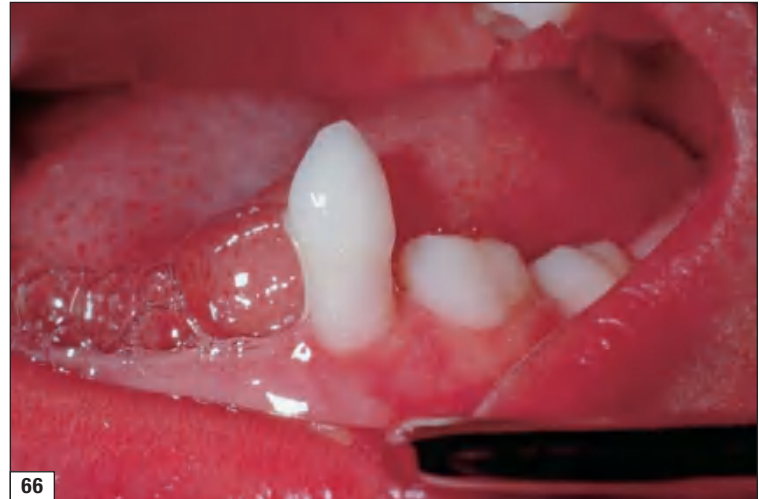Hypophosphatasia (Figs 66–68) is a rare autosomal recessive metabolic bone disease, with several types identified based on the age at diagnosis and the severity of the disease. The childhood form is usually diagnosed about the age of 2 years and is characterized by premature loss of the deciduous teeth, especially the incisors. Short stature, skeletal deformities and premature fusion of the cranial sutures may develop. Other dental findings include enlarged pulp chambers and alveolar bone loss. Lack of cementum on root surfaces contributes to the early loss of teeth.

Diagnosis

Diagnosis is clinical supported by imaging and biochemistry (assay of plasma alkaline phosphatase levels and urinary and plasma phosphoethanolamine levels).

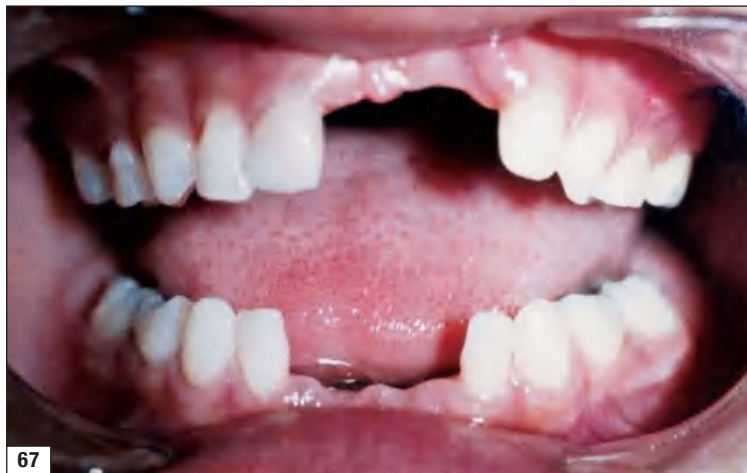Management

Reassurance only is usually required, but tooth space maintenance and prosthetic dentistry and genetic counseling may be indicated.

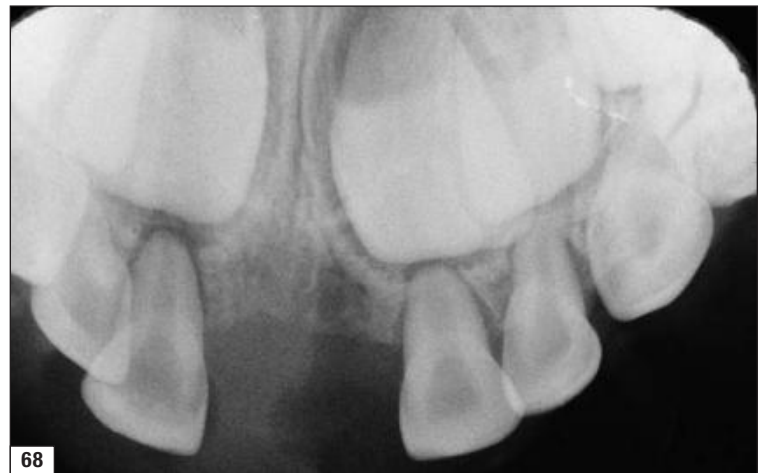

66

Figures 66–68. Hypophosphatasia.



67



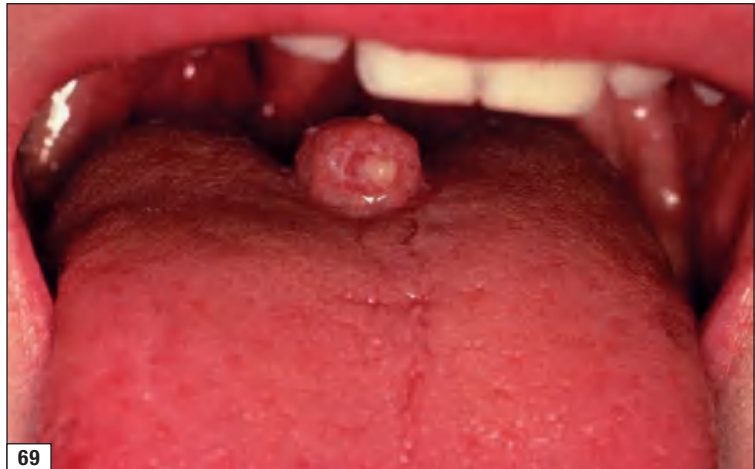68

LINGUAL THYROID

Lingual thyroid (Fig. 69) is a small sessile lump, seen mainly in females, in the midline of the tongue posterior to the foramen cecum. It can cause dysphagia, dysphonia and occasionally dyspnea. However, midline lumps in the posterior tongue rarely prove to be caused by a lingual thyroid.

Diagnosis and management

The neck should be examined and a scan performed to ensure there is a normal thyroid before any such lump is excised.



69

Figure 69. Lingual thyroid.

LIP PITS

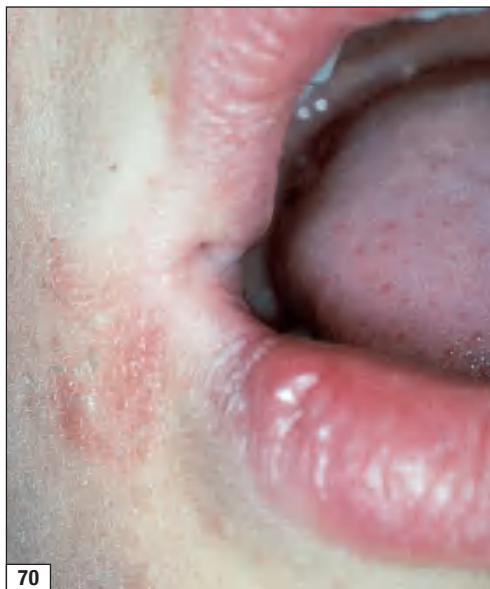Commissural lip pits (Fig. 70) are uncommon blind epithelial-lined developmental anomalies inherited as an autosomal dominant trait. Usually of no consequence, they may be associated with pre-auricular pits. Pits may also be paramedian on the vermillion (Figs 71, 72); may exude mucus and are most often associated with cleft lip or palate (Van der Woude's syndrome).

Diagnosis

Diagnosis is clinical.

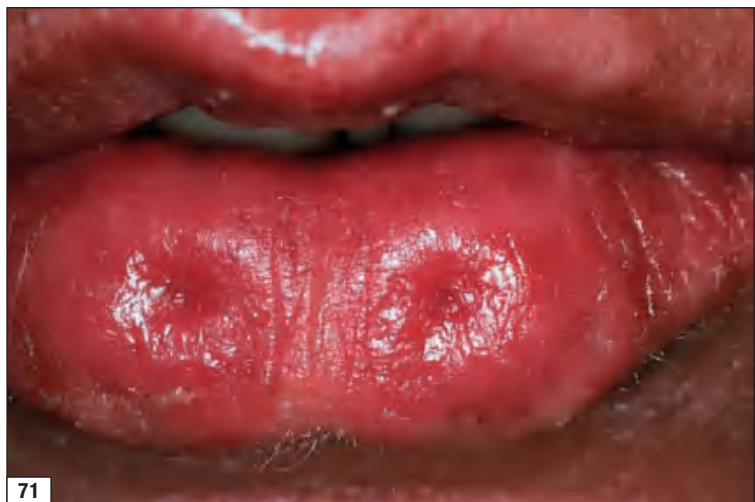Management

Reassurance only is usually required, but surgery and genetic counseling may be indicated for the labial lip pits.

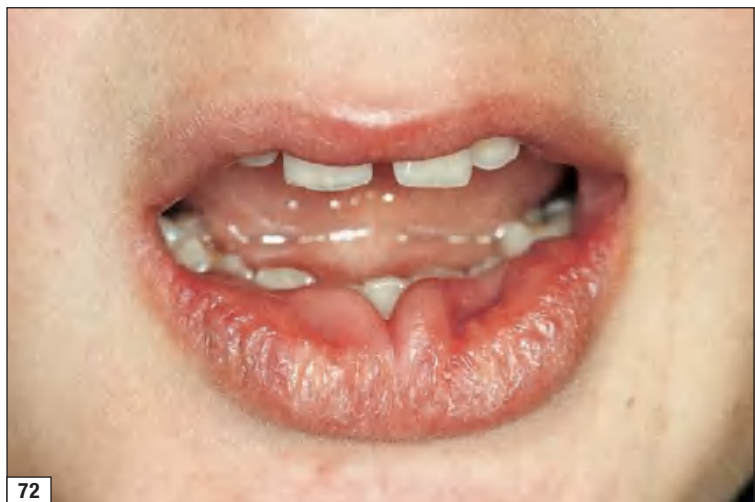

70

Figure 70. Commissural lip pits.



71



72

Figures 71, 72. Labial lip pits.

LYMPHANGIOMA

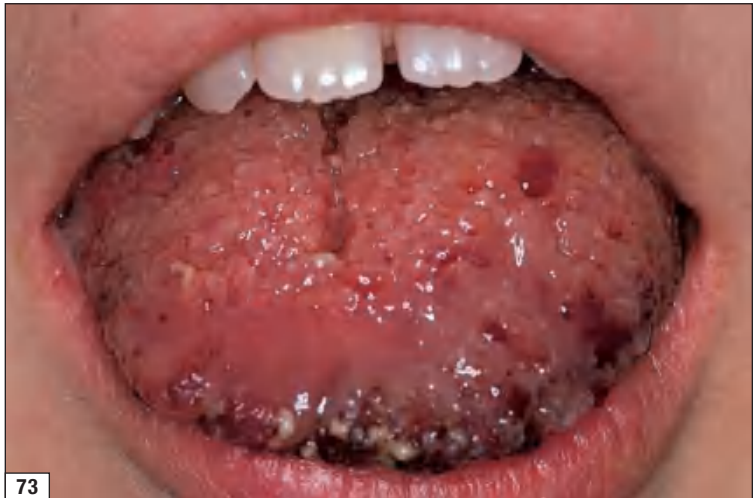Lymphangioma is a hamartoma (Figs 73–75) and most common in the anterior tongue or lip. Superficial lesions, typically have a pebbly or vesicular surface that imparts a ‘frogspawn’ appearance. Deeper lesions produce a diffuse fluctuant swelling with no surface changes. The color varies from a translucent pink to a blue-black color, depending on whether the lesion contains a number of blood vessels or if the lesion has been recently traumatized. The neonatal alveolar lymphangioma is a special variant that occurs in infants of African descent and is found on the alveolar ridge.

Diagnosis

Diagnosis is clinical, supported by imaging.

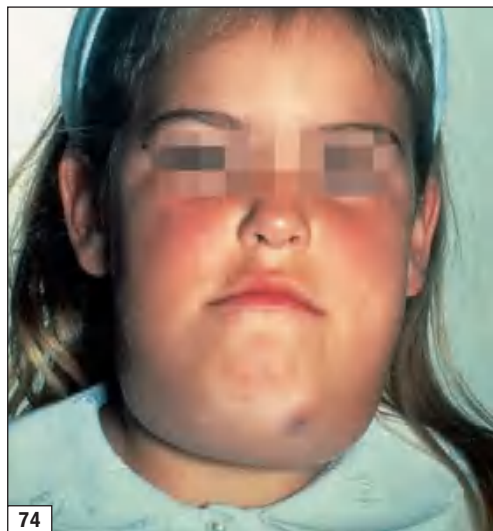Management

Surgery is often indicated and recurrence is common. Reassurance only is required for neonatal alveolar lymphangiomas because this variant spontaneously regresses.



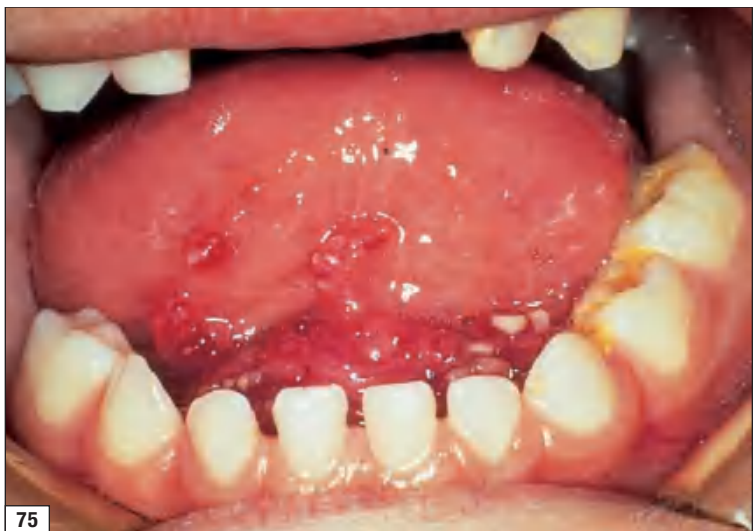73

Figure 73. Lymphangioma involving the tongue.



74

Figure 74. Large submental lymphangioma.



75

Figure 75. Same patient as in Figure 74 showing lymphangioma.

MELKERSSON–ROSENTHAL SYNDROME

Melkersson–Rosenthal syndrome (Figs 76, 77) consists of facial paralysis, facial edema, fissured tongue and plicated mucosal swelling. Not all patients have every component of the syndrome, which is closely related to orofacial granulomatosis and oral Crohn’s disease.

Diagnosis

Diagnosis is clinical, supported by biopsy. Crohn’s disease, sarcoidosis and orofacial granulomatosis should be excluded.

Management

Reassurance only is usually required, but surgery may be indicated. Corticosteroids, systemic and intralesional may control disease progression.

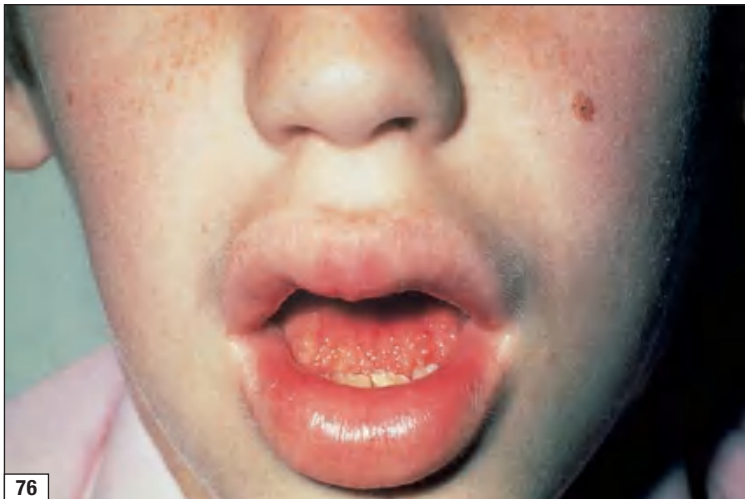

Figure 76. Facial edema especially involving the lips in Melkersson–Rosenthal syndrome.

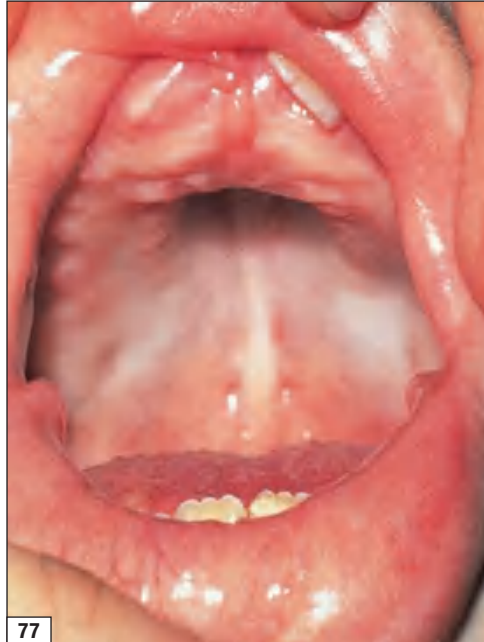

Figure 77. Plication and swelling of the midline palatal mucosa in Melkersson–Rosenthal syndrome.

NATAL TEETH

Rarely, teeth are present at or soon after birth (Figs 78, 79), and have been described even at 26 weeks' gestation. The incidence is from 1 in 700 to 1 in 6000 births. Usually the teeth involved are lower incisors of the normal primary dentition: in less than 10% they are supernumeraries. Rarely, there are associations with Ellis-van Creveld syndrome, pachyonychia congenita, Hallermann-Streiff syndrome or steatocystoma multiplex.

Diagnosis

Diagnosis is clinical, supported by imaging to establish which teeth are present.

Management

Reassurance only is usually required, but surgery may be indicated. The teeth usually cause no problems, but can ulcerate the tongue (Riga-Fede disease) or the mother's breast if the infant is suckling. Extractions are best restricted to those teeth that are supernumeraries or are very loose and in danger of being inhaled.

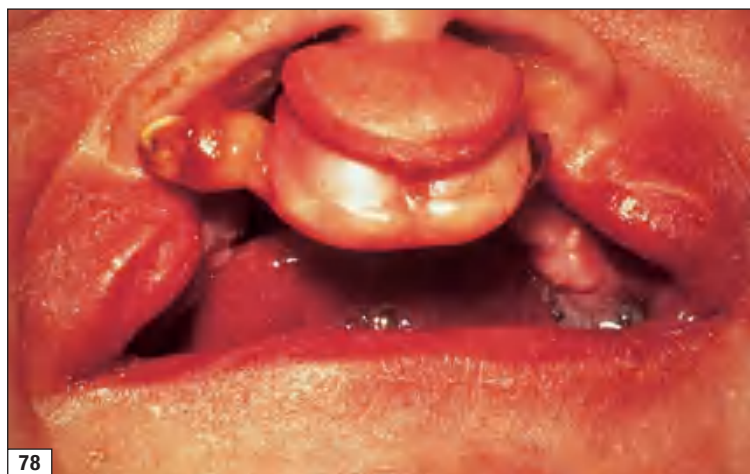

Figure 78. Natal teeth. Two natal teeth, one on each side of the premaxilla in a newborn baby with bilateral cleft lip and palate.

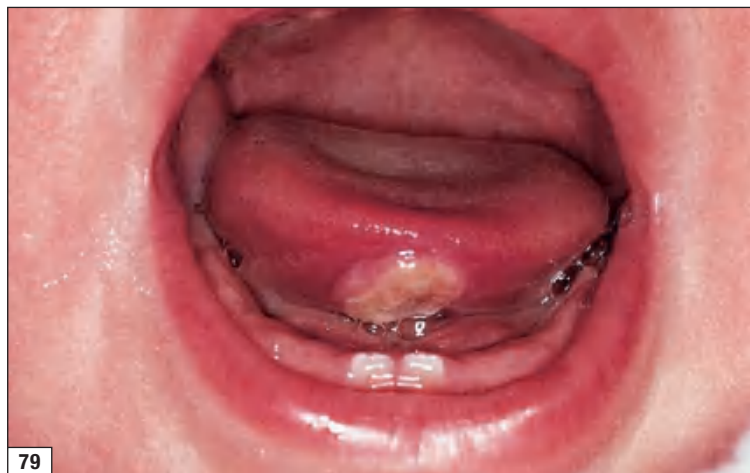

Figure 79. Ulceration of tongue caused by natal teeth.

ODONTODYSPLASIA

Odontodysplasia (Figs 80, 81) is a true odontodysgenesis imperfecta affecting all histological elements of the dental organ, but usually involving only adjacent teeth in one segment of a dental arch. Sometimes there is an associated vascular malformation. Both primary and secondary teeth can be affected. Affected teeth have been termed 'ghost teeth' because of their lack of density and faded character in standard radiographs.

Diagnosis

Diagnosis is clinical, supported by imaging.

Management

Surgery, prosthetic dentistry and genetic counseling may be indicated.

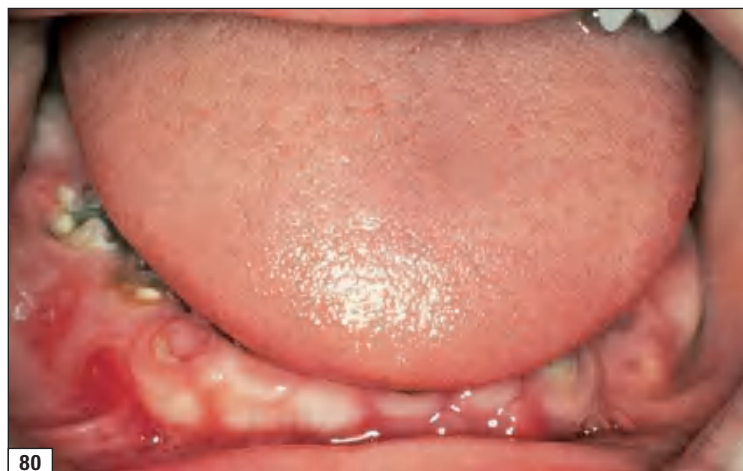

Figure 80. Odontodysplasia affecting the mandible. There are retained primary tooth remnants and buccal abscesses.

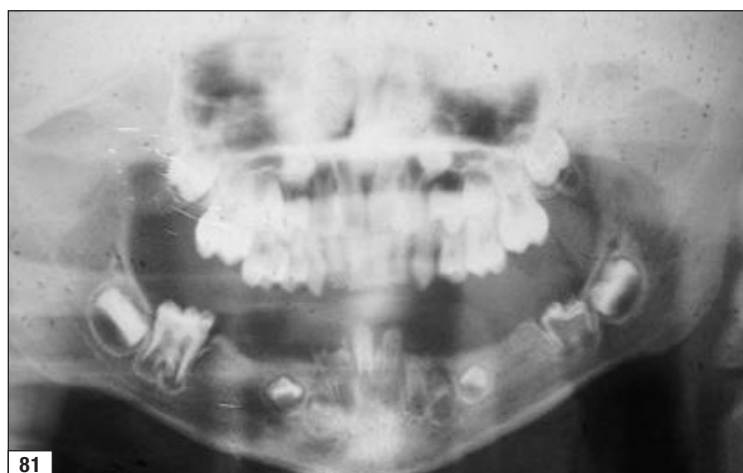


Figure 81. Odontodysplasia. A panoramic view of the same patient in Figure 80 taken 3 years later. The lower second permanent molars appear to be developing relatively normally.

ORAL-FACIAL-DIGITAL SYNDROME

Multiple fibrous bands may be associated with cleft or lobulated tongue in the oral-facial-digital syndrome (OFD; Fig. 82). In OFD type I, which is seen only in girls, there is also clinodactyly, cleft palate, hamartomas of the tongue, missing teeth and sometimes renal defects and learning disability. OFD type II (Mohr syndrome) is a less severe autosomal recessive condition, but there is often conductive deafness. Other orofacial-digital syndromes are rare.

Diagnosis

Diagnosis is clinical, supported by imaging.

Management

Surgery is required for cleft repair and some tongue abnormalities. Genetic counseling may be indicated.

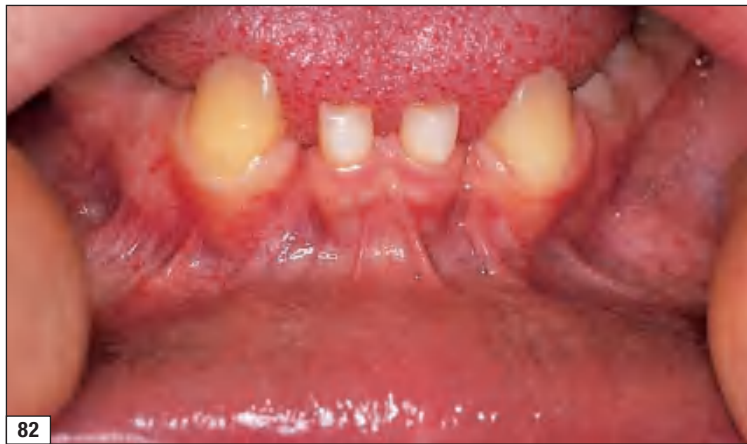

Figure 82. Hypodontia and multiple fibrous bands in oral-facial-digital syndrome type II (Mohr syndrome). The primary incisors are retained.

PAPILLON-LEFÈVRE SYNDROME

Papillon-Lefèvre syndrome (Figs 83, 84) is a rare, genetically-linked disorder of cathepsin manifesting with prepubertal periodontitis in association with palmar-plantar hyperkeratosis. Virtually all primary teeth are involved and most are lost by the age of 4 years. The permanent teeth are often lost by the age of 16 years.

Hyperkeratosis usually affects the soles more severely than the palms. The dura mater may be calcified, particularly the tentorium. The choroid can also be calcified.

A rare variant of the Papillon-Lefèvre syndrome includes arachnodactyly and tapered phalanges as well as the above features (Haim-Munk syndrome).

Diagnosis

Diagnosis is clinical, supported by imaging.

Management

Periodontal care and restorative dentistry and genetic counseling are indicated.

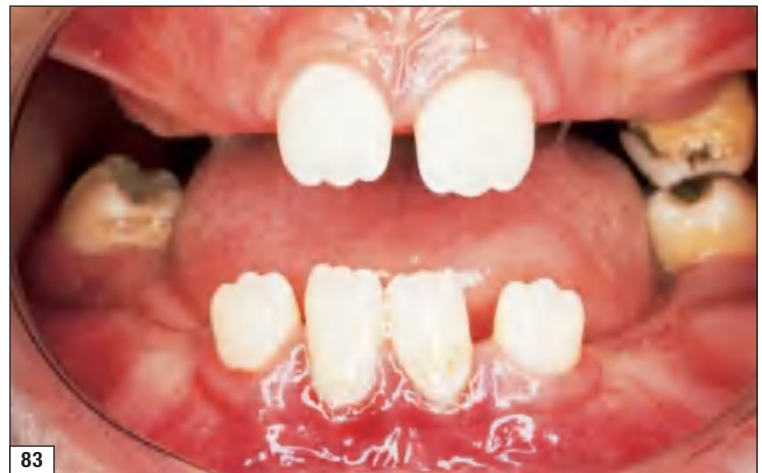

Figure 83. Periodontitis in Papillon-Lefèvre syndrome.

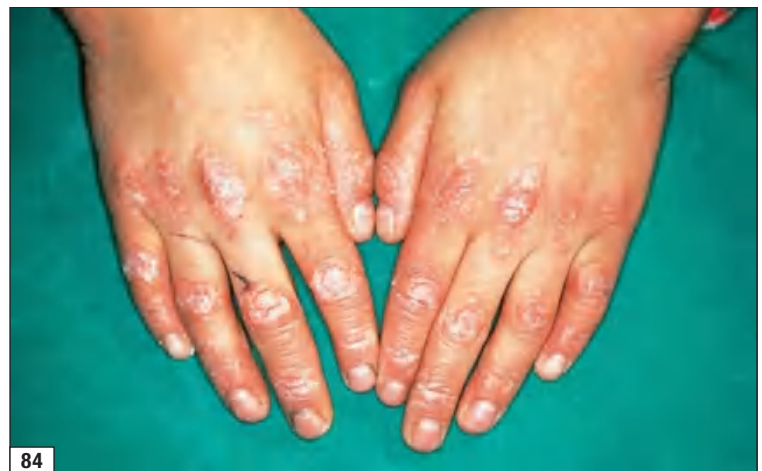

Figure 84. Hyperkeratosis in Papillon-Lefèvre syndrome.

PATAU'S SYNDROME

Cleft lip (often bilateral) and cleft palate with micrognathia are orofacial features of trisomy 13 (Fig. 85). In addition, multiple organ system anomalies are associated with this syndrome, including severe mental defects.

Diagnosis

Diagnosis is clinical, supported by imaging and karyotyping.

Management

Surgery and genetic counseling may be indicated. This syndrome has a high mortality rate.

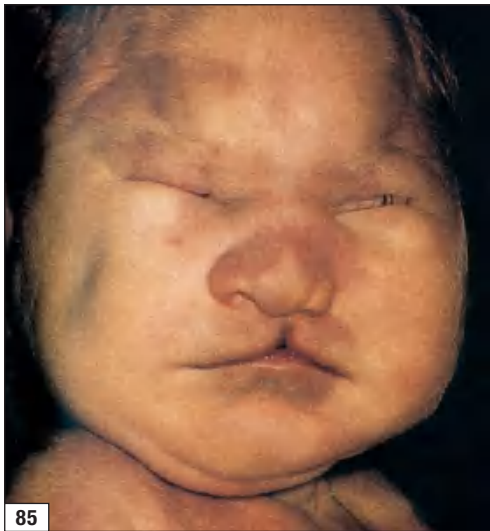

Figure 85. Patau's syndrome showing cleft lip.

PIERRE ROBIN SYNDROME

The Robin syndrome (or sequence) is severe congenital micrognathia with cleft palate (Fig. 86). It may be seen in Stickler syndrome (a disorder of type II collagen) and in fetal alcohol, methadone, phenytoin or retinoic acid syndromes. There may be glossoptosis and respiratory embarrassment. Episodic dyspnoea is often evident from birth. There may also be congenital cardiac anomalies and learning disability.

Diagnosis

Diagnosis is clinical, supported by imaging.

Management

Medical care is usually required and surgery and genetic counseling may be indicated.

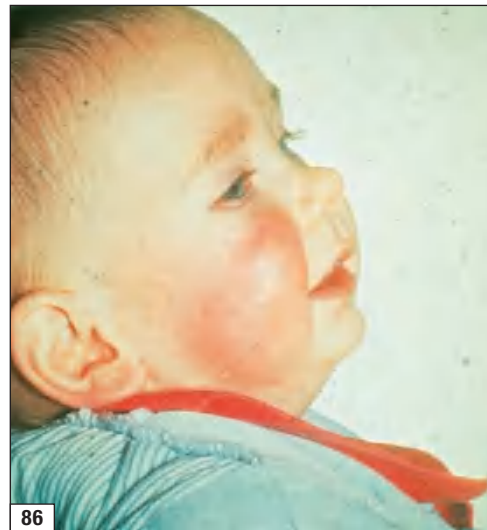


Figure 86. Pierre Robin sequence.

PLASMINOGEN DEFICIENCY

Ligneous conjunctivitis is a rare idiopathic form of chronic membranous conjunctivitis associated with fibrin deposits and often with associated lesions in the larynx, nose, cervix and gingivae (Fig. 87). Some patients develop corneal involvement and blindness, others may also develop congenital occlusive hydrocephalus. In most instances ligneous conjunctivitis may represent an autosomal recessive disorder, and in a few there may be other causes of blood vessel hyperpermeability, including drugs. In health, body fluid fibrinolytic activity clears fibrin deposits, but if plasminogen is deficient, this mechanism fails, with fibrin deposition occurring. There is no tendency to thrombosis, suggesting the existence of an alternative intravascular fibrinolytic mechanism. It has become evident that many cases of ligneous conjunctivitis are related to plasminogen deficiency.

The gingival lesions in ligneous conjunctivitis are mainly swelling with ulceration. Similar lesions without ocular involvement are seen in amyloidaceous ulcerated gingival hyperplasia. The mucosal lesions are characterized by subepithelial eosinophilic infiltrates containing fibrin, but in contrast, usually contain immunoglobulin and albumin. There is no staining for glycogen, lipid or amyloid.

Diagnosis

Diagnosis is clinical, supported by biopsy and biochemistry (assay of plasma plasminogen levels).

Management

Reassurance only is usually required, but surgery and genetic counseling may be indicated. It remains to be established whether therapy with topical heparin or intravenous purified plasminogen concentrate will effectively control the lesions.

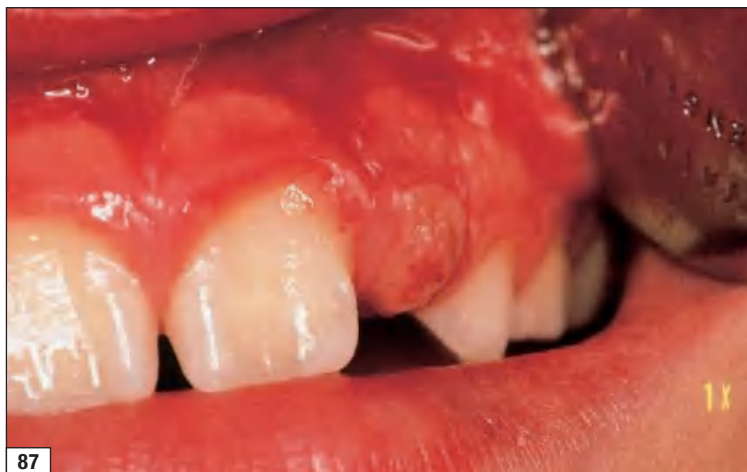

Figure 87. Plasminogen deficiency.

RETT SYNDROME

Rett syndrome (Figs 88, 89) seen only in females is characterized by progressive neurological disorder, loss of purposeful hand use and acquired microcephaly. Constant bruxism is a conspicuous feature.

Diagnosis

Diagnosis is clinical.

Management

Reassurance only is usually required, but restorative dentistry and genetic counseling may be indicated.

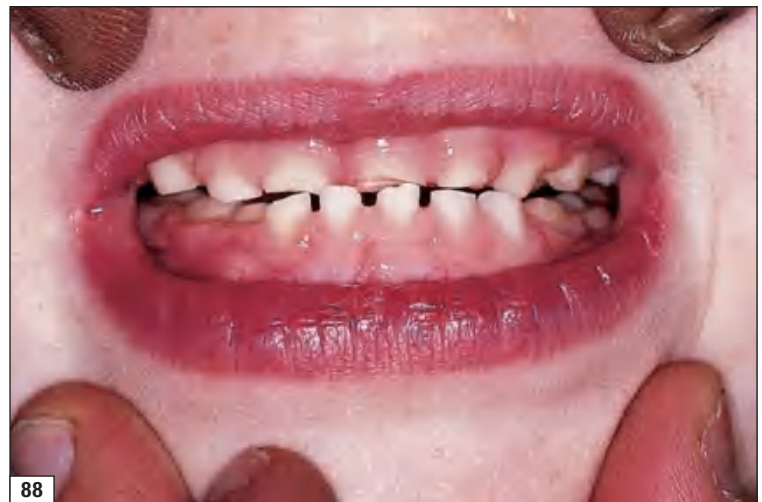

Figure 88. Pronounced attrition caused by bruxism in Rett syndrome.



Figure 89. Wringing of hands in Rett syndrome.

STURGE-WEBER SYNDROME (ENCEPHALOFACIAL ANGIOMATOSIS)

Sturge-Weber syndrome (Figs 90–92) is a neuroectodermal disorder in which angioma affects part of the face and usually extends into the occipital lobe of the brain, producing epilepsy and often hemiplegia and learning disability.

The hemangioma often appears to be limited to the area of distribution of one or more of the divisions of the trigeminal nerve. The affected area is swollen and hypertrophic.

The hemangioma may extend intraorally and be associated with hypertrophy of the affected jaw, macrodontia and accelerated tooth eruption. Because the patients are often treated with phenytoin there may be gingival overgrowth.

Diagnosis

Diagnosis is clinical supported by imaging. The latter shows intracranial calcification of the angioma.

Management

Reassurance only is usually required, but surgery and genetic counseling may be indicated. Lasers may improve the appearance of the port-wine stain on the face.

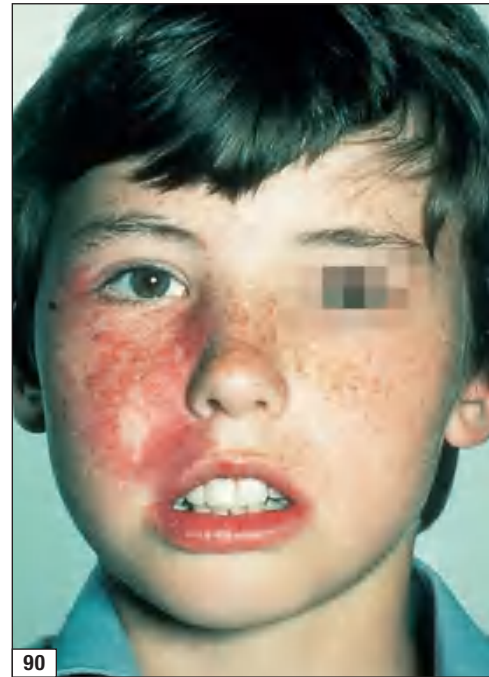

Figure 90. A 10-year-old boy with Sturge-Weber syndrome. There is an angioma affecting the maxillary division of the right trigeminal nerve.

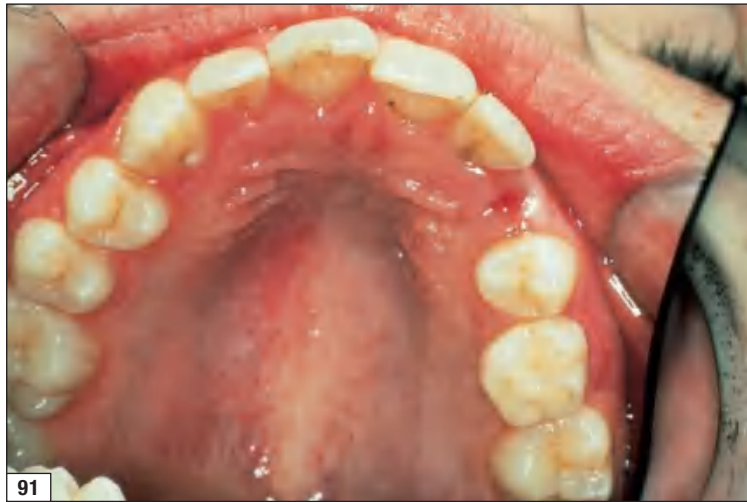

Figure 91. Sturge-Weber syndrome. The palatal view of the boy in Figure 90. The right side of the palate is slightly swollen and there are increased surface capillary markings. A primary canine has been shed from the unaffected side.

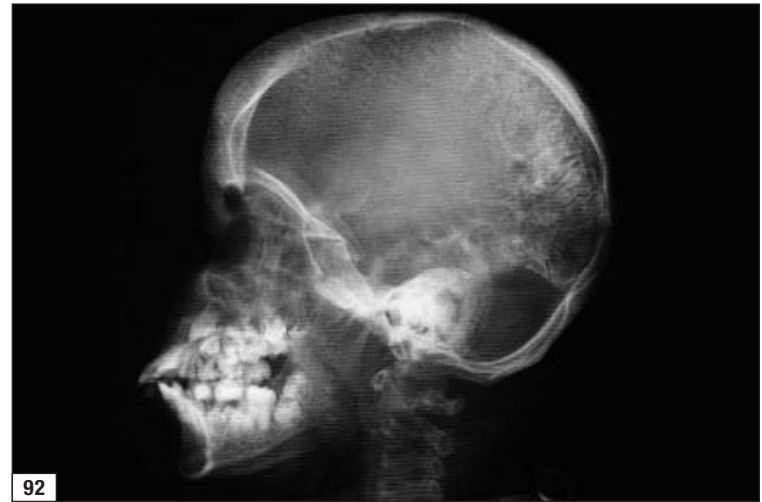

Figure 92. Intracranial calcification in Sturge-Weber syndrome.

SYPHILIS

Congenital syphilis (Figs 93, 94) is rare. *Treponema pallidum*, the causal bacterium of this sexually-transmitted disease, crosses the placenta only after the fifth month of pregnancy and can produce dental defects, typically Hutchinson's incisors. These teeth have a barrel-shape, often with a notched incisal edge. Such dysplastic permanent incisors, along with neural deafness and interstitial keratitis, are combined in Hutchinson's triad. The molars may also be hypoplastic (Moon's molars or mulberry molars).

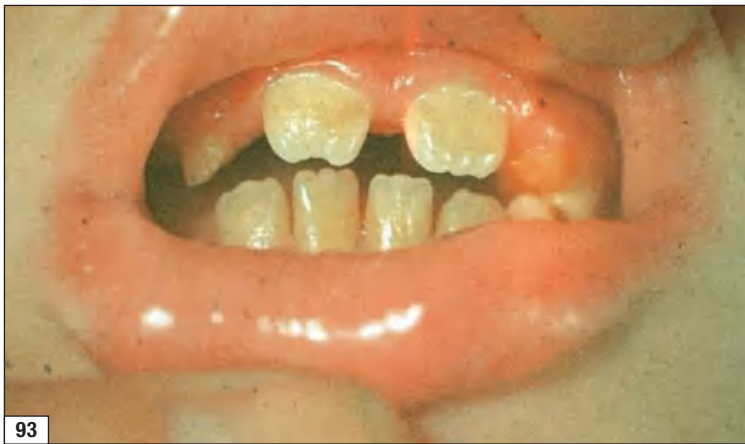Other stigmata include scarring at the commissures (rhagades or Parrot's furrows), high-arched palate and a saddle-shaped nose. Frontal and parietal bossing (nodular focal osteoperiostitis of the frontal and parietal bones called Parrot's nodes) may be seen, and learning disability, visual and hearing defects are common.

Diagnosis

Diagnosis is clinical, supported by serology.

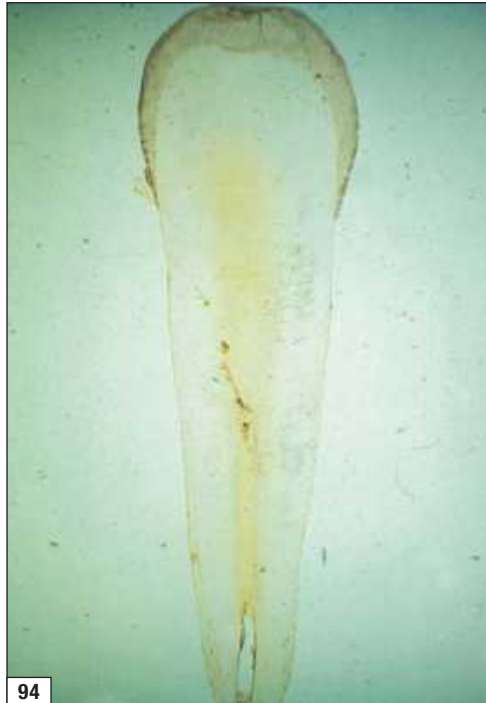Management

Medical care is usually required with antimicrobial therapy.



93

Figure 93, 94. Hutchinson's incisors in congenital syphilis.



94

VAN DER WOUDE'S SYNDROME

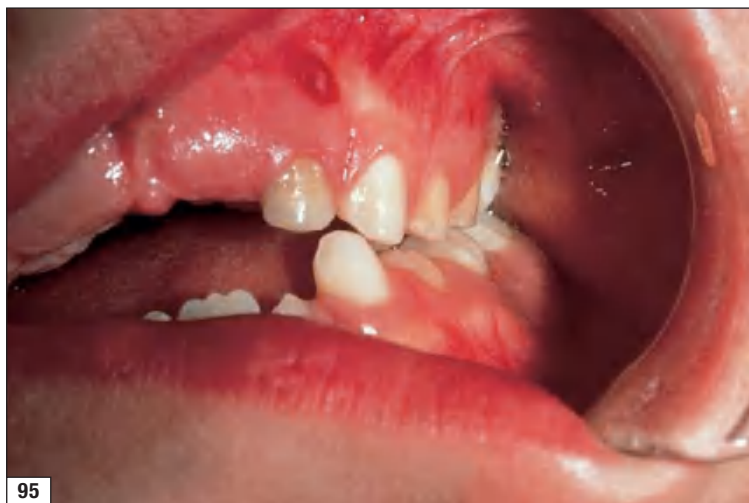Van der Woude's syndrome is a rare autosomal dominant syndrome in which lip pits (p. 31) are associated with a cleft lip and/or palate – sometimes seen with talipes equinovarus. The syndrome has a frequency of 1 in 75,000 to 1 in 100,000 in Caucasians.

VITAMIN D RESISTANT RICKETS

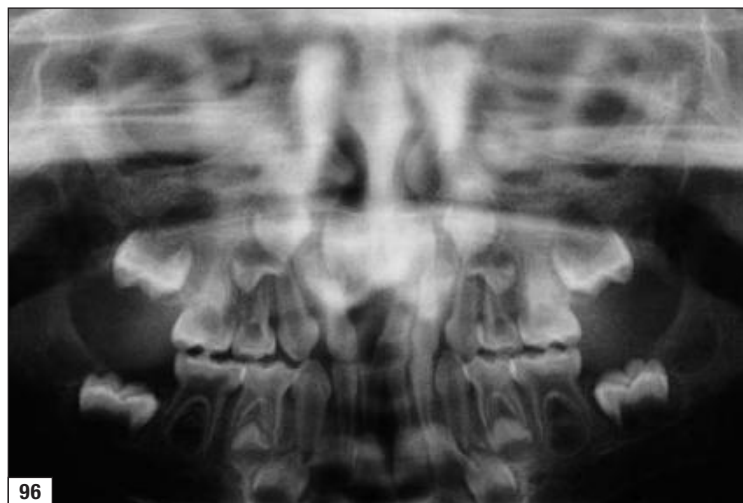
Vitamin D resistant rickets (Figs 95, 96) is characterized by:

- Hypophosphatemia associated with decreased renal tubular reabsorption of inorganic phosphates.
- Familial inheritance by X-linked dominant trait.
- Rickets or osteomalacia that does not respond to the usual doses of vitamin D.

There are marked effects on the teeth and supporting structures. The pulp horns extend nearly to the dentinoenamel junction and there is widespread formation of globular dentine with clefts in the region of the pulp horns. Consequently there is early pulpal invasion by microorganisms and resultant periapical infection is usually associated with multiple gingival fistulae even when the clinical appearance of the teeth is normal with no detectable caries. The lamina dura around the teeth is frequently absent or poorly defined and the alveolar bone pattern may be abnormal.



95



96

Figures 95, 96. Vitamin D resistant rickets.

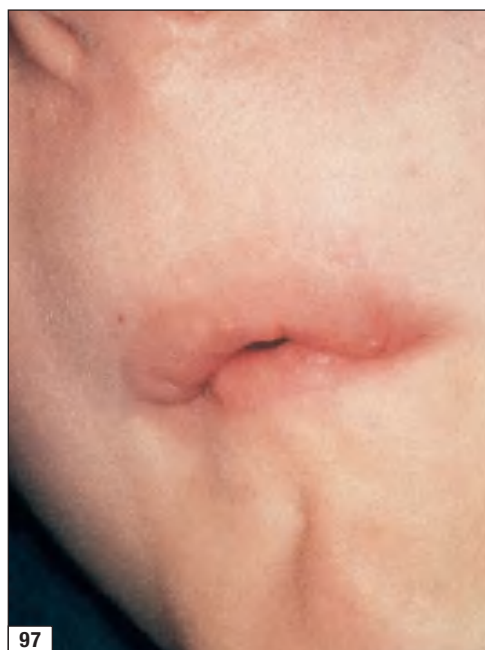WHISTLING FACE SYNDROME (CRANIOCARPOTARSAL DYSPLASIA)

The facial features of craniocarpotarsal dysplasia (Fig. 97) are variable and may include microstomia with a stiff immobile flat midface, full cheeks, small nose, long philtrum, small puckered mouth with 'H' shaped chin defect, pronounced supraorbital ridges, deep set eyes, micrognathia and short neck.

The microstomia may be marked with the intercommissural distance being about 65% of that for a normal child. The lips are pursed as in whistling in about 50% of cases.

The hard palate is often highly arched and the mandible and tongue tend to be small.

In 30% of cases a fibrous band runs from the middle of the lower lip to the chin and is demarcated by two paramedian grooves.



97

Figure 97. Whistling face syndrome.

WHITE SPONGE NEVUS (FAMILIAL WHITE FOLDED GINGIVOSTOMATOSIS)

White sponge nevus (Fig. 98) is a symptomless autosomal dominant disorder of keratins 3 and 13, which manifests from early childhood. Bilaterally, the oral mucosa is thickened, folded, spongy and white or gray. These changes are especially prominent on the buccal and labial mucosa and ventral tongue. The vaginal or anal mucosae can also be affected.

Diagnosis

Diagnosis is clinical, supported occasionally by biopsy.

Management

Reassurance only is usually required, but retinoids or tetracyclines may offer transient benefit and genetic counseling may be needed.

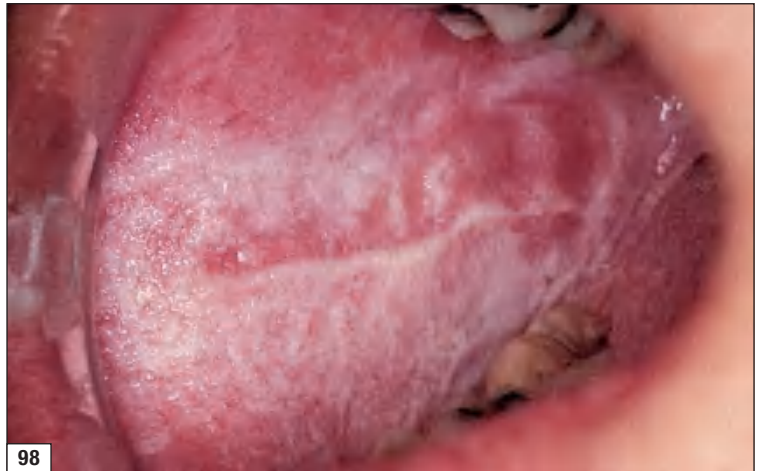

Figure 98. White sponge nevus.

3

Congenital and hereditary
disorders with lesser orofacial involvement

APERT'S SYNDROME (ACROCEPHALOSYNDACTYLY)

Craniosynostosis, a high steep forehead, ocular hypertelorism and an antimongoloid slope to the eyes are characteristics of both Apert's and Crouzon's syndromes. Apert's syndrome (Figs 99, 100) also involves progressive synostosis of bones in the hands, feet and vertebrae as well as ankylosis of joints. Palatal anomalies are common in Apert's syndrome, and one-third of patients have cleft palate. Maxillary hypoplasia is also seen.

Crouzon's syndrome is discussed on p. 49.

Diagnosis

Diagnosis is clinical, supported by imaging.

Management

Medical care is usually required and craniofacial surgery and genetic counseling may be indicated.

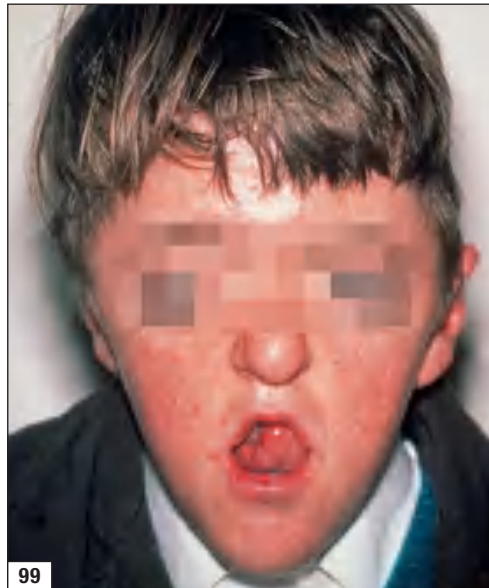

Figure 99. Apert's syndrome demonstrating the characteristic facial features.

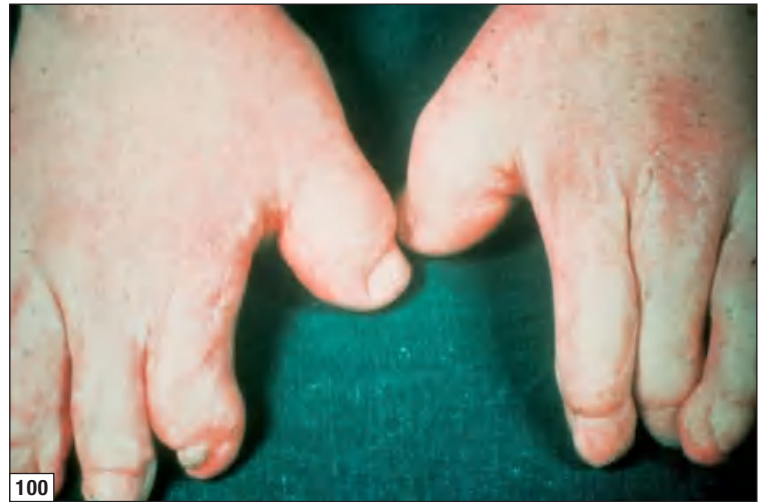

Figure 100. Digital anomalies in Apert's syndrome.

CARNEY SYNDROME

Carney syndrome, characterized by the complex of myxomas, spotty pigmentation and endocrine overactivity, is an autosomal dominant trait associated with cardiac myxomas. The pigmented lesions, usually develop in the first decade of life on the face and lips, and are similar to those in patients with Peutz-Jeghers syndrome.

Diagnosis

Diagnosis is clinical, supported by imaging and biochemistry.

Management

Medical care is usually required and genetic counseling may be indicated.

CHONDROECTODERMAL DYSPLASIA (ELLIS-VAN CREVELD SYNDROME)

Dwarfism, polydactyly, ectodermal dysplasia affecting nails and teeth, multiple frenae and hypoplastic teeth characterize this autosomal recessive syndrome (Figs 101–103). Fusion of the upper lip to the midline gingiva, and natal teeth are other common oral findings.



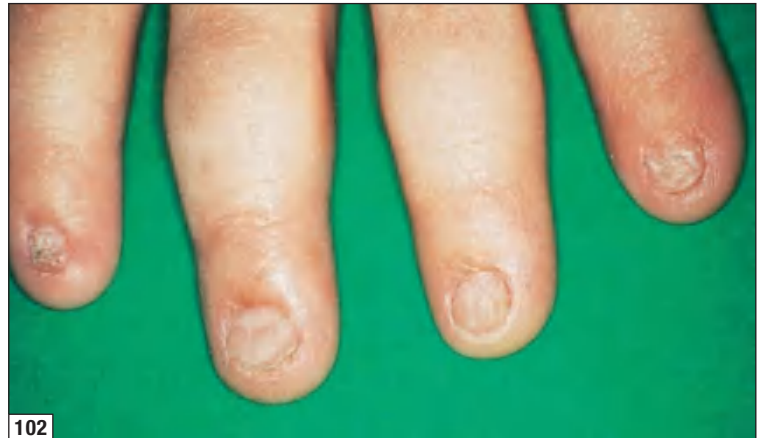101 **Figure 101.** Chondroectodermal dysplasia. Affected children are of small stature and often there is a marked genu valgum deformity.

Diagnosis

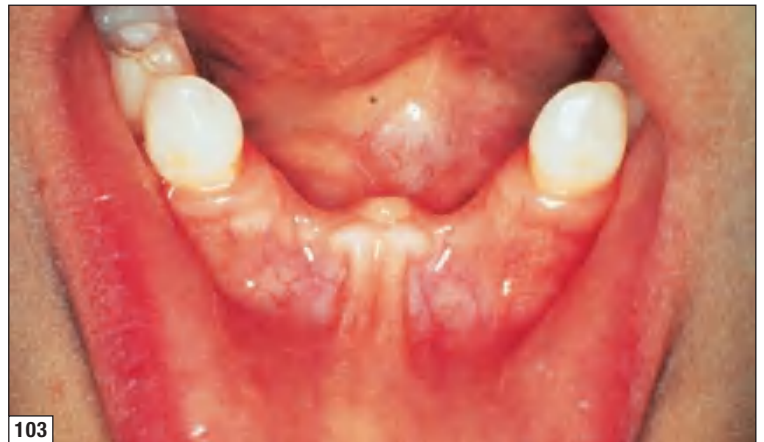Diagnosis is clinical, supported by imaging.

Management

Medical care is usually required and genetic counseling.



102 **Figure 102.** Dysplastic nails in chondroectodermal dysplasia.



103 **Figure 103.** The lower jaw in chondroectodermal dysplasia demonstrating hypodontia and high frenal attachments.

CLEIDOCRANIAL DYSPLASIA (CLEIDOCRANIAL DYSOSTOSIS)

Cleidocranial dysplasia (Figs 104–108) is an inherited defect of membranous bones and is often an autosomal dominant trait. Defects involve mainly the skull and clavicles. The skull sutures remain open and multiple wormian bones are evident in the occipitoparietal region. Persistence of the metopic suture gives rise to a vertical midline furrow in the forehead with frontal bossing.

The clavicles are hypoplastic or aplastic and when the patient attempts to bring the shoulders forward and together they can almost be approximated. Pelvic anomalies may be seen and kyphoscoliosis is common.

The midface is hypoplastic. The dentition may be compromised because of delayed eruption or impaction of teeth and the presence of multiple supernumerary teeth.

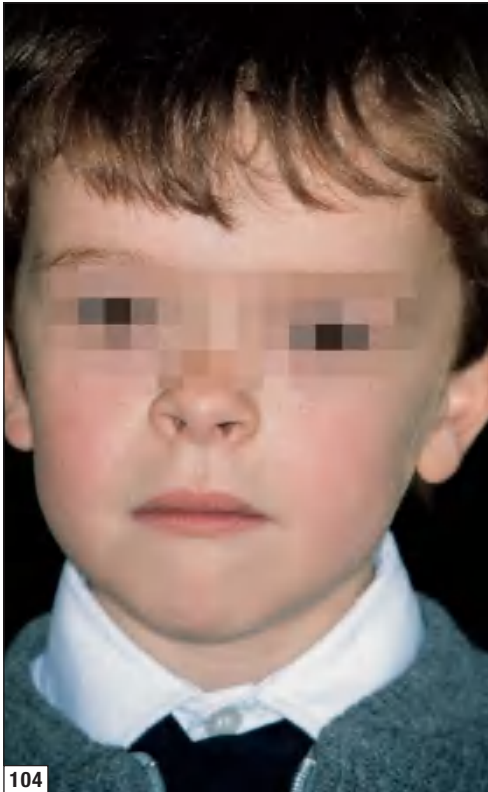

Figure 104. Hypertelorism in cleidocranial dysplasia.

Diagnosis

Diagnosis is clinical, supported by imaging, which shows multiple supernumerary, unerupted and impacted teeth. Dentigerous cysts are common.

Management

Medical care is usually required and surgery and genetic counseling may be indicated.

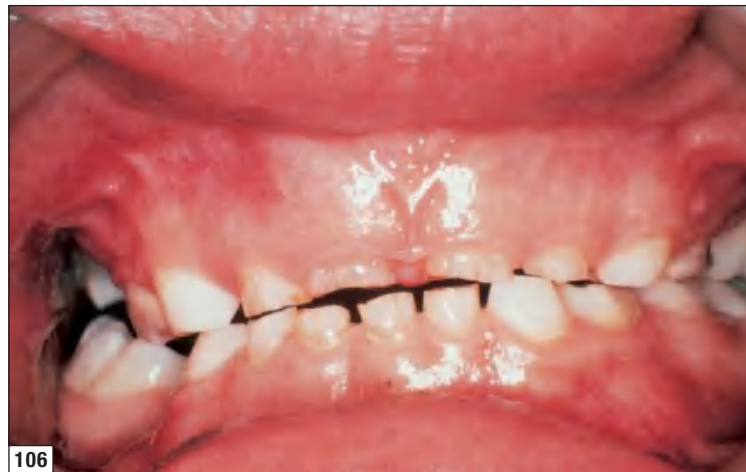

Figure 106. A 14-year-old patient with cleidocranial dysplasia, showing retention of the primary dentition.

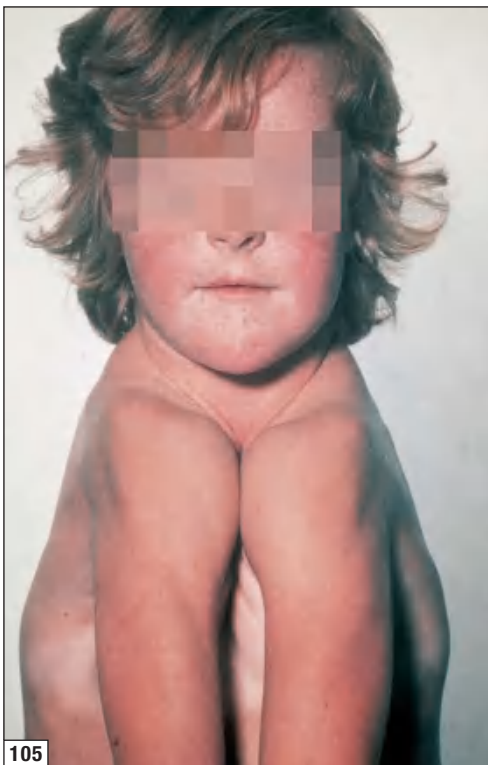

Figure 105. Absence of clavicular development allows the shoulders to be approximated in cleidocranial dysplasia.

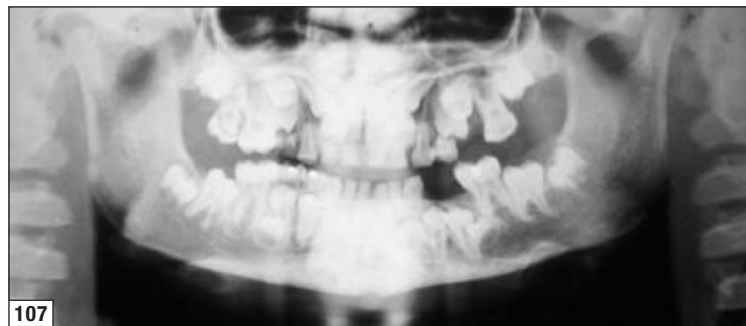


Figure 107. The panoramic view of the patient in Figure 106 showing the presence of unerupted supernumerary and normal permanent teeth.

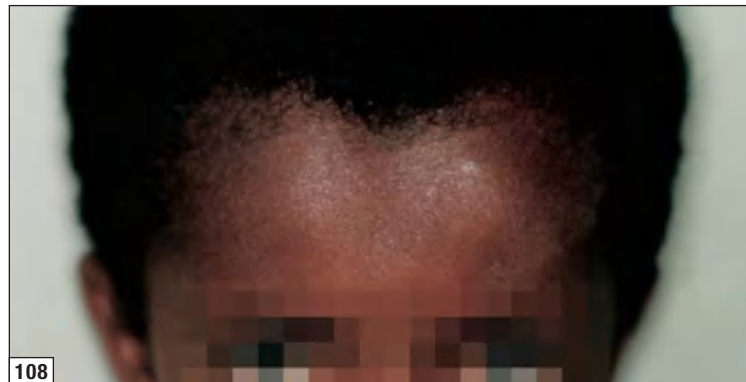

Figure 108. Frontal bossing because of persistent metopic suture in cleidocranial dysplasia.

COFFIN–LOWRY SYNDROME

Coffin–Lowry syndrome (Fig. 109) is an X-linked disease with a mutation at Xp 22.1–22.2. Diagnosis is often established late after skeletal deformities have appeared. Coffin–Lowry syndrome is characterized by puffy lax tapering fingers, learning disability (with greater severity in males), coarse facial features similar to those in acromegaly and musculoskeletal, central nervous system, cardiovascular and dermatological anomalies. Specific facial features include hypertelorism, prominent supraorbital ridges, ptosis of the eyelids, hypoplastic midface with a broad nasal base and prominent ears.

Specific oral features include thick pouting lips, deep midline furrowed tongue, high vaulted palate, mandibular prognathism, microdontia, spacing between teeth, early loss of teeth and delayed eruption of teeth.

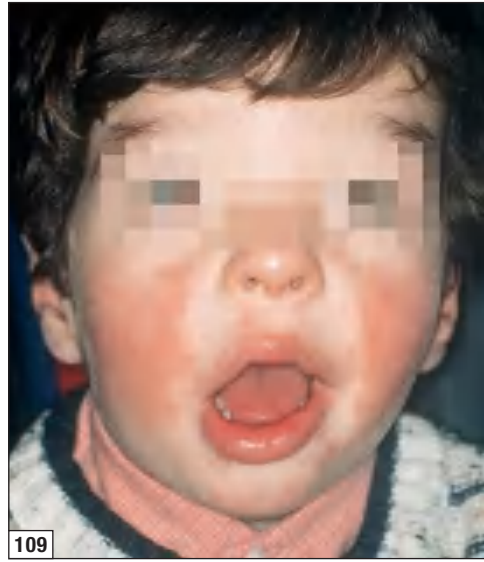

Figure 109.
Coffin–Lowry
syndrome.

COWDEN'S SYNDROME (MULTIPLE HAMARTOMA AND NEOPLASIA SYNDROME)

Cowden's syndrome (Figs 110, 111) is an autosomal dominant condition of multiple hamartomas, with a predisposition to tumors in adult life, particularly carcinomas of breast, thyroid and colon. Mucocutaneous lesions often precede the appearance of the malignant disease.

Papular oral lesions are common. Other oral lesions may include fissured tongue, hypoplasia of the uvula, and maxillary and mandibular hypoplasia.

Large numbers of papillomatous lesions are seen on the skin, especially over the neck, nose and ear. Other manifestations of Cowden's syndrome include small keratoses on the palms and soles, learning disability and motor incoordination.

Diagnosis

Diagnosis is clinical, supported by imaging.

Management

Medical care is usually required and genetic counseling may be indicated.

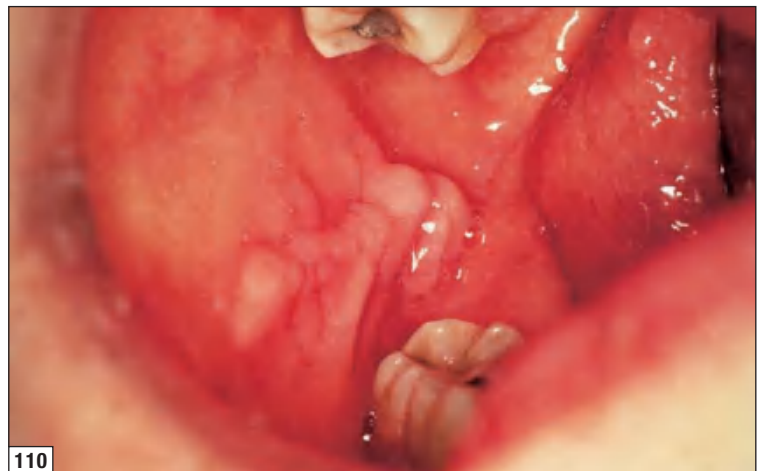

Figure 110. Oral papular lesions in Cowden's syndrome.

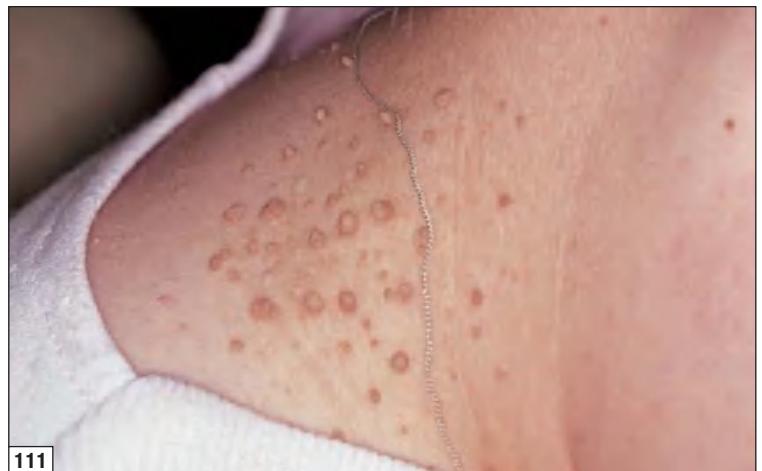

Figure 111. Papillomatous skin lesions in Cowden's syndrome.

CROUZON'S SYNDROME (CRANIOFACIAL DYSOSTOSIS)

Craniosynostosis, ocular hypertelorism and proptosis are characteristics of Crouzon's syndrome (Fig. 112), which is an autosomal dominant condition. Craniosynostosis, abnormal skull morphology and pronounced digital impressions ('copper-beaten skull') are seen on skull radiography. Pronounced lateral palatal swellings, malocclusion and clefting defects are oral findings.

Diagnosis

Diagnosis is clinical, supported by imaging.

Management

Medical care is usually required and craniofacial surgery and genetic counseling may be indicated.

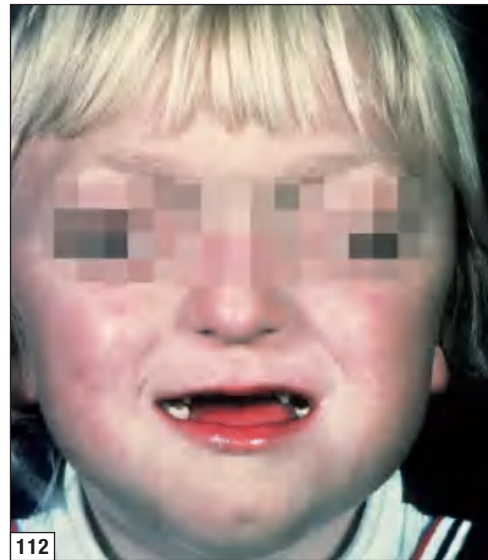

Figure 112. Crouzon's syndrome showing pronounced hypertelorism.

DYSKERATOSIS CONGENITA

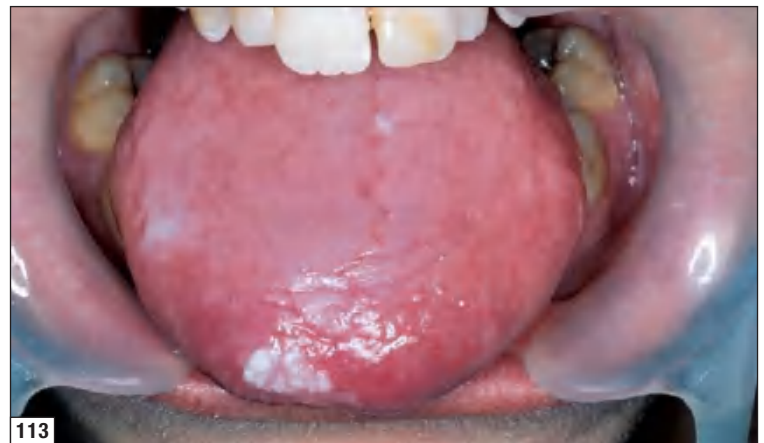Dyskeratosis congenita (Figs 113, 114) is an inherited, usually X-linked, disorder characterized by skin pigmentation, nail dystrophy and mucosal leukoplakia. As well as a variety of noncutaneous abnormalities, most patients have bone marrow failure and some also develop myelodysplasia and acute myeloid leukemia. Pancytopenia as well as humoral and cellular immune defects may lead to severe infections, which represent the main cause of death. The pathogenesis of dyskeratosis congenita is still unclear and a curative therapy is presently lacking. Pulmonary abnormalities are present in 19% of patients. The phenotype is less severe in affected females.

Diagnosis

Diagnosis is clinical, supported by hematology and marrow biopsy.

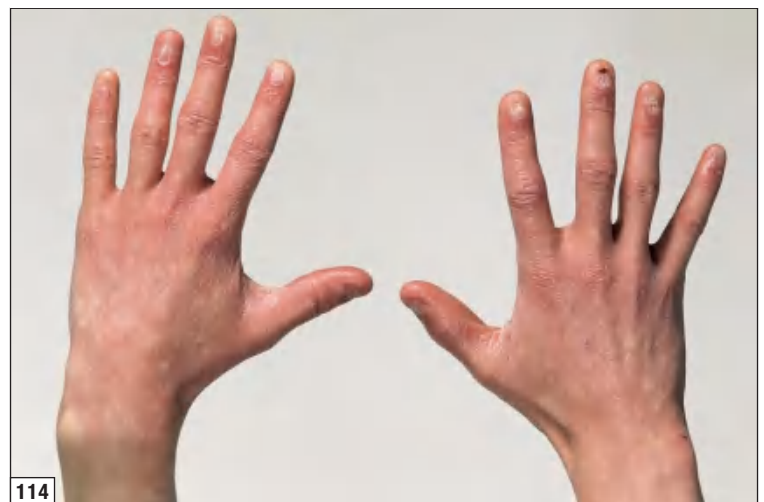Management

Medical care is required and genetic counseling may be indicated. Bone marrow transplantation is often indicated. Hematopoietic growth factors (granulocyte colony stimulating factor or granulocyte-macrophage colony stimulating factor) can be beneficial.



113

Figure 113. Dyskeratosis congenita showing oral leukoplakia.



114

Figure 114. Dyskeratosis congenita showing hands and nail dystrophy.

ECTODERMAL DYSPLASIA

Hypohidrotic ectodermal dysplasia (Figs 115–120) is a usually X-linked disorder characterized by sparse hair (hypotrichosis), absent sweat glands (hypohidrosis) and consequent fever. There may be respiratory infections and sometimes frontal bossing. Patients are otherwise well and mentally normal.

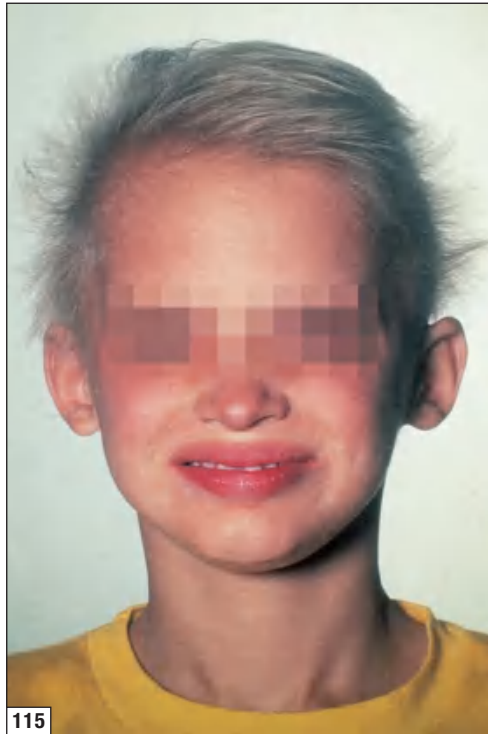

Figure 115. Characteristic facial appearance of X-linked hypohidrotic ectodermal dysplasia.

There is usually hypodontia rather than anodontia, and the few teeth that are present are often a simple conical shape and erupt late. The lower one-third face height may, therefore, be reduced.

Salivary gland hypoplasia and the subsequent dry mouth predisposes to caries.

Rare varieties include an autosomal dominant variety (the 'tooth and nail' type), characterized by hypodontia and hypoplastic nails, and a subtype in which teeth are normal (hypohidrotic ectodermal dysplasia with hypothyroidism).

Diagnosis

Diagnosis is clinical, supported by imaging and sweat tests.

Management

Medical care is usually required and restorative dentistry and genetic counseling may be indicated.

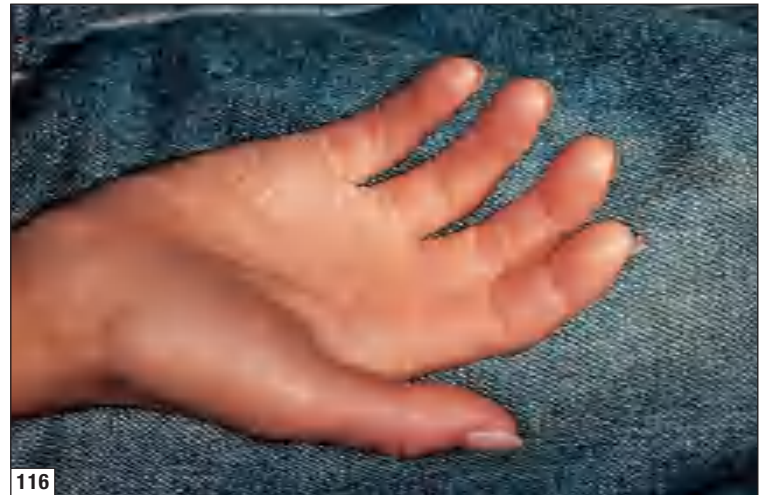
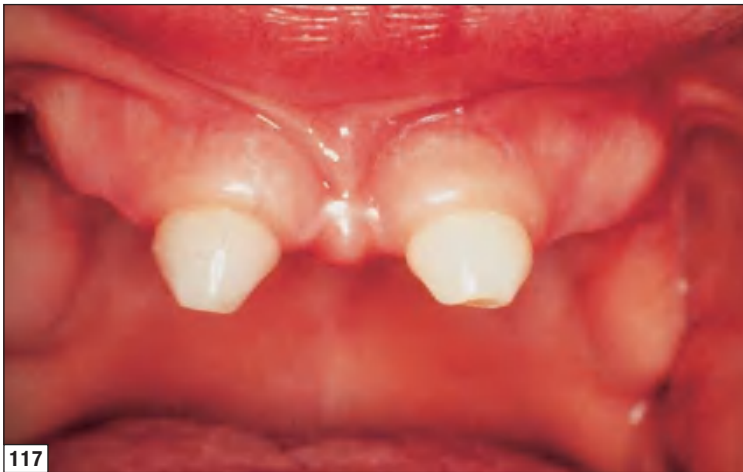
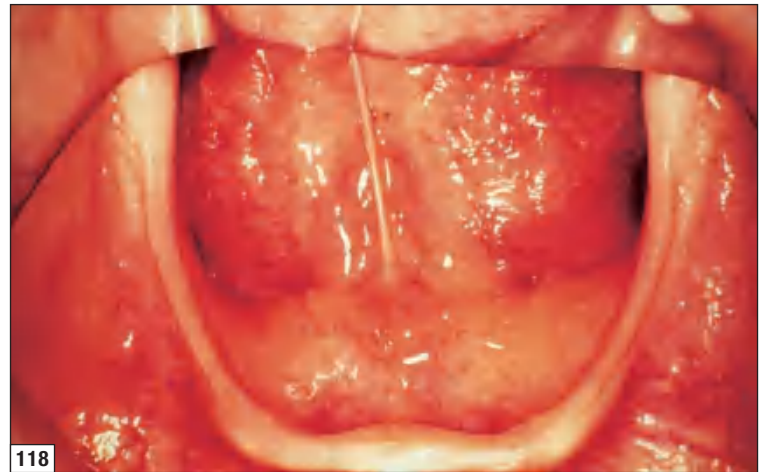Figure 116. Xeroderma in hypohidrotic ectodermal dysplasia.



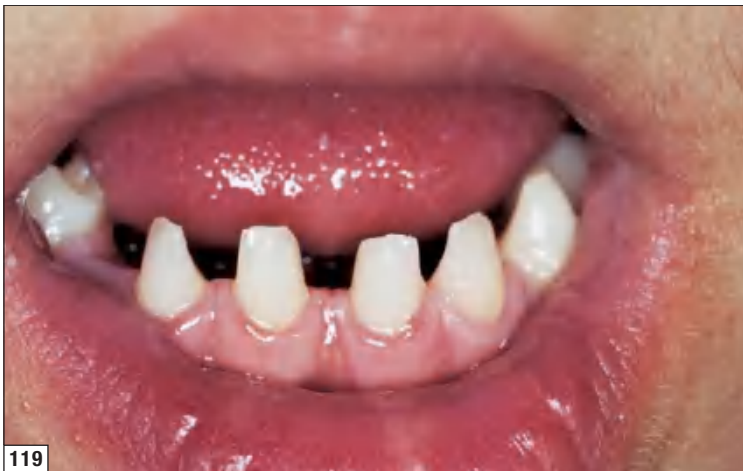117

Figure 117. Severe hypodontia in X-linked hypohidrotic ectodermal dysplasia. The primary canines are retained, but there is absence of all the permanent teeth.



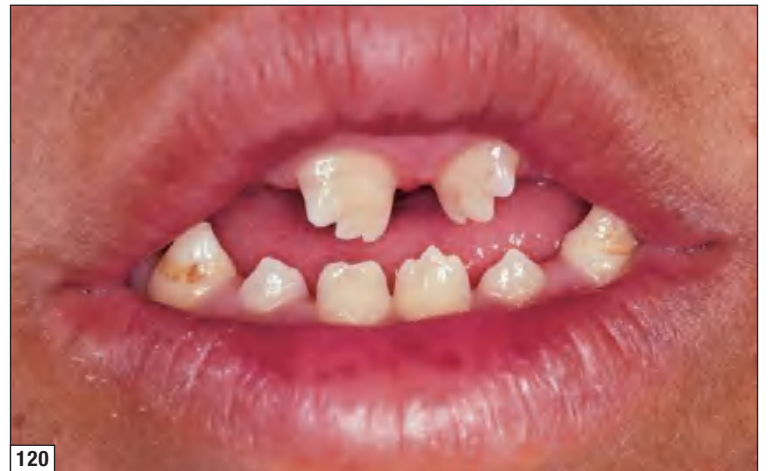118

Figure 118. The lower arch of a patient with hypohidrotic ectodermal dysplasia. All permanent teeth are absent.



119

Figure 119. Hypodontia and conical teeth in hypohidrotic ectodermal dysplasia.



120

Figure 120. Dental anomalies in hypohidrotic ectodermal dysplasia.

EHLERS–DANLOS SYNDROME

Ehlers–Danlos syndrome (Figs 121–124) comprises a group of disorders of collagen that are usually inherited as autosomal dominant traits. Hypermobility of joints is common; the skin is soft, extensible and fragile; purpura is common in some types and there may be other defects, such as mitral valve prolapse.

Although most affected individuals have normal teeth, small teeth with abnormal roots and multiple pulp stones may be found. Type

VIII Ehlers–Danlos syndrome is associated with early onset periodontal disease.

Diagnosis

Diagnosis is clinical, supported by imaging.

Management

Medical care is usually required and periodontal care and genetic counseling may be indicated.

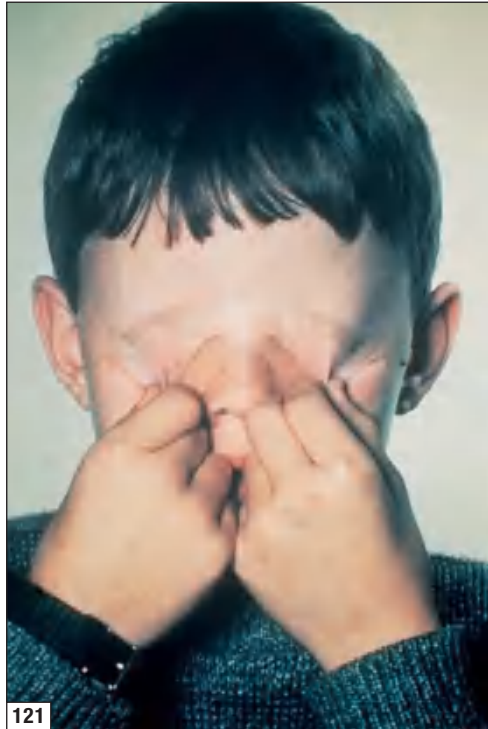

Figure 121. Hyperelasticity of the skin in Ehlers–Danlos syndrome.

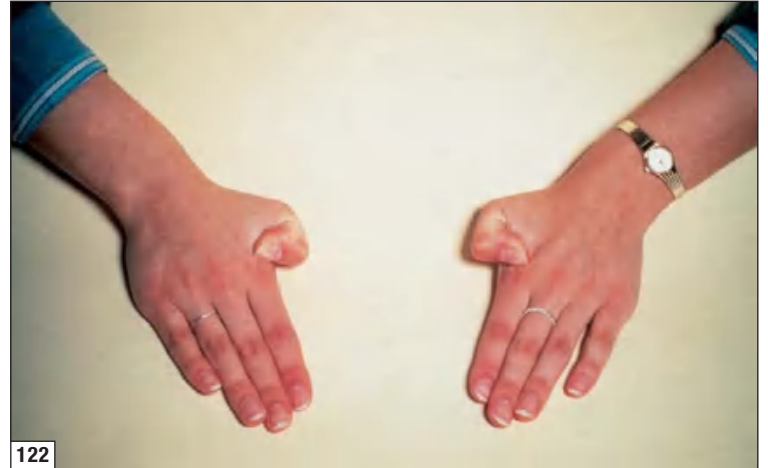

Figure 122. Hypermobility of the joints in Ehlers–Danlos syndrome.

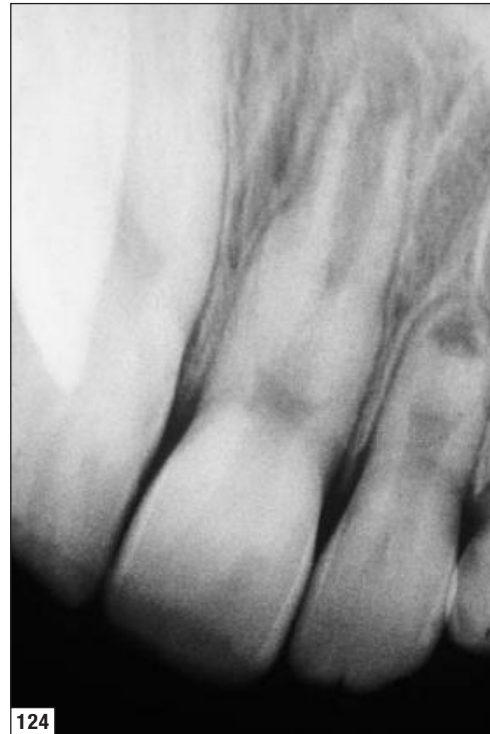

Figure 124. Premature apical closure, cessation of root growth and intrapulpal calcification in Ehlers–Danlos syndrome.

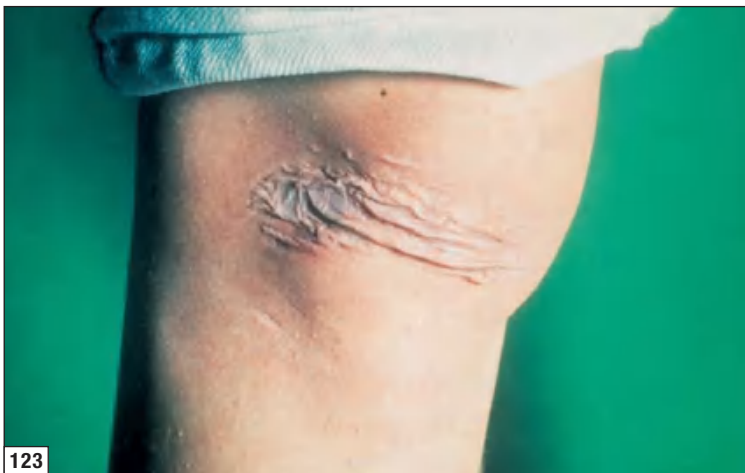

Figure 123. Because of the hyperelasticity of the skin, healing of skin lacerations over joints in Ehlers–Danlos syndrome can result in a very fine papyraceous scarring, as shown here. This easily breaks down and these lesions are best treated by a period of joint immobilization.

EPIDERMOLYSIS BULLOSA

Epidermolysis bullosa (Figs 125–127) is a group of rare inherited disorders of type VII procollagen in skin and mucosa epithelial basement membrane, mostly characterized by vesiculation at the epithelial basement membrane zone in response to minor trauma and consequent scarring. An acquired form of epidermolysis bullosa (epidermolysis bullosa acquisita) is a chronic blistering disease of skin and mucosae with autoantibodies to type VII procollagen of epithelial basement membranes.

In most forms, bullae appear in the mouth early in life, often precipitated by suckling, and break down to persistent ulcers that eventually heal with scarring. The tongue becomes depapillated and scarred.

Oral lesions are seen only rarely in the nonscarring simplex type of epidermolysis bullosa, in which the vesiculation is intraepithelial.

Enamel hypoplasia may be seen and in view of the fragility of mucosa, oral hygiene tends to be neglected with subsequent caries and periodontal disease. Squamous cell carcinoma is a rare complication.

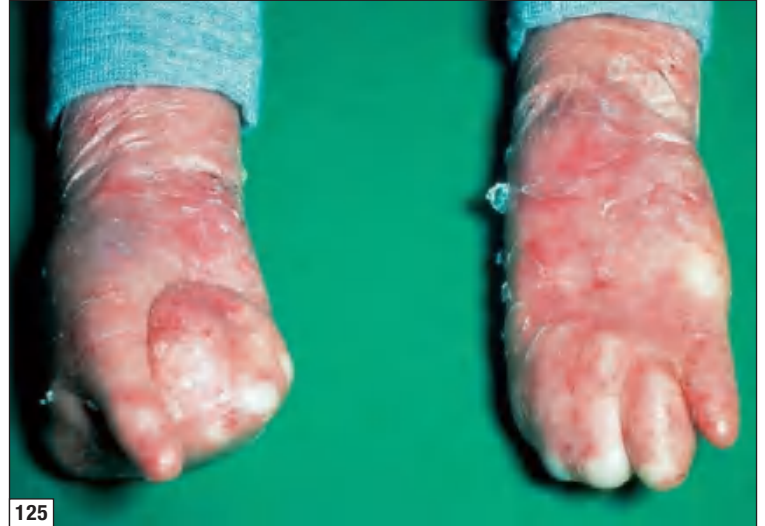Scarring with the dystrophic form affects the extremities, including the nails.

Diagnosis

Diagnosis is clinical, supported by biopsy.

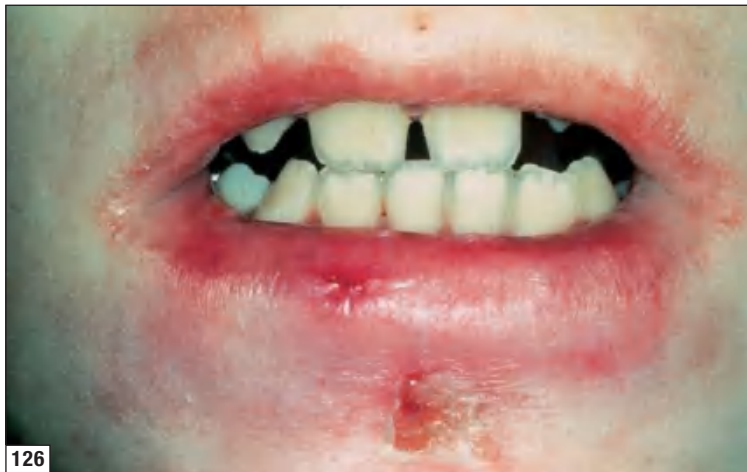Management

Medical care is usually required and genetic counseling may be indicated.



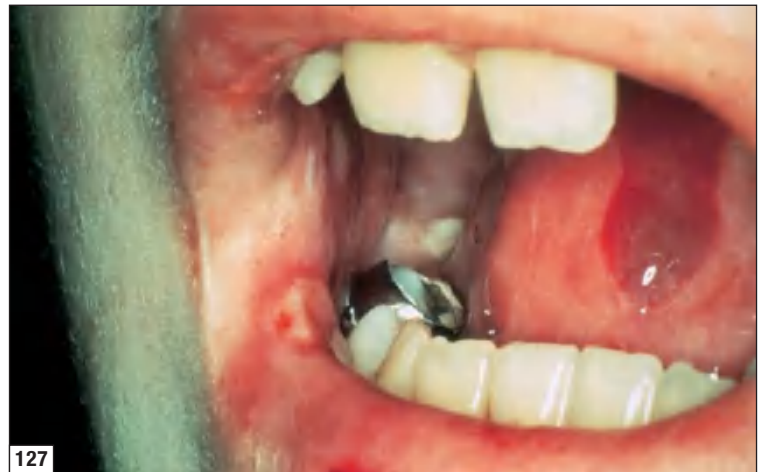125

Figure 125. The hands in epidermolysis bullosa – the result of repeated epidermal breakdown and scarring.



126

Figure 126. Scarring of the lower lip as a result of repeated bullae formation in epidermolysis bullosa.



127

Figure 127. Intraoral bullae demonstrating the extremely fragile mucosa in epidermolysis bullosa.

**EPILOIA (TUBEROUS SCLEROSIS;
BOURNEVILLE-PRINGLE DISEASE)**

Tuberous sclerosis (Figs 128–132) is an autosomal dominant condition, possibly related to a defect on chromosome 9, that is associated with neurological abnormalities and skin lesions. Most patients are prone to seizures and learning disability. Cerebral calcifications are seen on imaging.

Angiofibromas, typically seen in the nasolabial fold are pathognomonic, can be severely disfiguring and may involve other sites, such as the chin (adenoma sebaceum). Fibrous plaques on the forehead and 'shagreen patches' elsewhere and hypopigmented 'ash leaf' patches seen on the trunk are other cutaneous features. Subungual fibromas are another pathognomonic feature and may be seen with longitudinal ridging of the nails.

Patients may also have cardiac rhabdomyoma or renal hamartomas (cysts or angiomyolipomas).

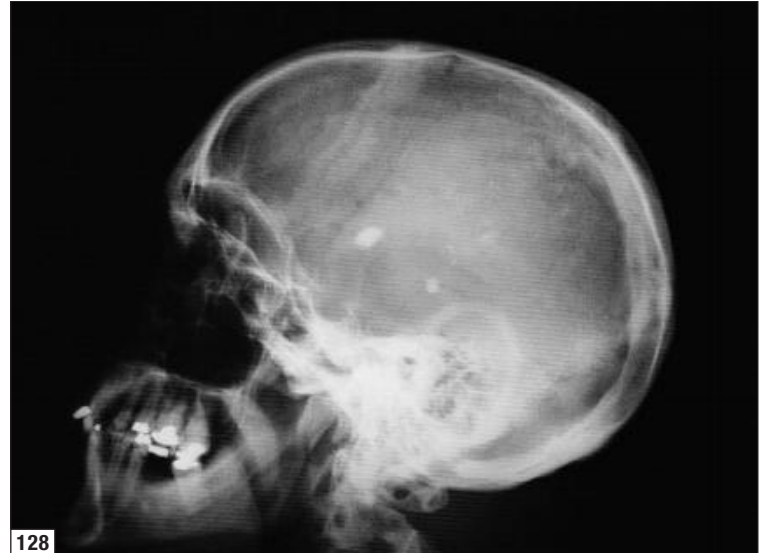Papilliferous oral mucosa lesions may be seen and pit-shaped enamel defects are a feature. Occasional patients may have phenytoin-associated gingival enlargement.

Diagnosis

Diagnosis is clinical, supported by imaging.

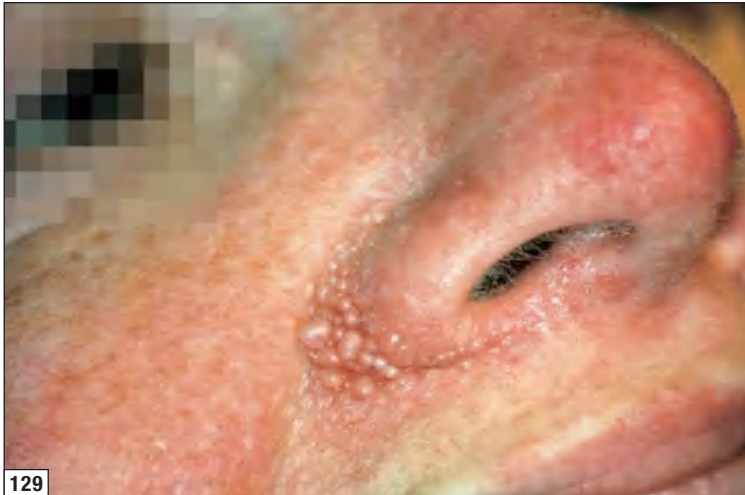Management

Medical care is usually required and genetic counseling may be indicated.



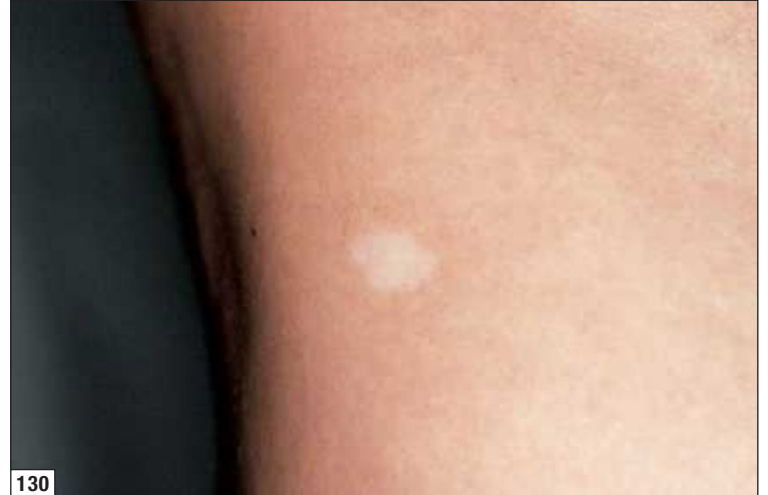128

Figure 128. Cerebral calcifications in epiloia (tuberous sclerosis).



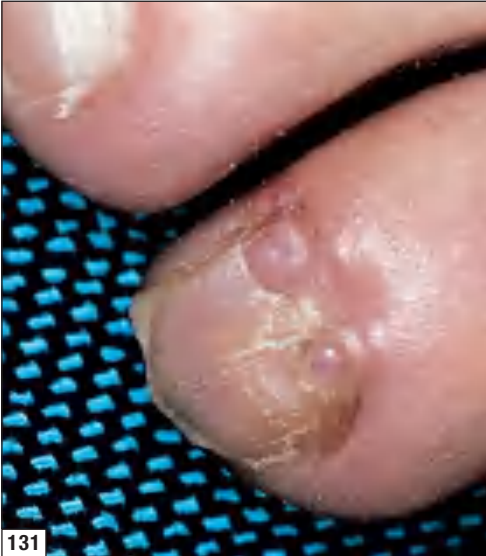129

Figure 129. Adenoma sebaceum in epiloia.



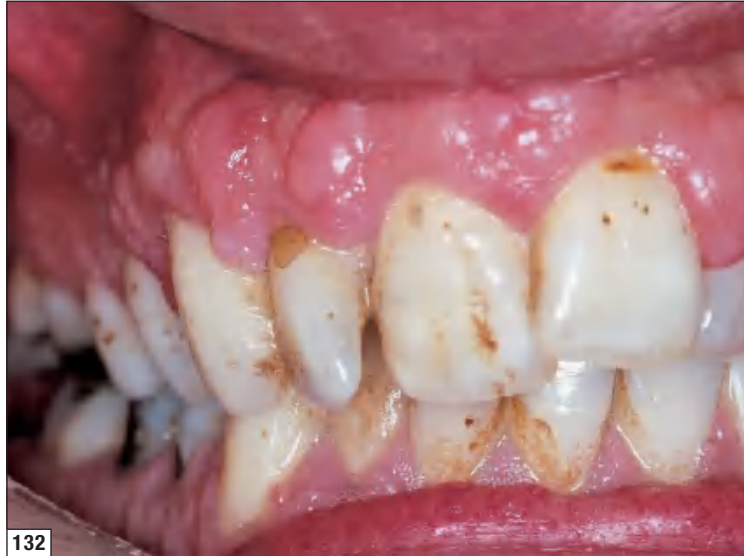130

Figure 130. 'Ash leaf' depigmentation in epiloia.



131

Figure 131. Subungual fibromas in epiloia.



132

Figure 132. Gingival fibrous plaques, and pitting hypoplasia of the tooth enamel in an adolescent with epiloia.

FRAGILE X SYNDROME (MARTIN-BELL SYNDROME)

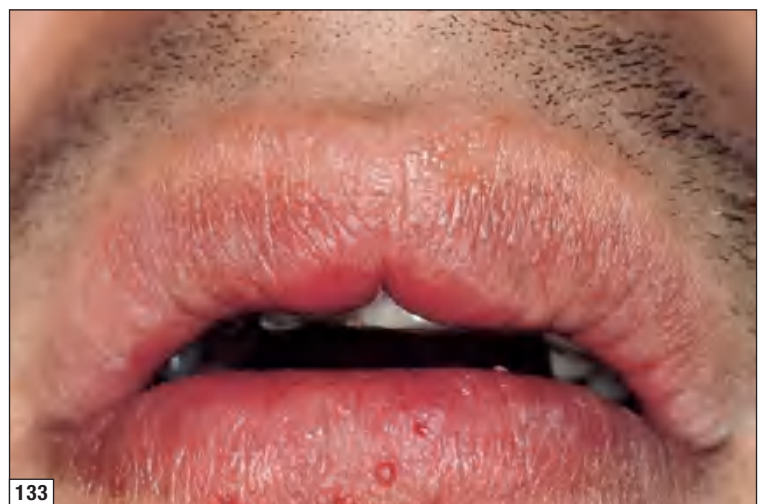Fragile X syndrome (Fig. 133) is a relatively common X-linked mental retardation syndrome in which males are moderately to severely affected while females are only mildly affected. Besides learning disability, there may be attention-deficit hyperactivity disorder, avoidant disorder, pervasive developmental disorder, anxiety disorder, mood disorder and schizotypal personality disorder. The range of defects is wide – mild connective tissue dysplasia, macro-orchidism, prominent jaw, large ears and a broad nasal bridge are common findings. Hypotonicity, submucous cleft and mitral valve prolapse may be seen.

Diagnosis

Diagnosis is clinical, supported by karyotyping.

Management

Medical care is usually required and genetic counseling may be indicated.



133

Figure 133. Fragile X syndrome: abnormal lip morphology.

GARDNER'S SYNDROME

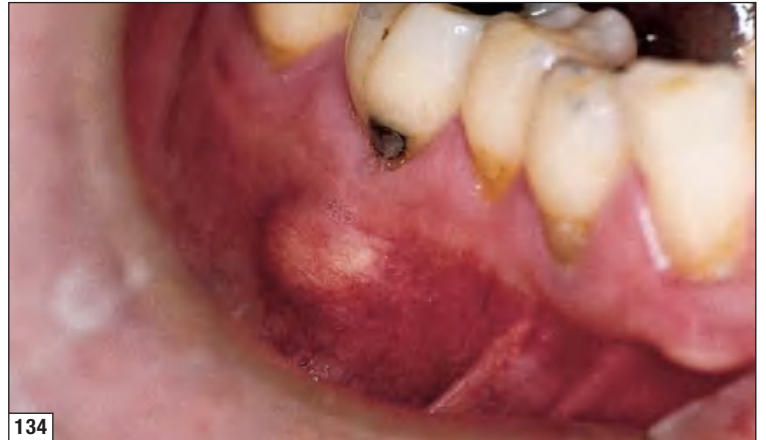Gardner's syndrome (Fig. 134) is an autosomal dominant condition that presents with jaw osteomas, polyposis coli, epidermoid cysts, desmoid tumors and pigmented lesions of the fundus of the eye. The patient may eventually develop colonic carcinoma. Multiple odontomas, supernumerary teeth and impacted teeth may be seen radiographically.

Diagnosis

Diagnosis is clinical, supported by imaging.

Management

Medical care is usually required and genetic counseling may be indicated. Surgical removal of the jaw osteomas is indicated to correct facial deformity.



134

Figure 134. Gardner's syndrome showing osteoma.

**GOLDENHAR'S SYNDROME
(OCULO-AURICULO-VERTEBRAL DYSPLASIA)**

In Goldenhar's syndrome (Figs 135, 136), defects of the eye, ears and vertebrae are associated with orofacial, cardiac, respiratory, renal, gastrointestinal and nervous system abnormalities.

Orofacial manifestations include unilateral facial hypoplasia, zygomatic, temporal, and maxillary hypoplasia, aplasia or hypoplasia of mandibular ramus and/or condyle with absence of the glenoid fossa, and flattening of the gonial angle. Macrostomia, high palate, cleft lip and palate, palate and tongue muscle hypoplasia and/or paralysis, bifid tongue, bifid uvula, double lingual frena, enlarged philtrum and hypodontia may also be seen. There may be agenesis of the ipsilateral parotid salivary gland and aberrant salivary gland tissue.

Diagnosis

Diagnosis is clinical, supported by imaging.

Management

Medical care is usually required and craniofacial surgery and genetic counseling may be indicated.

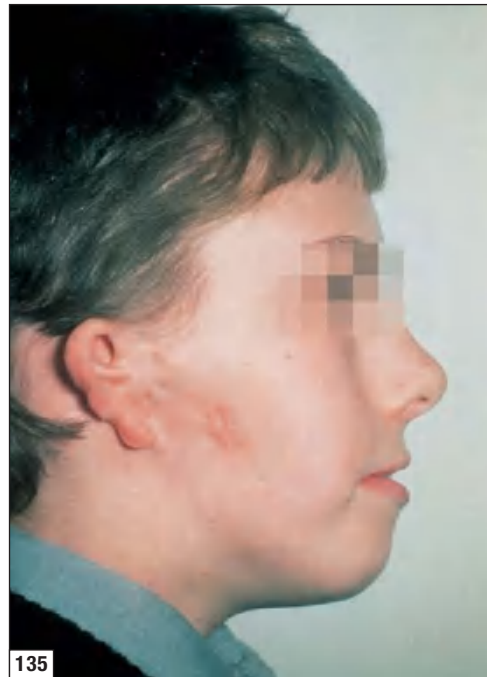

Figure 135. Goldenhar's syndrome demonstrating unilateral facial hypoplasia with failure of development of the external auditory meatus, canal and pinna of the ear. Accessory auricular appendages have been surgically removed.

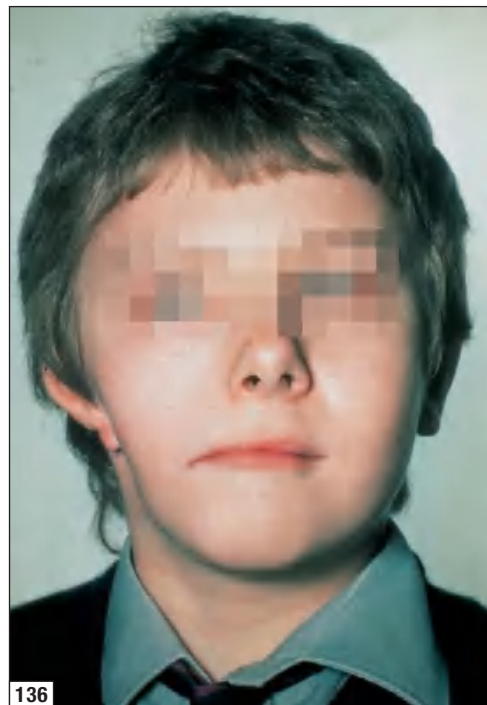

Figure 136. Goldenhar's syndrome.

GORLIN'S SYNDROME (GORLIN–GOLTZ SYNDROME, NEVOID BASAL CELL CARCINOMA SYNDROME)

Gorlin's syndrome (Figs 137–139) is an autosomal dominant condition of multiple basal cell nevi, with odontogenic keratocysts and other features. Frontal and parietal bossing and a broad nasal root give the typical facial appearance.

Multiple basal cell lesions, often with milia, appear in childhood or adolescence, mainly over the nose, eyelids and cheeks. Only about 50% of patients have marked numbers of nevoid basal cell carcinomas and only rarely are the lesions aggressive. Pits may be seen in the soles or palms. Occasionally, basal cell carcinomas arise in these pits.

Odontogenic keratocysts develop mainly in the mandible and during the first 30 years of life. Cleft lip and/or palate are seen in about 5% of patients.

Calcification of the falx cerebri is a common feature, occurring in over 80% of patients. There are many skeletal anomalies, but bifid ribs, kyphoscoliosis and other vertebral defects are common.

Medulloblastomas and other brain tumors have been reported, as have a range of neoplasms of other tissues, especially cardiac fibromas.

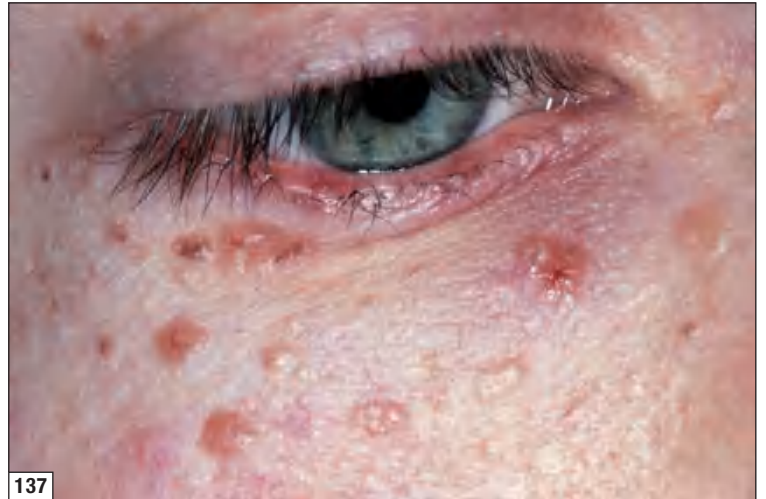Other occasional associations include pseudohypoparathyroidism and diabetes mellitus.

Diagnosis

Diagnosis is clinical, supported by imaging and biopsy of jaw and skin lesions.

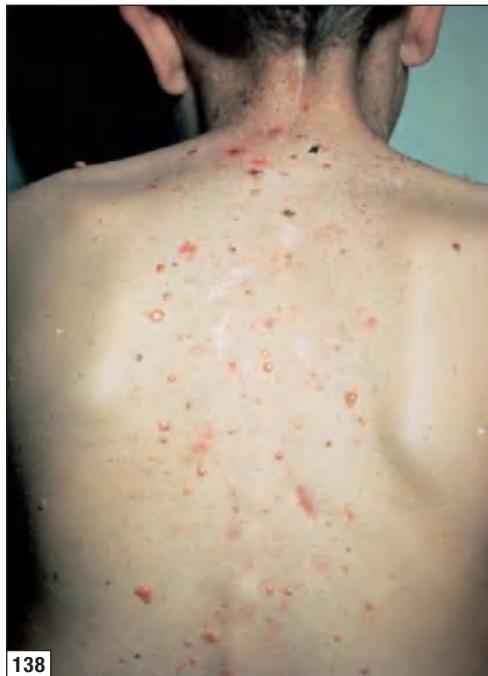Management

Medical care is usually required and surgery and genetic counseling may be indicated.



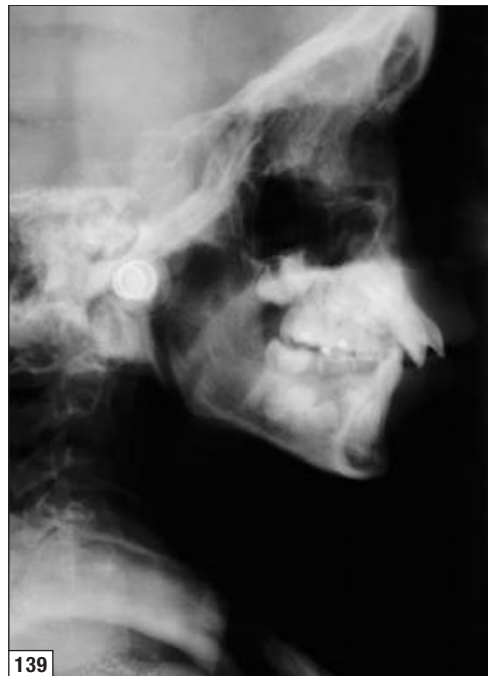137

Figure 137. Basal cell nevi in Gorlin's syndrome.



138

Figure 138. Multiple basal cell nevi on the back of a boy with Gorlin's syndrome.



139

Figure 139. Gorlin's syndrome – radiograph showing odontogenic keratocysts.

INCONTINENTIA PIGMENTI (BLOCH-SULZBERGER DISEASE)

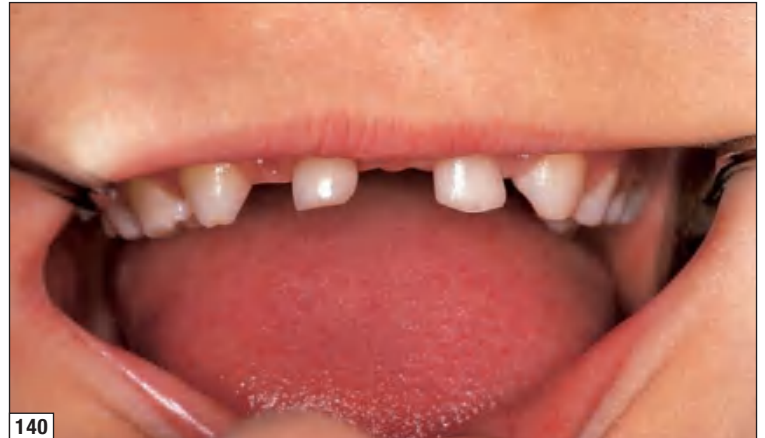Incontinentia pigmenti (Figs 140, 141) is a type of ectodermal dysplasia. It is a rare dominant disorder seen virtually only in females. Pigmented, vesicular or verrucous skin lesions are seen, often with learning disability and visual defects. Most patients have anomalies in both dentitions. Hypodontia, conical teeth and delayed eruption are the usual features.

Diagnosis

Diagnosis is clinical, supported by imaging.

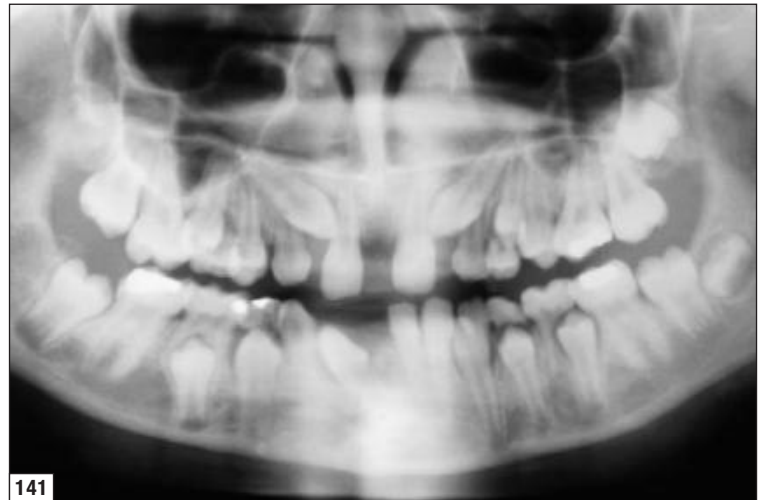
Management

Medical care is usually required and restorative dentistry and genetic counseling may be indicated.



140

Figure 140. Incontinentia pigmenti, showing hypodontia.



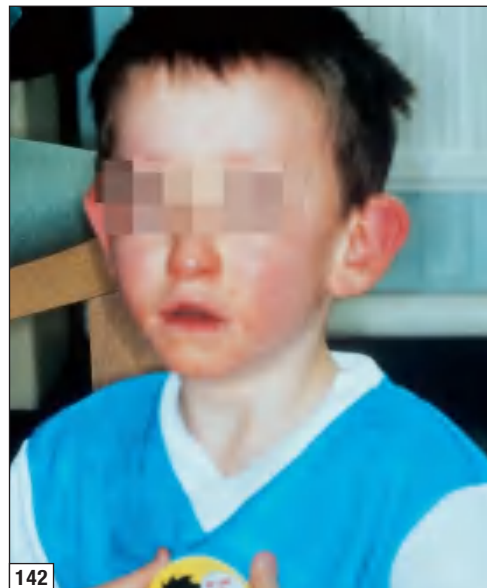141

Figure 141. Incontinentia pigmenti showing missing lateral incisors.

KABUKI MAKE-UP SYNDROME

Kabuki make-up syndrome (Fig. 142) is characterized by mild-to-moderate learning disability, postnatal progressive growth retardation and strikingly unusual facies reminiscent of the make-up used in the Kabuki theatre. The nose is broad with a depressed tip and or short septum and the ears are outstanding with prominent lobes. The teeth are widely spaced and cleft lip and/or cleft palate or submucous cleft is common. Over 30% have retrognathia. Congenital cardiac anomalies have been reported in about 30% of patients and these are mainly atrial septal defects, ventricular septal defects, single ventricle with common atrium, patent ductus arteriosus and coarctation of the aorta.

Short stature, short fifth fingers, scoliosis, rib anomalies, spina bifida occulta and dislocation of the hip are also commonly reported.



142

Figure 142. Kabuki syndrome.

MUCOPOLYSACCHARIDOSES

Deficiency of mucopolysaccharidases leads to the accumulation of mucopolysaccharides (glycosaminoglycans) and one of a number of syndromes characterized by dwarfism, hirsutism, coarse features, and macroglossia, often with learning disability, deafness, cardiac failure and corneal clouding.

Hurler's syndrome or gargoylism

Hurler's syndrome (Figs 143, 144) is the most common mucopolysaccharidosis. It manifests in early childhood with deteriorating mental and physical development. The head is large with premature closure of sagittal and metopic sutures. The pituitary fossa is boot- or slipper-shaped. Hepatosplenomegaly causes abdominal swelling, and umbilical hernia is common. Characteristic 'claw hand' occurs because the joints cannot be fully extended. There are also flexion contractures in many other joints.

Upper respiratory infections, cardiomegaly and murmurs are common. Delayed or incomplete eruption of teeth and radiolucent lesions around the crowns of the lower second molars may occur as well as temporomandibular joint anomalies.

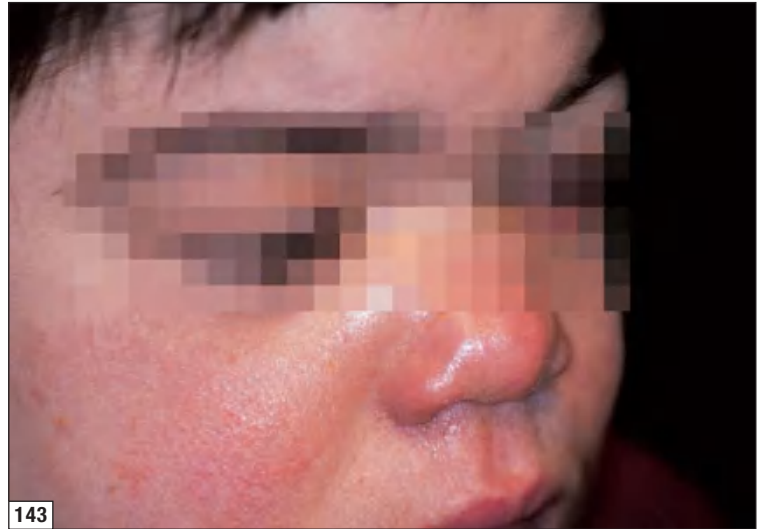

Figure 143. Coarse facial features and saddle nose in Hurler's syndrome.

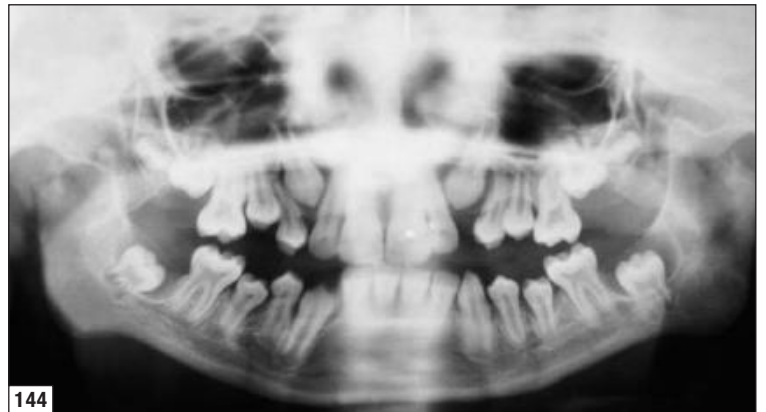


Figure 144. Radiolucencies around the second molar crowns and temporomandibular joint anomalies in Hurler's syndrome.

MORQUIO'S SYNDROME

Morquio's syndrome (Figs 145–147) (mucopolysaccharidosis type IVa) is inherited as an autosomal recessive trait. Features associated with the syndrome are skeletal deformities, muscle weakness and hyperextendible joints, corneal opacities, neurological symptoms because of spinal cord and medullary compression, progressive deafness, normal intelligence, facial changes of short nose and broad mouth and dental changes consisting of enamel defects in the primary and permanent dentitions.

The tooth enamel is thin with a pitted surface resulting in smaller teeth with interdental spacing. When the teeth erupt the cusps are sharp and pointed, but with wear the occlusal surface becomes flat. The enamel although thinner is of normal radiodensity. The clinical and radiographic appearance of the teeth is very similar to the hypoplastic form of amelogenesis imperfecta.

Diagnosis

Diagnosis is clinical, supported by imaging and biochemistry.

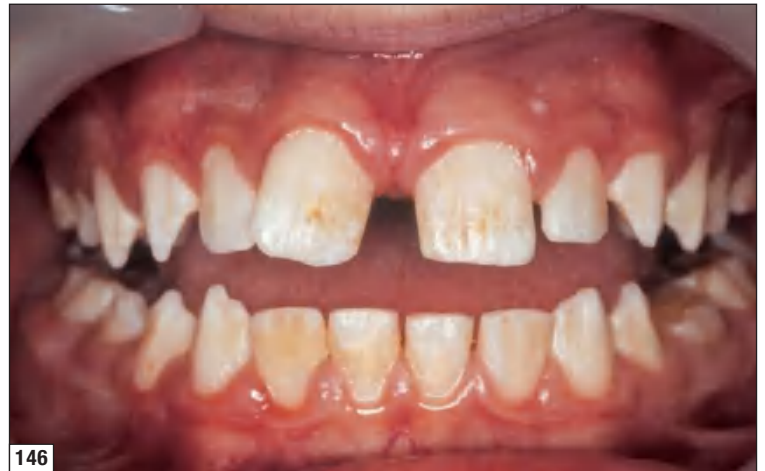Management

Medical care is usually required and surgery and genetic counseling may be indicated.



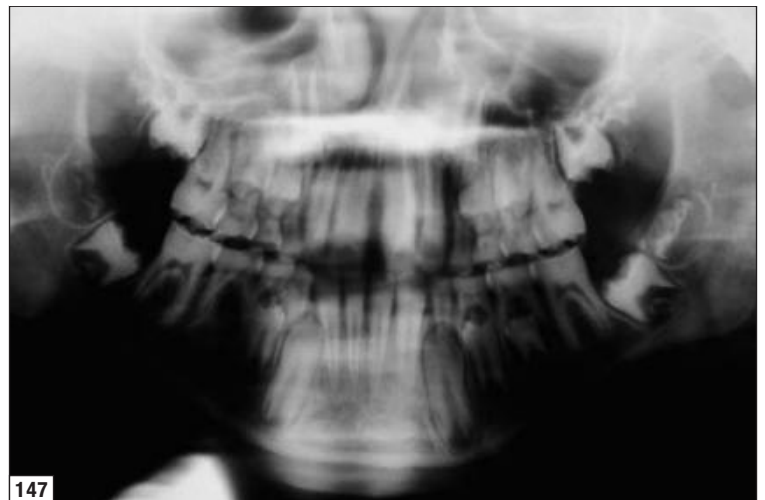145

Figure 145. Morquio's syndrome. Upper limb skeletal deformities.



146

Figure 146. Morquio's syndrome. Pitted enamel.



147

Figure 147. Morquio's syndrome. Thinner enamel.

MULTIPLE ENDOCRINE NEOPLASIA SYNDROME, TYPE III (MULTIPLE MUCOSAL NEUROMA SYNDROME IIB)

Neuromas of the lips and tongue are part of multiple endocrine neoplasia syndrome (MEN; type III or IIB) syndrome (Figs 148–150), which may include medullary thyroid carcinoma, pheochromocytoma and parathyroid hyperplasia. Most patients have an asthenic marfanoid habitus, with high-arched palate, pectus excavatum, arachnodactyly and kyphoscoliosis, but the lens subluxation and cardiovascular abnormalities of Marfan syndrome are not present. The facial appearance is striking with thick, slightly everted lips, which usually have a slightly bumpy surface as a result of multiple ‘neuromas’, which are actually hamartomatous proliferations of nerve axons, Schwann cells and ganglion cells (ganglioneuromatosis). Lesions may involve the lips, commissures and the tongue, but are less frequent on the buccal mucosa, gingivae, palate, pharynx or larynx. The eyelids are thickened, and multiple neuromas produce an irregular lumpy appearance (Figs 148–150).

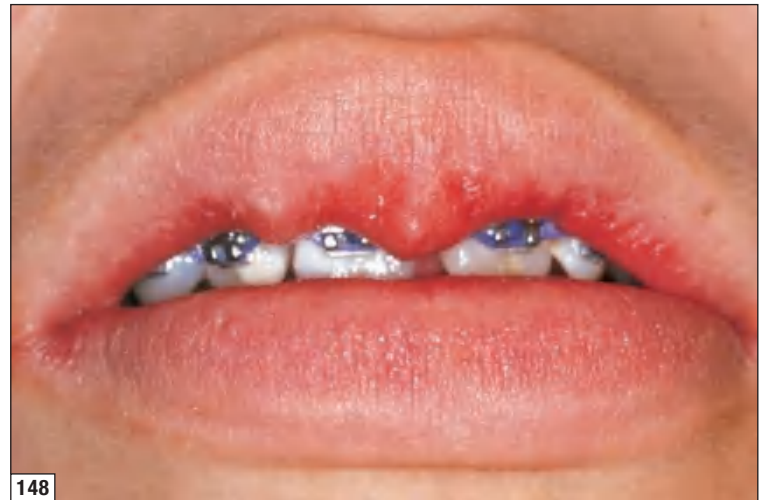Ganglioneuromatosis may also affect the eyelids and gastrointestinal tract.

Diagnosis

Diagnosis is clinical, supported by imaging and biochemistry, in particular, plasma and urinary calcitonin levels and vanillylmandelic acid levels.

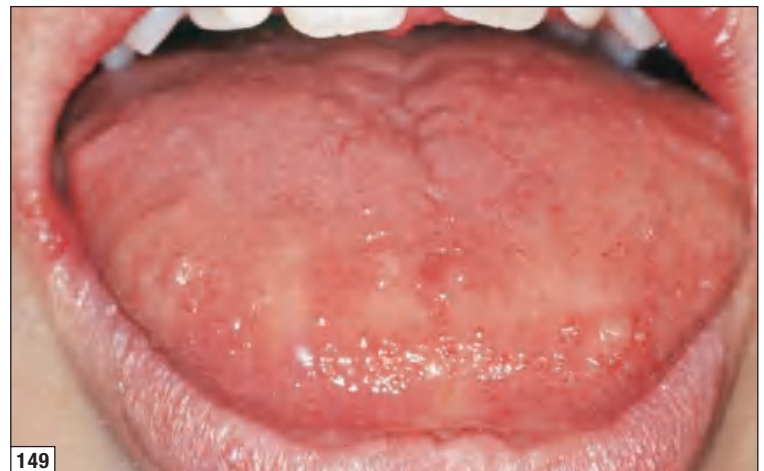Management

Medical care is required and surgery and genetic counseling may be indicated.



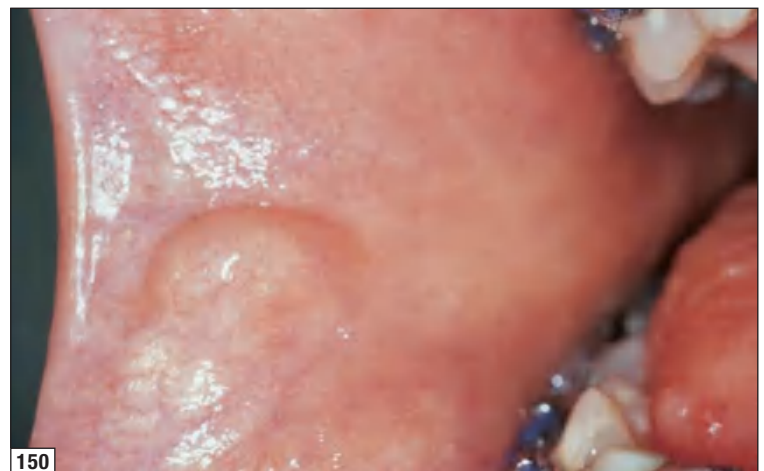148

Figure 148. Adolescent female with multiple endocrine neoplasia syndrome IIB with multiple mucosal neuromas of varying size on the lips.



149

Figure 149. Adolescent female with multiple endocrine neoplasia syndrome IIB with multiple mucosal neuromas of varying size on the tongue.



150

Figure 150. Adolescent female with multiple endocrine neoplasia syndrome III with buccal mucosa neuroma.

NOONAN'S SYNDROME

Noonan's syndrome (Fig.151) is characterized by short stature, unusual facies, congenital heart disease, chest deformity, mild learning disability, and cryptorchidism in males. It may be sporadic or inherited as an autosomal dominant trait. Facial features can include an increased mid face height, hypertelorism, retrognathia, a lower nasal bridge and nasal root, a wider mouth, a more prominent upper lip, and apparently lower set ears than normal control individuals.

The commonest cardiac lesions are pulmonary stenosis and hypertrophic cardiomyopathy. Abnormal vision and hearing are common. Other associations included undescended testes, hepatosplenomegaly and evidence of an abnormal bleeding tendency associated with low levels of clotting factors, particularly XI and XII, and associations with cherubism, giant cell lesions and neurofibromatosis.

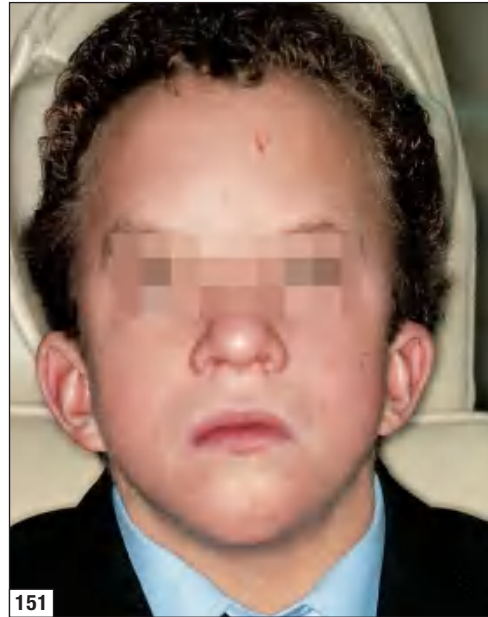

Figure 151. Noonan's syndrome.

OSTEOGENESIS IMPERFECTA (FRAGILITAS OSSIUM)

Osteogenesis imperfecta (Figs 152, 153) is a group of rare disorders in which a defect in type 1 collagen leads to fragile bones that fracture with minimal trauma. There are several subtypes, which vary in severity. Features may include otosclerosis, blue sclerae, hypermobile joints, cardiac valve defects (mitral valve prolapse or aortic incompetence), vertebral collapse and subsequent pareses and dentinogenesis imperfecta. The presence of dentinogenesis imperfecta varies, depending on the type of osteogenesis imperfecta. In some types of osteogenesis imperfecta, the primary dentition may be affected by dentinogenesis imperfecta, but the permanent dentition is only mildly affected or unaffected.

Usually both dentitions are affected, but the permanent dentition may exhibit less color changes and occlusal wear – this may be a result of an anterior and posterior open bite in the permanent dentition.

Diagnosis

Diagnosis is clinical, supported by imaging.

Management

Medical care is usually required and surgery, restorative dentistry and genetic counseling may be indicated.

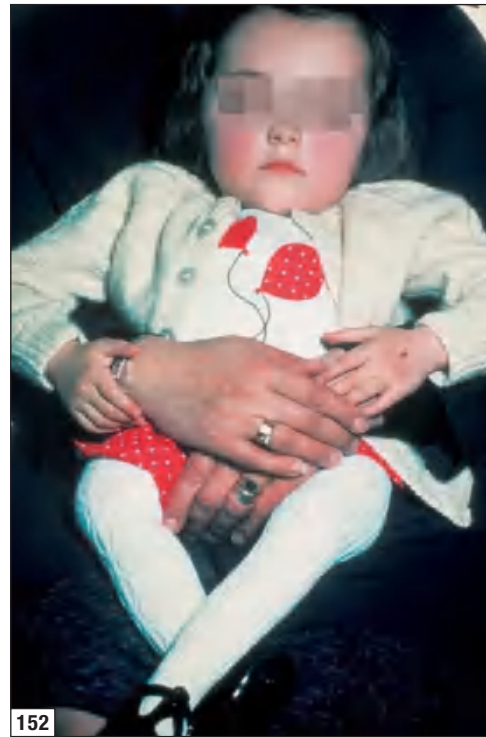

Figure 152. Osteogenesis imperfecta.

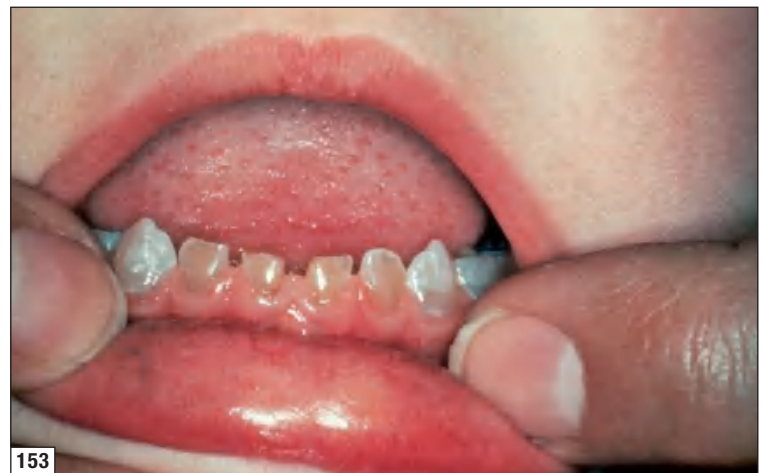

Figure 153. Teeth of patient in Figure 152 showing dentinogenesis imperfecta.

PEUTZ–JEGHERS SYNDROME

Peutz–Jeghers syndrome is an autosomal dominant trait characterized by hamartomatous intestinal polyposis and mucocutaneous melanotic pigmentations especially circumorally.

Peutz–Jeghers syndrome is characterized by discrete, brown-to-bluish black macules, mainly around the oral, nasal and ocular orifices. Mucosal and facial hyperpigmentation may also be seen in relatives.

Intestinal polyps are found mainly in the small intestine and rarely undergo malignant change, but, if they produce intussusception, surgical intervention is required. There is, however, a slightly increased risk

of gastrointestinal carcinoma and carcinoma of the pancreas, breast and reproductive organs.

Diagnosis

The diagnosis is clinical and should be suspected in any patient with oral and perioral pigmentation, even in the absence of gastrointestinal symptoms, but Carney syndrome should be excluded (see p. 45).

Management

The potential for malignancies requires that patients should receive close follow-up.

PRADER–WILLI SYNDROME

Prader–Willi syndrome (Figs 154–156) represents a chromosome 15 deletion. Obesity, learning disability, hypotonia, behavioral problems, minimal sexual development and decreased pain sensitivity are common characteristics. An open, triangular-shaped mouth, enamel hypoplasia, dental caries and malocclusion are typical oral findings.

Diagnosis

Diagnosis is clinical, supported by imaging, biochemistry and karyotyping.

Management

Medical care is usually required and restorative dentistry and genetic counseling may be indicated.

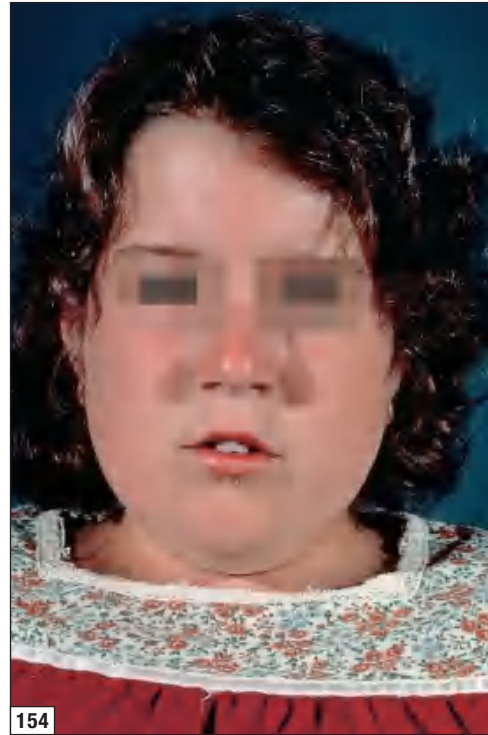

Figure 154. Adolescent female with Prader–Willi syndrome with characteristic facies.

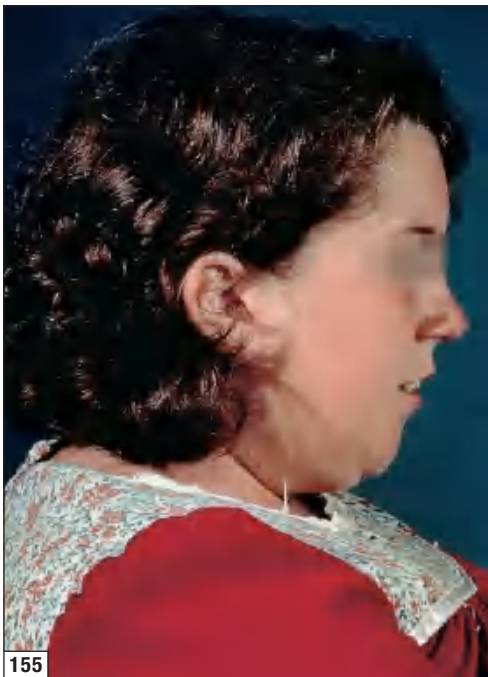

Figure 155. Adolescent female with Prader–Willi syndrome.

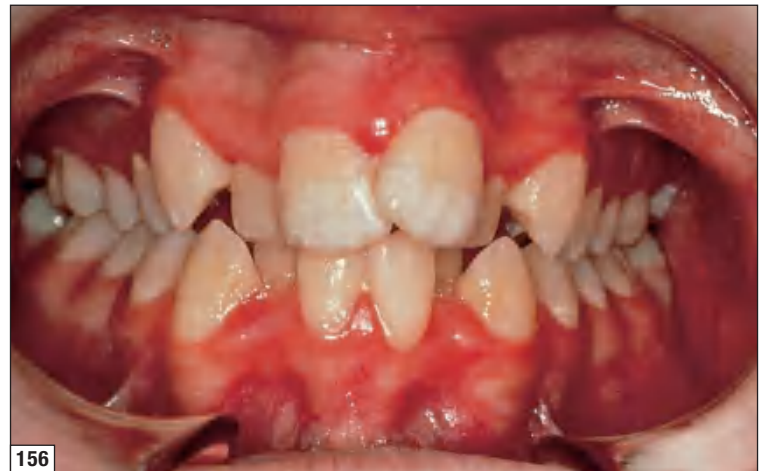
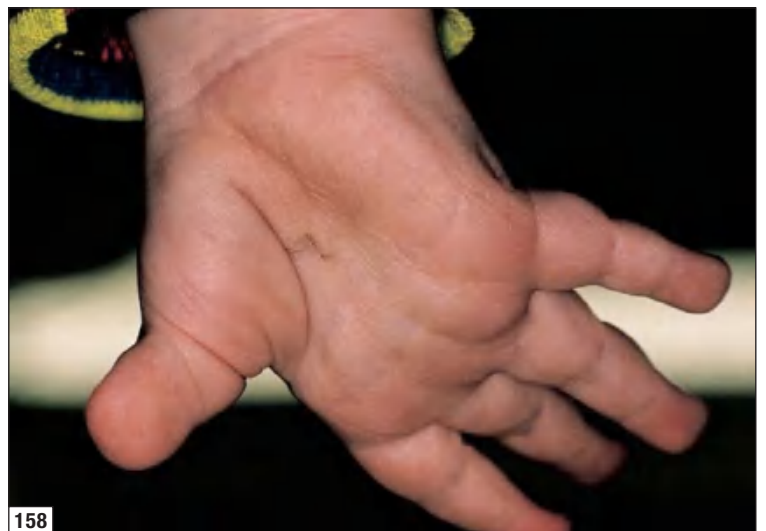
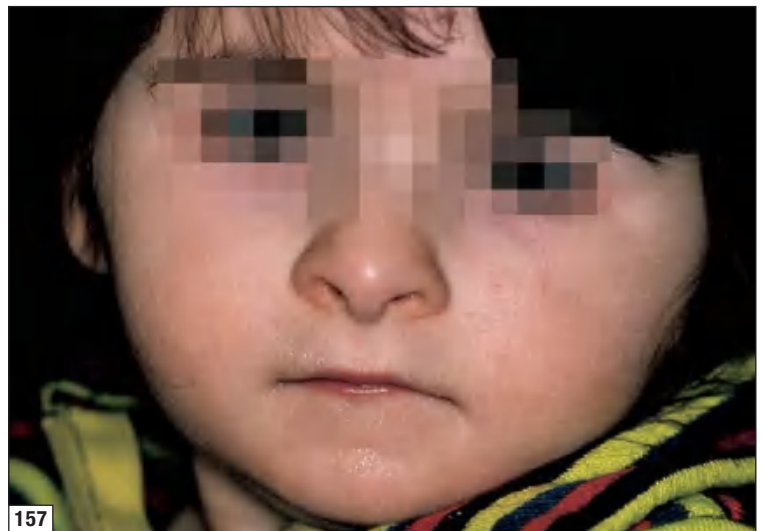Figure 156. Adolescent female with Prader–Willi syndrome with characteristic severe malocclusion.

RUBINSTEIN–TAYBI SYNDROME

Rubinstein–Taybi syndrome (otopalatodigital syndrome; Figs 157, 158) is a rare congenital anomaly comprising mental and growth retardation, broad thumbs and great toes, and an unusual face. The facial appearance includes downslant of the palpebral fissures, epicanthic folds, ptosis, strabismus, highly arched palate, simple ears and a small mouth. The nose is distinctive with a beaked appearance, broad fleshy bridge, deviated septum and short low columella. Cleft uvula, cleft palate or, rarely, cleft upper lip can be part of the syndrome. Tooth eruption timing is normal, though many patients have malpositioned, crowded teeth. Hypodontia, hyperdontia, and natal teeth can be manifestations of the syndrome. Most patients have talon cusps.



Figures 157, 158. Rubinstein–Taybi syndrome.

SJÖGREN–LARSSON SYNDROME

The Sjögren–Larsson syndrome (Figs 159–161) is a rare genetic condition, an inborn error of metabolism. Patients have deficient activity of the aldehyde portion of the nicotinamide adenine dinucleotide (NAD⁺) oxidoreductase complex. It is characterized by congenital ichthyosis, spastic hemiplegia or quadriplegia, and learning disability. The skin changes are concentrated in the neck, flexures and lower abdomen, where the scales are often dark.

Patients who have Sjögren–Larsson syndrome have higher caries indices, a higher frequency of gingivitis and periodontitis, a higher frequency of enamel hypoplasia, but a similar prevalence of malocclusions compared with fully healthy individuals, but not compared to others with learning disability. The degree of learning disability and the occurrence of epilepsy influence the extent of gingival and periodontal disease. The frequency of enamel hypoplasias is high.



Figures 159–161. Sjögren–Larsson syndrome.

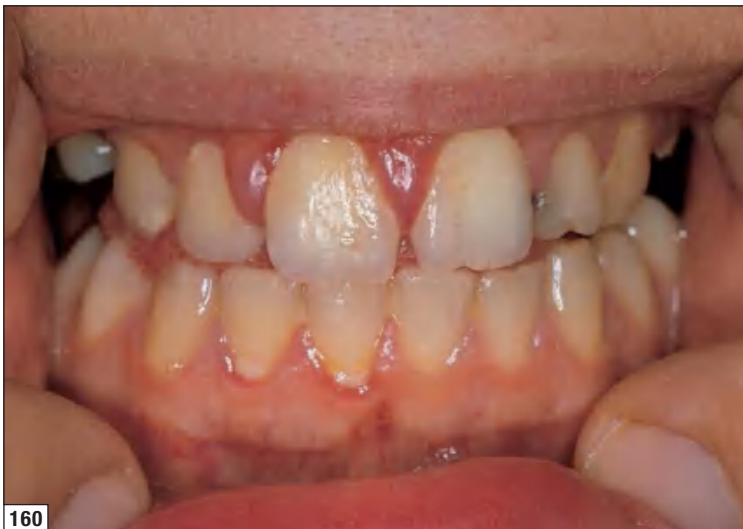

Figure 160. Enamel pitting and gingivitis.

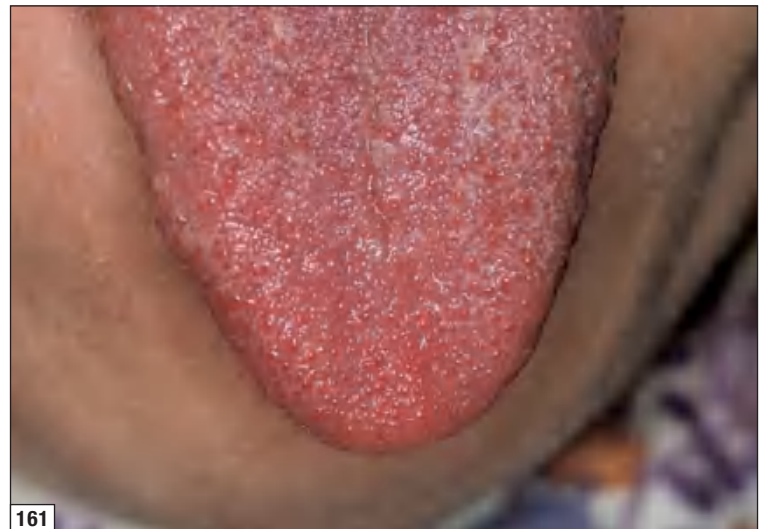

Figure 161. Normal salivation (this is not Sjögren's syndrome of xerostomia and keratoconjunctivitis sicca).

SOTOS SYNDROME (CEREBRAL GIGANTISM)

Sotos syndrome (Figs 162–164) is an autosomal dominant condition that represents an overgrowth syndrome. It consists of advanced height and bone maturation dating from infancy, learning disability and unusual craniofacial appearance characterized by macrocrania with dolichocephaly and ocular hypertelorism, and antimongoloid obliquity of the palpebral fissures. The frontal hairline is often receded.

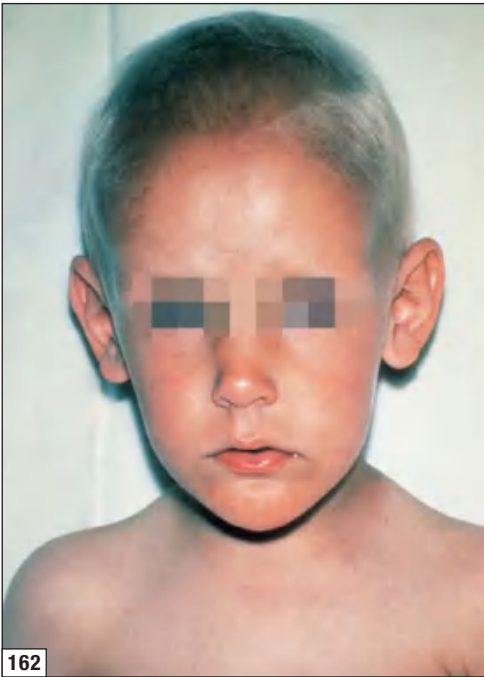High arched palate, precocious dental eruption and mandibular prognathism are the orofacial manifestations.

Diagnosis

Diagnosis is clinical, supported by imaging and biochemistry.

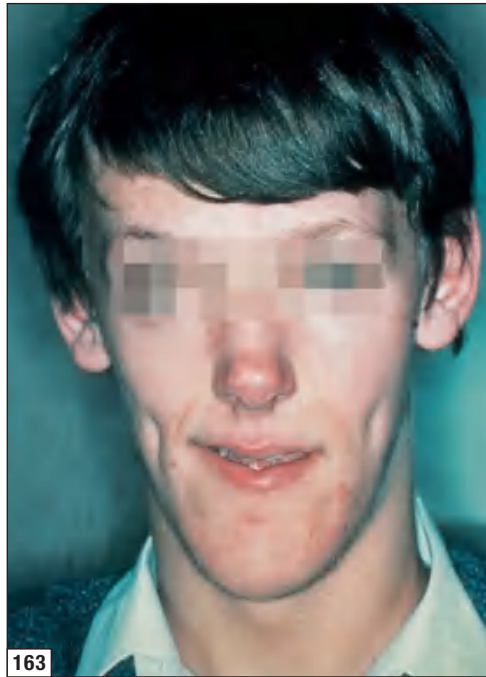Management

Medical care is usually required and craniofacial surgery and genetic counseling may be indicated.



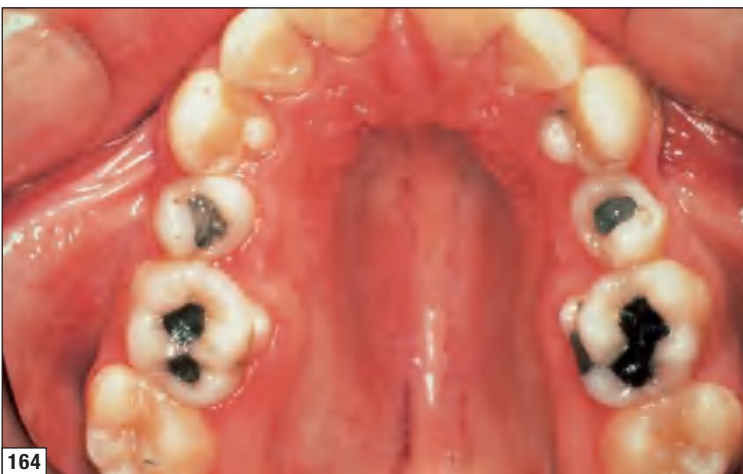
162

Figure 162. An infant aged 4 years with Sotos syndrome.



163

Figure 163. Sotos syndrome. The same patient as in Figure 162 now aged 17 years. There is marked macrocrania and dolichocephaly with mandibular prognathism.



164

Figure 164. The high-arched palate of the same patient with Sotos syndrome.

TRICHORHINOPHARYNGEAL SYNDROME TYPE I

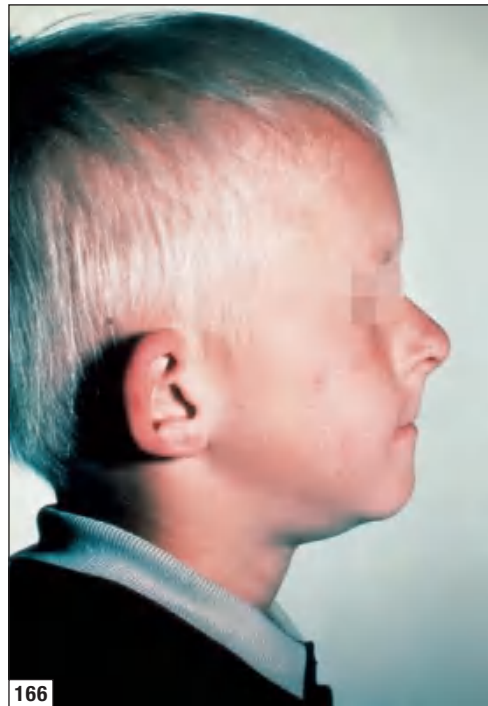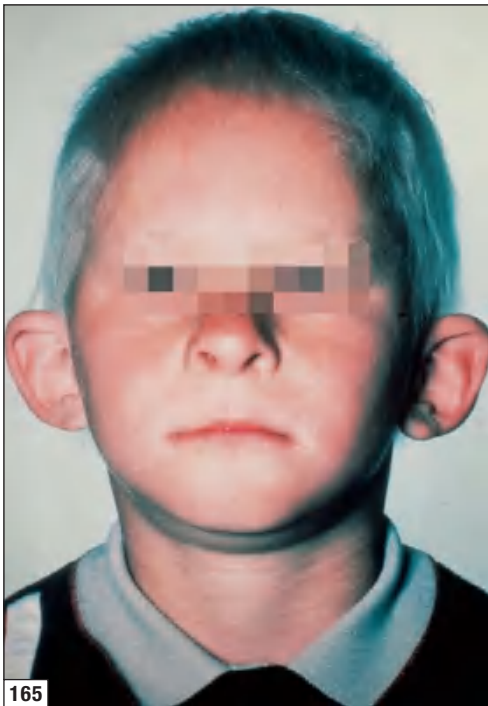Most cases of trichorhinopharyngeal syndrome type I (Figs 165–168) are associated with a chromosome 8 deletion and have an autosomal dominant inheritance pattern. This syndrome consists of cone-shaped epiphyses, sparse fine hair, bulbous nose with tented alae nasi and variable growth retardation. There may be midface hypoplasia, mild micrognathia, large outstanding ears and supernumerary teeth.

Diagnosis

Diagnosis is clinical, supported by imaging and karyotyping.

Management

Medical care is usually required and surgery and genetic counseling may be indicated.



Figures 165, 166. A 5-year-old male with somatic features characteristic of the trichorhinopharyngeal syndrome.

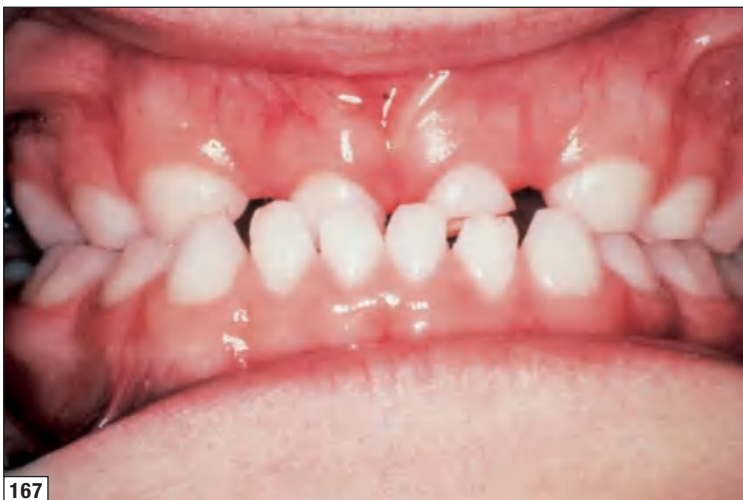

Figure 167. Trichorhinopharyngeal syndrome. Hypodontia affecting the primary dentition in the patient in Figure 165. Both maxillary primary lateral incisors are missing. In the permanent dentition the maxillary lateral incisors and all the mandibular incisors failed to develop.

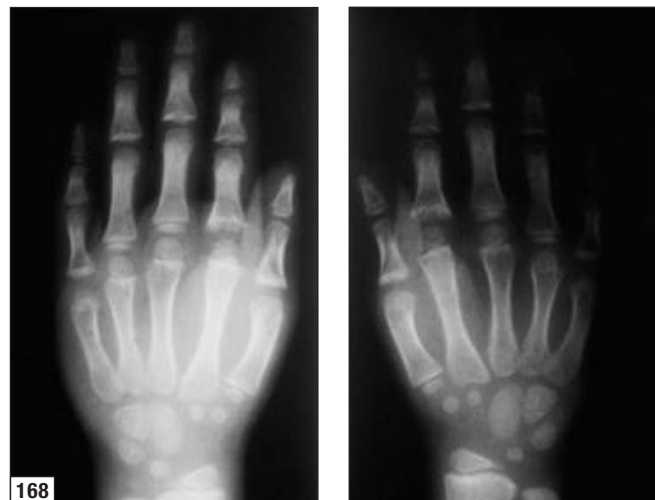


Figure 168. Trichorhinopharyngeal syndrome. Radiograph of the hands of the same patient as in Figure 165. The left hand is clearer and shows cone-shaped epiphyses of type 12 in all phalanges except the proximal phalanges of the middle and ring fingers and distal phalanx of the little finger. There is also a short fifth metacarpal and premature fusion of most epiphyses.

VON RECKLINGHAUSEN NEUROFIBROMATOSIS (NF TYPE I)

Von Recklinghausen NF I represents the most common type of neurofibromatosis with an autosomal dominant inheritance pattern. Major features of this syndrome include six or more café-au-lait macules, cutaneous neurofibromas, Lisch nodules and axillary freckling.

The most common oral manifestations are orofacial neurofibromas with a predilection for the tongue, enlarged fungiform papillae, widened inferior alveolar canal and mandibular foramen, intrabony

radiolucencies and malposition of teeth. Neurofibroma, which represents a benign overgrowth of all elements of a peripheral nerve, may undergo sarcomatous change.

Diagnosis

Diagnosis is clinical, supported by imaging, biopsy and karyotyping.

Management

Medical care is usually required, and surgery and genetic counseling may be indicated.

WILLIAMS SYNDROME

The hypercalcemia–supravalvular aortic stenosis syndrome, sometimes termed Williams syndrome (Figs 169, 170), comprises in its rare complete form, infantile hypercalcemia, characteristic so-called elfin facies, supravalvular subaortic stenosis or other cardiovascular abnormalities and learning disability. Most such cases appear to be sporadic. Hypercalcemia typically remits in infancy, but leaves growth deficiency, osteosclerosis and craniostenosis. Despite the learning disability, these children may be sociable and talkative ('cocktail party manner').

Facial features, which become more striking with age, include a flat midface, depressed nasal bridge, anteverted nostrils, long philtrum,

thick lips, wide intercommissural distance and open mouth. A high percentage of patients have blue eyes with a stellate iris pattern.

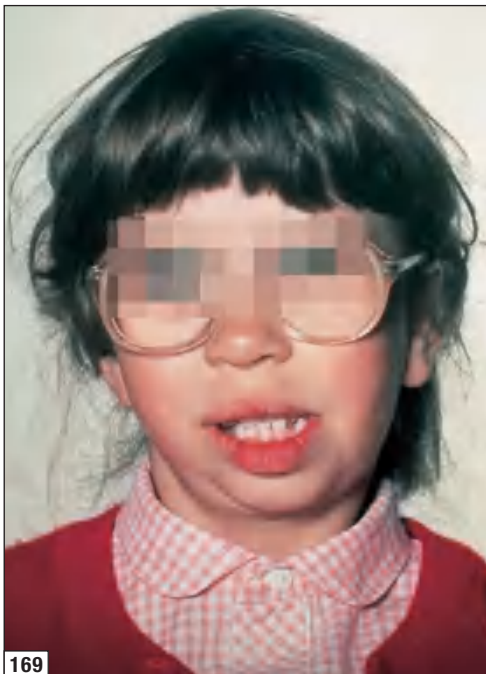Hypodontia, microdontia, small slender roots, dens invaginatus, mild micrognathia, delayed mineralization of teeth and prominent and accessory labial frena may be present.

Diagnosis

Diagnosis is clinical, supported by imaging, cardiac studies and biochemistry.

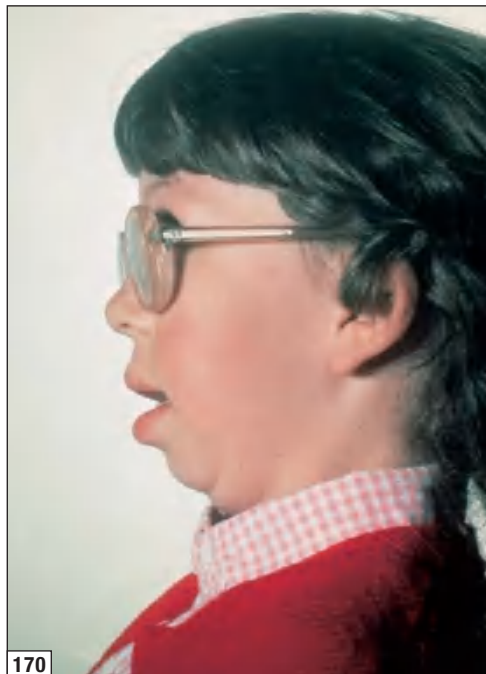
Management

Medical care is usually required and surgery and genetic counseling may be indicated.



169

Figure 169. Frontal facial view illustrating the characteristic somatic features of Williams syndrome.



170

Figure 170. Lateral facial view illustrating the characteristic somatic features of Williams syndrome.

4

Acquired disorders affecting the teeth

COMMON COMPLAINTS

Early loss of teeth

Early tooth loss in children is usually because of extraction as a result of dental caries. Incisor teeth may also be lost through trauma.

Unexplained early tooth loss in children requires investigation because it may also occur with, or be a presenting symptom of, systemic disorders such as Down syndrome, juvenile diabetes mellitus, immune defects (chronic neutropenia, aplastic anemia, leukemia, HIV), Langerhans cell histiocytosis, hypophosphatasia, prepubertal and juvenile periodontitis, Papillon-Lefèvre syndrome (palmoplantar hyperkeratosis), Ehlers-Danlos syndrome type VIII, Haim-Munk syndrome, Hajdu-Cheney syndrome, Coffin-Lowry syndrome, factitial extraction (psychiatric disease and pain insensitivity syndromes) and neoplasms (Table 2).

Variations in tooth eruption times

A delay in eruption (Table 3) of up to 12 months may be of little or no significance in an otherwise healthy child.

Local variations often result from local factors, such as a tooth in the path of eruption, insufficient space in the dental arch or dental

infection. Ectopic positioning and impaction most often occur in the third molar, second premolar and canine regions, because these are the last teeth to erupt.

Delayed eruption of the whole dentition suggests a systemic cause – hypothyroidism is one example, but there are many causes (Table 4).

Early eruption is uncommon, but may be seen, for example, in Sotos syndrome.

Table 2. Causes of early loss of teeth

Local	
Caries	
Periodontal disease	
Trauma	
Neoplasms	
Systemic	
Genetic defects	
Coffin-Lowry syndrome	
Papillon-Lefèvre syndrome	
Juvenile periodontitis and related disorders	
Ehlers-Danlos syndrome type VIII	
Neoplasms	
Hajdu-Cheney syndrome (acro-osteolysis syndrome)	
Eosinophilic granuloma (Langerhans cell histiocytosis)	
Immune defects	
Diabetes mellitus	
Inflammatory bowel disease	
Neutropenia	
Neutrophil defects (of adhesion, locomotion, phagocytosis, bactericidal activity)	
Monocyte defects	
Interleukin-1 abnormalities	
HIV infection and AIDS	
Collagen defects	
Ehlers-Danlos syndrome	
Enzyme defects	
Acatalasia	
Hypophosphatasia	
Acrodynia	

Table 3. Average tooth eruption times (there is a wide range)

Deciduous (primary) teeth		
	Upper (months)	Lower (months)
A – Central incisors	8–13	6–10
B – Lateral incisors	8–13	10–16
C – Canines (cuspids)	16–23	16–23
D – First molars	13–19	13–19
E – Second molars	25–33	23–31
Permanent teeth		
	Upper (years)	Lower (years)
1 – Central incisors	7–8	6–7
2 – Lateral incisors	8–9	7–8
3 – Canines (cuspids)	11–12	9–10
4 – First premolars (bicuspid)	10–11	10–12
5 – Second premolars (bicuspid)	10–12	10–12
6 – First molars	6–7	6–7
7 – Second molars	12–13	11–13
8 – Third molars	17–21	17–21

Table 4. Systemic causes of delayed tooth eruption

Down syndrome
Cytotoxic therapy
Radiotherapy
Cleidocranial dysplasia
Congenital hypopituitarism (rarely)
Congenital and juvenile hypothyroidism (rarely)
Gaucher's disease and mucopolysaccharidoses (rarely)
Osteopetrosis (rarely)
Others including, pyknodyostosis, craniosynostosis syndromes, Aarskog syndrome, Albright's hereditary osteodystrophy, chondroectodermal dysplasia, de Lange syndrome, and Gardner syndrome.

Variations in tooth number

Teeth missing from the normal series may have failed to develop (hypodontia), failed to erupt, or have been lost prematurely.

Hypodontia

Hypodontia is not uncommon, probably genetic, and most often affects third molars, second premolars or maxillary lateral incisors. It may be associated with a reduction in size of other teeth. Several teeth may be absent in disorders such as ectodermal dysplasia and Down syndrome. (See Table 5.)

Ectopic eruption of multiple teeth

It is not uncommon to see what appear to be two rows of teeth in the lower incisor region, when permanent teeth are erupting before the deciduous incisors have exfoliated (the mixed dentition; Fig. 171). Ectopic eruption of multiple teeth is most likely to occur when there is an arch length/tooth size discrepancy (inadequate space to accommodate the larger permanent teeth). The situation usually resolves as deciduous incisors are lost and with the help of normal pressure of the tongue against the lingually positioned teeth. However, it is not uncommon for crowding of the incisors to persist because of insufficient space.

Hyperdontia

Hyperdontia or extra teeth are not uncommon and appear to result from an inherited autosomal dominant trait. The frequency of this condition ranges from less than 1% in the primary dentition to about 1–3.5% in the permanent dentition. They are most frequently seen in the maxillary lateral incisor, premolar and third molar regions. Additional teeth of abnormal form (supernumerary teeth) are not also uncommon, usually small and/or conical in shape and are seen particularly in the maxillary midline and are referred to as mesiodens. Abnormal shaped

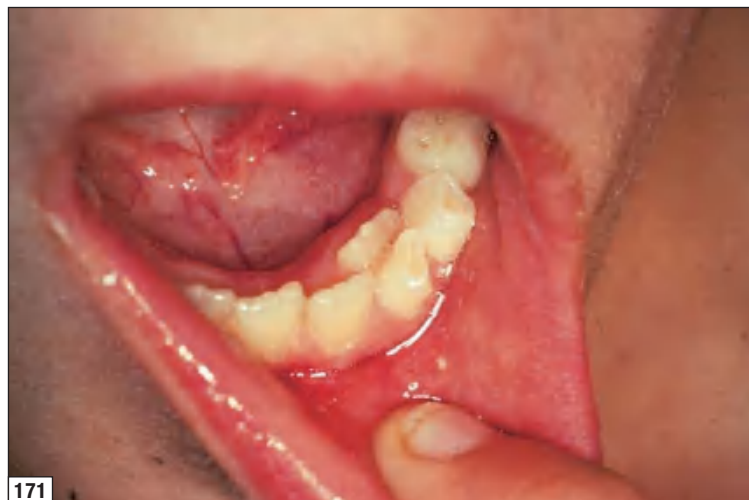

Figure 171. Permanent lateral incisor erupting lingual to a deciduous incisor.

Table 5. Ectodermal dysplasia and related syndromes

Down syndrome	Gorlin–Chaudhry–Moss syndrome
OFD I and II	Hallerman–Streiff syndrome
Rieger's syndrome	hypoglossia–hypodactylia
Incontinentia pigmenti	Johanson–Blizzard syndrome
Coffin–Lowry syndrome	progeria
Ellis–van Creveld syndrome	Witkop tooth–nail syndrome
LADD syndrome	Rothmund–Thomson syndrome
Otodental syndrome	Cranio-oculo-dental syndrome
Cockayne syndrome	oro-clefting syndromes
Ackerman syndrome	dysostoesclerosis, frontometaphyseal dysplasia
Ehlers–Danlos syndrome	Toumaala–Haapanen syndrome
Focal dermal hypoplasia	multiple nevi and mental retardation syndrome
Freire–Maia syndrome	
Goldenhar syndrome	

supernumerary teeth may also be seen distal to the third molars and are referred to as paramolars. These teeth usually remain unerupted and may cause a permanent tooth to impact. A diastema may develop when a mesiodens is present.

Additional teeth often occur alone in otherwise healthy individuals, occasionally in association with disorders such as cleidocranial dysplasia, Gardner syndrome, Hallermann–Streiff syndrome, and oral-facial-digital syndrome, type 1.

Variations in tooth size, shape, structure and color

A variety of local and generalized factors may act during the period of tooth formation and/or mineralization to disturb odontogenesis (Table 6). Tooth development *in utero* is generally well protected, but maternal disease and intrauterine infection, and systemic disturbance during early life may affect teeth. Intrauterine viral infections that may affect tooth structure include rubella and cytomegalovirus infection. The classical Hutchinson's incisors and Moon's (or mulberry) molars of congenital syphilis occur in some parts of the world, but are extremely uncommon in developed countries.

More generalized defects may be seen in a range of systemic disorders (e.g. prematurity, infections, jaundice, malabsorption, irradiation and cytotoxic therapy) during the time of tooth formation and mineralization, the defect relating to the timing, severity and duration of the disorder.

Intrinsic staining of an appreciable brown or gray color may be caused by tetracyclines given to a pregnant or lactating mother or to children under the age of 8 years. Excessive fluoride ingestion during early life may also result in enamel opacities and discoloration. With the exception of those parts of the world where water supplies contain very high levels of fluoride, this is most often mild.

Table 6. Causes of discolored teeth**Extrinsic discoloration (typically brown or black)**

Poor oral hygiene
 Tobacco products (smokeless tobacco, cigarettes)
 Beverages/food (e.g. tea, grape juice, colas)
 Drugs (e.g. iron, amoxicillin, chlorhexidine)
 Betel nut (pan, quid)

Localized intrinsic discoloration

Trauma (yellow to brown)
 Caries (white, brown or black)
 Restorative materials e.g. amalgam (black)
 Internal resorption, pink spot (pink)

Generalized intrinsic discoloration

Tetracyclines (brown, gray)
 Excessive fluoride (white or brown)
 Pathological jaundice or biliary atresia (green or blue)
 Amelogenesis imperfecta (yellow or brown)
 Dentinogenesis imperfecta (brown, gray or purple)
 Porphyria (red or brown)

Enamel and dentine defects of genetic origin are rare, but are occasionally severe, take a variety of forms and vary in their inheritance. They may occur in isolation in the form of amelogenesis imperfecta (enamel defective) or dentinogenesis imperfecta (dentine defective), or as part of a disorder such as epidermolysis bullosa dystrophica or osteogenesis imperfecta. In the case of some genetic defects of dentine for example, newly erupted teeth may appear brownish and translucent – an appearance seen in some patients who have osteogenesis imperfecta.

The risk of damage is greatest for most permanent teeth, particularly those of cosmetic importance, between birth and 6 years of age. Upper permanent incisors may show defects as a consequence of trauma to the primary predecessor. Local infection or trauma may cause a defect in a single tooth or group of teeth. Malformed teeth secondary to trauma or periapical infection of their deciduous predecessors are not uncommon and are termed Turner teeth.

Teeth, especially third molars, may genetically vary in size, form and structure. Microdontia (teeth smaller than usual) is largely genetic, most often affecting lateral incisors, which may be conical or peg-shaped. Microdontia of the permanent dentition may be seen following radiation therapy to the head and neck region in a young child. Small tooth size has also been associated with Russell–Silver dwarfism, Down syndrome, ectodermal dysplasia syndrome, incongentia pigmenti, Nance–Horan syndrome, Reiger syndrome and acrodental dysostosis.

Teeth larger than normal (megadont or macrodont) are very uncommon. This condition may be seen with pituitary gigantism, hemifacial hyperplasia, vascular lesions and in syndromes such as KBG syndrome and 47, XYY.

ABRASION

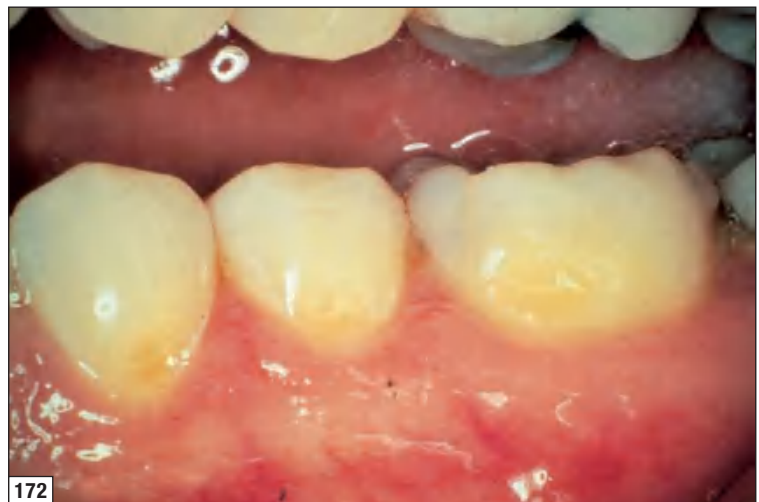Abrasion (Fig. 172) is the wearing away of tooth substance by a habit such as toothbrushing. Brushing with a hard brush and coarse dentifrice may abrade the cervical margin (neck of the tooth). The gingiva recedes, but is otherwise healthy. The cementum and dentine wear away, but the harder enamel survives, resulting in a notch at the cervical margin. Abrasion is uncommon in children.

Diagnosis

Diagnosis is clinical.

Management

Restorative dental care is often required.



172

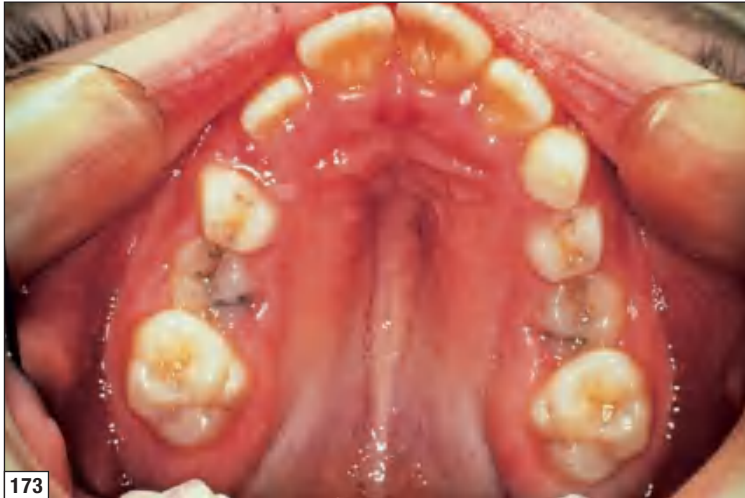Figure 172. Toothbrush abrasion of the cervical regions of the maxillary premolars and first permanent molar in a teenager with poor toothbrushing technique.

ANKYLOSIS

A primary molar may be retained and in infraocclusion ('submerged') because the permanent successor is absent. There is then bony ankylosis (Figs 173, 174) and no evidence of a periodontal ligament.

Diagnosis

Diagnosis is clinical, supported by imaging.

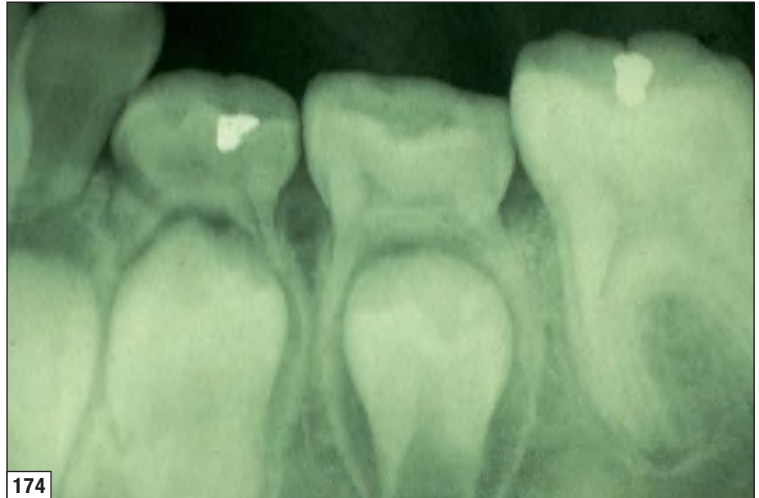


173

Figure 173. The maxillary second primary molars have undergone ankylosis to the underlying bone. Their occlusal surface is now considerably below the occlusal table and they are in danger of being covered by gingiva.

Management

Space maintenance is usually required if the tooth is removed prematurely. Restoring the tooth to the height of the plane of occlusion may prevent drifting of the adjacent teeth if the submerged tooth is not extracted.



174

Figure 174. The mandibular second primary molar is ankylosed. There is little evidence of a periodontal ligament around either root.

ATTRITION

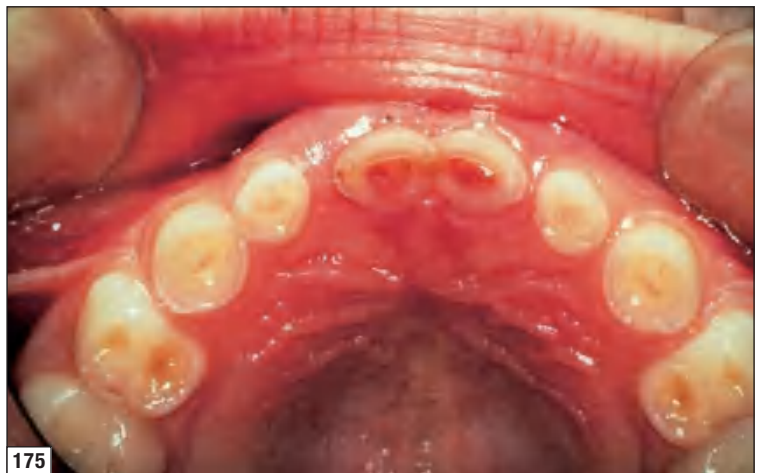Attrition (Fig. 175) is the wearing away of tooth substance by mastication. It is common in children, in the primary dentition and occurs especially where the diet is coarse or where there is a parafunctional habit such as bruxism (e.g. as may occur in cerebral palsy, learning disability, Rett syndrome). The incisal edges and cusps wear with more loss of dentine than enamel, leading to a flat or hollowed surface, but unless attrition is rapid, the pulp is protected by secondary dentine formation.

Diagnosis

Diagnosis is clinical, supported by imaging.

Management

Restorative dental care and/or occlusal coverage splint are often required.



175

Figure 175. Marked attrition of the primary dentition as a result of an excessive grinding habit. The pulps of the maxillary central incisors are exposed.

DENTAL CARIES

Most disease affecting the teeth and symptoms from teeth are a consequence of dental caries (Figs 176–178). Caries arises from the fermentation of dietary sugar by dental bacterial plaque to acids. Plaque is a complex biofilm that forms on teeth, particularly below the contact areas, along the gingival margin and in pits and fissures, adhering by a variety of mechanisms.

Fermentation of dietary carbohydrates, principally sucrose, by plaque bacteria to produce organic acids results in the initial process of demineralization. If this disease process progresses, proteolysis results in caries formation (dental decay). The main causal organisms are *Streptococcus mutans* and to a lesser extent *Lactobacillus* species.

Decalcification of tooth substance in stagnation areas, such as in pits and fissures, at the tooth contact areas and close to the gingival margin initially produces an opaque whitish area, referred to as a white spot lesion. Remineralization and lesion reversal may occur if cavitation is not present and if oral hygiene improves, the diet is changed (reduction in exposure to refined carbohydrates) and topical fluoride is applied (to rebuild partially dissolved hydroxyapatite crystals into fluoridated hydroxy-apatite, which is more resistant to acid dissolution). If unarrested, the enamel lesion progresses and breaks down to form a cavity and the dentine is invaded. The carious dentine is discolored and this eventually shows through the enamel. If untreated, caries almost inevitably progresses through the dentine to reach the dental pulp, which becomes inflamed. Such pulpitis causes pain and may result in pulpal necrosis and dental abscess formation.

Any change in local environment that makes the carious lesions self-cleansing, for example, loss of a tooth adjacent to an interproximal lesion or fracture of cusps overlying a lesion may arrest the caries. Lesions then darken and can become static.

In contrast, xerostomia markedly predisposes an individual to caries. This may happen for example, in children who have had radiotherapy to the salivary glands, which appreciably decreases normal salivary flow, thereby predisposing the teeth to rampant caries.

Caries has been declining for some years, mainly because of the protective effect of fluoride, but caries is now more prevalent in the disadvantaged and deprived.

Diagnosis

Diagnosis is clinical, supported by imaging.

Management

Caries is largely preventable by lifestyle modification. Change in dietary habits (particularly a reduction in frequency and total intake of refined carbohydrates), topical fluoride treatment and improved oral hygiene can prevent and arrest the progression of caries.

Diet

Sugars (particularly nonmilk sugars) in items other than fresh fruits and vegetables are the major dietary factors in caries etiology. The frequency and duration of exposure is more important than the amount.

In early childhood caries, both human and bovine milk can cause marked destruction of the teeth if the child is allowed to feed on demand, if the milk is sweetened with additional sucrose or if the child

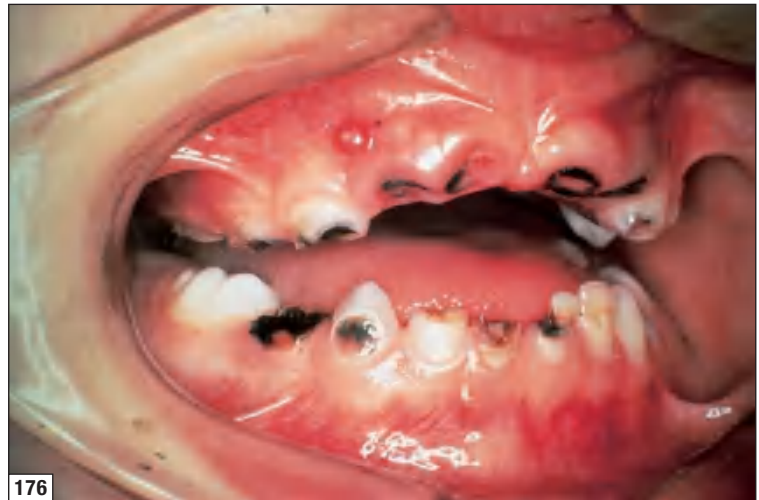

Figure 176. Advanced caries.

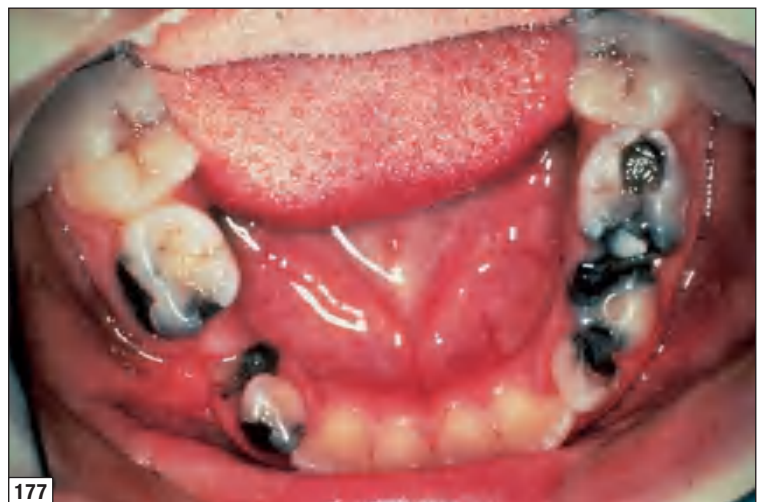
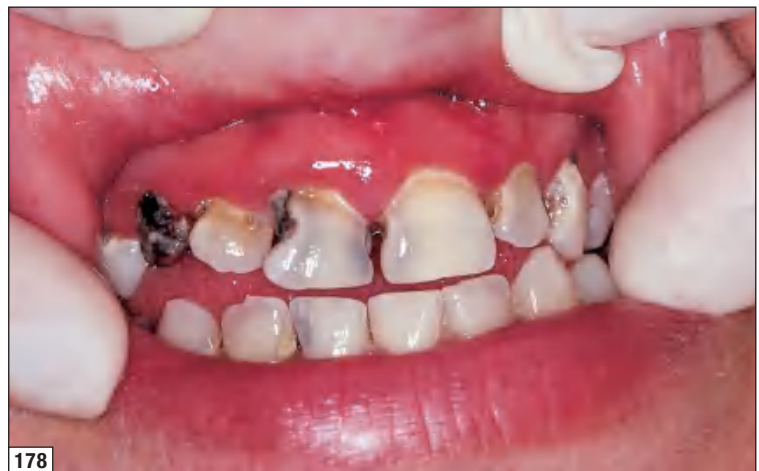
Figure 177. Extensive caries in the primary dentition caused by prolonged use of a night-comforter bottle containing a juice high in non-milk extrinsic sugars.



Figures 178. Extensive caries in a 9-year-old child as a result of excessive and frequent consumption of snack foods high in non-milk extrinsic sugars. The first permanent molars also had marked occlusal caries.

is allowed to sleep with a bottle of milk or juice ('nursing caries'). In this form of caries, rampant and marked destruction of the primary teeth, especially the maxillary incisors, is a characteristic finding. These teeth do not erupt decayed – with such a habit they can decay as they erupt.

Dietary advice should begin with emphasis on appropriate infant feeding and weaning practice. Drinks other than milk and water should not be given in feeding bottles and should be confined to main meals. Children should be introduced to a cup at about 6 months and should have ceased using bottles by 1 year. Weaning foods should be low in sugars other than those in fresh milk, fruits or vegetables. For older children and adults snack foods and drinks especially should be free of sugars. Because of the risk of erosion as well as of caries, frequent consumption of carbonated and cola type drinks should be discouraged: water and milk are preferred options. Saliva buffers may counter plaque acids and therefore chewing sugar-free gum or cheese after meals may be of value.

Fluorides

Fluorides are protective against caries. In practical terms, water fluoridation has been shown to reduce the prevalence of toothache and experience of extractions and has particular value in reducing social inequalities in oral health. Water fluoridation has consistently been shown to be the most effective, safe and equitable means of preventing caries, resulting in a decrease of 60%.

Fluoride is found in many toothpastes, and this may be largely responsible for the decline in caries. Because children under 6 years of age may ingest an appreciable amount of toothpaste, only a pea-sized amount of a paste with less than 1000 ppm of fluoride should be used with supervised brushing.

Fluoride rinses protect against caries and are especially useful in children at risk for smooth surface enamel caries. Only children who can effectively rinse and expectorate should use this topical agent. Use of other mouthwashes is a contentious issue. Fluoride drops, tablets, rinses or gels are useful mainly in children with special needs. Infants over 6 months and young children may be given daily fluoride drops or tablets provided there is no risk of fluorosis – white or colored flecks on the teeth – and therefore they should be given only where the water supply contains less than 600 micrograms/liter (0.6 ppm) fluoride, depending on the age of the child (Table 7).

Toothbrushing

Toothbrushing at least twice a day, using a small headed, soft bristle toothbrush helps reduce caries if a fluoride toothpaste is used. Overdiligence in brushing or an abrasive toothpaste can cause tooth abrasion; soft brushes and silica-based toothpastes are less abrasive than those with calcium carbonate or aluminium trihydrate bases.

Pit and fissure sealants

Resin material (plastic coatings) placed by the dental professional in the pits and fissures of the some primary molars and permanent teeth can also help reduce caries.

Vaccines

Despite attempts over the past 25 years, there is not yet a reliably successful or acceptable caries vaccine.

Sequelae of caries

Most dental pain occurs as a result of caries. Initially, caries presents clinically as a painless white spot (which is reversible enamel decalcifi-

Table 7. Fluoride drops or tablets for caries prophylaxis in children; doses in relation to water fluoride content (modified according to the most recent American Academy of Pediatric Dentistry Guidelines)

Fluoride ppm in water supply	Birth to 6 months	6 months to 3 years	3–6 years	6–at least 16 years
<0.3	0	250 µg (0.25mg)/day	500 µg (0.50 mg)/day	1 mg/day
0.3–0.6	0	0	250 µg (0.25mg)/day	500 µg (0.50 mg)/day
>0.6	0	0	0	0

cation), followed by cavitation and the appearance of a brownish discoloration. Once caries reaches the dentine, pain may result on stimulation thermally or with sweet/sour. Dentinal pain may also occur when dentine is exposed by trauma, erosion or abrasion. Dentinal pain subsides within seconds of removing the stimulus, and may be poorly localized, often only to an approximate area within 2–3 teeth adjacent to the affected tooth. The tooth should be restored (filled).

Untreated caries can progress through dentine to the pulp, which becomes inflamed (pulpitis). Within the rigid confines of the pulp chamber this produces severe persistent pain (toothache) and the pulp eventually undergoes necrosis when inflammation can spread around the tooth apex (periapical periodontitis), eventually forming an abscess, granuloma or cyst.

Periapical abscess

A periapical abscess (dental abscess, odontogenic abscess; Figs 179–183) is often a sequel of pulpitis caused by dental caries, but may arise in relation to any nonvital tooth (e.g. subsequent to trauma). A mixed bacterial flora is implicated, although the role of anaerobes such as fusobacteria and bacteroides species is increasingly recognized. Pain and facial swelling are characteristic. Most dental abscesses produce an intraoral swelling, typically on the labial or buccal gingiva. However, abscesses on maxillary lateral incisors and those arising from the palatal roots of the first molar may present palatally. Rarely, abscesses in children – especially those of lower incisors or molars – discharge extraorally.

Once the abscess discharges beyond the periosteum, the acute inflammation, pain and swelling resolve and a chronic abscess develops discharging from a sinus – usually buccally.

A granuloma may arise at the apex of a nonvital tooth and may occasionally develop into a cyst from proliferation of epithelial rests in the area (cell rests of Malassez). Many periapical cysts involve upper lateral incisors because these, not infrequently, become carious and the pulp can be involved relatively rapidly. A periapical cyst may be asymptomatic and often is a chance radiographic finding. It may present as a swelling (usually in the labial sulcus) or may become infected and present as an abscess.

A periapical cyst left *in situ* after the causal root or tooth is removed may continue to expand and is termed a residual cyst. This is almost invariably unilocular, but may expand to an appreciable size. It may be asymptomatic, detected as a swelling, a chance radiographic finding or become infected and present as an abscess or very rarely present as a pathological fracture.

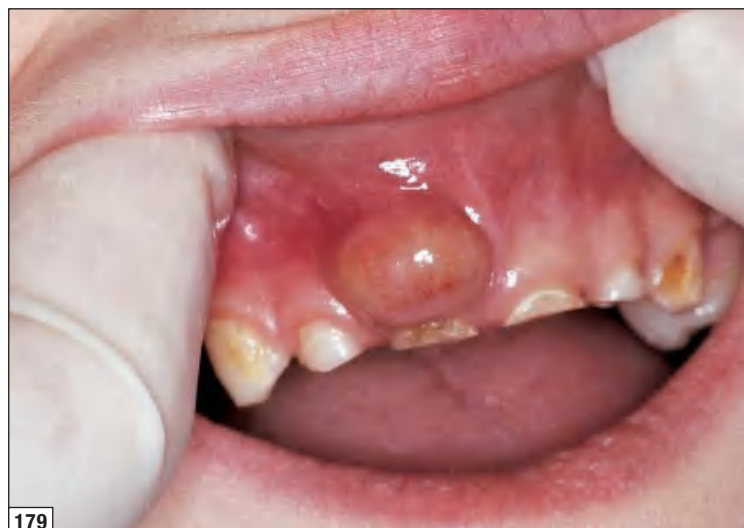Most odontogenic cysts are periapical cysts.

Diagnosis

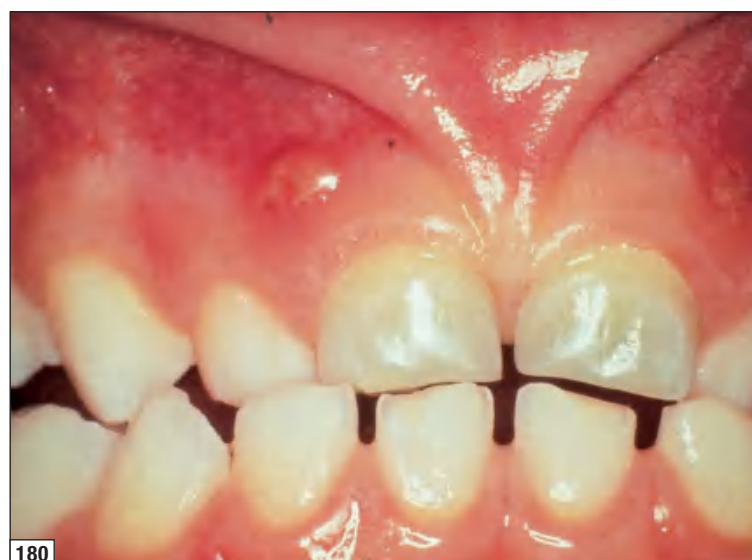Diagnosis is clinical, supported by imaging.

Management

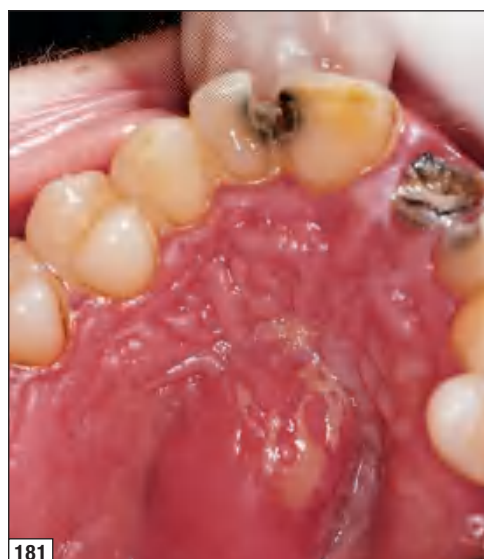Extraction or endodontic therapy of the affected tooth removes the source of infection. A small periapical cyst may remain attached to and be extracted with the causal root or tooth or resolve with endodontic therapy.



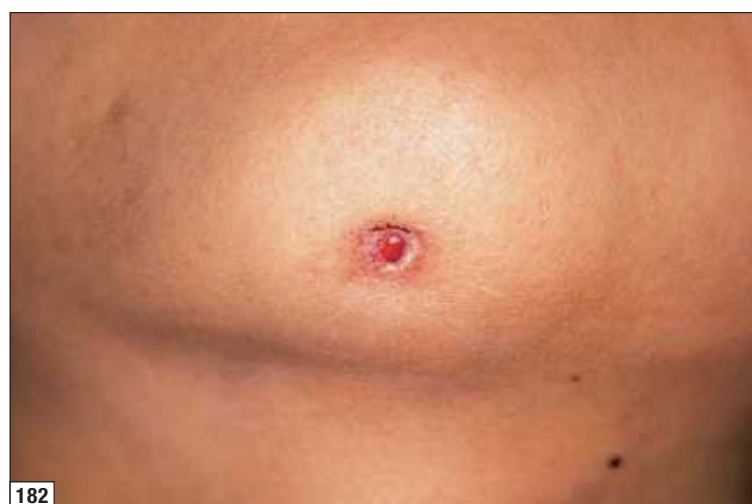179
Figure 179. Acute periapical abscess arising from a traumatized necrotic maxillary primary central incisor.



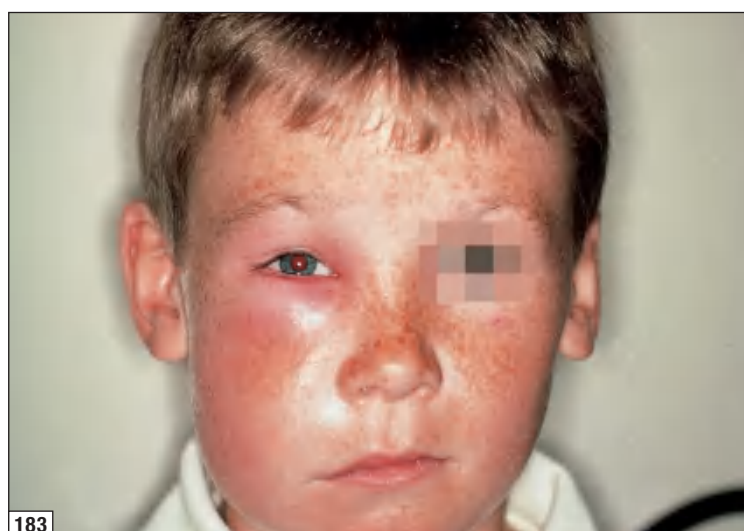180
Figure 180. Both maxillary primary incisors have periapical infection, which has pointed buccally through the labial plate to form collections of pus under the mucosa.



181
Figure 181. Acute periapical abscess arising from the carious maxillary permanent incisor.



182
Figure 182. Periapical abscess from a lower permanent incisor discharging onto chin sinus from dental abscess.



183
Figure 183. Facial swelling associated with a periapical abscess.

DILACERATION

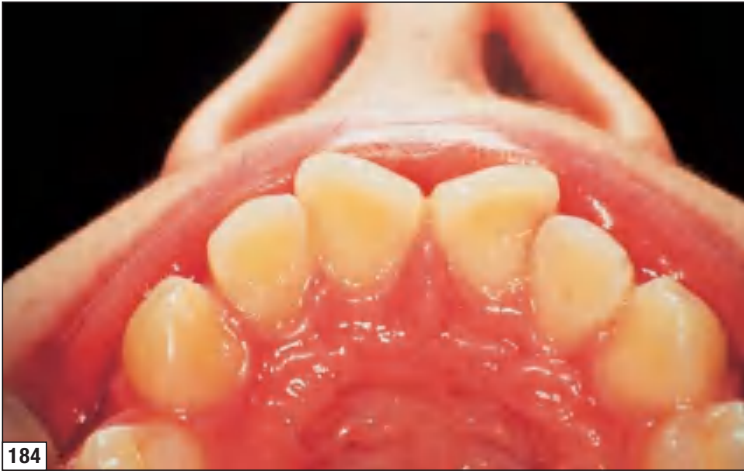Trauma to a developing tooth before it erupts, may produce distortion and dilaceration – a bend in either the root or the crown (Figs 184–186).

Diagnosis

Diagnosis is clinical, supported by imaging.

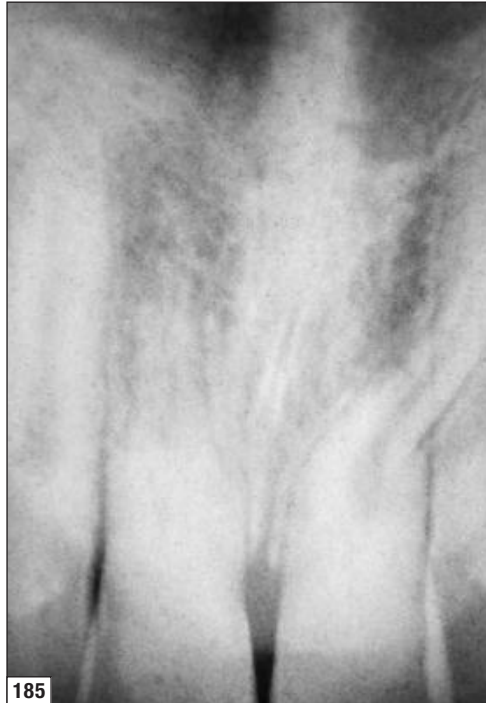Management

The condition is often best left alone.



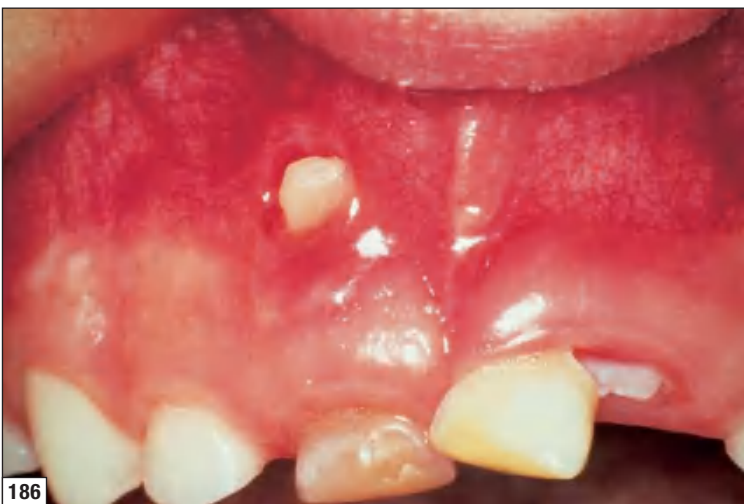184

Figure 184. Dilaceration of root of maxillary right central primary incisor.



185

Figure 185. Radiograph of Figure 184 reveals dilaceration of the middle third of the roots of these teeth. A history revealed an episode of trauma to these teeth shortly after eruption.



186

Figure 186. There is a dilaceration of the root of the maxillary right central primary incisor so that the apex is visible in the buccal sulcus. The dilaceration occurred at the crown/root junction as a result of a fall at the age of 1 year. The apex has appeared in the buccal sulcus as a result of the permanent successor trying to erupt palatal to it.

DOUBLE TEETH (CONNATION)

Teeth joined together are often described by terms that are based on the suspected etiology of the anomaly. For example, fusion is the term used to describe the union between the dentine and/or the enamel of two or more normally separate developing tooth germs. Gemination is the term used to describe the partial development of two teeth from a single tooth bud following incomplete division.

However, it is extremely difficult, if not impossible, to distinguish between fusion and gemination on clinical grounds. The number of normal teeth present is of little or no assistance as fusion may occur between a normal tooth and a supernumerary tooth or between two supernumerary teeth. Alternatively, gemination could occur in a tooth germ adjacent to a congenitally absent tooth and this would be indistinguishable clinically from fusion. For these reasons a general descriptive term such as connation, that describes the appearance without suggesting the etiology is appropriate.

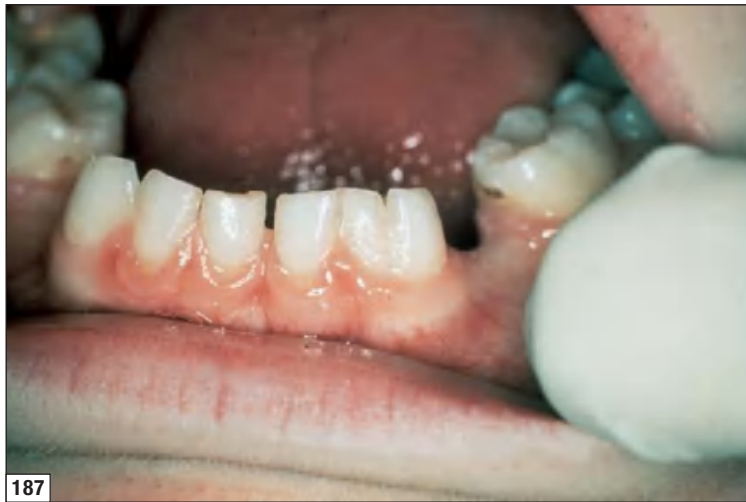

Figure 187. There is a connated tooth in the mandibular left primary canine region.

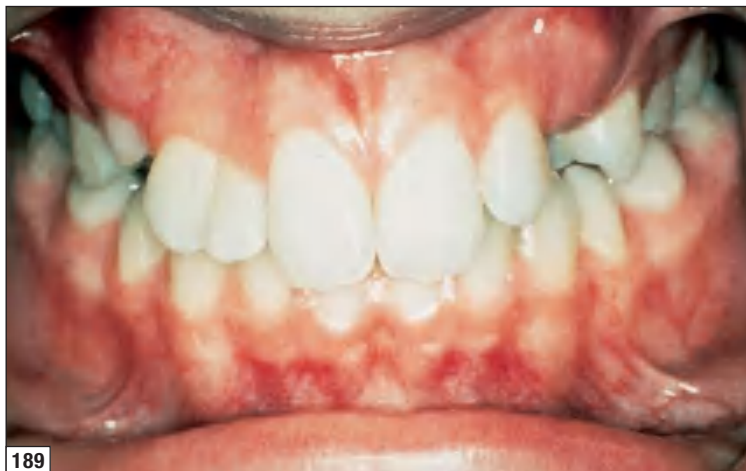

Figure 189. There is a connated tooth in the maxillary right permanent lateral region.

Connated (developed or born together) teeth are more frequent in the primary dentition, and are usually in the incisor or canine regions (Figs 187–190). The condition may be bilaterally symmetrical and some families show a dominant trait of connated teeth.

Diagnosis

Diagnosis is clinical, supported by imaging.

Management

The condition is often best left alone. Otherwise, surgical division, extraction or restorative dental care are required.

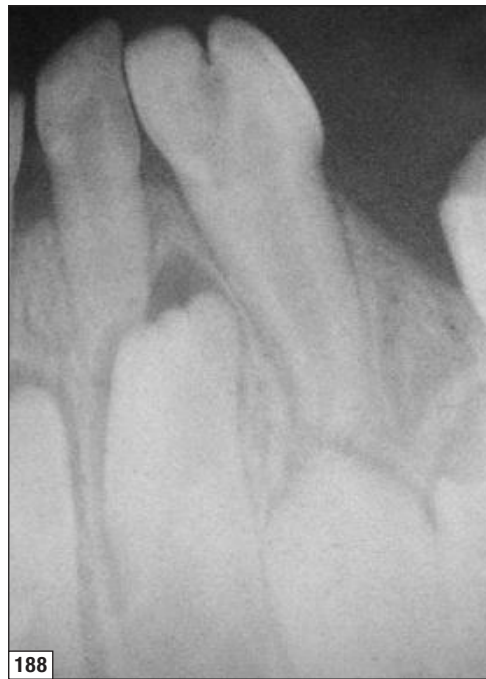

Figure 188. The periapical radiograph of the connated tooth in Figure 187 shows a single root and a common pulp chamber in the crown.

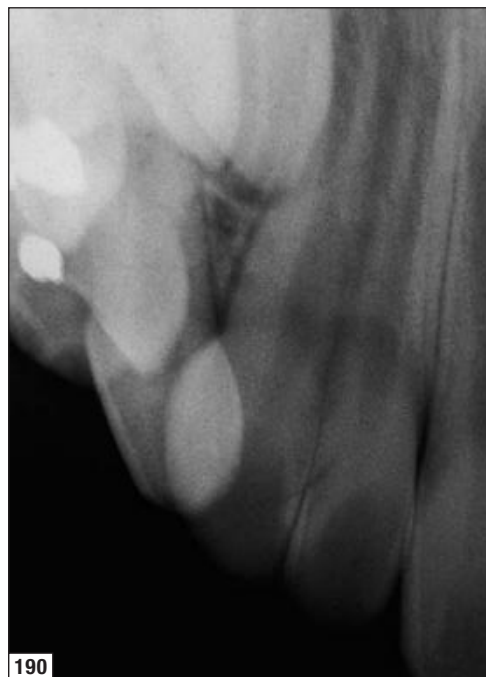


Figure 190. The periapical radiograph of the connated tooth in Figure 189 shows two separate dental elements joined only at the crowns, with no pulpal communication between the two elements.

ENAMEL CLEFT

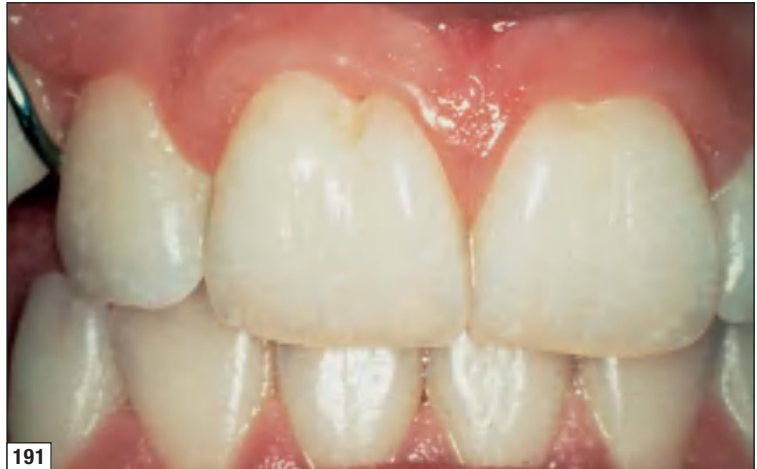Enamel clefts (Fig. 191) are often seen in the cervical region and are probably caused by a localized infolding of the ameloblast layer.

Diagnosis

Diagnosis is clinical, supported by imaging.

Management

The condition is often best left alone. Otherwise, restorative dental care is required.



191

Figure 191. There is enamel clefting in the cervical region of both maxillary permanent central incisors, more obvious on the right central incisor.

ENAMEL HYPOPLASIA

Tooth development can be disturbed by constitutional disturbances such as childhood febrile illnesses, cystic fibrosis and gastroenteritis, producing a linear pattern of defects corresponding to the site of amelogenesis at the time ('chronological' hypoplasia; Figs 192–199). Horizontal pits or grooves are usually seen in the incisal third of the crowns of permanent teeth. Intrauterine infections such as rubella, or metabolic disturbances may cause hypoplasia of the primary dentition and/or the cusp tips of the first permanent molars and incisal edges of the central incisors.

Infection of or trauma to a primary tooth, may cause hypoplasia of the underlying permanent successor. Lower premolars and maxillary central incisors are most frequently deformed because of a previous

odontogenic infection of the primary teeth.

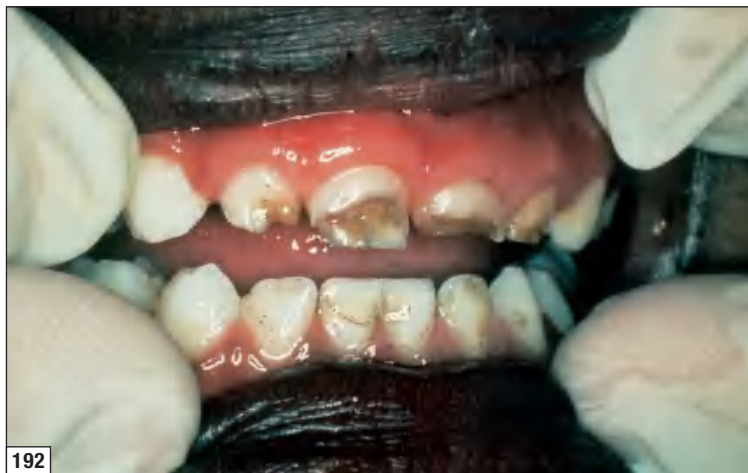Enamel hypoplasia may also be iatrogenically induced by cytotoxic chemotherapy or radiotherapy. Occasionally it may appear in the absence of any identifiable cause.

Diagnosis

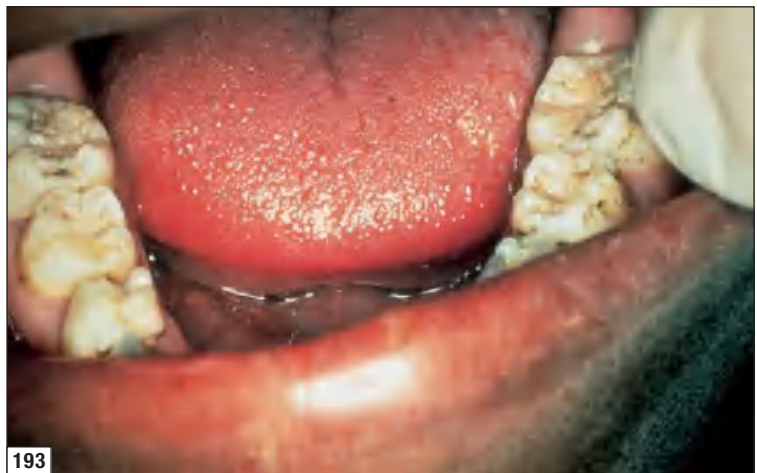Diagnosis is clinical, supported by imaging.

Management

The condition is often best treated with topical fluorides and restorative dental care.

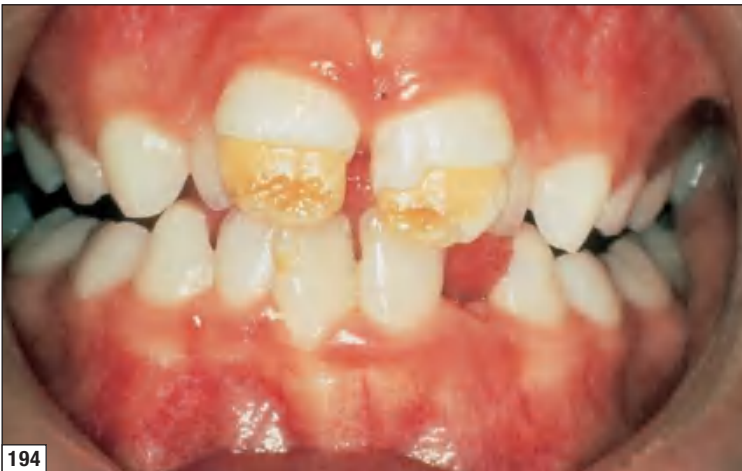

192



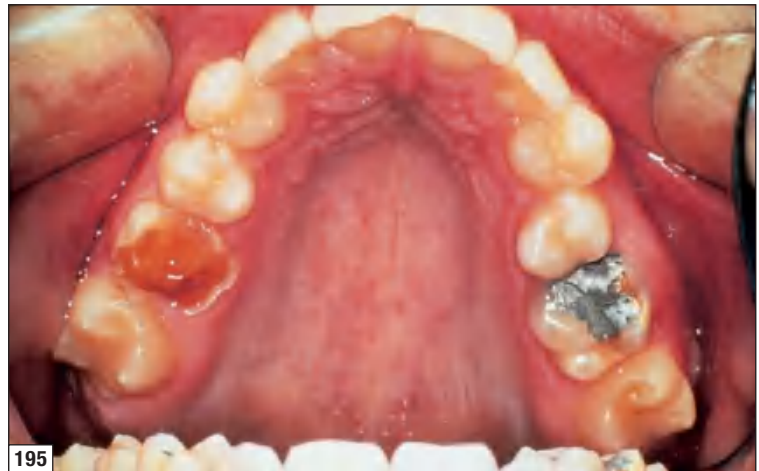193

Figures 192, 193. The enamel hypoplasia seen on the first and second incisors and primary molars was thought to result from maternal illness in the last trimester of pregnancy and failure of the infant to thrive coupled with recurrent pneumonia in the first 6 months of life.



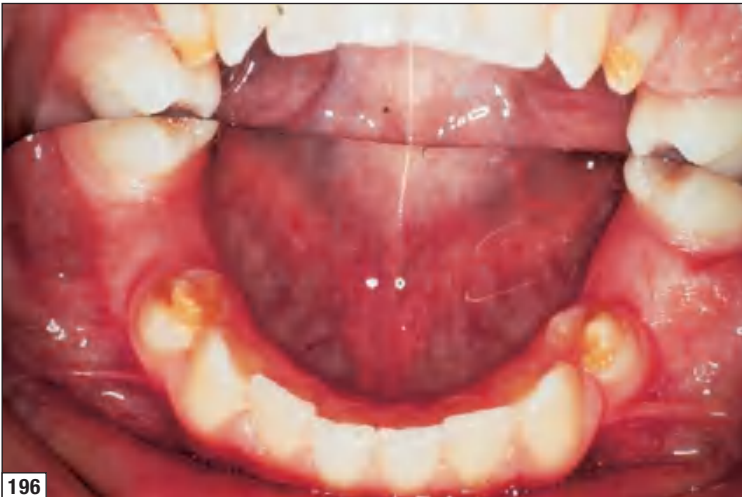194

Figure 194. The enamel hypoplasia affecting the incisal half of the permanent incisors resulted from a well-documented episode of primary incisor trauma at the age of 9 months.



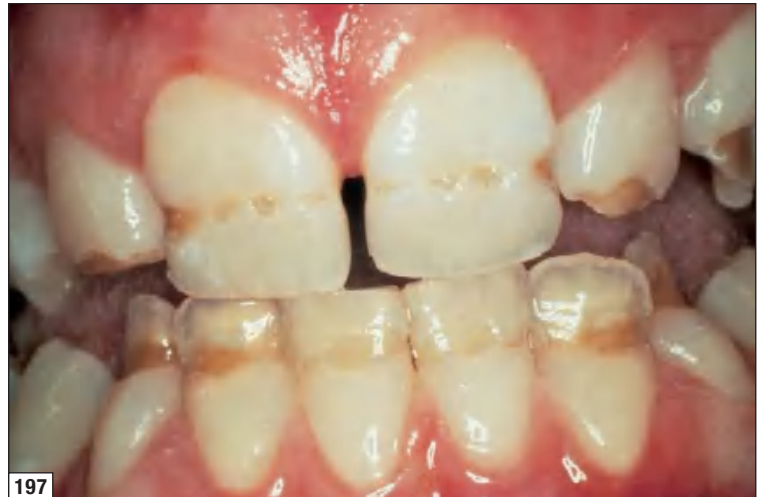195

Figure 195. The enamel hypoplasia affecting the first permanent molars was thought to be caused by a prolonged and difficult labor complicated by pre-eclamptic toxemia.



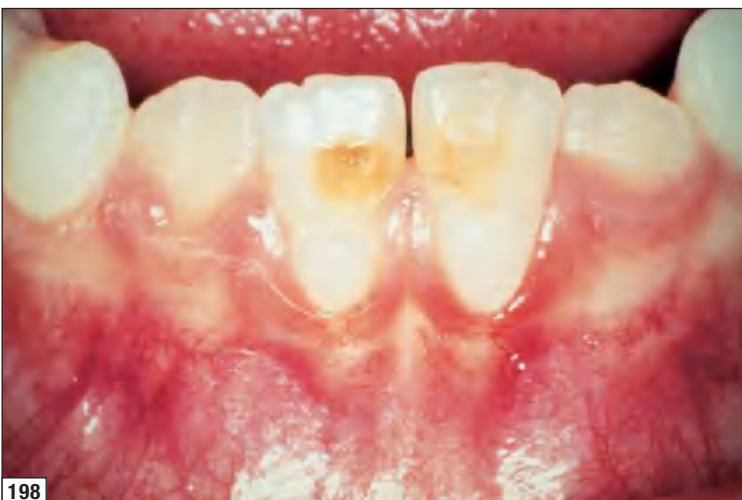196

Figure 196. Both mandibular first permanent premolars are hypoplastic. The predecessor first primary molars had had periapical abscesses.



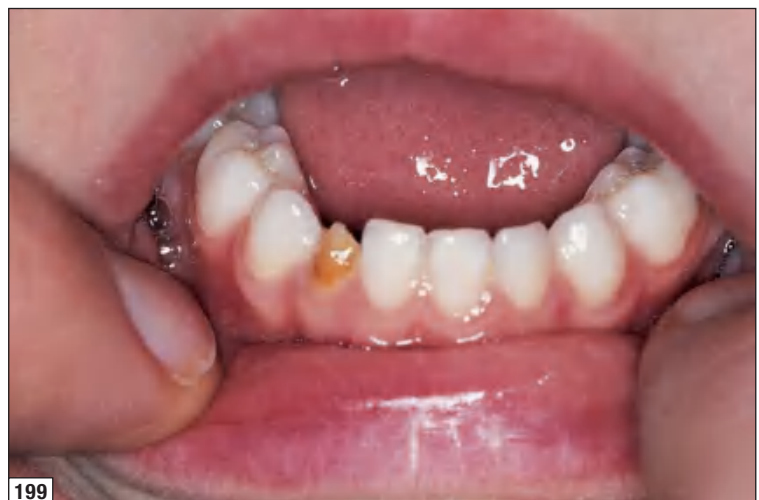197

Figure 197. The chronological hypoplasia affecting the maxillary and mandibular permanent incisors was probably caused by severe measles during the second year of life.



198

Figure 198. A milder case of enamel hypoplasia as a result of trauma to the primary predecessor. Both mandibular permanent central incisors have localized areas of staining and pitting.



199

Figure 199. Isolated enamel hypoplasia in a permanent lateral incisor (Turner tooth).

EROSION

Erosion (Figs 200–203) is the loss of tooth substance caused by acids. Citrus fruits, fruit drinks, carbonated beverages or recurrent vomiting may produce such lesions, which are more common in adolescents than younger children. Repeated gastric regurgitation over a prolonged period may cause erosion, mainly of the palatal surfaces of the upper teeth. This is seen especially in bulimia nervosa.

Other features of bulimia include enlargement of salivary glands (mainly parotids), palatal petechiae, possible conjunctival suffusion and esophageal tears (caused by retching), and Russell's sign – abrasions on the back of the hand or fingers caused by using the fingers to induce vomiting.

Diagnosis

Diagnosis is clinical, supported by imaging.

Management

Restorative dental care may be required and efforts should be made to prevent further erosion, either by modifying lifestyle and avoiding acidic beverages or using antacids if there is repeated vomiting. Rinsing with diluted bicarbonate solution after vomiting, may help to neutralize the acidity of the oral fluids in chronic cases.

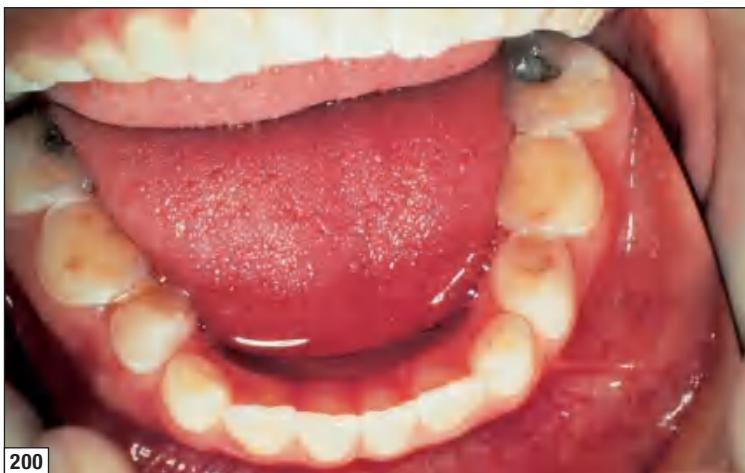


Figure 200. Marked erosion of the occlusal surface of the mandibular second primary molars and first permanent molars as a result of frequent intake of lime and lemon juice cordial.

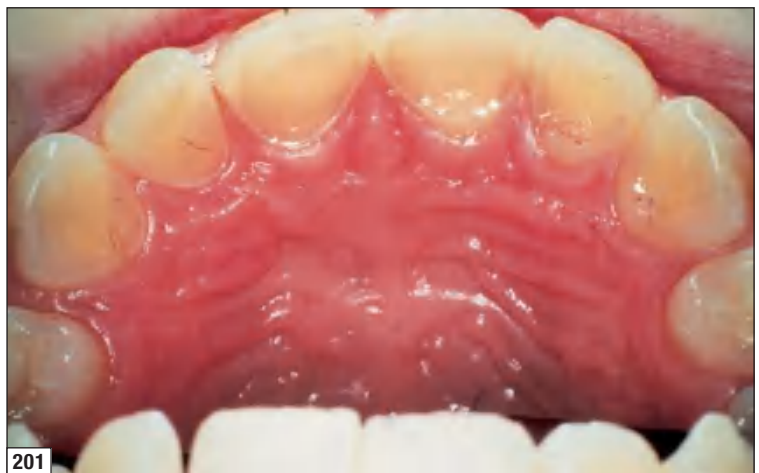
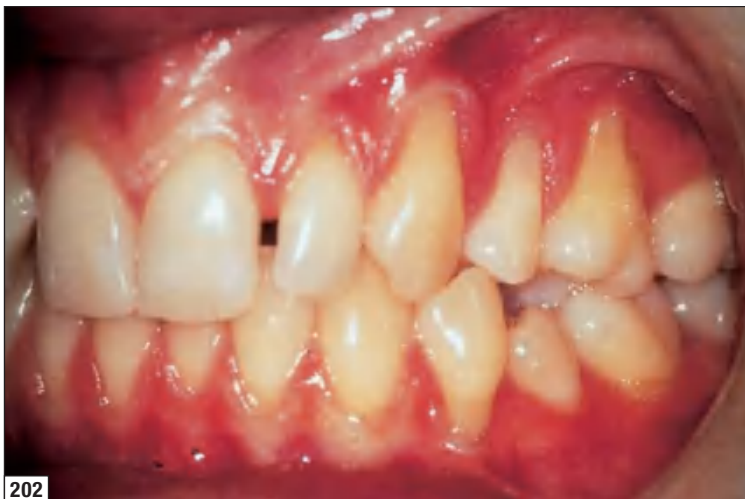
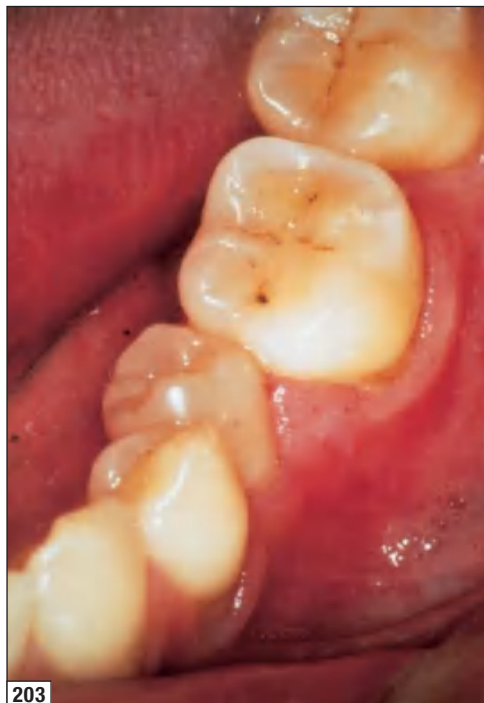Figure 201. Palatal erosion of the maxillary permanent canines and incisors in a cola drink addict.



Figures 202, 203. Erosion of both the occlusal and labial enamel in an adolescent with bulimia nervosa. In addition there is marked recession of labial gingiva caused by an incorrect brushing technique.



ERUPTION CYST AND HEMATOMA

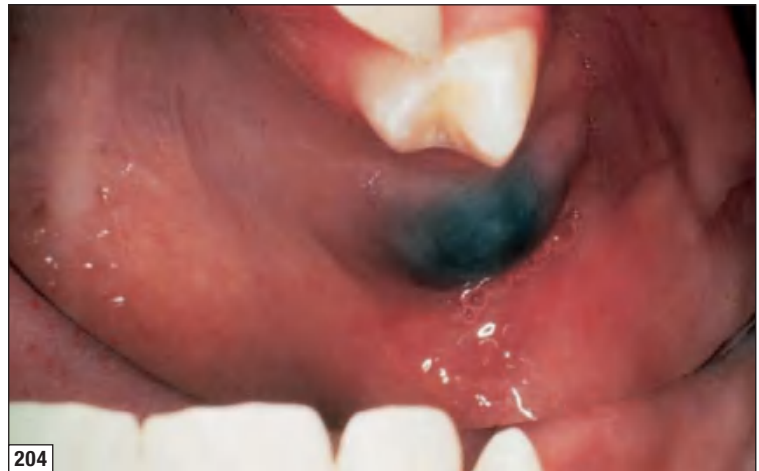The eruption cyst (Fig. 204) is a type of dentigerous cyst (i.e. it surrounds the crown of the tooth). This cyst often presents clinically as a smooth rounded swelling with a bluish appearance if there is no overlying bone. Eruption cysts most often involve the primary teeth and permanent molars (i.e. teeth with no predecessors) and often breakdown spontaneously as the tooth erupts.

Diagnosis

Diagnosis is clinical, supported by imaging.

Management

The condition is often best left alone. Surgery is indicated only if the tooth fails to erupt.



204

Figure 204. An eruption cyst in the maxilla heralding the imminent eruption of the second permanent molar tooth. The permanent second premolar and first molar have been extracted because of gross caries.

EXTERNAL RESORPTION

External resorption (Fig. 205) is usually either a response to trauma of the periodontal ligament or secondary to pulpal necrosis. Resorption is initiated in the periodontium and progresses from the external surface, eventually to involve the pulp.

Diagnosis

Diagnosis is clinical, supported by imaging.

Management

Endodontic care or extraction of the tooth is required.

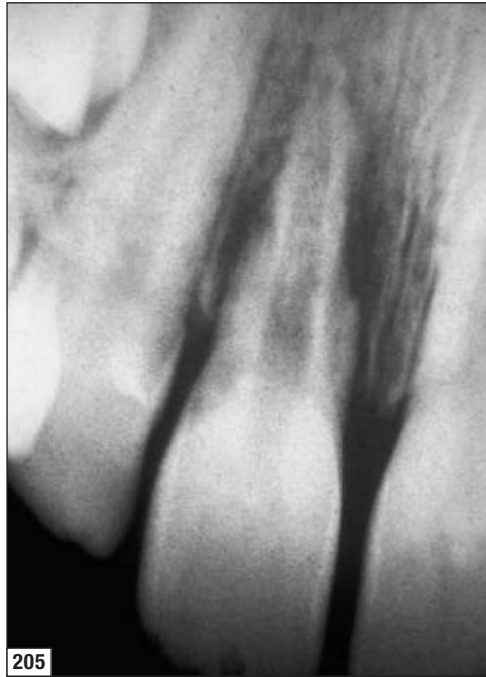

Figure 205. External inflammatory resorption affecting most of the root of a replanted maxillary permanent central incisor. The 'tram lines' of the root canal are still evident despite the 'moth-eaten' appearance of the root. This fact helps to distinguish external inflammatory resorption from internal inflammatory resorption, which is initiated from within the root canal.

EXTRINSIC STAINING

Extrinsic staining of the teeth (Figs 206–208) can be of various colors and is more likely to appear where plaque and chromogenic bacteria have accumulated. Discoloration is also seen when a carious lesion is present. Colored foods and beverages (spices, tea and grape juice), liquid or chewable medicines such as chlorhexidine, iron, multiple vitamins or long-term amoxicillin, and betel or tobacco products (smokeless tobacco and cigarettes) may be implicated.

Yellow/orange stain is believed to be caused by chromogenic bacteria and is also observed in children who receive liquid amoxicillin for long periods of time.

Brown stain is concentrated mainly where plaque accumulates, such as between the teeth, close to the gingival margins and in pits and fissures. It is usually caused by food and beverages, but can be caused by stannous fluoride products, chlorhexidine or betel or tobacco products.

Black stain is of unknown etiology often seen in clean mouths and is unusual in that it seems, by an unknown mechanism, to be associated with caries resistance. Also, black stain may be seen in children who take liquid ferrous sulfate for anemia. When there is a black dot appearance, it is thought to be caused by high levels of calcium and phosphate in the gingival debris, which could account for caries resistance.

Green stain is most common in children who have poor oral hygiene and may result from breakdown of blood pigment after gingival hemorrhage or from chromogenic bacteria.

Diagnosis

Diagnosis is clinical.

Management

Professional tooth cleaning is required.

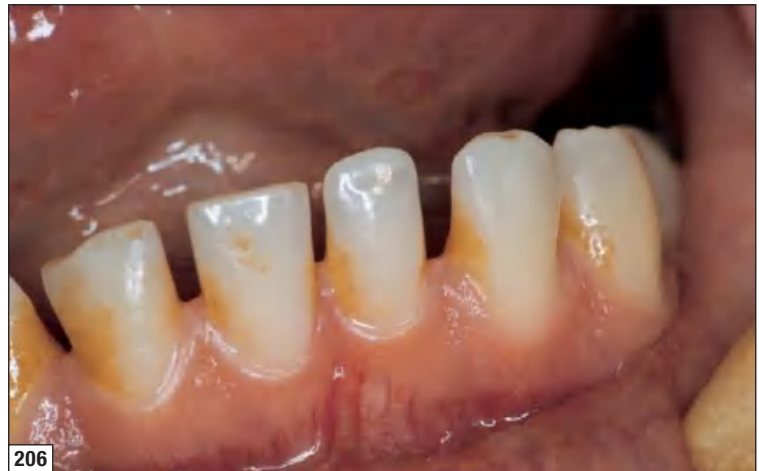

Figure 206. Orange amoxicillin superficial staining.

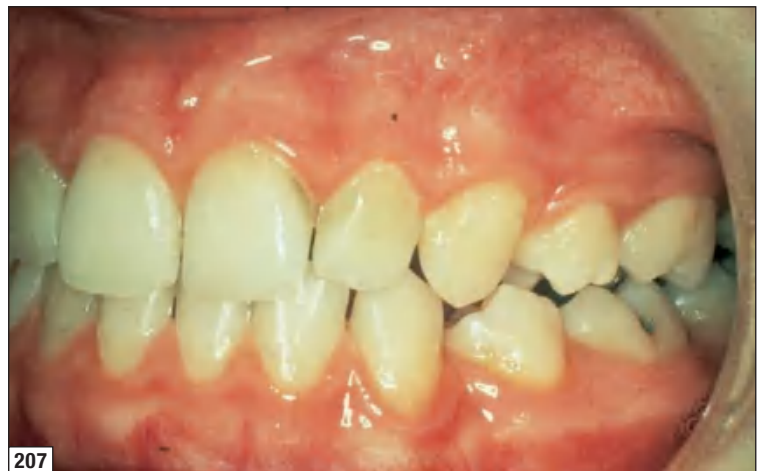

Figure 207. Green stain affecting the maxillary central and lateral permanent incisors as a result of poor oral hygiene.

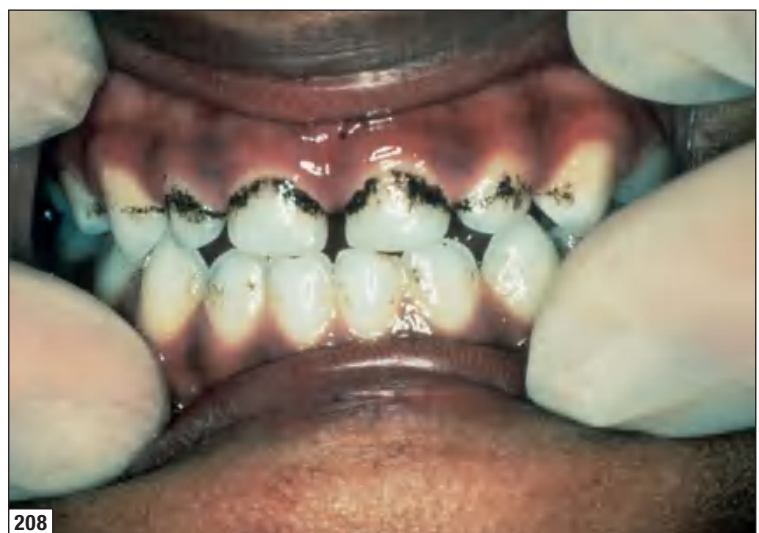

Figure 208. Black extrinsic stain affecting the primary dentition in an Ethiopian child who had a high intake of spicy foods and tea.

HYPERDONTIA

Additional teeth (Figs 209–218) can closely resemble the normal dentition (supplemental on accessory teeth) or be a simple conical shape (supernumerary teeth). In the midline, a supernumerary tooth is termed a mesiodens and may be inverted.

Unerupted supernumerary teeth often impede normal tooth eruption or more rarely are the site of cyst formation or cause of external resorption. Erupted supernumerary teeth can cause a malocclusion and may then predispose to caries or periodontal disease.

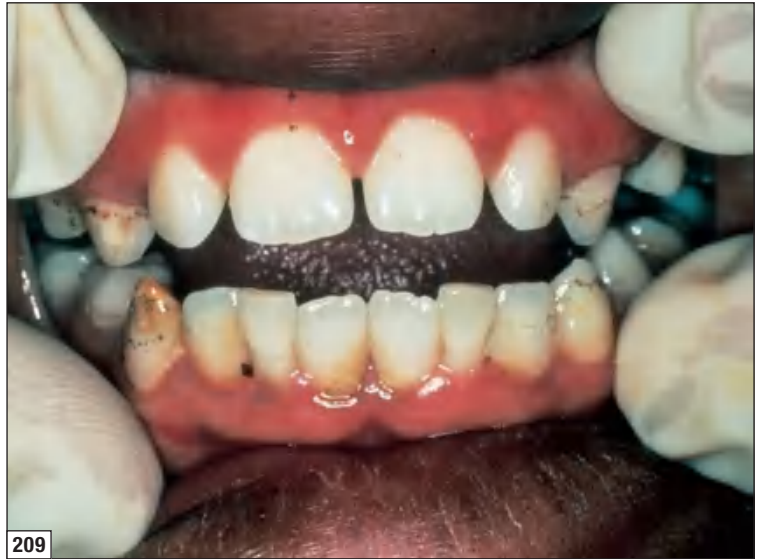Occasionally supernumerary teeth are a manifestation of a systemic disorder such as cleidocranial dysplasia or Gardner syndrome.

Diagnosis

Diagnosis is clinical, supported by imaging.

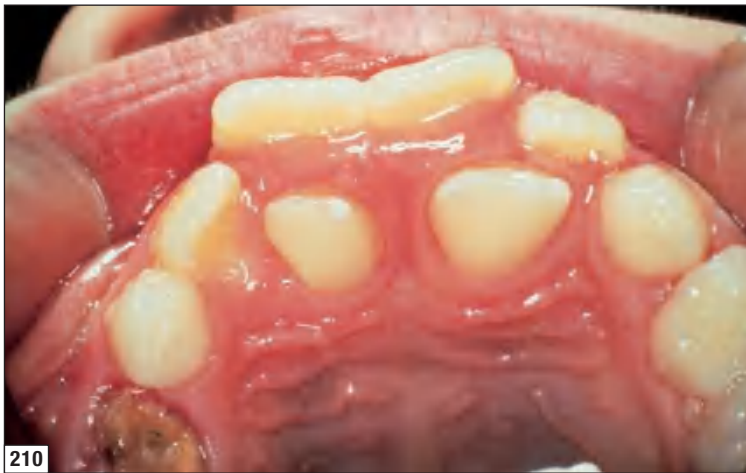Management

The extra tooth is often best removed. Otherwise, restorative dental care may be required.



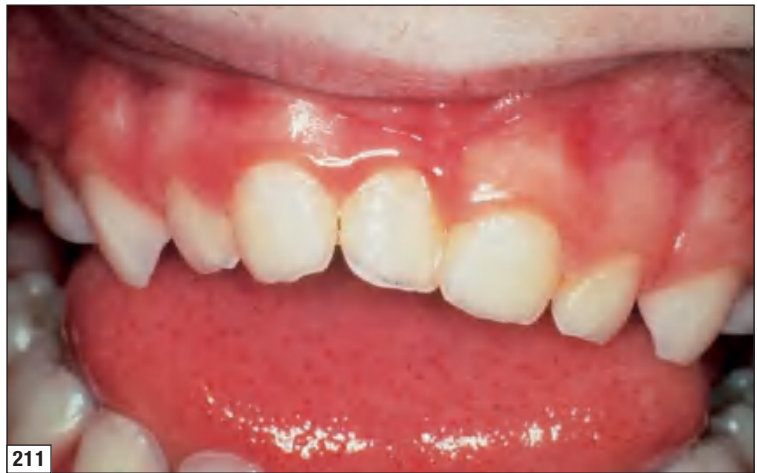209

Figure 209. Retained mandibular primary lateral incisors between central and lateral permanent incisors.



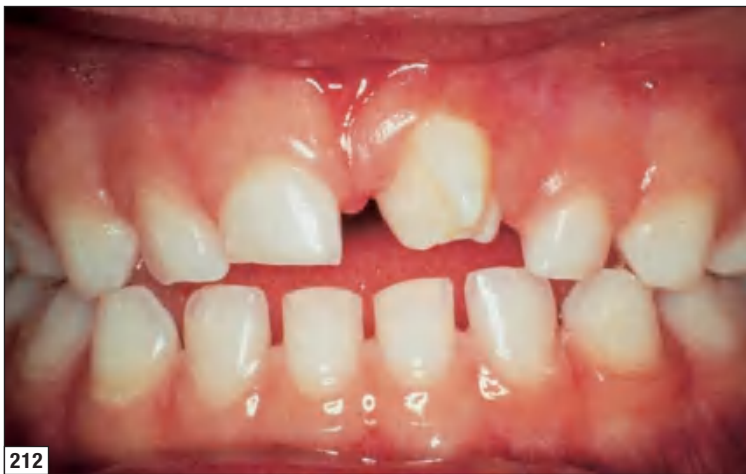210

Figure 210. Supplemental maxillary permanent lateral incisors have erupted palatal to the normal incisors.



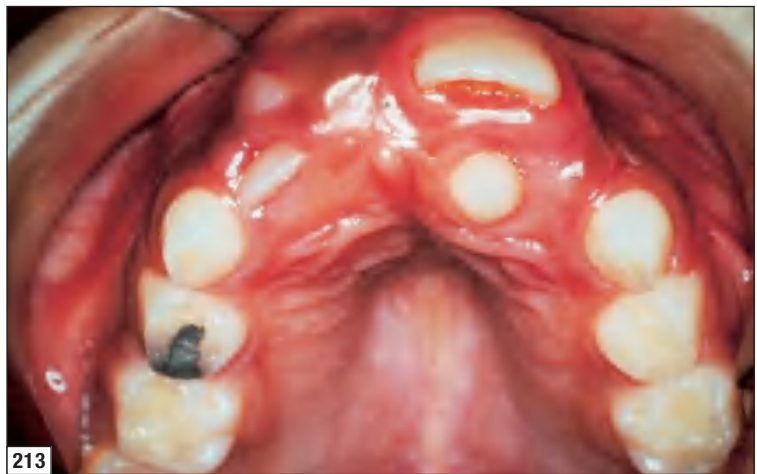211

Figure 211. A supplemental primary central incisor has erupted in the midline between the normal primary central incisors.



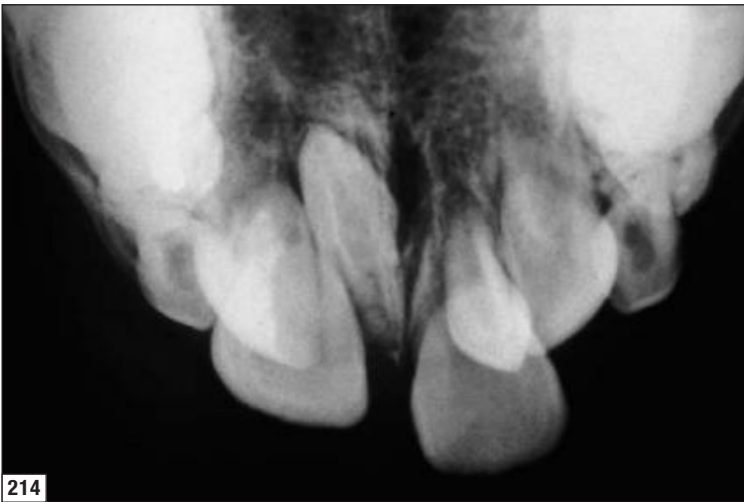212

Figure 212. The maxillary primary left central incisor exfoliated prematurely as a result of the eruption of a supernumerary element with a labially positioned 'talon' cusp.



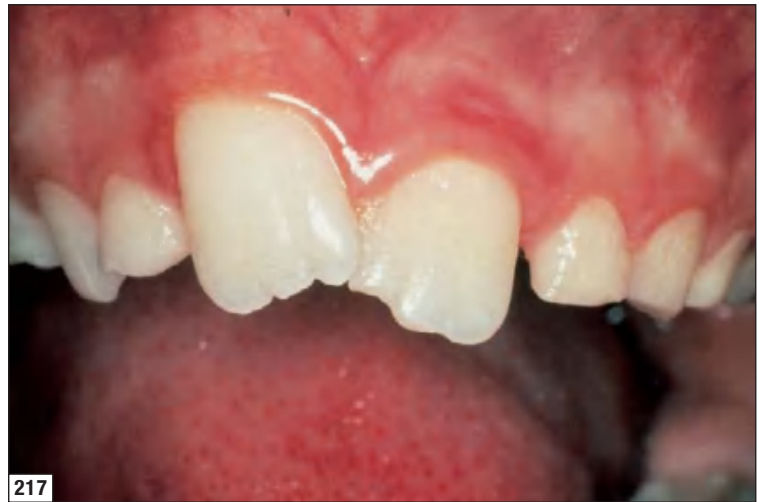213

Figure 213. There is an erupted supernumerary tooth palatal to the left maxillary central incisor. The right maxillary permanent central incisor is just visible high in the labial sulcus.



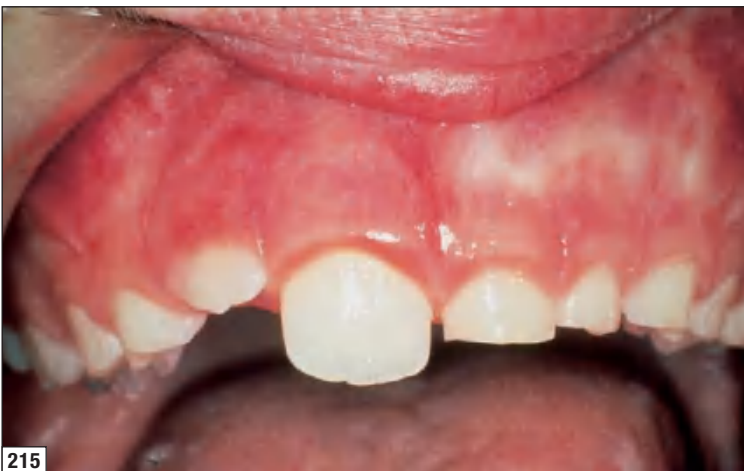214

Figure 214. The radiograph of Figure 213 shows an inverted mesiodens, which has impeded the eruption of the right maxillary permanent central incisor. The erupted left palatal supernumerary is also visible.



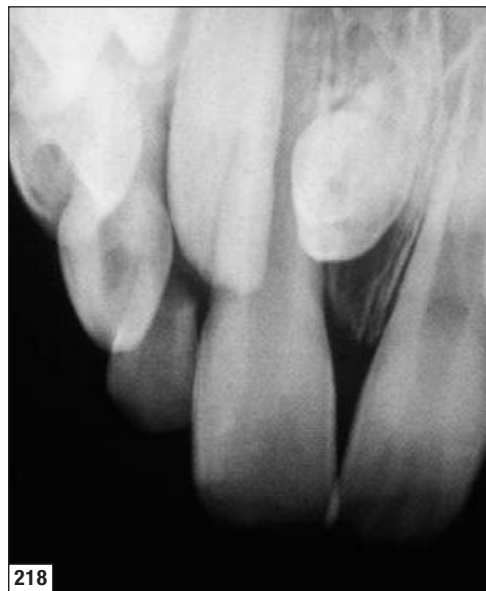217

Figure 217. Both maxillary permanent central incisors have erupted, but the right central incisor is not in alignment.



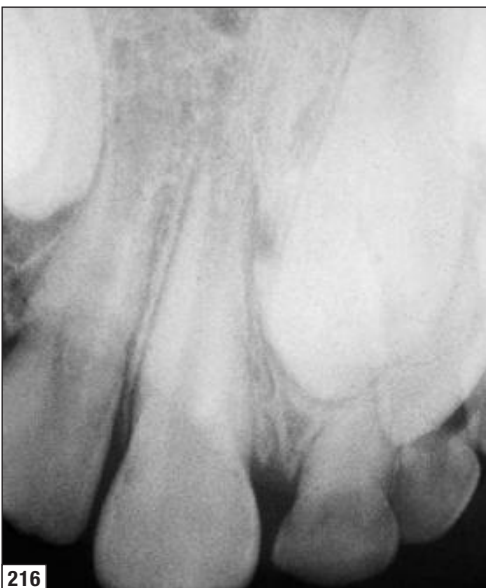215

Figure 215. There is failure of eruption of the maxillary left permanent central incisor.



218

Figure 218. The radiograph of Figure 217 shows a palatally positioned mesiodens, which has pushed the root and apex of the right central incisor distally.



216

Figure 216. Imaging of Figure 215 shows a mesiodens lying palatal to the crown of the unerupted tooth.

HYPERPLASTIC PULPITIS (PULP POLYP)

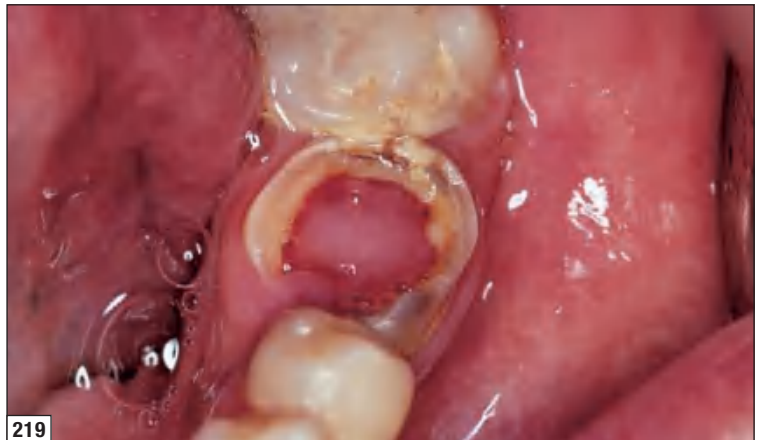The pulp survives trauma or carious infection only when the coronal pulp is widely exposed and there is a very good blood supply. This situation can occur in both primary and young permanent teeth, especially molars, and the pulp then becomes hyperplastic and epithelialized – producing a polyp (Fig. 219).

Diagnosis

Diagnosis is clinical.

Management

The tooth is often best removed. Otherwise, endodontic care is required.



219

Figure 219. Pulp polyp in a mandibular molar.

HYPODONTIA

Isolated hypodontia is fairly common, may have a genetic basis and affects mainly the permanent dentition, particularly third molars, second premolars or upper lateral incisors. Recently the gene, PAX9, has been identified in individuals who have multiple missing teeth. Hypodontia is often associated with microdontia and is often bilaterally symmetrical. The primary tooth is then commonly retained. Usually this is of little consequence, but occasionally, particularly in the case of lower primary molars, the retained tooth fails to maintain its occlusal relationship (infraocclusion or submergence).

Hypodontia is a feature of local disorders such as cleft palate and many systemic disorders. In some, the teeth are present, but fail to erupt; in others, such as ectodermal dysplasia or incontinentia pigmenti, they are truly missing (Figs 220–228). Rarely all teeth are absent (anodontia).

It is important to remember that teeth may be apparently missing because they are unerupted. In many cases this may be because they are impacted and therefore fail to erupt or, more rarely, eruption is delayed because of systemic disease, such as cretinism, hypoparathyroidism or Down syndrome.

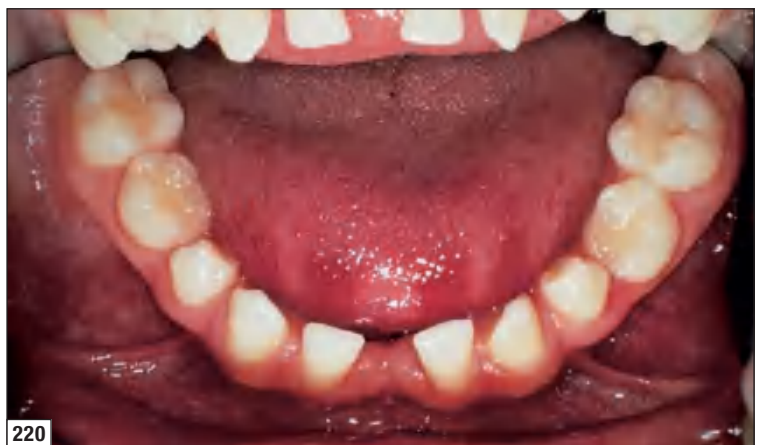Cytotoxic drugs and radiotherapy may also retard the eruption of teeth.

Diagnosis

Diagnosis is clinical supported by imaging.

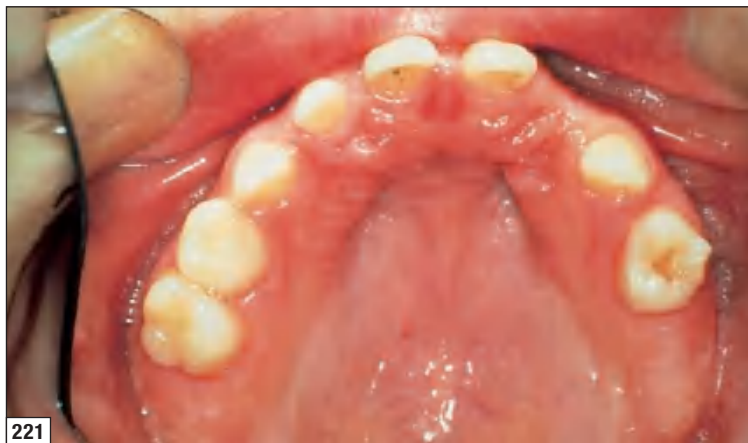Management

Restorative dental care is required. Dental implants may be indicated.

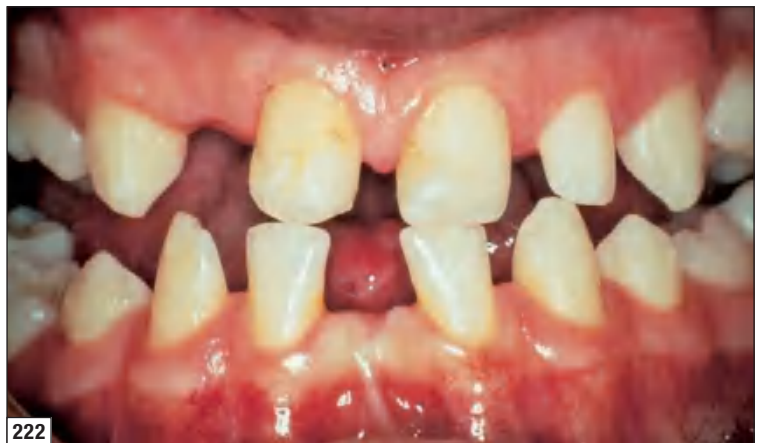

220

Figure 220. Hypodontia affecting the maxillary and mandibular arches in a 15-year-old male.

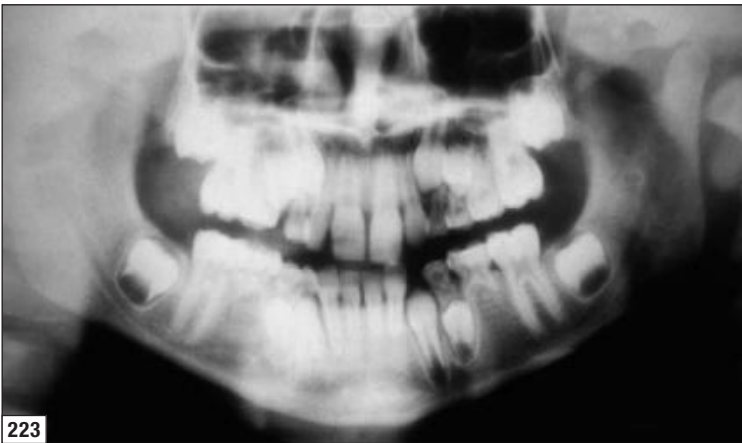

221



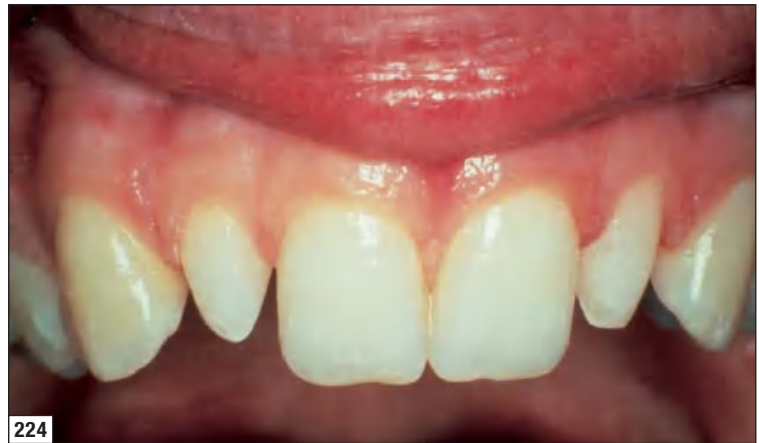222

Figures 221, 222. Multiple missing teeth.



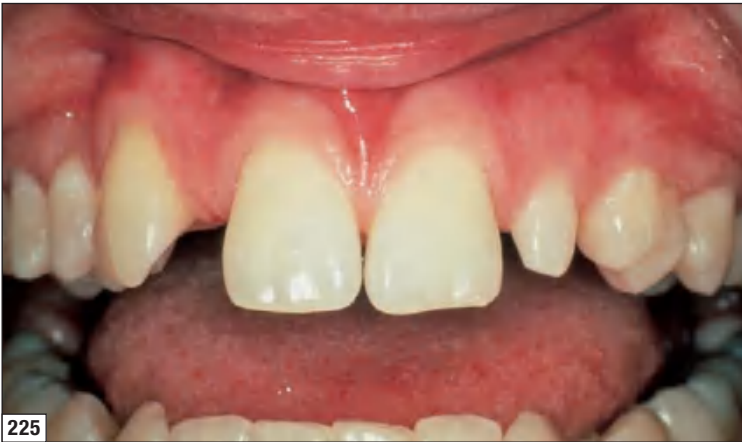223

Figure 223. The radiograph shows failure of tooth development of all permanent second premolars in a patient who had received chemotherapy between the ages of 2–2.5 years for the treatment of Wilms' tumor.



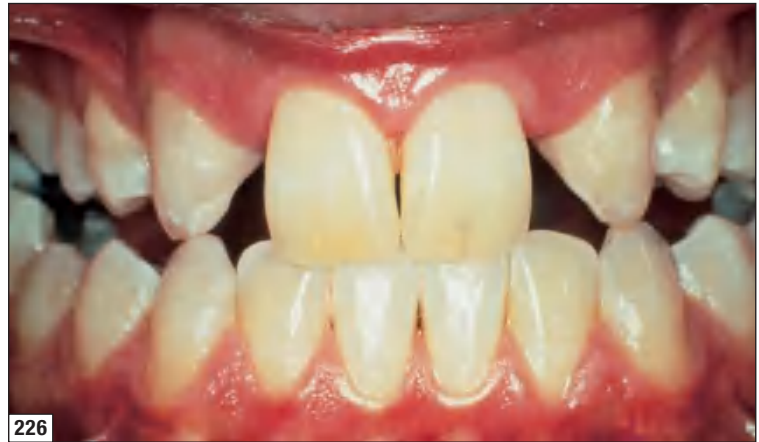224

Figure 224. Bilateral conical 'peg-shaped' permanent lateral incisors. There is often a family history of the same or of a peg-shaped lateral incisor on one side and absence on the contralateral side or of bilaterally absent lateral incisor.



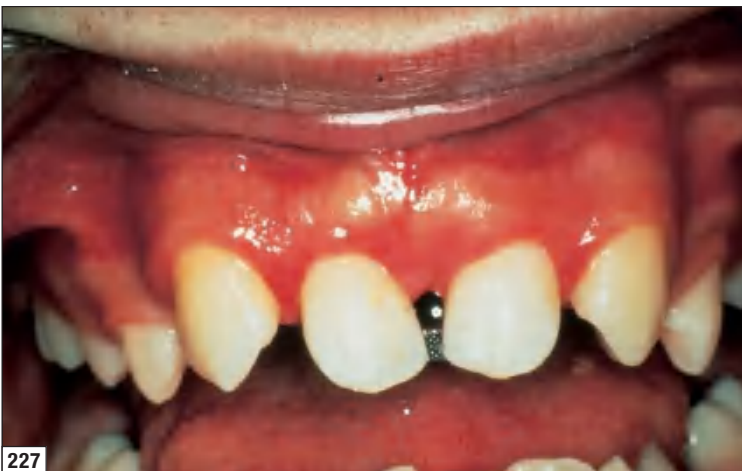225

Figure 225. A peg-shaped lateral incisor in the maxillary left quadrant with congenital absence of the maxillary right lateral incisor.



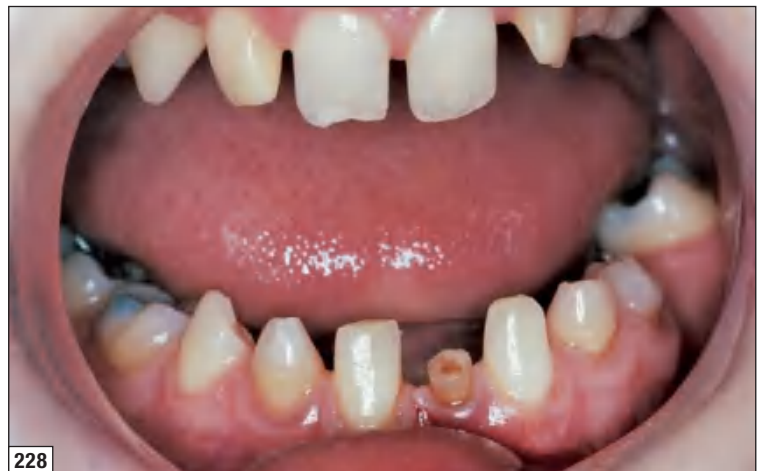226

Figure 226. Bilateral congenital absence of both maxillary permanent lateral incisors.



227

Figure 227. Traumatic hypodontia. Both maxillary permanent central incisors were lost at an earlier age as a result of trauma. The lateral incisors have drifted mesially to assume their current position.



228

Figure 228. Hypodontia with retained nonvital primary tooth.

IMPACTED TEETH

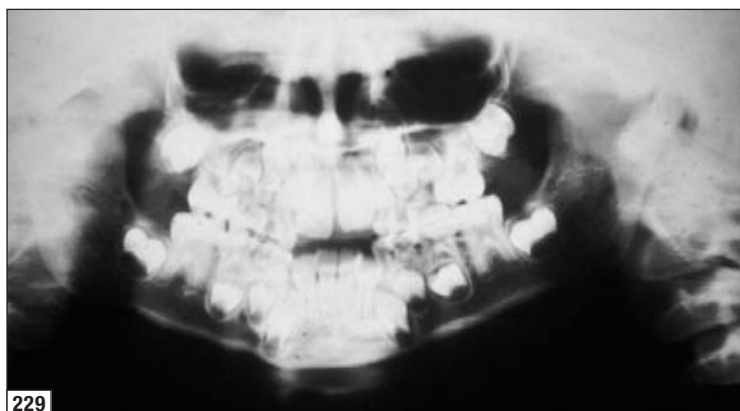
Lower third molars are the most common teeth to impact, that is, fail to erupt fully because of insufficient space (Figs 229–231). Canines and second premolars as well as other teeth also commonly impact. Impacted teeth may be asymptomatic, but occasionally cause pain, usually from pericoronitis or caries, or are the site of dentigerous cyst formation.

Diagnosis

Diagnosis is clinical, supported by imaging.

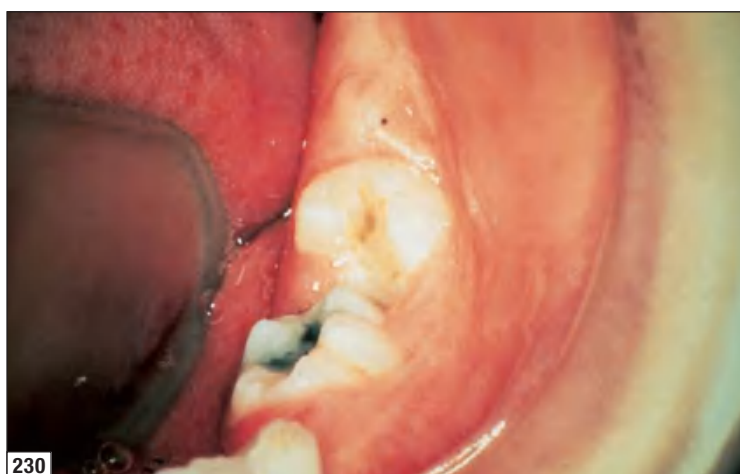Management

Exodontia is usually required in the child, especially when third molars are affected. Surgical exposure and orthodontic treatment may aid in bringing an impacted tooth into occlusion.



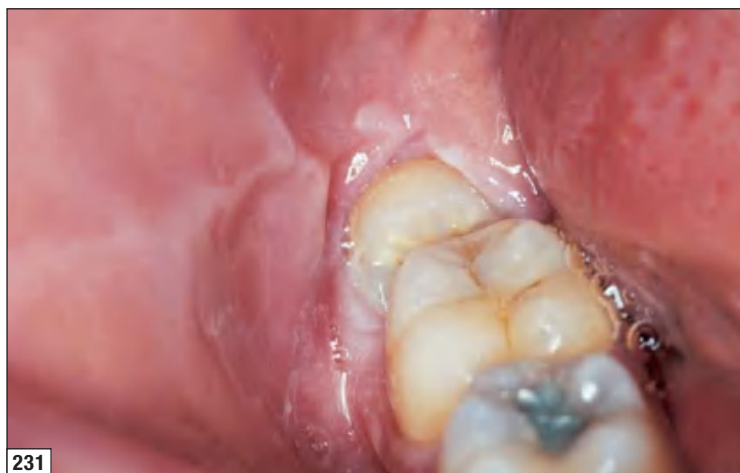229

Figure 229. The left maxillary first permanent molar has not erupted fully into the arch, but has impacted into the distal surface of the second primary molar. This is an occasional finding with no obvious cause.



230

Figure 230. The mandibular first permanent molar has erupted mesially to impact against the second primary molar. Such impactions are more common for mandibular third molars. There was no obvious cause for the impaction in this case.



231

Figure 231. Impacted mandibular third molar (wisdom tooth).

INTERNAL RESORPTION (PINK SPOT)

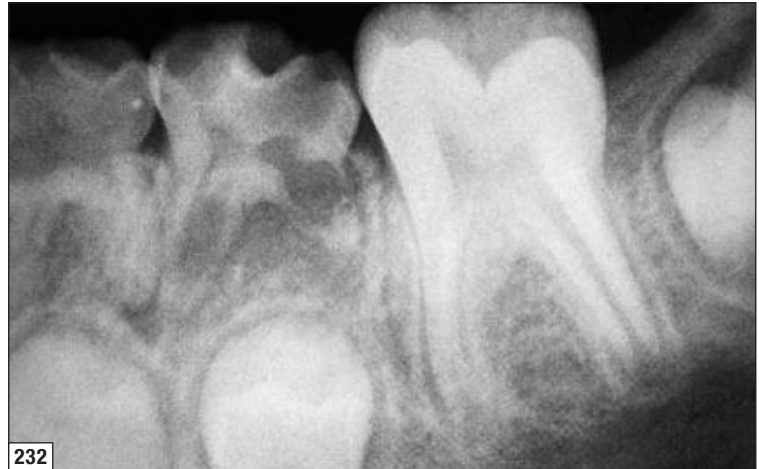In internal resorption (Figs 232–234) dentine is spontaneously resorbed resulting in enlargement of the pulpal chamber or canal. When it affects the crown of the tooth, pink discoloration is observed. The tooth is eventually lost as a result of marked root or coronal resorption. It is common to see this pattern when primary teeth are close to exfoliation and only a thin shell of the crown is present.

Diagnosis

Diagnosis is clinical, supported by imaging.

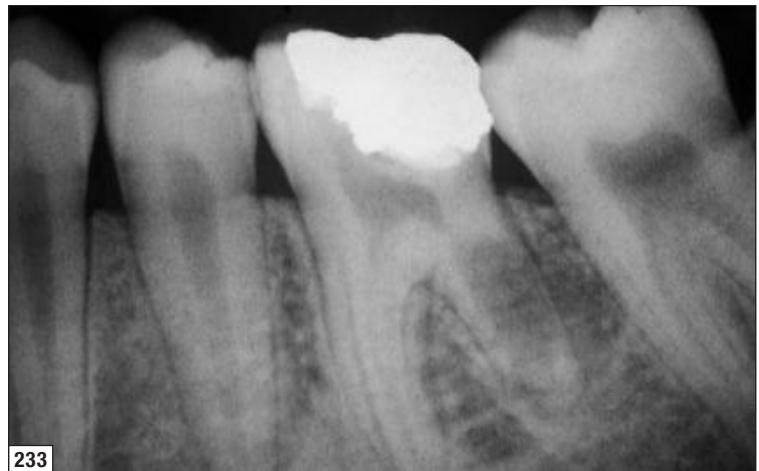Management

Endodontic care or extraction is required.



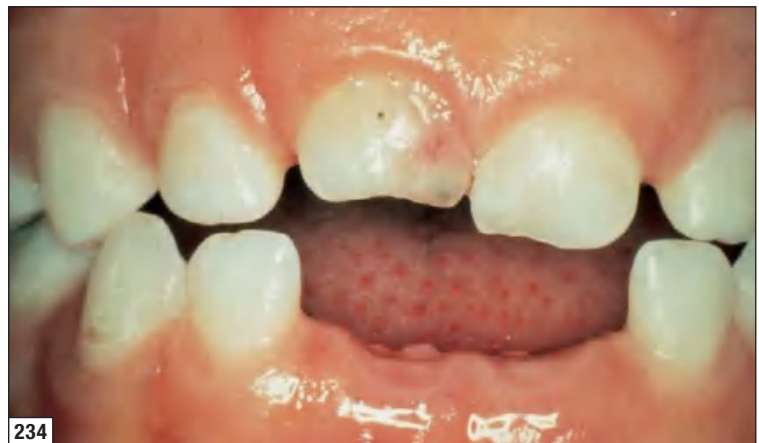232

Figure 232. There is internal resorption affecting both roots of the mandibular second primary molar. The architecture of the root canal is lost and there is ballooning of the canal as successive amounts of dentine are replaced with inflammatory and granulation tissue. The stimulus for internal resorption is from the necrotic products of pulpal necrosis.



233

Figure 233. There is internal resorption affecting the distal root of the mandibular first permanent molar.



234

Figure 234. Internal resorption in a primary maxillary right central incisor occurring naturally in a tooth about to be exfoliated. The pink hue produced by granulation tissue within the crown is visible.

INTRINSIC STAINING

Etiology

Fluorosis

Mottling of the enamel may be seen where the fluoride in drinking water exceeds about 2 ppm or where excess fluoride is taken via other sources, in particular from the ingestion of fluoridated toothpastes (Figs 235–237). In mild fluorosis, white flecks or patches are usually seen at even lower fluoride levels. Severe fluorosis causes brown and white mottling and pitting of the entire enamel. This can be difficult clinically to differentiate from amelogenesis imperfecta. The mottling is often severe enough to require cosmetic treatment of the upper anterior teeth.

Idiopathic

Whitish flecks in the enamel (Fig. 238) are not uncommon and may be idiopathic, but in both the primary and permanent dentition these whitish flecks commonly represent mild fluorosis.

Jaundice

Hemolytic disease of the newborn (icterus gravis neonatorum) is now rare and more infants survive with hyperbilirubinemia as a result of other causes such as biliary atresia. Jaundice in either case may cause enamel hypoplasia, usually in the permanent dentition, but the primary teeth may have a green–gray color that tends to fade over time (Figs 239–242).

Tetracyclines

Tetracyclines are a relatively common cause of tooth staining in adults, but this is rarely seen in children because tetracyclines are no longer recommended for this age group (Figs 243–245). Tetracyclines are taken up by developing teeth and by bone and if given to pregnant or nursing mothers or to children under the age of 8 years the tooth crowns become discolored. Staining is most obvious in light-exposed anterior teeth, initially being yellow, but darkening with time. Staining of the permanent dentition – yellow and brown bands of staining – is most obvious at the cervical one-third of the teeth where the thinner enamel allows the color of the stained dentine to show through. Staining is greater the larger the dose of tetracycline, and is least with oxytetracycline. Affected teeth may fluoresce bright yellow under ultraviolet light and this helps to distinguish tetracycline staining from dentinogenesis imperfecta. Fluorescence is also seen in undecalcified sections viewed under ultraviolet light. In older children most tooth crowns have formed and tetracycline staining then affects only the roots.

Porphyria

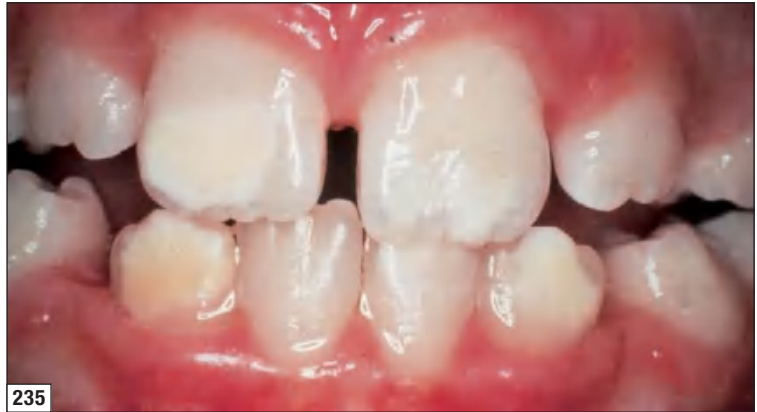Congenital erythropoietic porphyria is a rare cause of yellow to brown–red tooth discoloration.

Diagnosis

Diagnosis is clinical, supported by imaging.

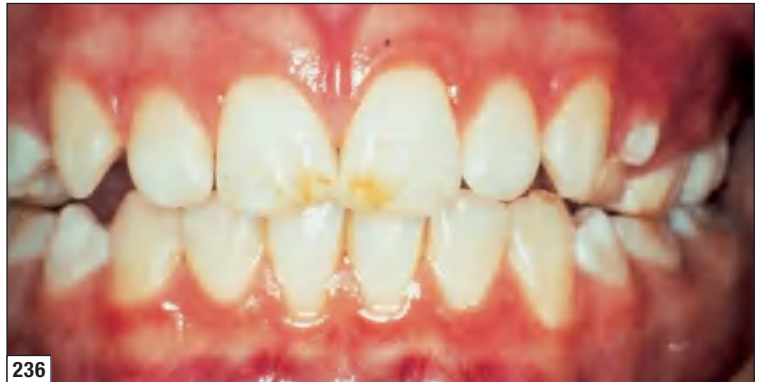Management

Restorative dental care is required.



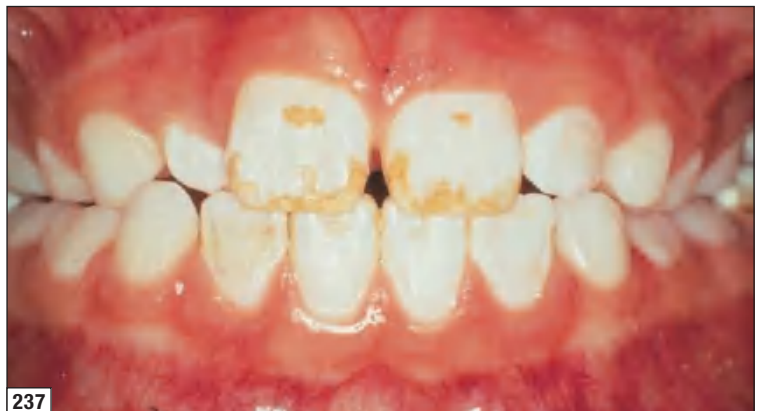235

Figure 235. Mild fluorosis. There are diffuse white opacities affecting all the permanent teeth. In addition there is brown staining of the maxillary central incisors and both the maxillary and mandibular first permanent molars. This patient had lived from birth to the age of 7 years in Tanzania where there was a naturally fluoridated water supply.



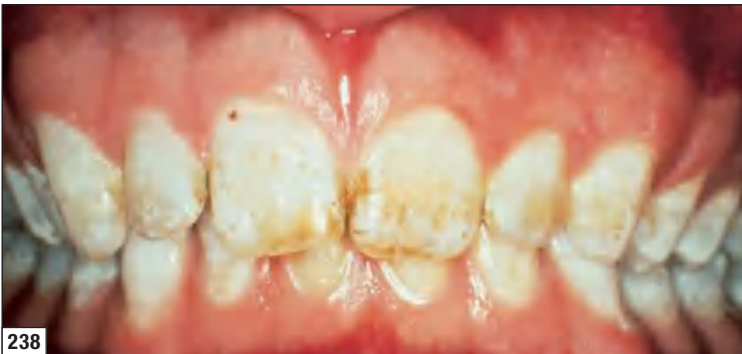236

Figure 236. A more severe case of fluorosis than in Figure 235. The brown staining on the maxillary incisors is more extensive and darker in color. This patient had a well documented history of eating fluoridated toothpaste.

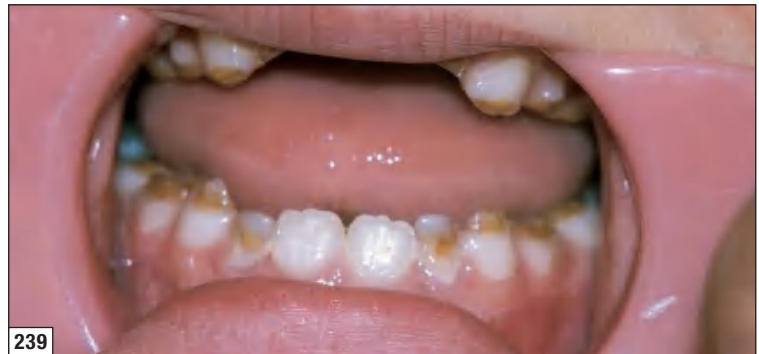

237

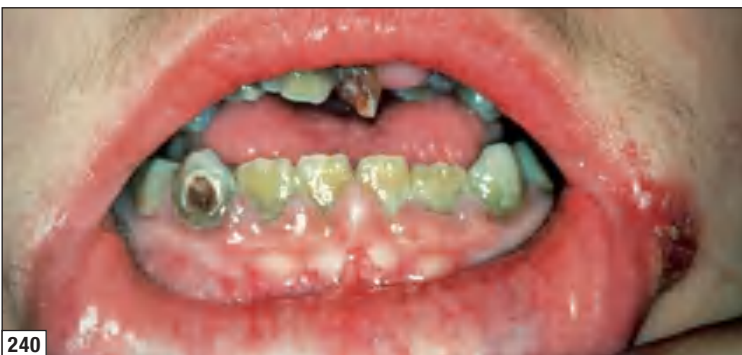Figure 237. Severe fluorosis with pitting of the enamel as well as white and brown mottling. This patient has been brought up in the Far East where there was not only a naturally fluoridated water supply, but also fluoride supplements in the form of tablets had been taken.



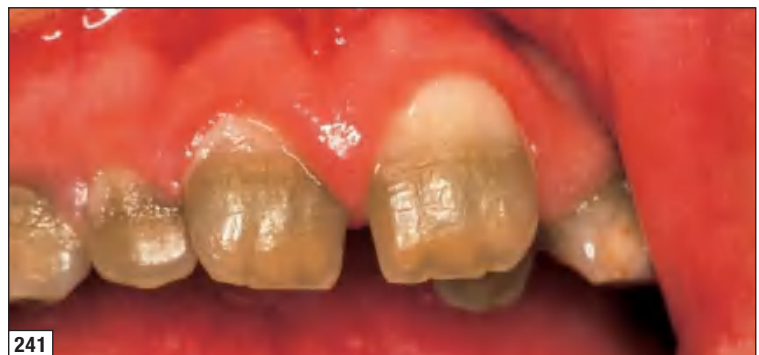238
Figure 238. Idiopathic white patches affecting the permanent maxillary central and mandibular lateral incisors.



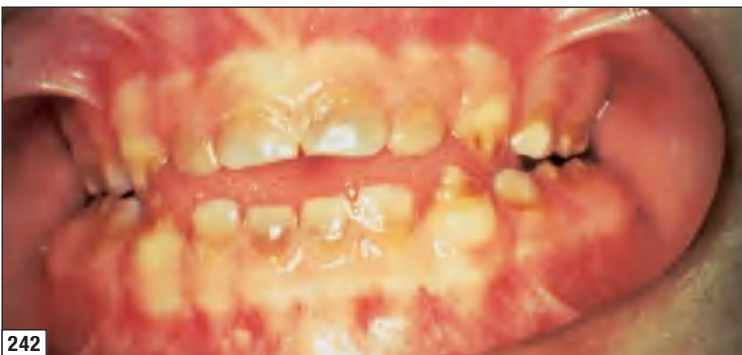239
Figure 239. Kernicterus showing pigmented enamel hypoplasia of the primary teeth.



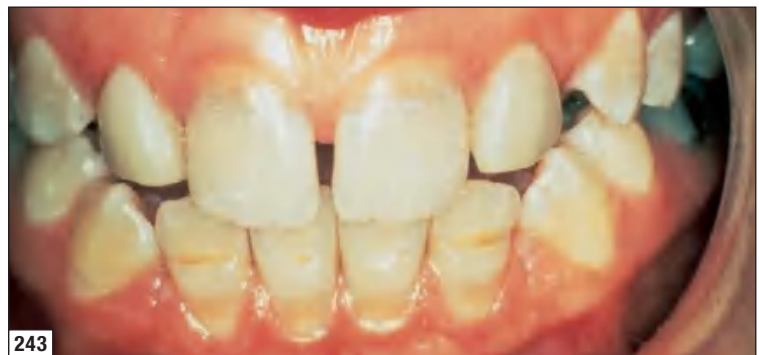240
Figure 240. Bile pigment staining of teeth in congenital liver disease. There is also oral neglect with caries, and gingival hyperplasia produced by ciclosporin therapy after liver transplantation.



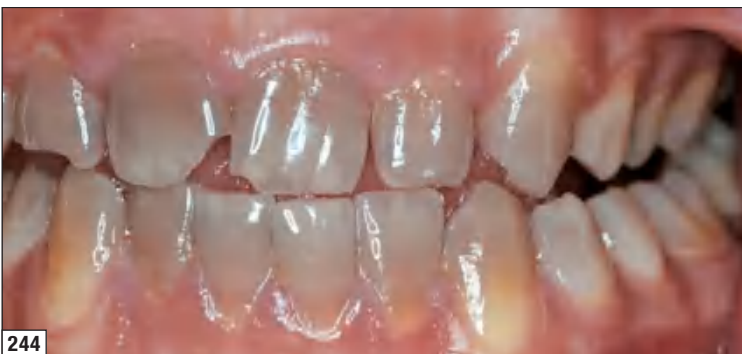241
Figure 241. Bile pigment staining of teeth in congenital liver disease.




242
Figure 242. Bile pigment staining from biliary atresia has discolored the incisal half of these teeth, but following liver transplantation the later-developing tooth structure is unpigmented.



243
Figure 243. Tetracycline staining.



244
Figure 244. Intense yellow tetracycline staining of the permanent dentition. Banding is more evident in the mandibular incisors.



245
Figure 245. Fluorescence of tetracycline stained tooth under ultraviolet light.

MACRODONTIA

In true generalized macrodontia (Fig. 246) all the teeth are larger than normal. In hemihypertrophy of the face or when vascular lesions are present, the teeth of the involved side may be larger than the unaffected side.

Diagnosis

Diagnosis is clinical, supported by imaging.

Management

The condition is often best left alone. If a malocclusion exists, orthodontic therapy and selective extractions may be indicated.

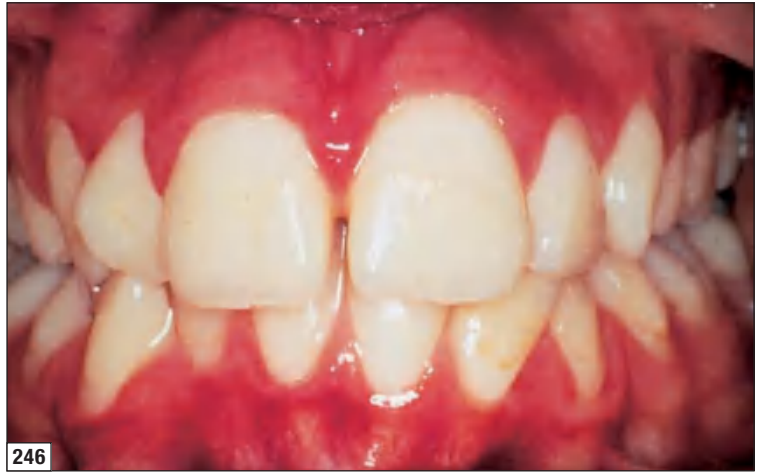

Figure 246. True generalized macrodontia. Both maxillary permanent central incisors were 12 mm in diameter.

MALOCCLUSION

Malocclusion is the improper positioning of the teeth and jaws (Figs 247–249). It is a variation of normal growth and development, which can affect the bite (occlusion), the ability to clean teeth properly, gingival health, jaw growth, speech development and appearance. Textbooks of orthodontics give full details of this subject.

Heredity and environmental factors can both play a role in the development of malocclusion. The shape and size of the face, jaws and teeth are mostly inherited, though environmental factors can also have an impact; irradiation and chemotherapy, for example, can markedly influence the growth of the face and dentition.

Treatment of disorders such as crowded teeth or protruding teeth has an impact on both aesthetics and oral function. In addition, prominent teeth can be damaged easily during sports.

Crowding of teeth is very common, particularly in the canine, second premolar and lower incisor regions. The permanent canines normally erupt slightly later than the premolars and lateral incisors and if there is lack of space in the dental arch (dentoalveolar disproportion), they are crowded out of the dental arch. Second premolars and third molars are the other teeth that may suffer this fate. Any of these teeth, especially lower third molars, may impact. The lower incisors are frequently crowded and malaligned (imbricated).

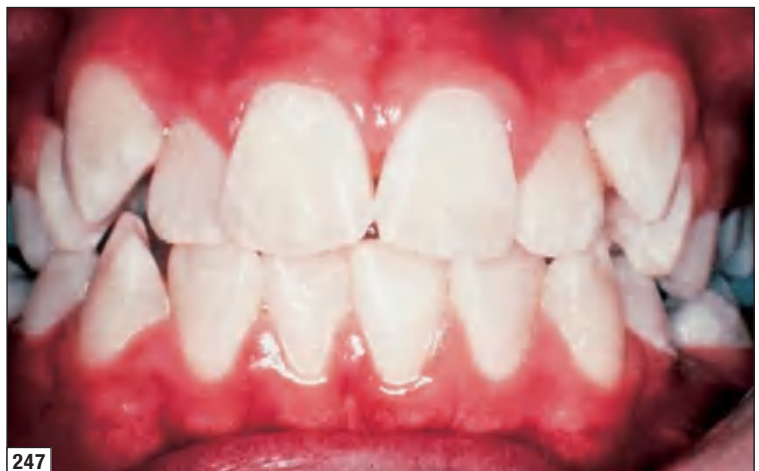

Figure 247. Crowding. There is insufficient space for the maxillary permanent canine teeth, which have erupted buccal to the arch, resulting in them becoming more prominent.

Mandibular retrusion is common, but only rarely results in a typical 'bird face'. Maxillary protrusion is also common and this type of malocclusion is termed a class II malocclusion. Mandibular protrusion (class III malocclusion) is uncommon, but typically associated with the Hapsburg chin of a prognathic mandible. In mandibular protrusion, the teeth often show reverse overjet with the upper incisors occluding lingual to the lowers.

In anterior open bite (Figs 250, 251), the posterior teeth are in occlusion, but the incisors fail to meet. Anterior open bites may be caused not only by increased height of the lower face, but by tongue posture, trauma or thumb-sucking or pacifier habits.

Diagnosis

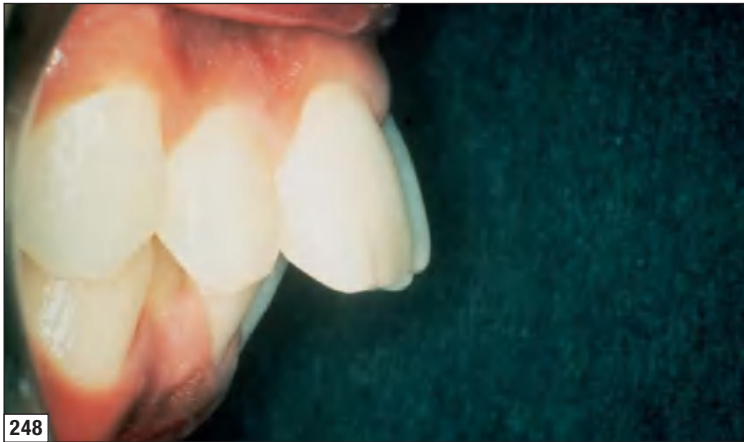Diagnosis is clinical, supported by imaging.

Management

Most orthodontic treatment is carried out in children because the teeth can then be most readily moved. Some problems are treated most effectively when the child is actively growing and for this reason, the timing of referral is critical. This particularly applies to children who have very prominent upper teeth and a small lower jaw. Failure to treat at the appropriate age may mean that orthodontic correction of the problem

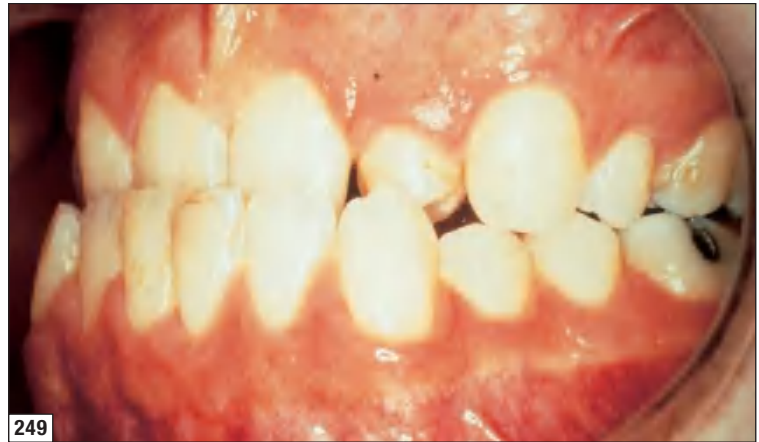is not feasible and may result in the patient having to undergo surgery at a later stage.

Carefully controlled removal of selected primary teeth may be necessary to guide the permanent teeth into proper position. Some malocclusions cannot be treated successfully without removing permanent teeth and there are other situations where removal of permanent teeth is contraindicated. Typically, premolars are the teeth selected for extraction because this maintains aesthetics. In other cases, molar teeth may be extracted because this offers space for tooth alignment and these teeth are the most likely to become carious. Only very rarely are anterior teeth extracted. Treatment otherwise mostly involves moving the teeth through the supporting alveolar bone to the desired position; this must be carried out slowly and carefully, to avoid pain or damage to the teeth. It is carried out using either fixed or removable appliances. These appliances (braces) gently move the teeth and bone until they are in a desirable position. The braces consist of a bracket, made of plastic, metal or ceramics, and an arch wire, which connects them. The teeth are moved by adjusting the pressures on them via the archwire. Springs or elastic bands may be used to help. The appliances are tightened periodically and some discomfort is felt at that time, for a few hours to several days. The length of time required to move the teeth to the desired location varies with an average of 18–30 months for children.



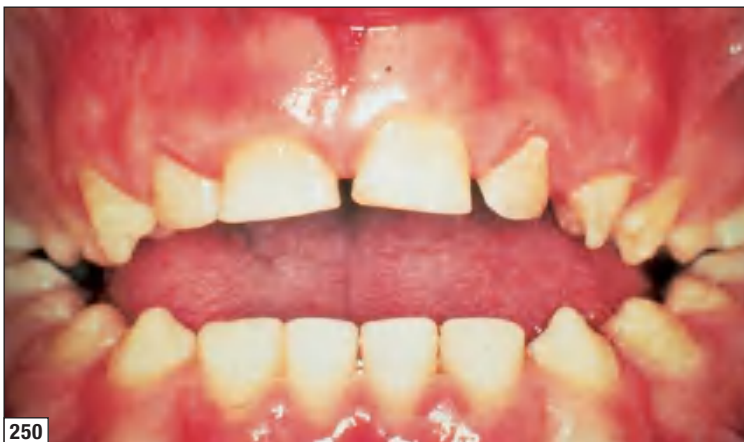248

Figure 248. Class II malocclusion, type I. The maxillary permanent central incisors are prominent and with the posterior teeth in occlusion the lips will not be able to cover the anterior teeth whilst at rest. The overjet in this case was 11 mm.



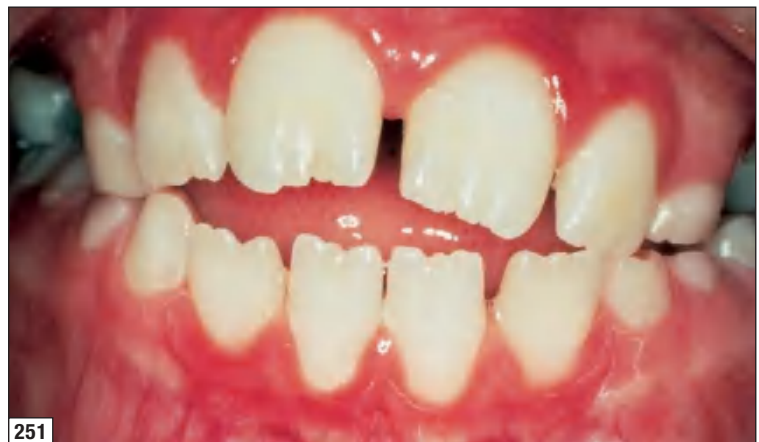249

Figure 249. Class III malocclusion.



250

Figures 250, 251. Anterior open bite. The posterior teeth are in occlusion, but the incisors fail to meet.



251

ODONTOMES

Odontomes are a group of non-neoplastic developmental anomalies or malformations derived from dental formative tissues. They contain fully formed enamel and dentine and can be considered as dental hamartomas.

The complex odontome (Fig. 252) consists of a mass of irregularly arranged dental tissue in which enamel, dentine, cementum and pulpal tissue are represented. The compound odontome comprises numerous discrete tooth-like structures, which may not resemble teeth of the normal dentition, but in which enamel, dentine, cementum and pulp are arranged as in a normal tooth.

Invagination of enamel and dentine (dilated odontome; dens in dente; dens invaginatus; Fig. 253) may also dilate the affected tooth. Ameloblasts invaginate during development to form a pouch of enamel such that a radiograph shows what resembles a tooth within a tooth. This odontome is prone to caries development in the abnormal pouch. Pulpitis may follow.

A small occlusal nodule, (evaginated odontome; dens evaginatus; Fig. 254) is seen, especially in mongoloid races. Because the nodule contains a pulp horn, pulpitis is not uncommon when there is attrition.

Diagnosis

Diagnosis is clinical, supported by imaging.

Management

Complex and compound odontomes require surgical removal. Restorative dentistry is usually required for other odontomes.

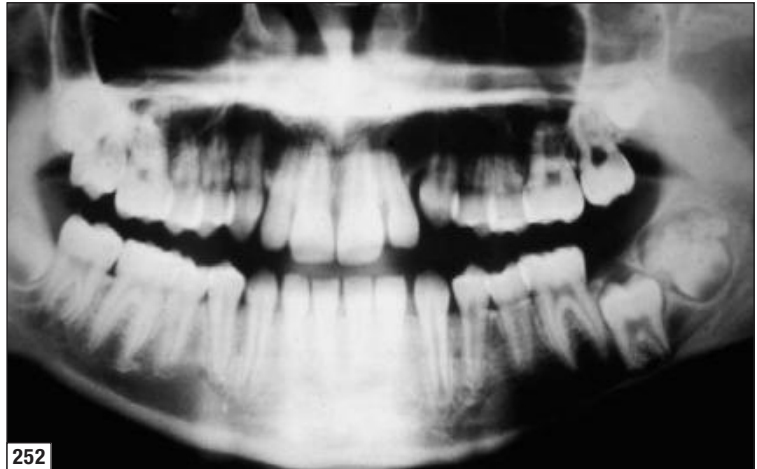

Figure 252. A complex odontome in the left mandibular angle arising from a developing third permanent molar. The patient had received chemotherapy from 8–10 years of age for acute lymphoblastic leukemia.

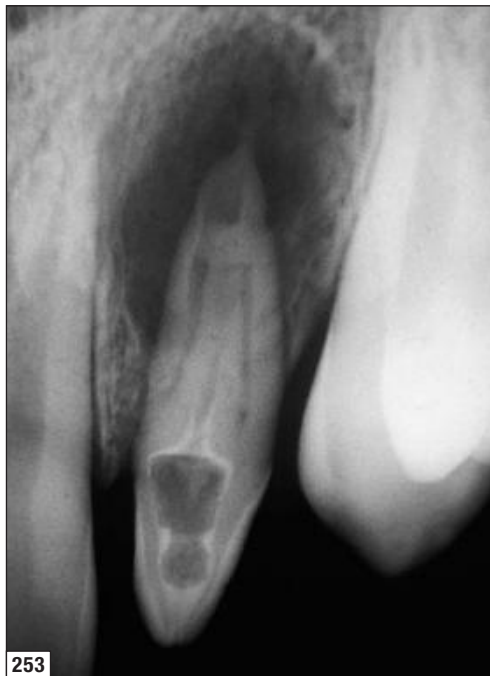

Figure 253. An invaginated odontome of the maxillary permanent left lateral incisor. Pulpal infection has resulted in a large periapical abscess.

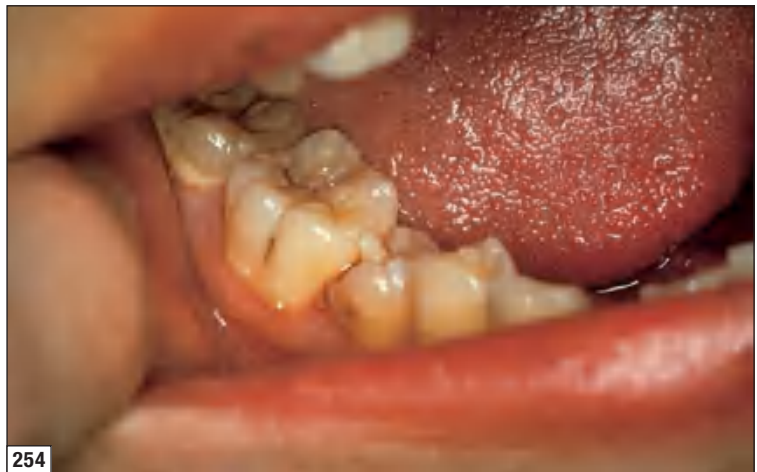

Figure 254. Dens evaginatus.

PROMINENT TUBERCLES OR CUSPS

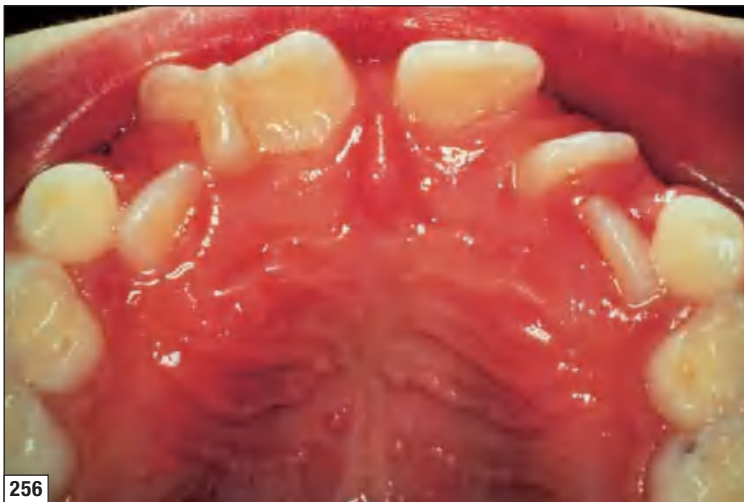Teeth are occasionally malformed with a large palatal cusp, sometimes to the extent that they have a talon cusp configuration (Figs 255–257).

Diagnosis

Diagnosis is clinical, supported by imaging.

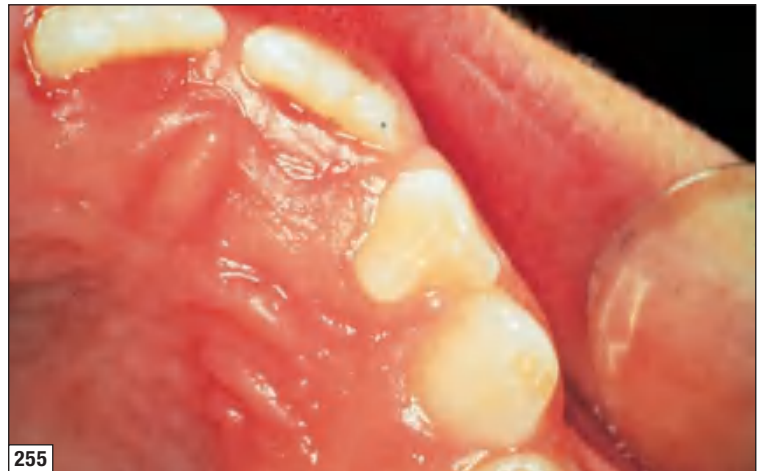Management

The condition is often best left alone. Otherwise, restorative dentistry is usually required.



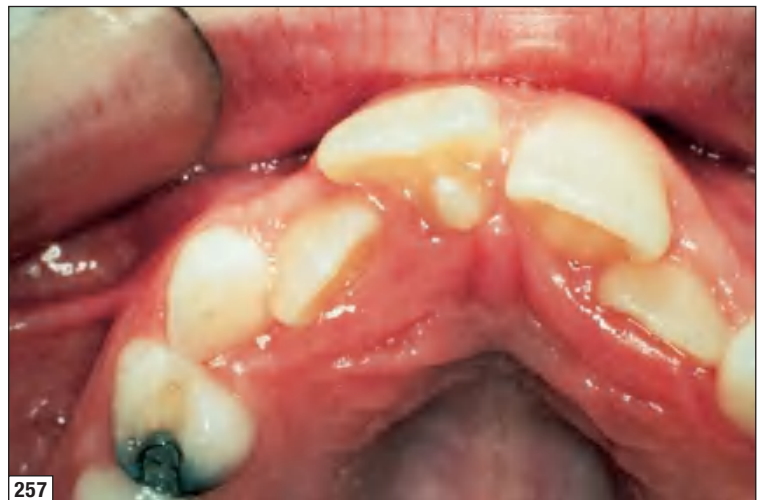256

Figure 256. There is a large connated tooth in the maxillary right permanent central position, which also has a prominent palatal (talon) cusp. On the other side of the arch there is a supplemental lateral incisor. In this case the connated tooth has probably arisen as a result of fusion between the normal central incisor and a supplemental element.



255

Figure 255. A talon cusp of the maxillary right lateral primary incisor. Such prominent cusps in either the primary or the permanent dentitions may interfere with occlusion and then necessitate treatment.



257

Figure 257. A prominent palatal cusp on the cingulum area of the maxillary permanent right central incisor.

TAURODONTISM

Taurodontism (Fig. 258) is the term applied to teeth that clinically look normal, but on a radiograph, resemble those of ungulates (hence the Latin origin, *taurus*, a bull). The crown is long, the roots short. Taurodont teeth lack a pronounced constriction at the neck of the tooth and are parallel-sided. The floor of the pulp chamber is lower than normal and the pulp appears extremely large. Taurodontism usually affects permanent molars, especially the lower second molar, sometimes only one in the arch, but may affect teeth in the primary dentition.

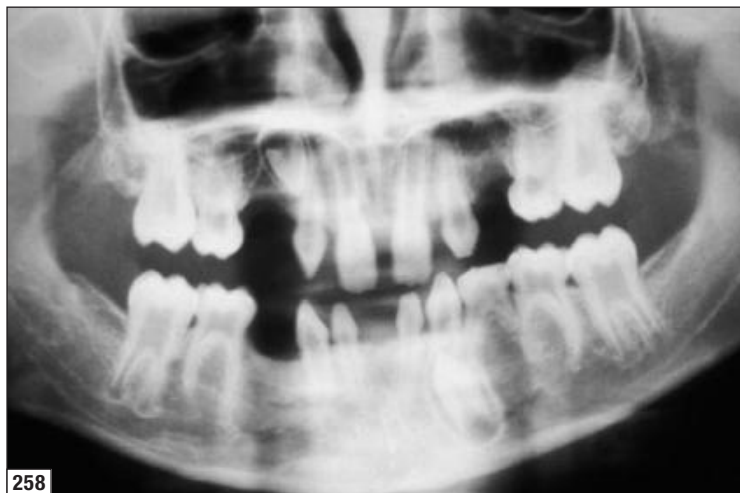Taurodontism is usually a simple racial trait, but may rarely be associated with a genetic disorder such as Klinefelter syndrome, trichodonto-osseous syndrome; oral-facial-digital syndrome or ectodermal dysplasia.

Diagnosis

Diagnosis is clinical, supported by imaging.

Management

The condition is best left alone.



258

Figure 258. Taurodontism of the maxillary and mandibular first permanent molars.

TRANSPOSITION

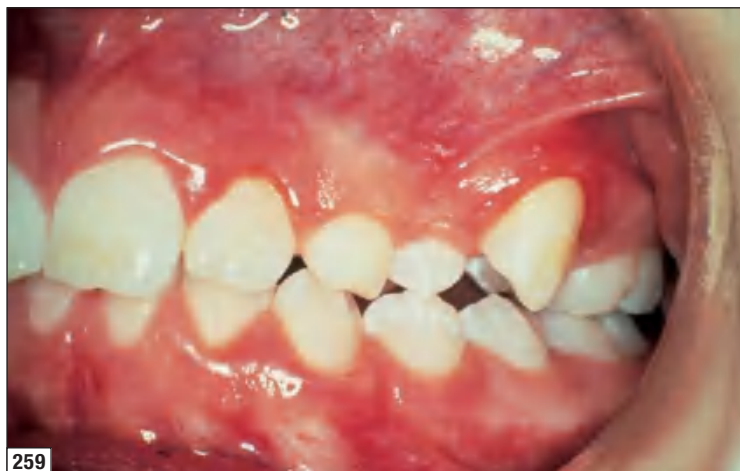A transposition (Fig. 259) is when the normal positions of two teeth are reversed (transposed).

Diagnosis

Diagnosis is clinical, supported by imaging.

Management

Orthodontics or restorative dentistry options are usually required.



259

Figure 259. Transposition: the maxillary permanent left canine has erupted distal and buccal to the first premolar.

TRAUMA

Although any tooth can be traumatized it is mainly the maxillary incisors that are damaged (Figs 260–261). The damage to a crown can involve the enamel alone or can extend to involve the dentine or even pulp. The pulps of affected teeth may become necrotic after trauma (and then darken with time and may result in periapical abscess formation) or the tooth may be subluxed or lost completely. Always ensure that this is not a nonaccidental injury.

Diagnosis

Diagnosis is clinical, supported by imaging.

Management

Fractured teeth

Restorative dentistry is usually required to protect the pulp of fractured teeth. If the pulp has been affected, then endodontic treatment may be required.

Avulsed primary teeth

Avulsed primary teeth should not be replanted.

Avulsed permanent teeth

The quicker a tooth is replanted, the better the prognosis for permanent retention; teeth replanted within 15 minutes stand a 98% chance of being retained. The best method is to:

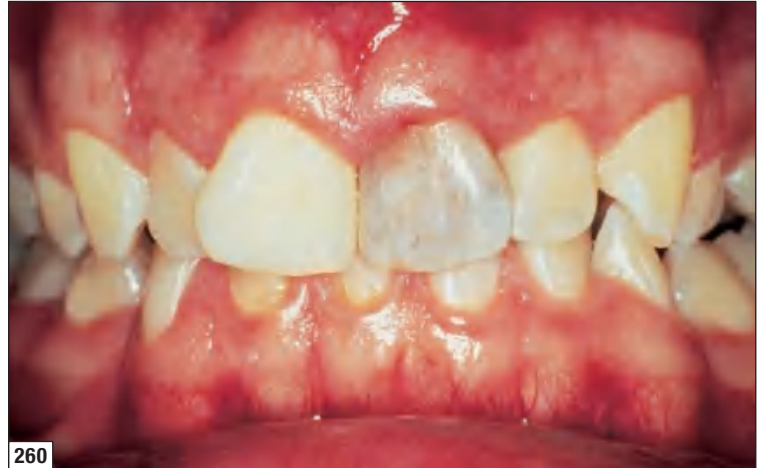- replant as soon as possible
- hold the tooth by the crown (do not handle the root)
- if contaminated, rinse with sterile or clean water or saline.

If immediate replantation is not possible, place the tooth in cool fresh milk or saline; otherwise, if the child is cooperative, place the tooth in the buccal sulcus and get to the dentist as soon as possible:

- if the socket contains clot, remove it with saline irrigation
- replant the tooth in the correct position
- manually compress the socket bony plates
- splint for 7–10 days, soft diet, Chlorhexidine mouthwash, Amoxicillin 125–250mg TDS for 5 days
- regular follow up is required
- fully formed apex teeth will require extirpation prior to splint removal
- open apex teeth replanted within 30–45 mins may revascularise and should be followed very closely

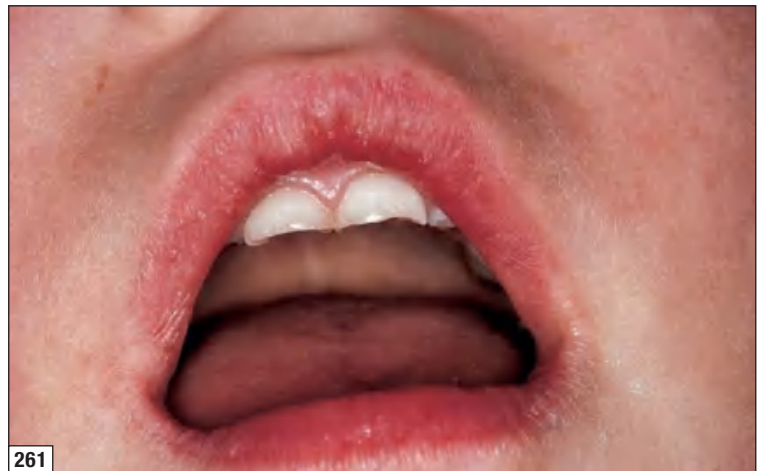After extirpation:

- non-setting calcium hydroxide should be placed in root canal and changed 3 monthly until there is no evidence of progressive resorption at 1 year after replantation



260

Figure 260. The maxillary permanent left central incisor is nonvital and discolored as a result of trauma some years previously. Products of blood breakdown and pulpal necrosis have passed into the dentinal tubules to give the dark blue-gray appearance.



261

Figure 261. Trauma to both maxillary central incisors.

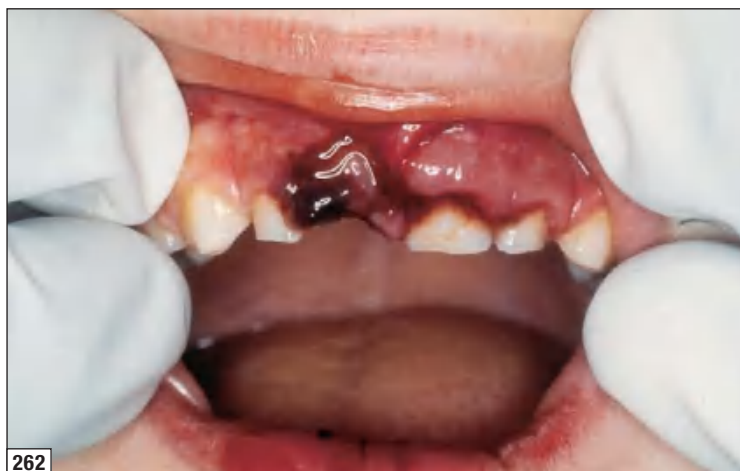CHILD ABUSE (NONACCIDENTAL INJURY)

Child abuse is any act of omission or commission that endangers or impairs the physical or emotional health or development of a child (Figs 262–267). It is an important condition to be recognized because there is a high risk of further assaults on or death of the child and of siblings.

Abused children frequently have facial and oral lesions and most are less than 3 years of age and usually less than 1 year of age. The child is often cowed, may also be malnourished and generally neglected, and there may be evidence of previous trauma and delay in seeking care.

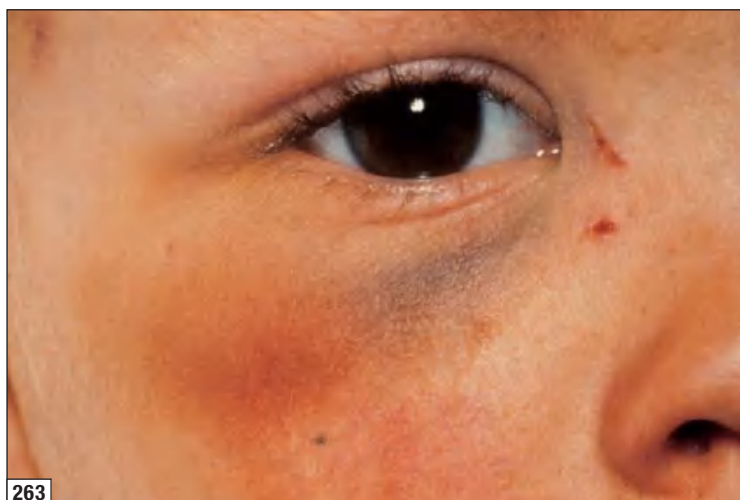Extra oral injuries are varied and often multiple. Lacerations, bruising, pinching, bites, abrasions or burns are the main soft tissue lesions. Intra orally abrasions, lacerations and dental trauma are common injuries. Burns are less common. Abrasions, lacerations and burns are often caused by the feeding implements or by food or drink in the young infant. Torn labial frenums should be regarded as suspicious in the child who is not yet learning to walk. A significant number of children have old fractures to ribs or long bones. Fractures to the jaws are less common but 95% of all head injuries under the age of 1 are non-accidental. There may be permanent neurological and intellectual impairment.

Child abuse must be suspected if any injuries are incompatible with the history. After genuine accidents, children are usually immediately taken for medical or dental attention; when children are abused, there is often considerable delay. The child must be fully examined to exclude serious injury, especially subdural hematomas or intraocular bleeding, and must therefore be admitted to hospital. Full records *must* be kept. A skeletal radiographic survey should be undertaken to reveal both new and old injuries and a pediatrician should be consulted.



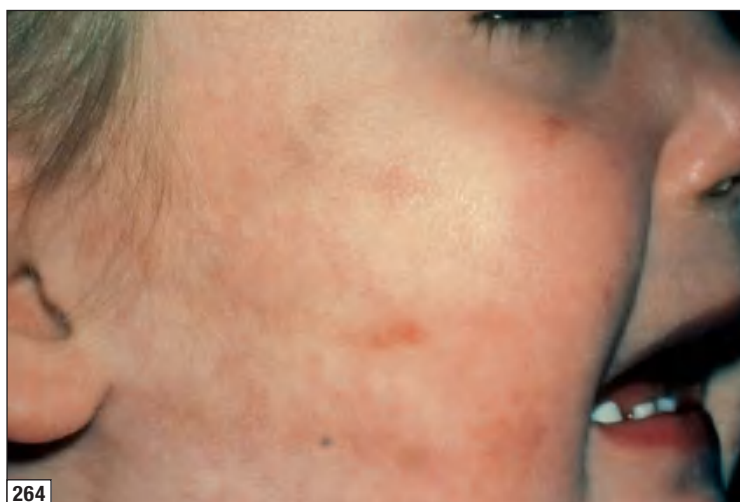262

Figure 262. Nonaccidental injury (child abuse) – dental injuries.



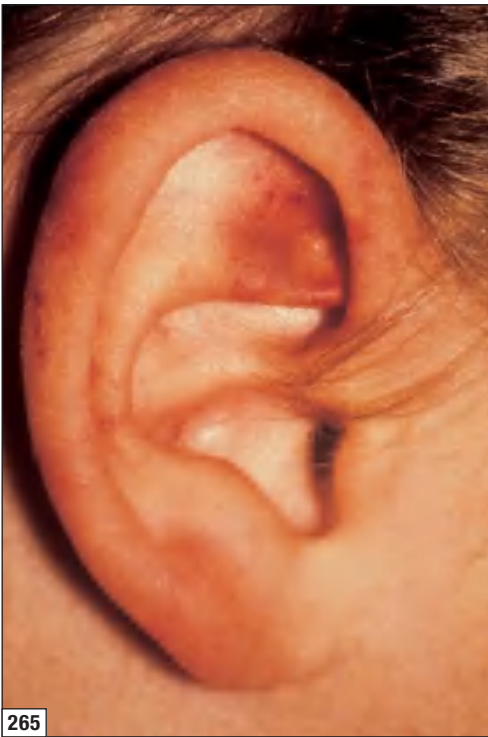263

Figure 263. Nonaccidental injury (child abuse) – bruises of different vintages with small lacerations.



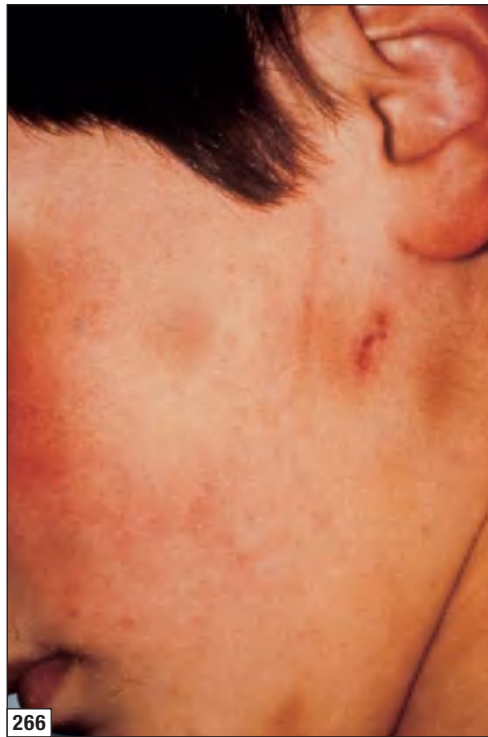264

Figure 264. Nonaccidental injury (child abuse) – parallel bruises from the slap of a hand.



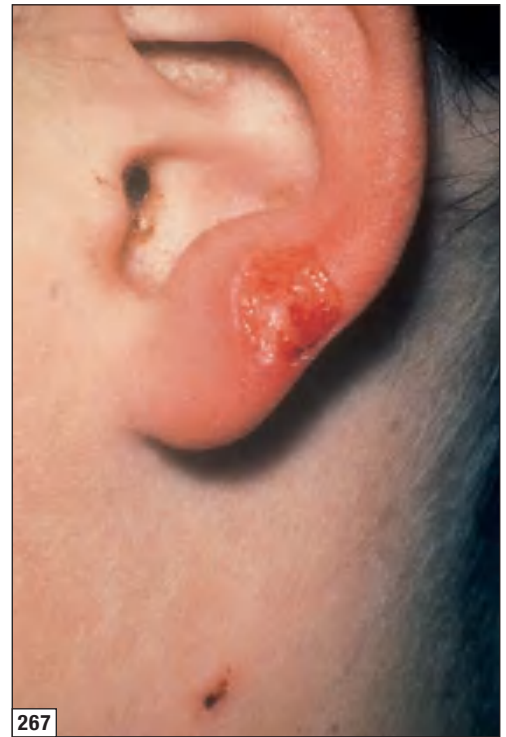265

Figure 265. Nonaccidental injury (child abuse) – pinch mark to upper ear.



266

Figure 266. Nonaccidental injury (child abuse) – finger tip bruising with small lacerations.

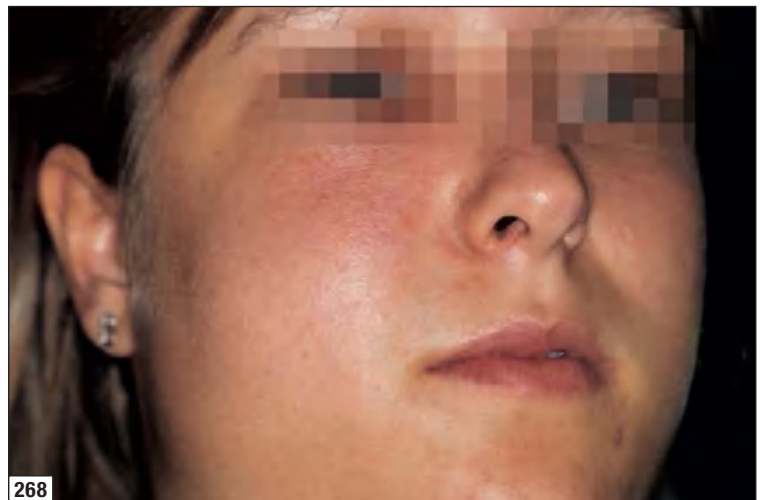

267

Figure 267. Nonaccidental injury (child abuse) – cigarette burn to ear.

SURGICAL EMPHYSEMA

Air may enter the subcutaneous tissues via a number of routes after trauma (Fig. 268), especially if an air rotor is used for surgery, and sometimes during endodontic treatment. The emphysema produces swelling that crackles on palpation. It typically resolves spontaneously, but it is prudent to offer a course of antibiotics. Occasionally the air may track to the mediastinum.



268

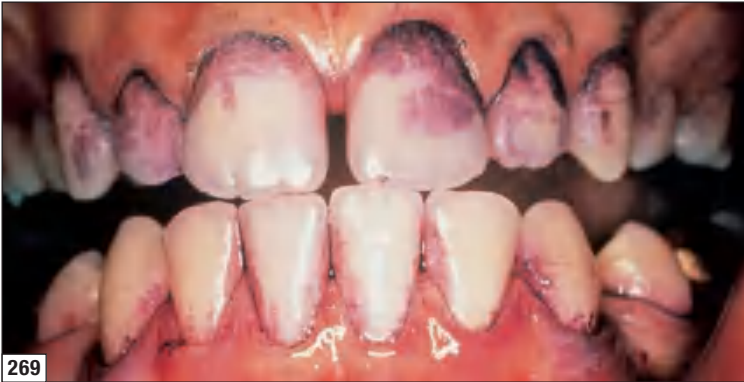Figure 268. Surgical emphysema, arising from the introduction of air into the subcutaneous tissue, during dental treatment.

5

Acquired gingival and periodontal disease

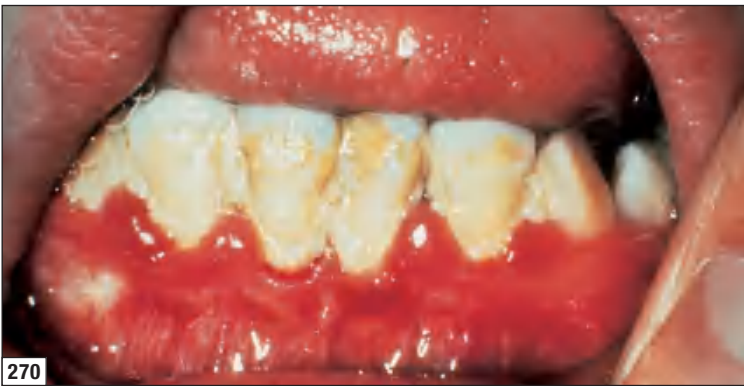INFLAMMATORY GINGIVAL AND PERIODONTAL DISEASE

Most acquired gingival and periodontal disease is inflammatory and arises as a reaction to dental bacterial plaque. Plaque is a complex biofilm that forms on teeth mainly, particularly between them, along the gingival margin and in fissures and pits, adhering by a variety of mechanisms (Fig. 269). If plaque is not regularly removed the flora evolves, an inflammatory reaction arises in the adjacent gingival tissues, and plaque may calcify, forming calculus (tartar) both above the gumline (supragingival calculus) and beneath (subgingival calculus). In extreme examples of poor oral hygiene, the teeth and gingivae are covered with a soft white



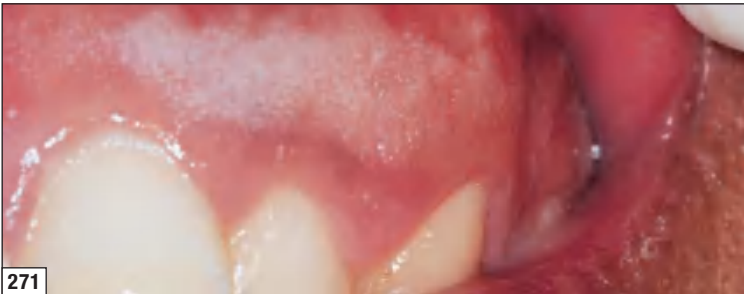269

Figure 269. Plaque identified around the gingival aspects of the teeth by using a disclosing solution containing vegetable dye.



270

Figure 270. Materia alba covering the mandibular anterior teeth with associated gingivitis.



271

Figure 271. Materia alba of the maxillary-attached gingiva aggravated by severe lip incompetence and chronic mouthbreathing are observed in this adolescent with neuromuscular dysfunction. The filmy nonadherent creamy white plaques were incorrectly managed with an antifungal suspension for 1 year with no resolution.

cheesy deposit of debris (materia alba; Figs 270, 271) from food, effete epithelial cells and dental plaque. Calculus deposits may be extensive, especially in sites close to salivary duct orifices (e.g. lingual to the lower incisors and buccal to upper molars; Fig. 272).

Calculus cannot be removed by toothbrushing, and may be associated with periodontal disease. Severely handicapped children are the most frequently seen with this problem: gingivitis usually follows.

Management

Toothbrushing and flossing

Plaque is best removed mechanically, but even after thorough toothbrushing, plaque often remains between the teeth unless they are flossed. Plaque is not especially obvious clinically, although teeth covered with plaque lack the lustre of clean teeth. Various dyes can be used to disclose the plaque and reinforce the effectiveness of oral hygiene measures.

Toothbrushing and flossing are the most effective way of removing plaque, but only remove plaque from smooth dental surfaces and not from deep pits and fissures. Electric toothbrushes are useful for people with impaired manual dexterity.

Antiplaque dentifrices

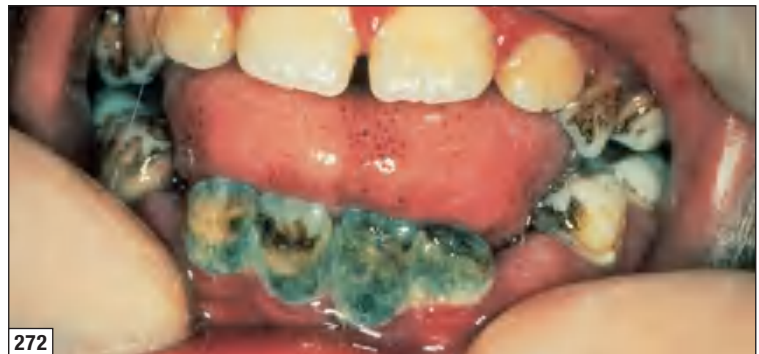Toothpastes containing triclosan or chlorhexidine have antiplaque activity and can be protective against gingivitis and periodontitis without adverse reactions.

Antiplaque mouthwashes

Mouthwashes are subject to highly competitive advertising, but although legal constraints ensure that claims are never untrue, the impression gained may be optimistic; many have only a transient antiseptic activity, and some can be harmful, causing mucosal reactions. Most effective antiplaque mouthwashes have prolonged retention on oral surfaces by adsorption, maintained activity once adsorbed, then slowly desorb, with continued activity. Chlorhexidine helps control plaque and periodontal disease, but binds tannins and thereby can cause dental staining if a child drinks tea. This can be cleaned off by dental professionals. Triclosan has antiplaque effect and does not stain teeth. Products that contain essential oils and alcohol (e.g. Listerine) may also reduce plaque.

Calculus control

Calculus can be prevented by regular thorough plaque removal. Products containing phosphates and phosphonates may help prevent calculus, but some have produced adverse reactions. Calculus cannot be removed by toothbrushing or safely by chemicals; only professional scaling will remove adherent calculus.



272

Figure 272. Calculus covering the mandibular incisors in a 10-year-old child. Calculus is covered by plaque and attracts appreciable extrinsic stain.

COMMON COMPLAINTS

Gingival bleeding

Bleeding from the gingival margins is common and:

- Is usually a consequence of gingivitis, including eruption gingivitis.
- May be a sign of platelet or vascular disorders and is common in leukemia and complications of HIV infection (Table 8).

Gingival lumps

Pyogenic granuloma may produce a friable gingival enlargement, usually as a consequence of chronic irritation. During hormonal changes, including puberty (and pregnancy), this may cause a localized or generalized swelling of the gingival papillae, which may bleed or ulcerate (Table 9). Usually large lesions require surgical removal.

Fibroepithelial polyp (irritation fibroma, fibrous epulis) is a pink firm enlargement that appears to be purely reparative in nature and often represents the mature stage of a pyogenic granuloma. It may need to be removed.

Malignant causes of gingival enlargement are rare in children, but include:

- sarcomas (e.g. fibrosarcoma, rhabdomyosaroma)
- carcinomas, usually metastatic
- Kaposi's sarcoma (rare)
- lymphoma, leukemia
- Langerhans cell histiocytosis.

Gingival pigmentation

Gingival pigmentation is usually seen in certain races (e.g. people of color) or caused by:

- embedded dental amalgam or lead from pencil
- smoker's melanosis
- Addison's disease
- Kaposi's sarcoma (rare)
- drugs, such as minocycline
- melanotic macule
- melanocytic nevus
- melanoma (rare)
- deliberate tattoo placement.

Gingival red lesions

The most common cause of gingival redness is gingivitis. In this, the erythema is usually restricted to the gingival margins and interdental papillae. Intense erythema may be seen in persons with rapidly progressive gingivitis and periodontitis, such as in some immune defects. Red lesions may also represent:

- traumatic erosions
- reactive gingival lesions such as pyogenic granuloma, peripheral giant cell granuloma, ulcerated peripheral ossifying fibroma
- eruption cyst/hematoma
- desquamative gingivitis
- contact (allergic) gingivitis
- hemangiomas
- Wegener's granulomatosis (rare)
- neoplasms (rare)

Gingival swelling

Widespread gingival swelling can be a feature of chronic gingivitis and may be caused by drugs, hormonal changes, and systemic diseases (see Table 9).

Table 8. Causes of gingival bleeding in childhood

Local causes

- Eruption gingivitis
- Acute/chronic gingivitis
- Chronic periodontitis
- Foreign body entrapment
- Acute necrotizing ulcerative gingivitis
- Hemangioma
- Reactive hyperplasias, such as pyogenic granuloma
- Facial injury

Systemic causes

- Hormonal changes, such as pregnancy, puberty
- Any thrombocytopathy
- Diabetes mellitus (poorly controlled)
- Anemia
- Leukemia
- HIV-associated periodontal disease (linear gingival erythema, necrotizing ulcerative gingivitis/periodontitis)
- Scurvy
- Clotting defects
- Drugs (e.g. anticoagulants)

Gingival ulcers

Gingival ulcers are often of infective etiology. Other causes of ulcers include:

- self-injury, in psychologically disturbed or mentally challenged patients
- malignant neoplasms (rare in children)
- drugs (such as cytotoxic agents)
- systemic disease – hematological, mucocutaneous, gastrointestinal.

Gingival white lesions

Most white lesions are caused by debris or are innocuous keratoses caused by friction, but causes include:

- infections (e.g. candidosis, papillomas)
- burns (e.g. from aspirin or mouthwashes) – the mouth can also be the site of habitual drug (e.g. cocaine use)
- smokeless tobacco keratosis
- scars (cicatrix)
- dermatoses (usually lichen planus – uncommon in children)
- syndrome-related leukoplakias/leukodermatoses
- other conditions.

Halitosis (fedor oris or oral malodor)

Malodor predominantly originates from the mouth. Gram-negative anaerobic microflora is primarily responsible for odor formation in the mouth, in particular, *Fusobacterium nucleatum*, *Treponema denticola*, *Prevotella intermedia*, *Porphyromonas gingivalis*, *Bacteroides forsythus*, *Eubacterium* spp. and others. These plaque organisms cause putrefaction, in particular, proteolysis of proteins to peptides, to amino acids, and thence to substrates possessing free thiol groups, such as cysteine and reduced glutathione give rise to volatile sulfide compounds (VSC). These include:

- hydrogen sulfide
- methylmercaptan

Table 9. Systemic causes of gingival enlargement**Generalised causes****Congenital**

Hereditary gingival fibromatosis and related disorders
 Mucopolysaccharidoses
 Fucosidosis
 Aspartylglycosaminuria
 Leprechaunism (Donohue syndrome)
 Pfeiffer's syndrome
 Infantile systemic hyalinosis
 Lipoid proteinosis
 Ligneous conjunctivitis
 Amyloidaceous ulcerated gingival hyperplasia (plasminogen deficiency)

Acquired

Prepuberty/pregnancy gingivitis
 Plasma cell gingivitis
 Infections – primary herpetic gingivostomatitis
 Hematological – acute myeloid leukemia, preleukemic leukemia(s), aplastic anemia, vitamin C deficiency (scurvy)
 Drugs – phenytoin, ciclosporin, calcium channel blockers, vigabatrin
 Deposits – mucocutaneous amyloidosis
 Chronic granulomatous disorders – sarcoidosis, Crohn's disease, orofacial granulomatosis

Local causes**Congenital**

Retrocuspid papilla
 Neuroectodermal tumor of infancy
 Melanocytic nevus
 Gingival cysts of the newborn
 Hemangioma
 Fabry syndrome (angiokeratoma corporis diffusum universale)
 Cowden syndrome
 Tuberous sclerosis
 Sturge–Weber syndrome
 Congenital epulis of newborn
 Neonatal alveolar lymphangioma
 Gingival hamartoma/choristoma/teratoma
 Gingival hyperplasia associated with segmental odontomaxillary dysplasia

Acquired

Incisive papilla cyst
 Infections – Heck's disease, papillomas, condylomas, verrucae, tuberculosis, mycoses
 Lymphomas
 Langerhans cell histiocytosis
 Other primary and secondary neoplasms (e.g. papillomas)
 Wegener's granulomatosis
 Hormonal tumor (pregnancy epulis)
 Fibroepithelial epulis
 Giant cell granuloma (alone or in association with secondary or primary hyperparathyroidism)
 Peripheral ossifying fibroma/odontogenic fibroma
 Sarcoidosis
 Crohn's disease
 Orofacial granulomatosis
 Inflammatory myofibroblastic tumor (inflammatory pseudotumor)

- dimethyl sulfide
- dimethyl disulfide

Identified responsible sulfides originate mainly from the tongue coating, gingival crevice and periodontal pockets. Mouthbreathing and xerostomia aggravate this condition.

Individuals who refrain from oral hygiene soon develop malodor, but this is worse if there is any form of ulceration, xerostomia or aerodigestive tract sepsis including that caused by:

- gingivitis
- periodontitis
- dental abscess
- dry socket (alveolar osteitis)
- rhinitis/sinusitis/tonsillitis
- plugged tonsillar crypts (Fig. 273)

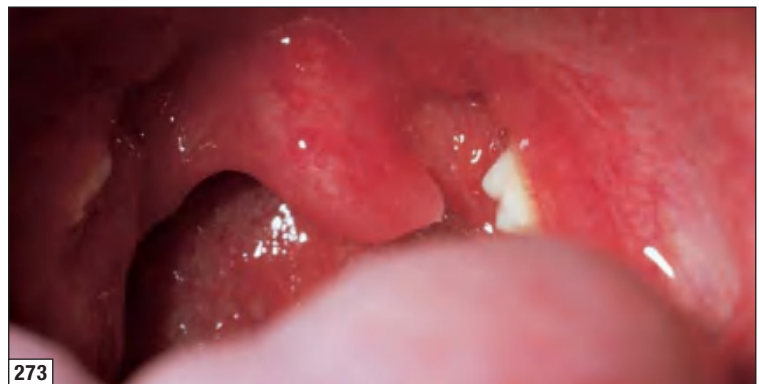

Figure 273. Bilateral plugged tonsillar crypts were a source of irritation and halitosis in this young child.

- nasal foreign bodies (Figs 274, 275)
- tumors.

Many foods and drinks can cause malodor, which is especially obvious with garlic, onions, curries, durian etc. Solvent abuse, tobacco use and drugs including alcohol, may also be implicated. Rare causes include:

- diabetic ketoacidosis
- renal or hepatic dysfunction
- psychiatric disease, as in delusional halitosis or as a feature in schizophrenia.

Diagnosis

Diagnosis is clinical, supported by imaging.

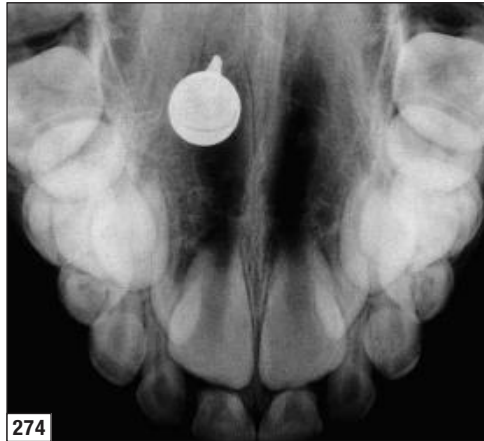
Management

Management requires establishing the presence of true halitosis and assessing its severity with a portable sulfide monitor (halimeter). Dietary, infective and systemic causes must be excluded. A full assessment of oral health is always indicated. The most reliably effective management is then:

- improving oral hygiene, including routine brushing or scraping of the dorsal tongue
- chewing sugar-free gum
- oral deodorants, especially those containing essential oils and zinc compounds
- chlorhexidine oral rinse
- metronidazole in severe or recalcitrant cases

Periodontitis of early onset and/or rapidly advancing

If periodontitis is seen in children or young adults, or is rapidly advancing, systemic factors should be excluded (Table 10).



Figures 274, 275.

Foreign body from the nasal cavity. Children not infrequently put objects into their nose and ears as well as their mouth.

ACUTE NECROTIZING ULCERATIVE GINGIVITIS (VINCENT'S DISEASE)

Chiefly affecting young adults, acute ulcerative gingivitis (acute necrotizing ulcerative gingivitis, AUG, ANG, ANUG) is associated with proliferation of spirochetes, *Borrelia vincentii*, fusiform bacilli and *Prevotella intermedia* and other anaerobes. Predisposing factors are respiratory infections, viral infections, including infectious mononucleosis and rubeola, poor oral hygiene, smoking and immune defects. Pericoronitis is thought to represent a localized form of the disease. In young children, an underlying neutropenia, leukemia or progression of HIV infection may be important causes.

Painful ulceration of the interdental papillae is the typical feature of this condition, creating a punched-out appearance to the gingival architecture. Painful gingival papillary ulceration occasionally spreads from the papillae to the gingival margins (see cancrum oris, p. 113). There is often accompanying sialorrhoea, halitosis and a pronounced tendency for gingival bleeding.

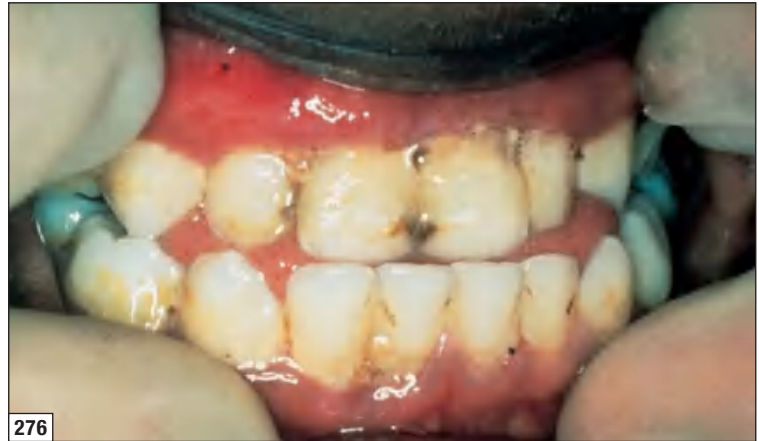Diagnosis

Diagnosis is clinical, supported by microbiology in some instances.

Management

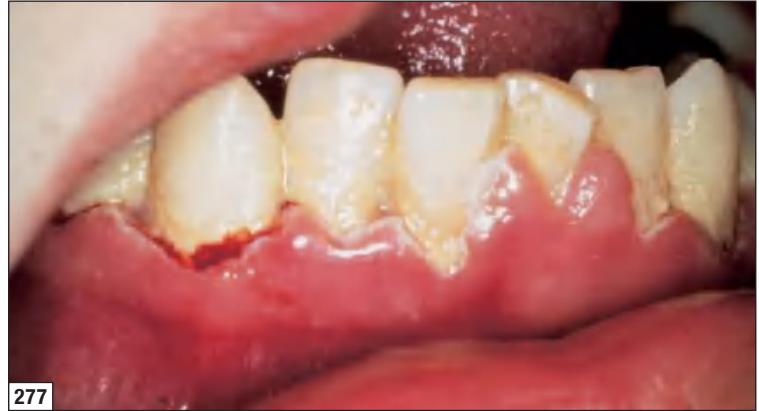Debridement and antimicrobials are indicated, especially in immunocompromised patients.

Local debridement is key to managing this condition in addition to improved nutrition and sleep habits. Oral hygiene must be improved. Topical antimicrobial mouthrinses may promote healing after debridement. Oral analgesics and systemic antibiotics are indicated when an elevated temperature and lymphadenopathy are present. Treatment options are given in Table 11.



276

Figure 276. Acute necrotizing ulcerative gingivitis affecting the maxillary and mandibular anterior regions in a 6-year-old child. Oral hygiene and nutrient intake were poor.



277

Figure 277. Acute necrotizing ulcerative gingivitis showing papillary and marginal gingival ulceration.

Table 11. Treatment options for acute necrotizing ulcerative gingivitis***Topical antimicrobial oral rinse**

Drugs	Peridex, PerioGard, Chlorohex 1200, generics (chlorhexidine gluconate 0.12%) or Corsodyl or Chlorohex 2000 (chlorhexidine gluconate 0.2%) oral rinse
Dispense	480 mL
Directions for use	Rinse with 15 mL for 30 seconds and expectorate. Use at least twice daily, after breakfast and before bed.
Pediatric significance	Applying the medication with a cotton tipped applicator and placing it on the ulcer helps to minimize the reversible tooth-staining properties of chlorhexidine gluconate oral rinse. Tea and coffee increase this tooth-staining effect. Both Peridex and PerioGard contain 11.6% alcohol, and therefore parental supervision is important to prevent accidental ingestion. The oral rinse without alcohol is formulated at a 0.2% concentration to have a comparable antimicrobial effect. Most flavoring agents as well as the foaming agents in toothpaste will destroy the antimicrobial effect of chlorhexidine. All foamy residue from toothbrushing should be rinsed away before using this agent. A 30-minute period should elapse between toothpaste use and chlorhexidine rinse. Occasional minor irritation and mucosal sloughing, and parotid swelling have been noted. Although commonly used, the clinical effectiveness and safety have not been established in people under the age of 18 years.

Systemic antibiotics for severe infections

Drug	Penicillin V or VK 250, 500 mg tablets
Dispense	28–40 tablets
Directions for use	Take 1 tablet four times daily for 7–10 days.
Pediatric significance	The pediatric dosage is 25 to 50 mg/kg/day for children less than 12 years old and the maximum dose for this age group is 3 g/day. For children under 1 year this amounts to about 62.5mg four times daily; for those aged 1–5 years, 125mg four times daily and for those aged 6–12 years, 250 mg four times daily. Oral suspensions are available in the dosage forms of 125 mg/5 mL and 250 mg/5 mL and are sweetened with sugar. A systemic antibiotic should be prescribed only when acute systemic manifestations are present.

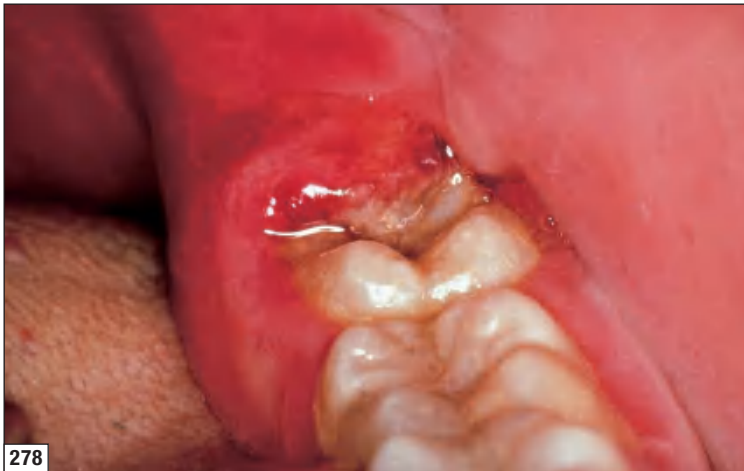Drug	Metronidazole (Flagyl) 250, 500 mg tablets
Dispense	21–30 tablets
Directions for use	Take 1 tab three times daily for 7–10 days.
Pediatric significance	The pediatric dosage for anaerobic infections is 15–35 mg/kg/day. An oral suspension can be compounded by the pharmacist in a dosage form of 250 mg/5 mL. Important drug interactions include ethanol or medications containing ethanol, and phenytoin. A combination of metronidazole and penicillin V is relatively inexpensive and provides good coverage of oral pathogens against Gram-positive aerobes and Gram-positive and Gram-negative anaerobes. Because of the broad spectrum of this combination, these antibiotics may be indicated for some cases of facial cellulitis.

Drug	Clindamycin (USA: Cleocin; UK: Dalacin C) 150, 300 mg tablets
Dispense	21–30 tablets
Directions for use	1 tablet every 8 hours for 7–10 days.
Pediatric significance	Clindamycin is an alternative for penicillin-allergic children who cannot tolerate metronidazole. The pediatric dosage is 10–30 mg/kg/day. The oral solution is available in the dosage form of 75 mg/5mL and is sweetened with sucrose. This antibiotic provides good coverage of oral pathogens against Gram-positive aerobes and Gram-positive and Gram-negative anaerobes. It also has good bone penetration and is effective for deep soft tissue and staphylococcal infections. In severe infections it is recommended that children be given no less than 300 mg/day regardless of body weight. Liver and renal function should be monitored in neonates and infants.

*Improving the oral hygiene is the most important measure.

ACUTE PERICORONITIS

Inflammation of the operculum over an erupting or impacted tooth is common (Figs 278, 279). The gingiva surrounding the lower third molar is the site most commonly affected, but it may be associated with any primary or permanent molar. Patients complain of pain, trismus, swelling and halitosis. There may be fever and regional lymphadenitis associated with a swollen, red and often ulcerated operculum. With multiple recurrences, paradental cyst (buccal bifurcation cyst) may develop, resulting in marked furcal bone loss and marked buccal expansion of the jaws, especially the mandible.



278

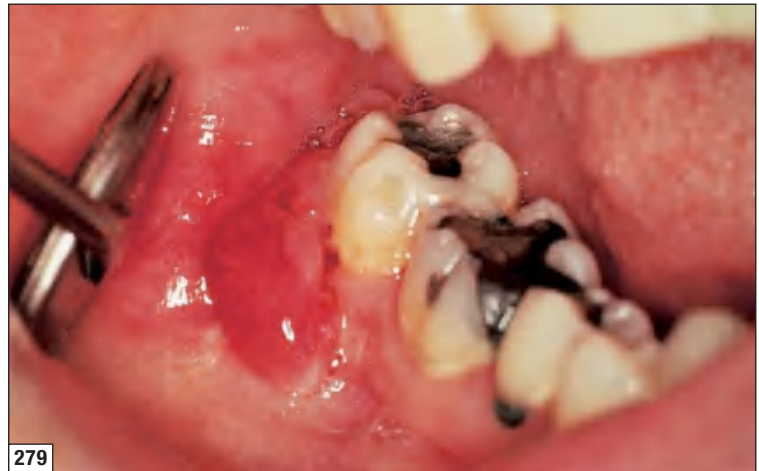Figure 278. Acute pericoronitis associated with a partially erupted mandibular permanent molar.

Diagnosis

Diagnosis is clinical, supported by imaging and microbiology in some instances.

Management

Oral hygiene must be improved. Debridement and antimicrobials (as shown in table 11) are indicated, especially in immunocompromised patients or those who have systemic manifestations such as fever. If the offending tooth is a third molar then the tooth may need extraction after the acute condition has resolved.



279

Figure 279. Migratory abscess of the buccal sulcus – a rare sequela of acute pericoronitis.

CANCRUM ORIS (NOMA)

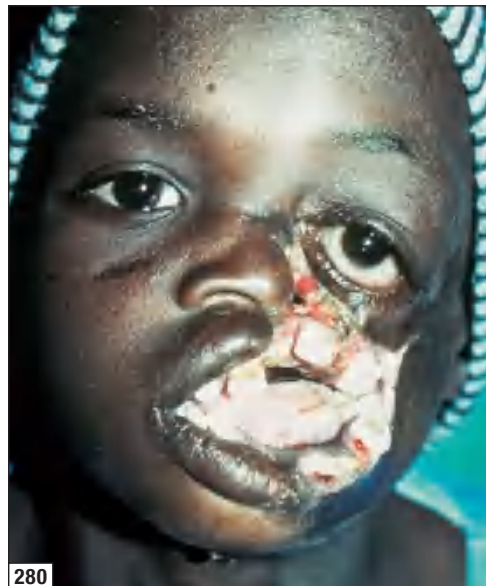Although usually a trivial illness in healthy children, ANUG in malnourished, debilitated or severely immunocompromised patients may extend onto the oral mucosa and skin with gangrenous necrosis (cancrum oris, noma, Fig. 280). Predisposing infectious diseases include measles, chickenpox, malaria, tuberculosis and HIV infection. Anaerobes, particularly bacteroides species, have been implicated, and the condition is especially seen in malnourished patients from the developing world or war zones. Recently, Herpesviridae, especially cytomegalovirus, have been associated with these lesions. Gangrenous stomatitis has also been reported in HIV disease.

Diagnosis

Diagnosis is clinical, supported by microbiology in some instances.

Management

Oral hygiene must be improved. Debridement and antimicrobials are indicated (see Table 11). Reconstructive surgery is needed in severe cases.



280

Figure 280. Cancrum oris in an African child.

CHRONIC HYPERPLASTIC GINGIVITIS

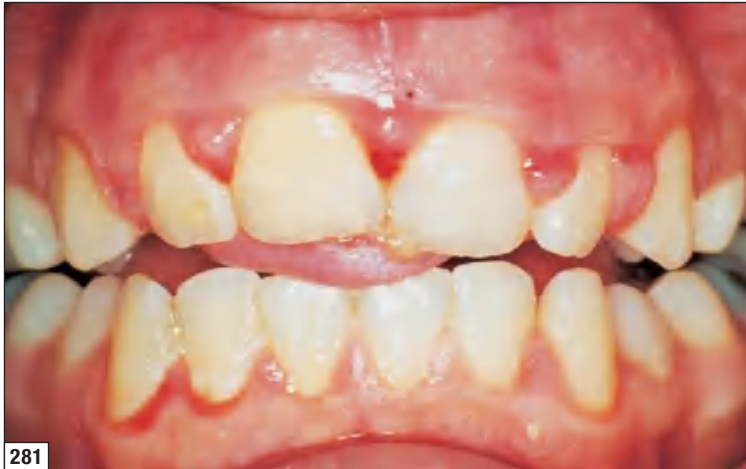Gingivitis may be hyperplastic (Figs 281–283), especially where there is mechanical irritation, such as orthodontic appliances, or mouthbreathing, or sometimes with the use of some drugs (see Table 9 and p. 116).

Diagnosis

Diagnosis is clinical.

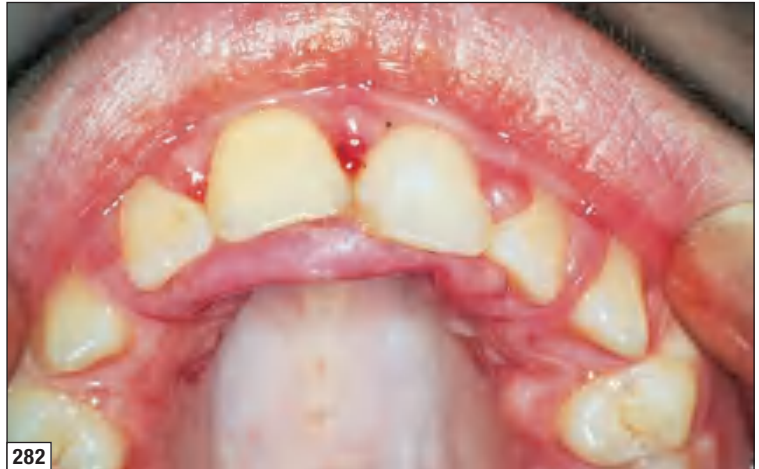Management

Oral hygiene must be improved. Periodontal surgery may be indicated, especially in patients who do not respond to changes in regimen.



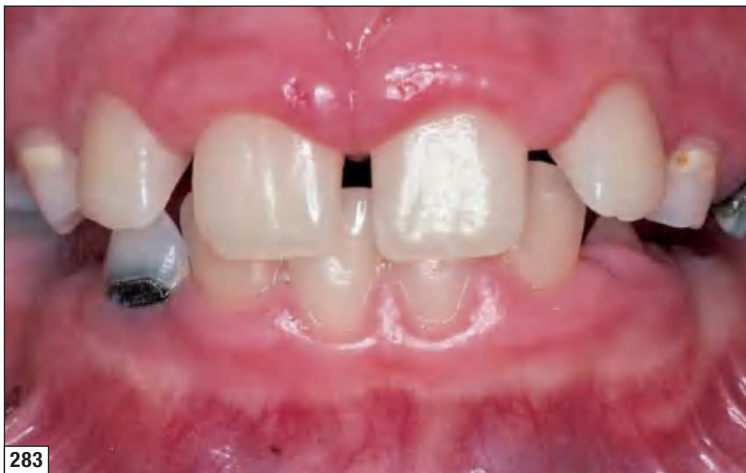281

Figures 281. Chronic hyperplastic gingivitis affecting the maxillary labial and palatal gingivae after orthodontic removable appliance treatment to retract teeth in the upper labial segment.



282

Figure 282. Chronic hyperplastic gingivitis affecting the maxillary labial and palatal gingivae after orthodontic removable appliance treatment to retract teeth in the upper labial segment.



283

Figure 283. Chronic hyperplastic gingivitis in a mouthbreather.

CHRONIC MARGINAL GINGIVITIS

Gingivitis occurs in 50% of children between the ages of 4–5 years and increases to about 100% during puberty. Most of the adult population have a degree of gingivitis, which commences in childhood.

Chronic marginal gingivitis (Figs 284, 285) is caused by the accumulation of plaque on the tooth close to the gingiva. Inflammation of the margins of the gingiva is painless and often the only features are gingival bleeding on eating or brushing, and possibly some halitosis. There may be gingival erythema, swelling and bleeding on examination. If left uncorrected, gingivitis may slowly and painlessly progress to periodontitis with detachment of the gingiva, periodontal pocket formation, alveolar bone

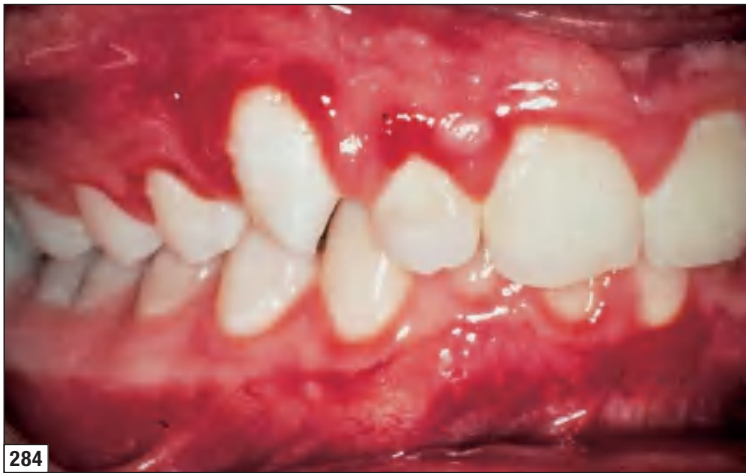loss and ultimately tooth loss. However, although advanced periodontitis is rare in children, localized attachment loss is found in about 20% of the adolescent population. The features are those of marginal gingivitis, but with destruction of alveolar bone support. There is deep periodontal pocket formation and associated tooth mobility and migration.

Diagnosis

Diagnosis is clinical.

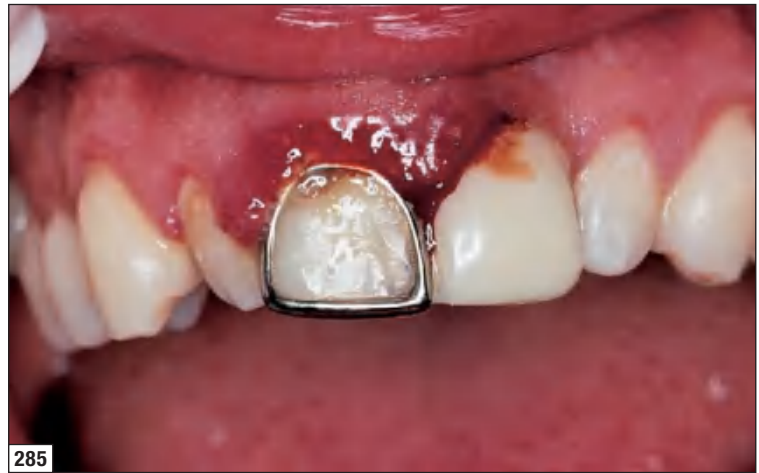Management

Oral hygiene must be improved.



284

Figure 284. Chronic marginal gingivitis, especially of the maxillary gingiva. Oral hygiene is more efficient in the posterior parts of the mouth.



285

Figure 285. Marginal gingivitis closely related to a restoration (a basket crown – now outdated).

DRUG-INDUCED GINGIVAL OVERGROWTH (HYPERPLASIA)

The anticonvulsant phenytoin is the drug that classically produces gingival overgrowth or hyperplasia (Figs 286, 287). Poor oral hygiene exacerbates the hyperplasia, which appears interdentally 2–3 months after treatment is started. The gingival papillae enlarge to a variable extent, with relatively little tendency to bleed, and may even cover the tooth crowns.

Ciclosporin (cyclosporine) is a commonly used immunosuppressive drug that can cause gingival hyperplasia (Fig. 288) closely resembling that induced by phenytoin. It is seen mainly anteriorly and labially and is exacerbated by poor oral hygiene and concurrent administration of nifedipine or other calcium channel blockers.

Calcium channel blockers, such as nifedipine, are occasionally used as antihypertensives in children and can produce gingival hyperplasia, similar to that induced by phenytoin. Some other drugs have similar effects.

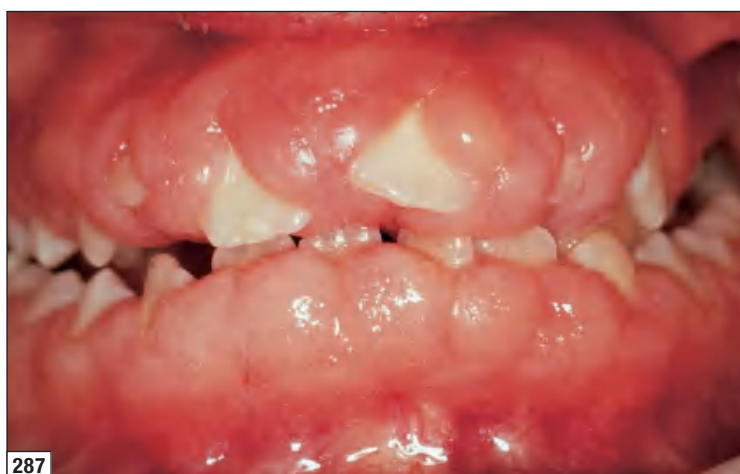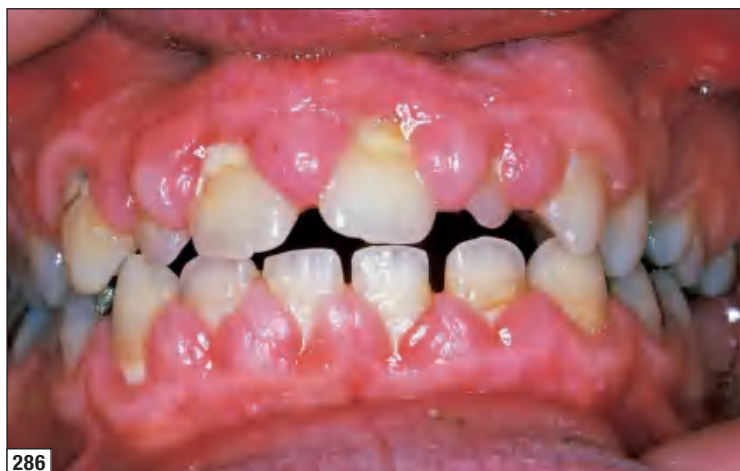All types of drug-induced gingival hyperplasia can also be associated with hirsutism.

Diagnosis

Diagnosis is clinical.

Management

Oral hygiene must be improved. Gingival resection may be indicated, in patients who cannot change medication or in those in whom the condition does not resolve on drug modification.



Figures 286, 287. Phenytoin-induced gingival hyperplasia

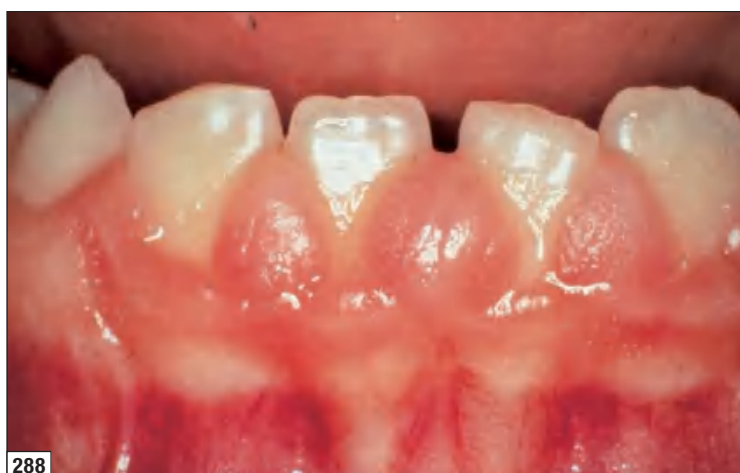

Figure 288. Ciclosporin-induced gingival hyperplasia in a 9-year-old child. The drug had been taken regularly for 2 years after a heart transplant.

PYOGENIC GRANULOMA

Pyogenic granulomas (Figs 289, 290) are an exaggerated response to minor trauma that commonly occurs on the gingiva, lip or tongue. They tend to be soft, fleshy, irregular-surfaced vascular lesions that bleed readily. They originate frequently where there is a slight malocclusion leading to plaque accumulation. Most pyogenic granulomas are seen in the maxilla anteriorly.

Diagnosis

Diagnosis is clinical, supported by excision biopsy.

Management

Oral hygiene must be improved. Excision is usually indicated, along with removal of contributing local irritant.

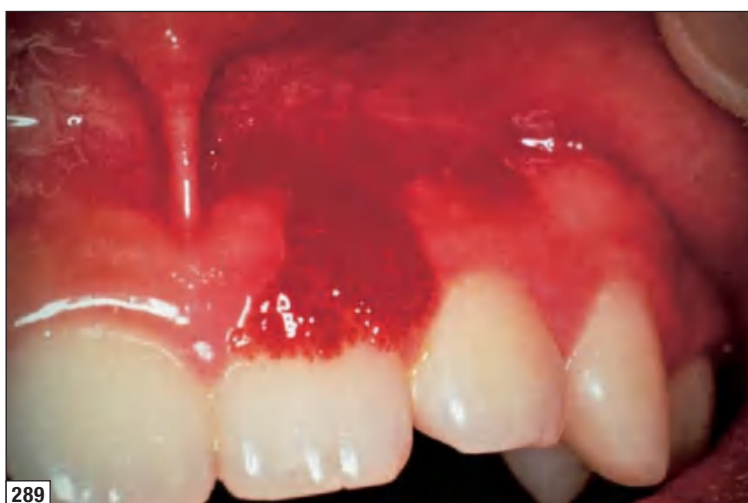

Figure 289. Pyogenic granuloma arising from the anterior maxillary gingiva in a patient with very poor oral hygiene.

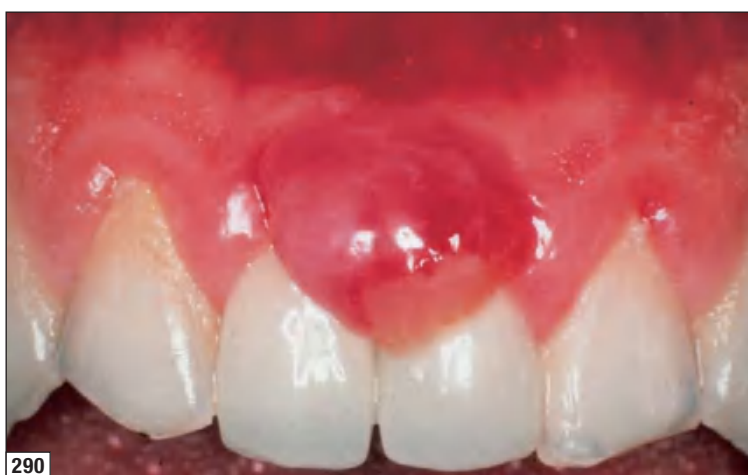

Figure 290. Pyogenic granuloma.

FIBROEPITHELIAL POLYPS

Fibroepithelial polyps (fibrous epulis, irritation fibroma; Figs 291–294) are common in the mouth, but are seen mainly in adults. They appear to be purely reparative in nature.

The variable inflammatory changes account for the different clinical presentations of fibrous nodules from red, shiny and soft enlargements to those that are pale, stippled and firm. Commonly, they are round, pedunculated swellings arising from the marginal or papillary gingiva (epulides), and sometimes adjacent to sites of irritation (e.g. a carious lesion). They are usually painless. They may reach quite a large size, but the prognosis is good.

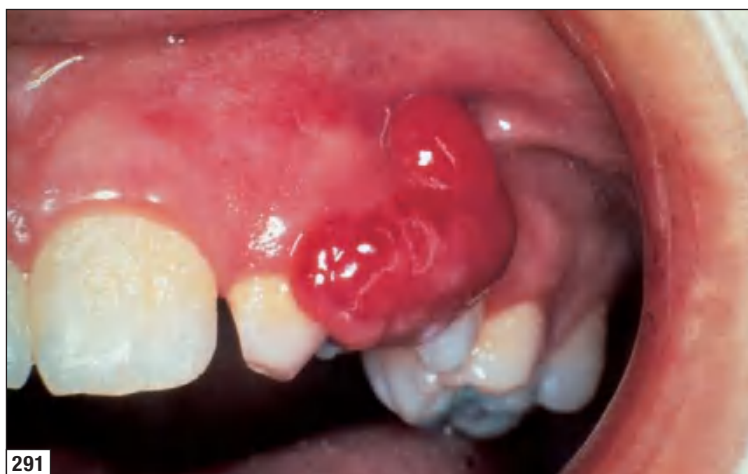The true fibroma, a benign neoplasm of fibroblastic origin, is rare in the oral cavity and many lesions in the past called fibromas were probably fibroepithelial polyps. The peripheral ossifying fibroma (Fig. 293) and giant cell fibroma (Fig. 294) are reactive hyperplastic lesions that have a similar clinical appearance as the fibroepithelial polyp.

Diagnosis

Diagnosis is clinical, supported by excisional biopsy.

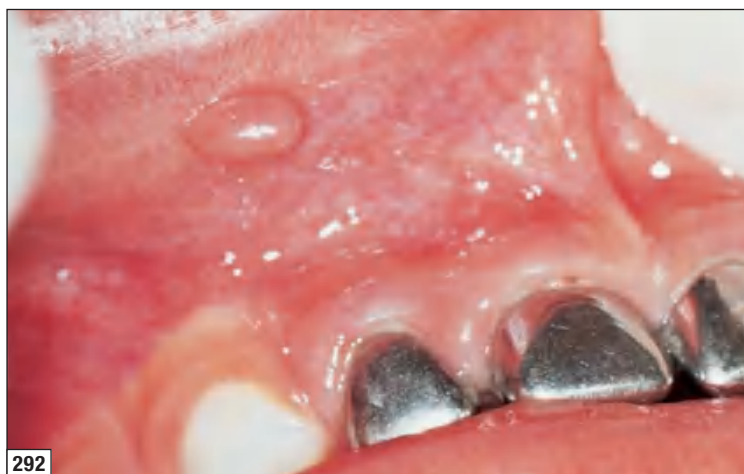Management

Excision is usually indicated.



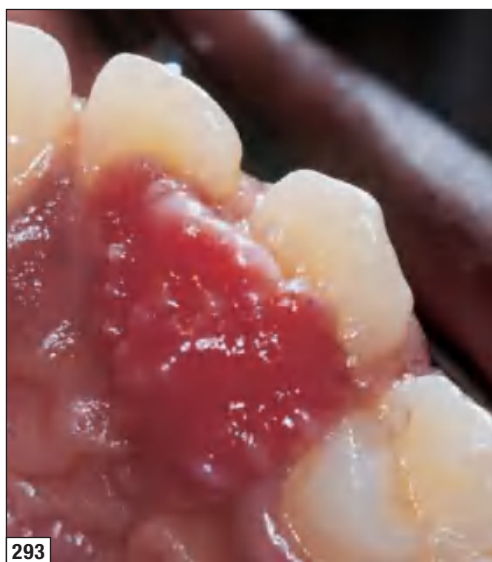291

Figure 291. A large vascular fibroepithelial polyp arising from the interdental area between a maxillary primary canine and primary first molar. The first molar had extensive mesial caries.



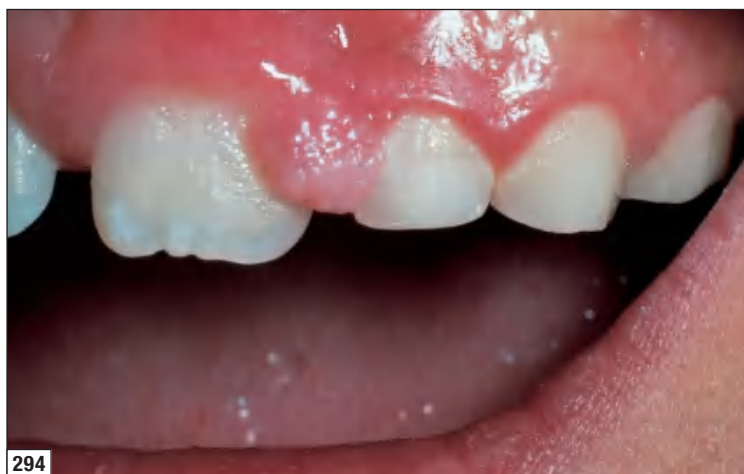292

Figure 292. Irritation fibroma of the upper labial mucosa in a young child. The cause of the reactive lesion was repeated trauma from a grossly carious primary incisor, which had been restored with a stainless steel crown.



293

Figure 293. Peripheral ossifying fibroma of the anterior palatal gingiva with a red bosselated surface.



294

Figure 294. Giant cell fibroma of the anterior attached gingiva. This reactive soft tissue nodule has a pale, heavily stippled surface, which can resemble verruca vulgaris.

GIANT CELL GRANULOMA (GIANT CELL EPULIS)

Giant cell granuloma (Fig. 295) is a benign, non-neoplastic gingival enlargement of proliferating fibroblasts in a highly vascular stroma containing many multinucleate giant cells and is most common in children in an area that has borne primary teeth.

The giant-cell epulis characteristically arises on the attached gingiva, adjacent to primary or permanent teeth, usually anterior to the first permanent molar. Classically, the most notable feature is the deep-red or purple color, although older lesions tend to be paler. Superficial erosion of the adjacent alveolar bone and displacement of teeth are common findings in children.

Giant cell granulomas are occasionally a feature of hyperparathyroidism.

Diagnosis

Diagnosis is clinical, supported by imaging and excisional biopsy. Recurrent or multifocal lesions may require biochemistry studies to exclude hyperparathyroidism.

Management

Oral hygiene must be improved. Excision is usually indicated.

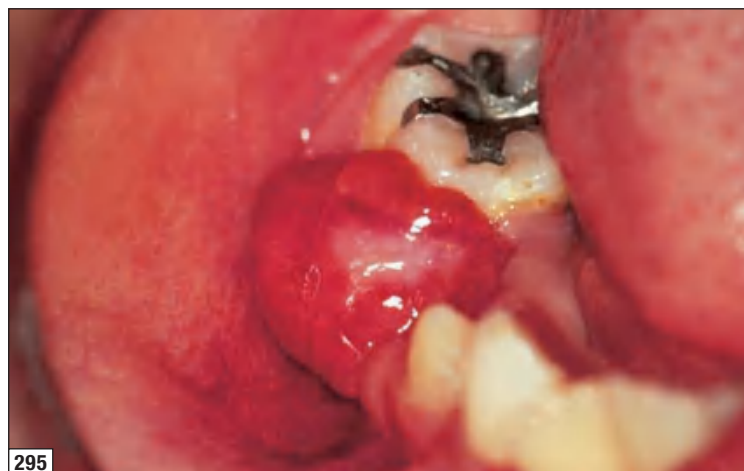

Figure 295. Giant cell granuloma.

LATERAL PERIODONTAL ABSCESS (PERIODONTAL ABSCESS)

Lateral periodontal abscesses (Fig. 296) are seen almost exclusively in patients with chronic periodontitis, but may follow impaction of a foreign body, or can be related to a lateral root canal on a nonvital tooth. Mobile primary teeth associated with delayed exfoliation may be another cause in children. Debris and purulent exudate (pus) cannot escape easily from the pocket and therefore an abscess with pain and swelling results.

Lateral periodontal abscesses usually discharge either through the pocket or buccally, but more coronally than a periapical abscess.

Diagnosis

Diagnosis is clinical, supported by imaging and microbiology in some instances.

Management

Oral hygiene must be improved. Curettage and antimicrobials are indicated, especially in immunocompromised patients or those with systemic manifestations such as fever. Extraction of the affected primary tooth is usually indicated.

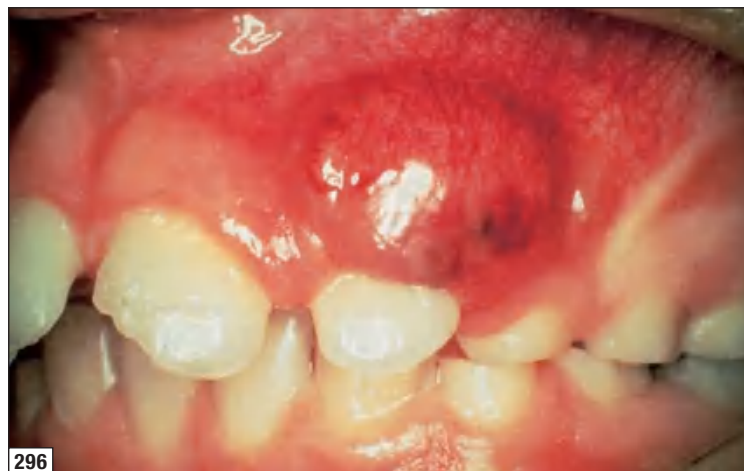

Figure 296. Lateral periodontal abscess.

EARLY-ONSET PERIODONTITIS

Early-onset periodontitis is rare in children (Fig. 297) and includes both prepubertal and juvenile forms of the disease. Prepubertal periodontitis is characterized by localized loss of attachment in the primary dentition, especially the molar regions. It is usually accompanied by mild to moderate inflammation and evidence of plaque accumulation. In some instances, periodontitis develops despite good control of plaque and is typically related to an immune defect. A range of systemic causes may underlie this form of periodontitis, notably poorly controlled diabetes mellitus, white cell dyscrasias including neutrophil defects and neutropenias, and other immune defects including HIV AIDS, Papillon-Lefèvre syndrome and leukocyte adhesion deficiency.

Localized juvenile periodontitis is characterized by localized periodontal destruction, classically in the permanent incisor and first molar regions in adolescents or young adults in the absence of poor oral hygiene or obvious (gross) systemic disease. At least some cases appear to be inherited as an autosomal trait, although a neutrophil chemotactic defect has been found. Despite the genetic predisposition, *Actinobacillus actinomycetemcomitans* is associated with this disease.

Generalized juvenile periodontitis (periodontosis) occurs in adolescents and is seen especially in females. It may be associated with minor defects of neutrophil function and with microorganisms such as *Actinobacillus actinomycetemcomitans* and *Capnocytophaga* spp. With this disease the entire dentition is affected. In addition there are typically large amounts of plaque and calculus present and the inflammation may be severe. Similar periodontal destruction can be seen in Down syndrome, Ehlers-Danlos type VIII syndrome, and hypophosphatasia.

Diagnosis

Diagnosis is clinical, supported by imaging and microbiology and biochemistry in some instances.

Management

Oral hygiene must be improved. Topical and systemic antimicrobials are indicated after scaling and curettage.

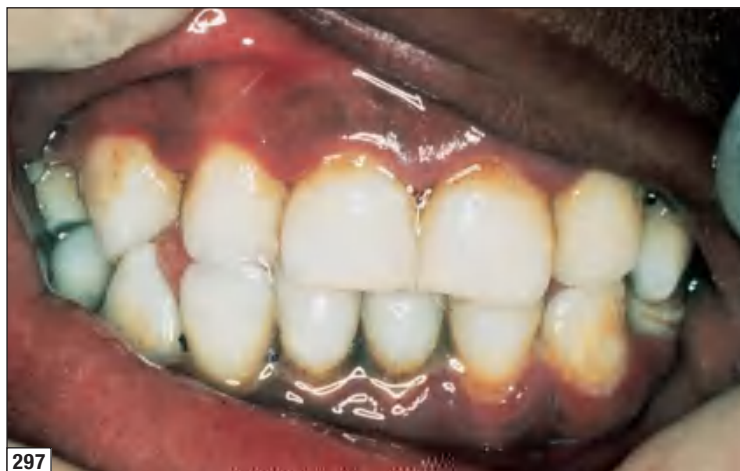

Figure 297. Periodontitis affecting the maxillary and mandibular labial segments in a 9-year-old child with poor oral hygiene and a history of previous episodes of acute necrotizing ulcerative gingivitis.

TRAUMA

Self-induced ulcers of the gingival margin (Fig. 298) are not common, but may be seen in children who have behavioral disorders. The upper and lower canine region buccally seems a typical site for damage by picking with the fingernails. This may be a form of Munchausen's syndrome—deliberate self-harm directed towards gaining operative intervention.

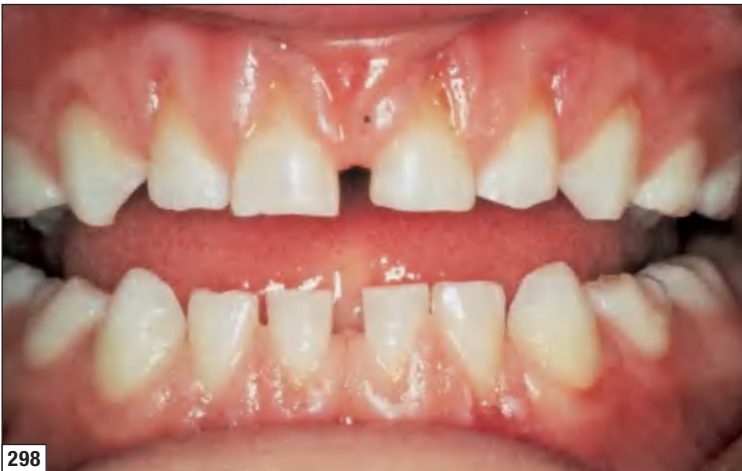Trauma can damage the periodontium, sometimes through excessive occlusal stresses and sometimes through direct damage (class II division 2 malocclusion; Figs 299–301). In this malocclusion the upper incisors can strip the periodontium labial to the lower incisors, while the upper incisor periodontium may be traumatized palatally by the lower incisors.

Diagnosis

Diagnosis is clinical.

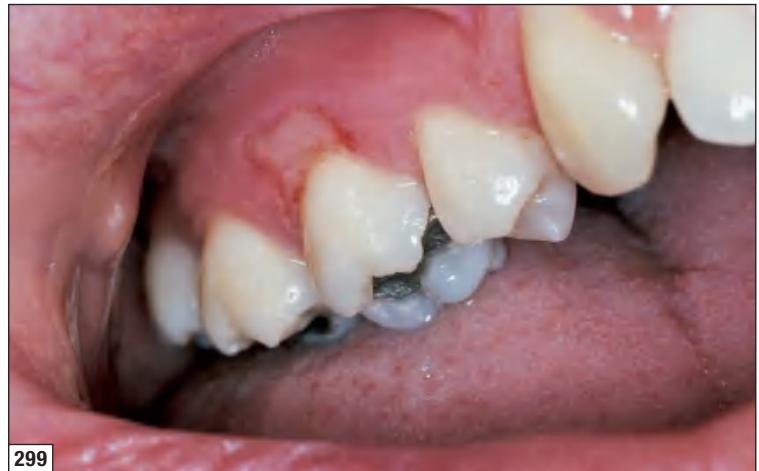Management

Behavioral intervention or psychiatric attention is required if self inflicted. Orthodontic treatment may be beneficial if the trauma is induced by malocclusion.



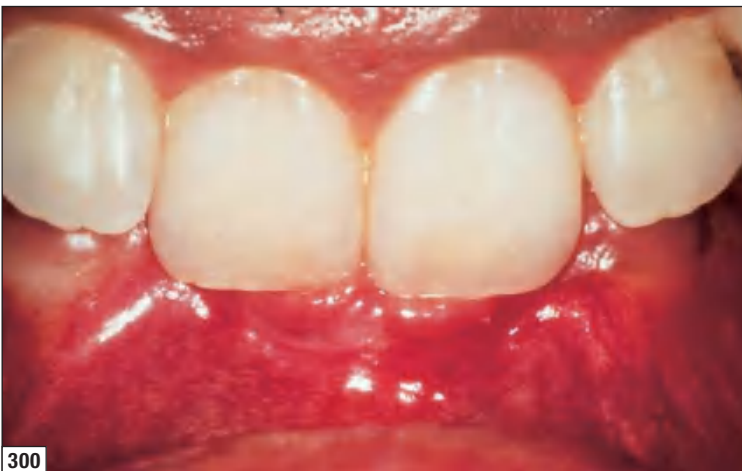298

Figure 298. Gingivitis artefacta produced by the fingernails in a 6-year-old child. The maxillary anterior gingivae are the most severely affected. There is recession of the gingival margins and the root surfaces are visible.



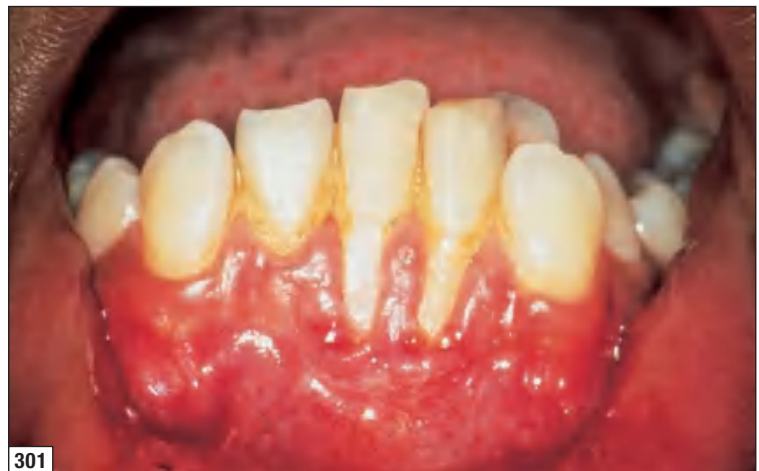299

Figure 299. Gingival self-inflicted damage.



300

Figures 300, 301. Gingival damage as a consequence of a class II division 2 malocclusion with a deep overbite.



301

6

Acquired mucosal disorders

COMMON COMPLAINTS

Lumps and swellings

Patients often notice a lump first because it becomes sore.

Pathological causes of lumps and swellings include a range of different lesions (Tables 12, 13)

Apart from the history, features that can help in reaching the diagnosis include:

- alteration in size or color
- any discharge from the lesion (clear fluid, pus, blood)
- duration
- pain or tenderness.

The relevant medical history should be fully reviewed because several systemic disorders may be associated with intraoral or facial swellings.

Inspection should include a careful note of:

- The location of the lump in relation to anatomical structures present. For example, many midline lesions tend to be developmental in origin (e.g. torus palatinus).
- Whether a lesion is bilateral – few neoplastic lumps are bilateral.
- The site, shape, size (in millimetres).
- The color of the lump. A lump pale in color may suggest underlying fibrosis or soft tissues stretched over bony enlargement; red suggests inflammation, hemangioma or giant cell granuloma. Purple suggests angioma or Kaposi's sarcoma. Any variations in color within the lump (e.g. the yellow appearance of a 'pointing' abscess) should be observed.
- The surface characteristics. Papillomas have an obvious anemone-like appearance; carcinomas and other malignant lesions and deep mycoses tend to have a nodular surface and may ulcerate.
- Abnormal blood vessels – which can suggest a neoplasm.
- Whether the swelling has an orifice or sinus, and if fluid is draining check whether it is clear, cloudy or purulent.
- Similar or relevant changes elsewhere in the oral cavity should be noted.

Palpation may then help determine whether the lump:

- contains fluid (i.e. fluctuant because of cyst fluid, mucus, pus or blood)
- is soft, firm or hard like a carcinoma (indurated)
- is painful (suggesting an inflammatory lesion)
- releases fluid (e.g. pus from an abscess)
- blanches (vascular).
- crackles (like an egg-shell being broken) as in a cyst
- overlies an underlying structure (e.g. the crown of a tooth under an eruption cyst)
- is in deeper structures (e.g. submandibular calculus).

Bimanual palpation should be used when investigating lesions in the submandibular salivary glands, floor of the mouth, cheek and occasionally the tongue.

Investigations

The nature of many lumps can only be established after further investigation. In particular:

- Any teeth adjacent to a lump in the jaw should be tested for vitality, and any caries or suspect restorations should be investigated.
- The periodontal status of any involved teeth should be determined.
- Radiographs or other imaging techniques are required whenever a lump involves the jaws, and should show the full extent of the

Table 12. Lesions that may present as lumps or swellings in the mouth

Normal	Others
Pterygoid hamulus	Angioedema
Parotid papillae	
Lingual papillae	
Unerupted teeth	
Developmental	
Hemangioma	
Lymphangioma	
Maxillary and mandibular tori	
Hereditary gingival fibromatosis	
von Recklinghausen's neurofibromatosis	
Inflammatory	
Abscess	
Pyogenic granuloma	
Crohn's disease	
Orofacial granulomatosis	
Sarcoidosis	
Wegener's granulomatosis	
Others	
Traumatic	
Epulis	
Fibroepithelial polyp	
Denture granulomata	
Cystic	
Eruption cysts	
Developmental cysts	
Cysts of infective origin	
Fibro-osseous	
Cherubism	
Fibrous dysplasia	
Paget's disease	
Hormonal	
Pregnancy epulis/gingivitis	
Puberty gingivitis	
Oral contraceptive pill gingivitis	
Drugs	
Phenytoin	
Ciclosporin (cyclosporine)	
Calcium channel blockers	
Vigabatrin	
Blood dyscrasias	
Leukemia	
Lymphoma	
Neoplasms	
Benign	
Malignant	

lesion and possibly other areas. Special radiographs (e.g. of the skull, sinuses, salivary gland function), computed tomography, magnetic resonance imaging, ultrasound or other investigations may, on occasions, be indicated.

- Photographs may be useful for future comparison.
- Blood tests may be needed if there is a suspicion of a blood dyscrasia or endocrinopathy. Special blood tests (e.g. for autoantibodies) may be indicated for suspected vesiculobullous lesions.
- Biopsy may be indicated.

Pigmented lesions

The main causes of oral pigmentation in children are given in Table 14.

Localized hyperpigmented lesions

Hemangiomas and purpura and rarely Kaposi's sarcoma give rise to localized red and purple lesions. Brown or black lesions are usually amalgam tattoos or melanotic macules, but melanocytic nevi should be excluded.

Generalized mucosal hyperpigmentation

Generalized mucosal hyperpigmentation is usually racial in origin or caused by pigmentary incontinence (e.g. in smokers) and only occasionally has a systemic cause, such as drugs (e.g. zidovudine, clofazimine, antimalarials, minocycline) or Addison's disease.

Red lesions

Most red oral lesions are inflammatory or benign vascular hamartomas, but some are neoplastic, such as hemangiopericytoma, hemangioendothelioma, vascular leiomyoma.

Table 13. Some conditions associated with multiple oral lumps

Papillomas
Condylomas
Papillary hyperplasia
Cowden's syndrome
Focal epithelial hyperplasia
Focal dermal hypoplasia
Lipoid proteinosis
Multiple endocrine neoplasia (endocrinopathy) syndrome
Drug-induced gingival swelling
Hereditary gingival fibromatosis
Crohn's disease
Orofacial granulomatosis
Sarcoidosis

Table 14. Main causes of oral pigmentation in childhood

Local causes

Amalgam or graphite tattoo
Ephelis (freckle)
Nevus
Laugier–Hunziker syndrome
Melanotic macules
Complex of myxomas, spotty pigmentation and endocrine overactivity
Malignant melanoma
Kaposi's sarcoma
Peutz–Jeghers syndrome

General causes

Racial
Drugs (e.g. antimalarials, clofazimine, minocycline, zidovudine)
Addison's disease
Albright's syndrome
Other rare causes (e.g. hemochromatosis, generalized neurofibromatosis, incontinentia pigmenti)

Ulcers

Many ulcers are of local or infectious etiology. Other causes of ulcers (Table 15) include:

- aphthae
- malignant neoplasms
- drugs
- systemic disease – hematological, mucocutaneous, gastrointestinal.

Table 15. Main causes of mouth ulcers in children

Local causes (e.g. trauma or burns)
Recurrent aphthae (and Behçet's syndrome)
Malignant neoplasms (rarely)
Ulcers associated with systemic disease
<i>Microbial disease</i>
Herpetic stomatitis
Chickenpox
Hand, foot and mouth disease
Herpangina
Infectious mononucleosis
Acute necrotizing gingivitis
HIV infection and AIDS
Rarely fungal infections, tuberculosis or syphilis
<i>Cutaneous disease (uncommon)</i>
Erosive lichen planus
Pemphigus
Pemphigoid
Erythema multiforme
Dermatitis herpetiformis
Chronic bullous disease of childhood and linear IgA disease
Epidermolysis bullosa
Other dermatoses
<i>Blood disorders</i>
Anemia
Leukemia
Neutropenia
Other white cell dyscrasias
<i>Gastrointestinal disease</i>
Celiac disease
Crohn's disease
Ulcerative colitis
Rheumatic disease
Lupus erythematosus
Behçet's syndrome
Sweet's syndrome
<i>Drugs (e.g. cytotoxics)</i>
<i>Irradiation of the oral mucosa.</i>
<i>Acrodynia</i>
Disorders of uncertain pathogenesis
Periodic fever, aphthous stomatitis, pharyngitis and cervical adenitis syndrome (PFAPA)
Eosinophilic ulcer
Necrotizing sialometaplasia
Hypereosinophilic syndrome

White lesions

White mucosal lesions were formerly called leukoplakia and often believed to be potentially malignant. The term leukoplakia is now restricted to white lesions of unknown cause. Most white lesions are innocuous keratoses caused by cheek biting or friction, but other causes are:

- infections (e.g. candidosis, papillomas and rarely hairy leukoplakia)
- dermatoses (usually lichen planus, occasionally genodermatoses)
- neoplastic disorders (e.g. leukoplakias and carcinomas – rare)
- other conditions, which must be excluded, usually by biopsy (Table 16).

Table 16. Main causes of oral white lesions in childhood

Local causes
Cheek biting
Frictional keratosis
Burns
Idiopathic keratosis
Carcinoma rarely
Systemic causes
Candidosis
Lichen planus
Lupus erythematosus
Papillomas (some)
Hairy leukoplakia (AIDS mainly)
Chronic renal failure
Inherited lesions (e.g. white sponge nevus; dyskeratosis congenita)

ACUTE CANDIDOSIS (THRUSH, CANDIDIASIS, MONILIASIS)

Candida species are common oral commensal organisms. *Candida albicans* is the most common species and can act as an opportunistic pathogen if the oral ecology is disturbed due to xerostomia or by corticosteroids or antibiotics, or if the patient is immunocompromised or anemic. Other species such as *C. krusei* are seen increasingly in immunocompromised people.

Thrush (Fig. 302) appears as white flecks or plaques, which are easily removed with gauze to leave an erythematous base. Thrush can affect any oral site, typically the palate or upper buccal vestibule posteriorly.

Acute candidosis can also present as red lesions (erythematous candidosis). Altered taste usually accompanies candidosis. Red scaling or fissuring of the corners of the mouth, referred to as angular cheilitis, may coexist with an intraoral infection or occur alone. In infants and toddlers, diaper rash may also be present.

Although most cases of intraoral candidosis develop suddenly, without treatment they may persist for extended periods of time. Chronic candidosis is discussed on p. 212.

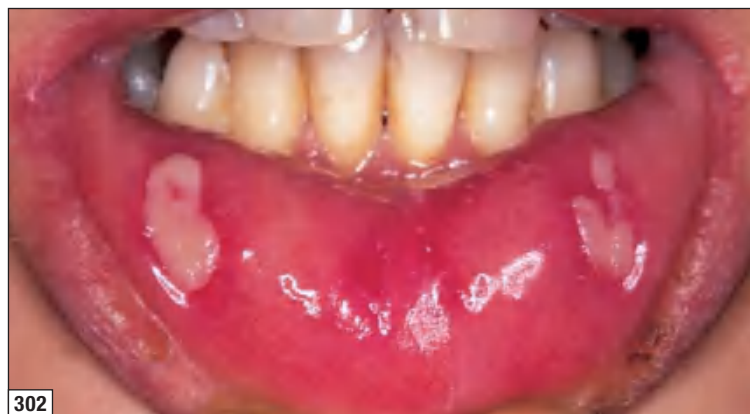

Figure 302. Thrush in a leukemic patient.

Diagnosis

Diagnosis is clinical, supported by microbiology, hematology, immunology and other investigations in some instances.

Management

Identifying the predisposing circumstances is important for managing this infection. Improved oral hygiene, caries control, the daily cleaning of pacifiers and orthodontic appliances and the replacement of contaminated toothbrushes are necessary to treat the disease and to prevent recurrences. A variety of antifungal medications are available for use in pediatrics, including topical and systemic agents.

Topical and systemic antifungal agents are recommended for treatment. Unpleasant taste and a high sucrose content of topical medications are concerns for children. Systemic agents are the drugs of choice for immunocompromised children and for children who have skin and nail involvement.

Systemic azoles have gained preference despite the fact they may be hepatotoxic and responsible for many drug interactions and are expensive. Those currently available include *imidazoles* (clotrimazole, miconazole, econazole, ketoconazole), and *triazoles* (fluconazole and itraconazole). Fluconazole is currently preferred. It is active against most *C. albicans*, though resistance may appear, especially in people with immune defects, but is less active against non-*albicans Candida* species. Fluconazole is well absorbed from the gut, even in the absence of gastric acidity; oral absorption is rapid and nearly complete within 2 hours. Fluconazole appears to undergo relatively little metabolism in the body, elimination being predominantly renal. With normal renal function the serum half-life is approximately 30 hours. Oral fluconazole is generally well tolerated, toxicity is mild and infrequent, and, with usual doses, fluconazole does not appear to suppress the synthesis of corticosteroid hormones. Nausea, headache and rashes may occur. Fluconazole may interact with terfenadine, astemizole and cisapride to produce dysrhythmias, and it increases the activity of anticoagulants, ciclosporin, benzodiazepines, anticonvulsants and sulfonylureas.

Treatment options are given in Table 17.

Table 17. Treatment options for acute candidosis

Topical antifungal agents

Drug	Nystatin (USA: Mycostatin, Nilstat, UK: Nystan, Nystamont) oral suspension 100,000 units/mL
Dispense	240 mL
Directions for use	Rinse with 4 mL for 2 minutes and swallow or expectorate, four times daily. Use for 14 days and re-evaluate. Do not eat or drink for 30 minutes after use.
Pediatric significance	For infants decrease the dosage to 2 mL, 4 times a day. For children who cannot rinse, place 1–2 mL along both sides of the buccal mucosa, using a disposable plastic dropper or syringe. Older children who have pharyngeal involvement or tonsillar hypertrophy should gargle and swallow or expectorate the solution. These products usually contain 30–50% sucrose (Nystamont does not) and therefore oral hygiene must be reinforced. Because of the sulfurous taste, children may find this treatment objectionable. The pharmacist can add raspberry, grape or wild cherry flavoring drops to improve patient acceptance.
Drug	Clotrimazole 10 mg/mL suspension (not UK)
Dispense	60 mL
Directions for use	Swab 1–2 mL onto the affected area four times daily. Use for 14 days and re-evaluate. Do not eat or drink for 30 minutes after use. Shake well before using.
Compounding instructions	Crush six 100 mg clotrimazole vaginal inserts, reducing to a fine powder. Add 60 mL confectioner's glycerin or OralBalance moisturizing gel (Laclede) and mix thoroughly.
Pediatric significance	This is useful for very young children who cannot rinse and when nystatin suspension has been ineffective. Because of its adherent properties, the mixture can be swabbed onto the nipple of the pacifier or inside the removable, palatal coverage appliance, along with concurrent mucosal therapy. When more volume is needed for rinsing, clotrimazole 10 mg/mL can be diluted with sterile water for irrigation to 10 mg/2.5 mL by the pharmacist.

Table 17. Treatment options for acute candidosis (*continued*)

Drug	Amphotericin B (UK: Fungilin) 100 mg/1 mL oral suspension (or 10 mg lozenge Fungilin)
Dispense	48 mL
Directions for use	Swish or swab the mouth with 1 mL and swallow, four times daily. Use for 14 days and re-evaluate. Do not eat or drink for 30 minutes after use.
Pediatric significance	This antifungal agent is approved for pediatric use at the same dosage as that recommended for adults. This pleasant tasting suspension contains less than 1% alcohol (no sugar) and is sweetened with glycerin. The small volume is advantageous for those who cannot expectorate, but may be a disadvantage because it is difficult to cover widespread infection with such a small volume. The suspension may be diluted by a pharmacist to 100 mg/4 mL for easy swish and expectorate.

Drug	Clotrimazole (Mycelex) 10 mg troches (not in UK)
Dispense	70 troches
Directions for use	Slowly dissolve 1 troche every 3 hours while awake (5 troches per day). Use for 14 days and re-evaluate.
Pediatric significance	It takes about 15 to 20 minutes to dissolve one of these lozenges in the mouth. For maximum effectiveness, it is important that children are instructed not to chew the troches or swallow the medication prematurely. Young children, who could aspirate or choke on the troches, should be given another agent. This medication contains about 60% sucrose content and therefore thorough oral hygiene measures should be reinforced.

Systemic antifungal agents

Drug	Fluconazole (Diflucan) 100 mg tablets (US also 50mg, 150mg, 200mg tablets and suspension 50mg/5ml and 200mg/5ml) (UK also 50mg capsules or suspension 50mg/5 mL)
Dispense	11–15 tablets
Directions for use	Take 100 mg twice daily for the first day, then 100 mg every day for 10–14 days.
Pediatric significance	The pediatric dose is 3–6 mg/kg/day and it is safe to use in infants. Suspensions are available in 50 or 200 mg/mL strengths and are sweetened with sucrose. Several drug interactions may occur with this medication, but the major drug interactions include terfenadine, astemizole, cisapride, lorazepam, midazolam, and triazolam. Although a rare event, hepatotoxicity has been reported.

Drug	Ketoconazole (Nizoral, generic) 200mg tablets
Dispense	7–14 tablets
Directions for use	Take 1 tablet every day for 7 to 14 days. Do not take antacids within 1 hour of this medication. Take with food.
Pediatric significance	The pediatric dose for children greater than 2 years of age is 3.3–6.6 mg/kg/day. An oral suspension of 20 mg/mL may be compounded by a pharmacist. The suspension must be stored in refrigerator, but is stable for only 7 days. Ketoconazole generic tablets are now available making this drug regimen much less expensive than fluconazole. Several drug interactions may occur with this medication, but drugs that are contraindicated with use include terfenadine, astemizole, and cisapride. Although an uncommon event, hepatotoxicity has been reported, including hepatitis in children.

Topical antimicrobial oral rinse

Drug	Peridex, PerioGard, Chlorohex 1200, generics (chlorhexidine gluconate 0.12%) or Corsodyl or Chlorohex 2000 (chlorhexidine gluconate 0.2%) oral rinse
Dispense	480 mL
Directions for use	Rinse with 15 mL for 30 seconds and expectorate. Use twice daily, after breakfast and before bed.
Pediatric significance	Both Peridex and PerioGard contain 11.6% alcohol and therefore parental supervision is important to prevent accidental ingestion. The oral rinse without alcohol is formulated at a 0.2% concentration to have a comparable antimicrobial effect. Most flavoring agents as well as the foaming agents in toothpaste will destroy the antimicrobial effect of chlorhexidine. All foamy residue from toothbrushing should be rinsed away before using this agent. A 30-minute period should elapse between toothpaste use and chlorhexidine rinse. Tooth staining, occasional minor irritation and mucosal sloughing, and parotid swelling have been noted. Although commonly used, the clinical effectiveness and safety have not been established in children under the age of 18 years. This mouthrinse may be effective when poor oral hygiene or orthodontic appliances are a contributing factor.

Topical antifungal ointments and creams

Drug	Mycostatin, Nilstat or generic (nystatin) ointment 100,000 units/gm (not in UK)
Dispense	15 g tube
Directions for use	Apply a thin layer to the corners of the fitting surface or the inside of a removable orthodontic appliance. Use four times daily, after meals and before bed.
Drug	Clotrimazole (Lotrimin – Rx, Lotrimin AF – OTC; UK: Canesten, Masnoderm) cream 1%
Dispense	15 g for prescription and 12 g or 24 g (OTC) tube
Directions for use	Apply a thin layer to the corners of the mouth. Use four times daily, after meals and before bed.

Table 17. Treatment options for acute candidosis (*continued*)

Drug	Miconazole (USA: Monistat–Derm – Rx, Micatin – OTC; UK: Daktarin) cream 2%
Dispense	15 g for prescription and 15 g or 30 g (OTC) tube
Directions for use	Apply a thin layer to the corners of the mouth. Use four times daily, after meals and before bed.
Drug	Ketoconazole (Nizoral) cream 2%
Dispense	15 g tube
Directions for use	Apply thin layer to the corners of the mouth or inside of removable orthodontic appliance. Use four times daily, after meals and before bed
Pediatric significance	The imidazole antifungals (clotrimazole, miconazole, ketoconazole) exert some <i>in vitro</i> activity against some Gram-positive bacteria, including <i>Staphylococcus aureus</i> , which is beneficial when managing some cases of angular cheilitis. Miconazole may interfere with anticoagulant control.
Topical antifungal/corticosteroid agent	
Drug	Nystatin/triamcinolone acetonide (USA: Mycolog II; UK: Nystadermal) ointment
Dispense	15 g tube
Directions for use	Apply thin layer to the corners of the mouth three times a day for 5 days
Pediatric significance	This agent is often the best choice for chronic cases of angular cheilitis when deep fissures are present because it combines both anti-inflammatory and antifungal properties into one ointment. Concomitant oral antifungal treatment may be indicated, especially when recurrences are frequent.

AMALGAM AND OTHER TATTOOS

Amalgam tattoos are common causes of blue–black pigmentation (Figs 303–305), usually seen buccally in the mandibular gingiva, or at least close to the teeth, mainly in older children or adolescents. Radio-opacities may or may not be seen on imaging. Similar lesions can result if for some reason pencil lead or other similar foreign bodies become embedded in the oral tissues. Occasionally adolescents deliberately have tattoos made in their mouth.

Diagnosis

Diagnosis is clinical. Imaging may help to confirm the diagnosis. Biopsy may be indicated to exclude a nevus, but otherwise these lesions are innocuous.

Management

These lesions are often best left alone.

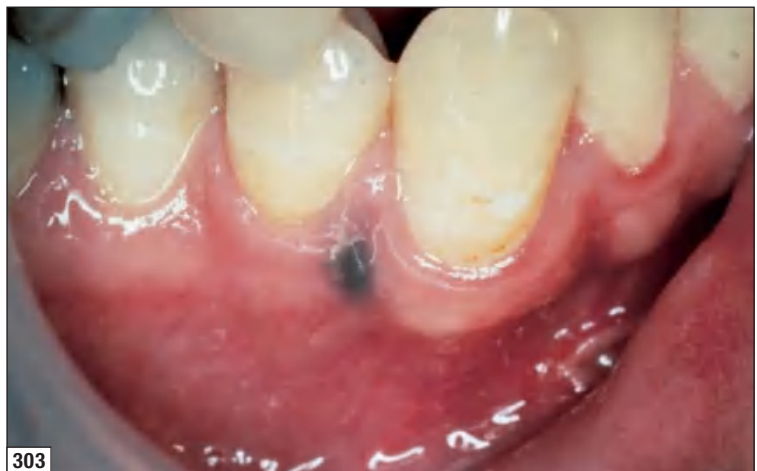

Figure 303. Amalgam tattoo.

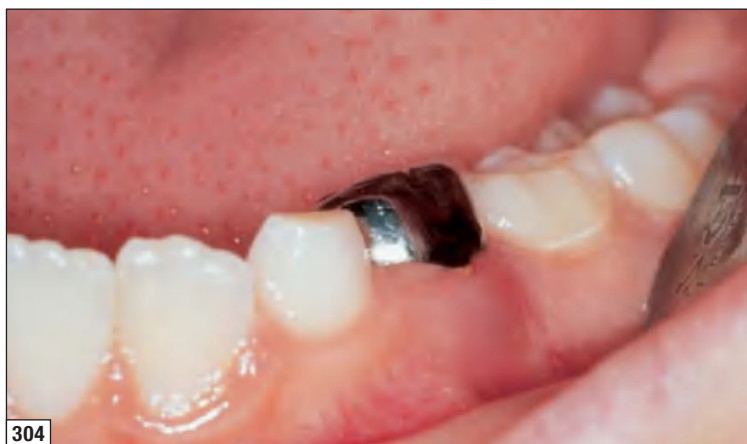

Figure 304. A translucent blue gingival swelling noted adjacent to a mobile primary molar with a stainless steel crown appeared to be an amalgam tattoo but proved to be an eruption cyst.

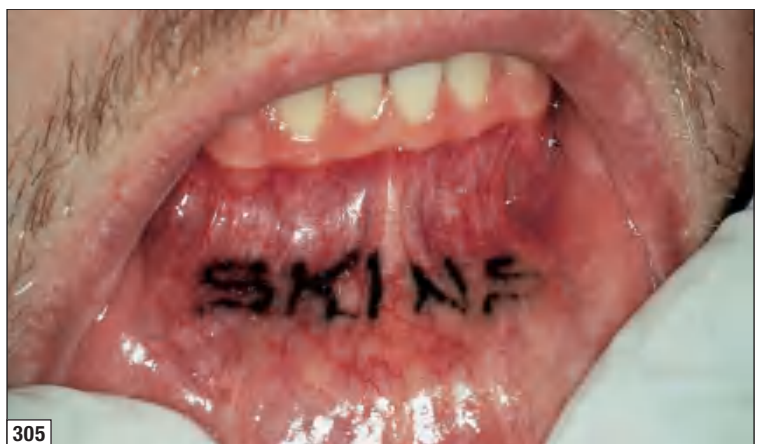

Figure 305. Deliberate intraoral tattoo.

ANGIOEDEMA

Lip, facial or oral swelling may be a feature of angioedema (Fig. 306), which is often an allergic type 1 hypersensitivity response induced by foods, drugs and other allergens (Table 18). The edema, if involving the neck and extending to the larynx, can cause rapidly fatal respiratory obstruction and may be associated with anaphylactic reactions.

In oral allergy syndrome there is a combination of oral pruritus, irritation and swelling of the lips, tongue, palate and throat, sometimes associated with other allergic features such as rhinoconjunctivitis, asthma, urticaria-angioedema, and anaphylactic shock. It is precipitated mainly by fresh foods such as fruits and vegetables, and sometimes by pollens because of cross-reacting allergens. Cooking often destroys the allergens.

Diagnosis

Angioedema is diagnosed clinically.

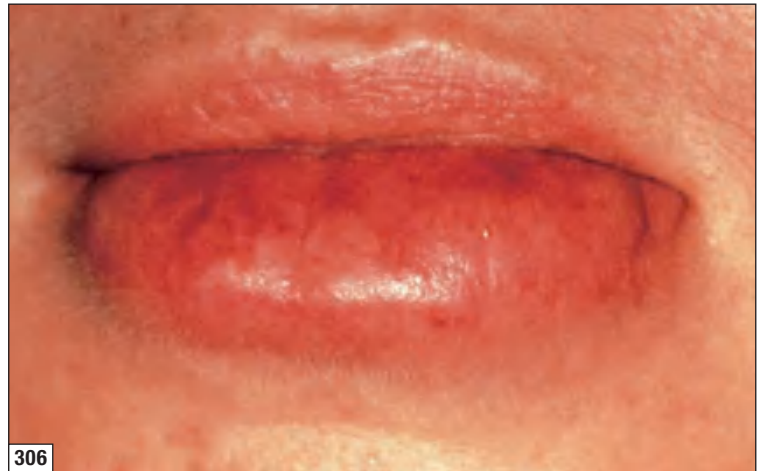
Management

Although angioedema is of acute onset and often only mild and transient, there is always the potential of obstruction of the airway, and therefore medication is indicated. Mild angioedema may respond to antihistamines or to a sympathomimetic agent such as ephedrine which can be taken by mouth. In more severe cases, especially if there is a threat to the airway, the emergency should be managed in the same way with intramuscular adrenaline (epinephrine), and with systemic corticosteroids or antihistamines as for an anaphylactic reaction. For intractable chronic cases, corticosteroids may be required.

Oral allergy syndrome may respond to antihistamines or to a sympathomimetic agent such as ephedrine, which can be taken by mouth.

Table 18. Common drug allergens precipitating angioedema

Captopril
Antihypertensives
Antibiotics
Nonsteroidal anti-inflammatory drugs
Doxorubicin
Opiates
Sedatives
Vaccines



306

Figure 306. Angioedema.

ANGULAR STOMATITIS (ANGULAR CHEILITIS, CHEILOSIS, PERLECHE)

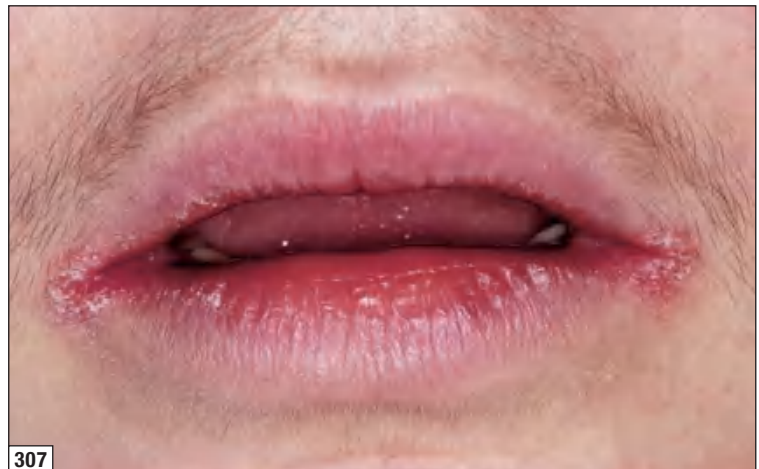Angular stomatitis (Fig. 307) is bilateral and produces erythema, fissuring or ulceration at the commissures, which can be painful and disfiguring. Rarely, angular stomatitis is a manifestation of iron deficiency or of vitamin deficiency, or an immune defect. In children, lip incompetence and drooling may predispose to this condition. Although *Candida albicans* is the prevalent organism, *Staphylococcus aureus* and other microorganisms may sometimes be isolated.

Diagnosis

Diagnosis is clinical, supported by microbiology, biochemistry and hematology in some instances.

Management

Antimycotics are indicated, especially in immunocompromised patients. There is at least a theoretical advantage in using topical miconazole because this is also antibacterial (see Candidosis, p. 128).



307

Figure 307. Angular stomatitis in a diabetic boy.

APHTHAE (RECURRENT APHTHOUS STOMATITIS, RAS)

Recurrent aphthae typically:

- start in childhood or adolescence
- are multiple
- are ovoid or round
- recur
- have a yellowish depressed floor
- have a pronounced red inflammatory halo.

There appears to be a genetically determined immunological reactivity to unidentified antigens, possibly microbial. There may be:

- a family history of RAS
- associations with HLA-antigens B51 and Cw7
- changes in cell-mediated immune responses and cross-reactivity with *Streptococcus sanguis* or heat shock protein.

Immunological changes are detectable, but there is no reliable evidence of autoimmune disease. Most patients with RAS are well, but some prove to have associations with:

- stress
- trauma
- deficiency of a hematinic such as iron, folate or vitamin B₁₂ (about 10–20%) or B₁
- celiac disease or Crohn's disease
- menstruation
- food allergy – some react to nuts, chocolate, potato crisps etc.

A minority of patients prove to have systemic disease such as:

- Behçet's syndrome (see p. 136)
- immunodeficiencies, including HIV disease, IgG2 deficiency, and cyclic neutropenia
- a syndrome with periodic fever, aphthous stomatitis, pharyngitis and cervical adenitis (PFAPA), but with no neutropenia
- cytophagic histiocytic panniculitis
- Sweet's syndrome.

Aphthae may present different clinical appearances and behaviors:

Minor aphthae

Minor aphthae (Mikulicz's aphthae; MiRAS; Fig. 308) are recurrent, often ovoid ulcers with an inflammatory halo and are:

- small, 2–4 mm in diameter
- last 7–10 days
- tend not to be seen on gingiva, palate or dorsum of tongue
- heal with no obvious scarring.

Most patients develop not more than six ulcers at any single episode.

Major aphthae

Major aphthae (Sutton's ulcers; MaRAS; Fig. 309) are recurrent, often ovoid ulcers with an inflammatory halo, but are less common, much larger, and more persistent than minor aphthae, and can affect the lip, soft palate and dorsum of tongue as well as other sites. Sometimes termed periadenitis mucosa necrotica recurrens (PMNR), major aphthae:

- can be well over 1 cm in diameter
- are most common on the soft palate, fauces and lips
- can take several months to heal
- may leave obvious scars on healing.

At any one episode there are usually fewer than six ulcers present.

Herpetiform ulcers

Herpetiform ulcers are so termed because patients have a myriad of small ulcers that clinically resemble those of herpetic stomatitis. It is,

however, a distinct entity, lacking the associated fever, gingivitis and lymph node involvement of primary herpetic stomatitis. Herpetiform ulcers:

- start as multiple pinpoint aphthae
- enlarge and fuse to produce irregular ulcers
- can be seen on any mucosa, but especially on the ventrum of the tongue.

Diagnosis

Aphthae are diagnosed from the history and clinical features. There is no diagnostic test of value, but blood tests may be useful for excluding possible deficiencies or other conditions. Diagnosis is clinical supported by microbiology, biochemistry and hematology in some instances. A full blood picture, hemoglobin, white cell count and differential, red cell indices, iron studies, and possibly red cell folate and serum vitamin B₁₂ measurements may help exclude systemic disorders.

Biopsy is indicated only where another diagnosis is suspected.

Management

The aims of treatment are to:

- reduce pain
- reduce ulcer duration
- increase disease-free intervals.

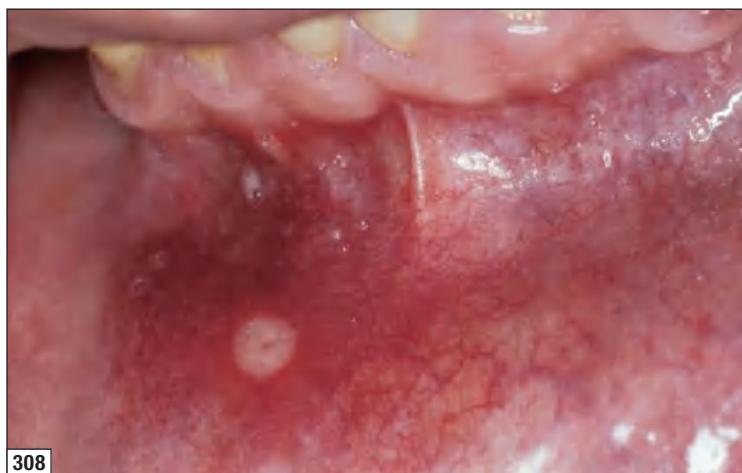

Figure 308. Minor aphthae.

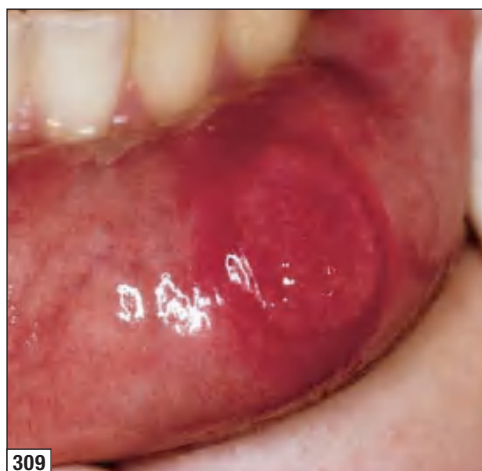

Figure 309. Major aphthae.

Identifying the potential cause is the most effective way for managing this condition, but usually these efforts are futile. Management is not always necessary if the symptoms are mild or if the recurrences are infrequent.

In children, pain control may be important especially before meals and before bedtime. Over-the-counter (OTC) topical anesthetics are useful for local management of pain, while systemic oral analgesics may be more practical and more effective to use.

Ulcer duration may be reduced by use of antimicrobials or corticosteroids. Antimicrobial oral rinses decrease the risk of secondary infections and therefore promote healing. Topical anti-inflammatory agents decrease the inflammatory responses, which are responsible for the signs and symptoms of local tissue injury. Anti-inflammatory agents, especially topical corticosteroids, are prescribed most frequently in problematic cases. These topical agents target lymphocytes, which are thought to be primary mediators for tissue destruction in these oral ulcers.

In moderate to severe cases of aphthous ulcers, oral analgesics in combination with anti-inflammatory medications provide the maximum pain control.

Any allergens and irritant foods such as potato crisps should be avoided. Aphthae may respond to the use of:

- benzydamine rinse to ease the discomfort (not in children under 12 years)
- chlorhexidine aqueous mouthwash
- topical corticosteroids.

Palliative management with coating agents and topical anesthetics are frequently effective for simple and very sporadic forms of this disease. Topical corticosteroids of varying potency are recommended when lesions are frequent or with large lesions that interfere with normal function. Short-term systemic corticosteroids may be used in refractory cases. Anti-inflammatory agents and immune modulator drugs have been beneficial in some patients. Treatment options are given in Table 19.

Table 19. Treatment options for aphthae

Topical anesthetics

Drug	Carmellose sodium – contains 20% benzocaine oral paste. (USA: Orabase-B OTC) (not in UK)
Directions for use	Apply to affected area four times daily, before meals and before bed. Allow paste to melt over the ulcer. Do not rub paste into ulcer.
Drug	Orabase-B gel (OTC) (not in UK)
Directions for use	Swab onto dried mucosal surface. Allow 30 seconds for film to set. Apply to affected area four times daily, before meals and before bed. Contains 15% benzocaine in ethylcellulose gel. Alcohol content (57%) causes an initial sting.
Drug	Zilactin-B gel (OTC) (not in UK)
Directions for use	Apply to affected area four times daily, before meals and before bed. It may cause some burning because of the high amount of alcohol (90%). Application of ice before using may help to relieve this side-effect. Contains 10% benzocaine.
Drug	Cepacol Sugar Free Maximum Strength Cherry or Cool Mint Oral Anesthetic Lozenges (OTC) (not in UK)
Directions for use	Dissolve one lozenge every 2 hours for pain. Contains 10 mg of benzocaine and 4.5 mg of menthol.
Pediatric significance	In the UK: Anbesol, Calgel, Dentmox, Rinstead, Woodwards and Ulc-Aid are pain-relieving preparations available OTC. Many OTC products are available for temporary pain relief of oral ulcers. Product selection in children depends on texture, taste, duration of action, ease of application and side-effects, especially burning sensation. Topical agents with a high alcohol content may be too irritating for children to use. Although gels and pastes are used primarily for pain control, there appears to be some advantage in placing an occlusive barrier over the ulcer to promote healing.

Topical antimicrobial oral rinse

Drug	Peridex, PerioGard, Chlorohex 1200, generics (chlorhexidine gluconate 0.12%) or Corsodyl or Chlorohex 2000 (chlorhexidine gluconate 0.2%) oral rinse
Dispense	480 mL
Directions for use	Rinse with 15 mL for 30 seconds and expectorate. Use twice daily, after breakfast and before bed.
Pediatric significance	Because of the reversible tooth staining properties of chlorhexidine gluconate oral rinse, applying the medication with a cotton tipped applicator and placing it on the ulcer helps to minimize this side-effect. Tea and coffee increase this tooth-staining effect. Both Peridex and PerioGard contain 11.6% alcohol, and therefore parental supervision is important to prevent accidental ingestion. The oral rinse without alcohol is formulated at a 0.2% concentration to have a comparable antimicrobial effect. Most flavoring agents as well as the foaming agents in toothpaste will destroy the antimicrobial effect of chlorhexidine. All foamy residue from toothbrushing should be rinsed away before using this agent. A 30-minute period should elapse between toothpaste use and chlorhexidine rinse. Tooth staining, occasional minor irritation and mucosal sloughing and parotid swelling have been noted. Although commonly used, the clinical effectiveness and safety have not been established in children under the age of 18 years.

Table 19. Treatment options for aphthae (*continued*)**Topical anti-inflammatory paste**

Drug	Aphthasol (amlexanox) oral paste 5% (not in UK)
Dispense	5 g tube
Directions for use	Apply to the ulcers after meals and before bed, until healed.
Pediatric significance	This agent has been shown to increase healing rate and pain relief by about 1 day. Children should be instructed to wash their hands after use to prevent irritation, especially from accidental rubbing of the eyes. A burning sensation may occur following the application of this paste that may not be well accepted by children. In addition, the clinical effectiveness and safety have not been established in people under the age of 18 years, but it is probably safe and offers a reasonable alternative to topical corticosteroids.

Topical corticosteroid medications (topical pellets, ointments, gels and oral pastes: listed in increasing order of potency)*

Drug	Hydrocortrone hemisuccinate (UK: Corlan) 2.5mg
Dispense	100 pellets
Directions for use	Dissolve one pellet by the ulcers, four times each day.
Drug	Triamcinolone acetonide (USA: Kenalog; UK: Adcortyl) in Orabase 0.1%
Dispense	5 g tube
Directions for use	Coat the lesion with a thin film after each meal and at bedtime. Do not eat or drink for 30 minutes after application. Use until ulcer is no longer painful, preferably less than 5 days.
Drug	Betamethasone valerate (USA: Valisone; UK: Betnovate) 0.1% ointment
Dispense	15 g tube
Directions for use	Apply to affected areas after each meal and at bedtime. Do not eat or drink for 30 minutes after application. Use until ulcer is no longer painful.
Drug	Fluocinonide (USA: Lidex; UK: Metosyn) gel or ointment 0.05%
Dispense	15 g
Directions for use	Apply to the ulcer after each meal and before bed. Do not eat or drink for 30 minutes after application. Use until ulcer is no longer painful.
Pediatric significance	Topical corticosteroids for intraoral use are not generally recommended for children under the age of 2 years. These medications should not be used for longer than 7 days to decrease the potential risk of adrenocortical insufficiency unless the child is being properly supervised for this complication. Oropharyngeal candidiasis is another side-effect that some children will develop with corticosteroid use. For better adherence and pain control, the corticosteroid ointments may be mixed with equal parts of Orabase or Orabase-B oral paste. The gel formulations may sting upon application and tend to separate and harden when mixed with the occlusive oral pastes.
Drug	Clobetasol propionate (USA: Temovate; UK: Dermovate) gel or ointment 0.05%
Dispense	15 g tube
Directions for use	Apply to the ulcer after each meal and before bed. Do not eat or drink for 30 minutes after application. Use until ulcer is no longer painful.
Pediatric significance	This agent is not usually recommended for children under the age of 12 years because of the possibility of tissue absorption and the potential risk for developing adrenocortical insufficiency with prolonged use in children. It is best to reserve this topical agent for severe major aphthae when other topical medications are not effective. The same recommendations and side-effects apply to this topical corticosteroid as described above for the less potent medications.

*Use for limited period only

Table 19. Treatment options for aphthae (*continued*)**Topical corticosteroid mouthwashes***

Drug	Dexamethasone (Decadron) elixir 0.5 mg/5 mL
Dispense	237 mL
Directions for use	Rinse with 1 teaspoonful (5 mL) for 2 minutes four times daily, after meals and before bed and expectorate. No not eat or drink for 30 minutes after use.
Drug	Betamethasone (Celestone) syrup 0.6 mg/5 mL (not in UK)
Dispense	236 mL
Directions for use	Rinse with 1 teaspoonful (5 mL) for 2 minutes, four times daily, after meals and before bed and expectorate. No not eat or drink for 30 minutes after use. Betamethasone 0.5 mg tablets (UK: Betnesol) can be dissolved in 10 ml water for use as above.
Drug	Triamcinolone acetonide 0.1% aqueous suspension (not in UK)
Dispense	200 mL
Directions for use	Rinse with 1 teaspoonful (5 mL) for 2 minutes, four times daily, after meals and before bed and expectorate. Do not eat or drink for 30 minutes after use. Shake well before using
Compounding directions to pharmacist	Add 5 mL of 95% ethanol with 5 mL of triamcinolone acetonide 40 mg/mL for injection in an 8 oz oval plastic bottle. Quantity sufficient to make to 200 mL with sterile water for irrigation (not bacteriostatic). This formulation expires in 6 months. Nystatin oral suspension may be substituted as the vehicle if the child is prone to recurrent oropharyngeal candidiasis. It may be flavored with raspberry, chocolate or NutraSweet for children.
Pediatric significance	In general, liquid corticosteroids used as oral rinses are indicated when there are multiple and widespread lesions and/or when direct topical application to individual ulcers is difficult because of the location. The alcohol content varies from 5% for Decadron elixir, 2.5% for triamcinolone suspension to less than 1% for Celestone syrup. Decadron elixir is sweetened with glycerin and saccharin and Celestone syrup contains sorbitol and sucrose. Rinsing with these liquid corticosteroids is not indicated for children who are unable to cooperate or expectorate. The same recommendations and potential side-effects apply to these liquid corticosteroids as those described for the ointments, gels and pastes.

Systemic corticosteroids*

Drug	Prednisone 5 mg, 10 mg, 20 mg tablets
Dispense	Dependent on professional judgment
Directions for use	20–60 mg every morning for 5–10 days
Pediatric significance	Systemic corticosteroids should be prescribed in consultation with a physician and limited to short burst therapy to decrease the risk of adrenocortical suppression. A maintenance phase should be instituted, which includes the use of topical corticosteroids when recurrences are frequent. The maximum dosage is 60 mg/day for the shortest duration, but not to exceed 10 days. Some children experience insomnia, headache, irritability and candidal infections. Prednisone oral solution 1 mg/mL with 5% alcohol is also available for children who are unable to swallow tablets.

Systemic immunomodulating agent

Drug	Cimetidine (USA: Tagamet; UK: Tagamet, Dypamet) liquid 60 mg/mL
Dispense	Varies depending on weight
Directions for use	Take 20–40 mg/kg/day in three divided doses for 6 months
Pediatric significance	The effectiveness of this histamine-2 antagonist for managing aphthous ulcers in children has not been evaluated in controlled studies. In addition, the mechanism of action of this drug for managing this mucosal disease is uncertain, but it appears to be an immunomodulator.

*Use for limited period only

BEHÇET'S SYNDROME (BEHÇET'S DISEASE)

Aphthae of any of the types described above usually occur in isolation in apparently healthy persons.

A minority are a manifestation of Behçet's syndrome (Figs 310–312), in which major aphthae are associated with genital ulcers and uveitis. Behçet's syndrome is more common in Japan, China, Korea and the Middle East, and may have an immunogenetic basis.

Behçet's syndrome is a multisystem disease affecting the mouth in most cases. Other sites commonly affected are:

- Genitals – ulcers resembling oral aphthae affect scrotum and labia majora mainly.
- Eyes – visual acuity is often impaired. Uveitis (posterior uveitis, retinal vasculitis) is one of the more important ocular lesions and is more common in males.
- Skin – rashes include an acneiform pustular rash, pseudofolliculitis, erythema nodosum, pustules at venepuncture sites (pathergy).
- Neurological – headache, psychiatric, motor or sensory manifestations.
- Vascular – thrombosis of large veins such as the vena cavae or dural sinuses caused by raised von Willebrand's factor.
- Joints – arthropathy of large joints. An overlap syndrome with relapsing polychondritis has also been described (mouth and genital ulcers with inflamed cartilage – MAGIC – syndrome).

Diagnosis

Behçet's syndrome is not the only cause of this constellation of lesions. Other causes, such as ulcerative colitis, Crohn's disease, mixed connective tissue disease, lupus erythematosus and Reiter's syndrome, should be excluded. Diagnostic criteria for Behçet's syndrome are not completely agreed, but include recurrent oral ulceration (more than two episodes in 12 months) plus two or more of the following:

- recurrent genital ulceration
- eye lesions
- skin lesions
- pathergy.

There are no diagnostic laboratory criteria, but suggestive are the presence of:

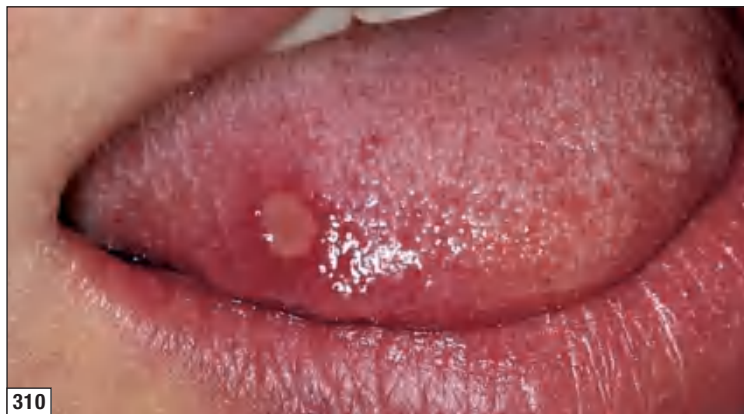- pathergy
- HLA B5101
- autoantibodies to cardiolipin, neutrophil cytoplasm, endothelium or phospholipids.

Management

Medical care is required (see Aphthae, Table 19). Oral hygiene must be improved. Symptoms may be controlled with benzydamine oral rinse or spray. A chlorhexidine mouthwash may also aid healing.

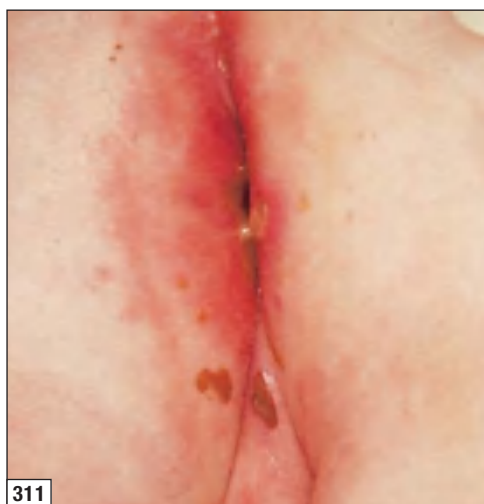Palliative management with coating agents and topical anesthetics is frequently helpful. Topical corticosteroids of varying potency are recommended when lesions are frequent or with large lesions that interfere with normal function. Short-term systemic corticosteroids may be used in refractory cases. Anti-inflammatory agents and immune modulator drugs have been beneficial in some patients.

Symptoms may be controlled with topical corticosteroids, but systemic corticosteroids, azathioprine or colchicine are often required. Systemic manifestations may require aspirin, anticoagulants and immunosuppression using colchicine, corticosteroids, azathioprine, ciclosporin, dapsone, pentoxifylline or thalidomide.



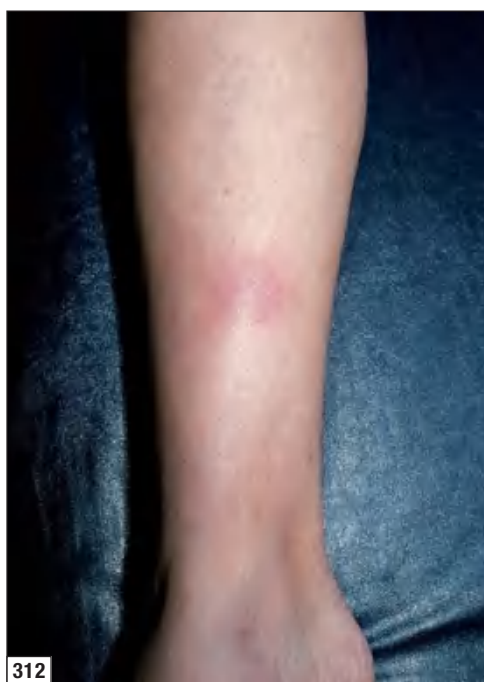310

Figure 310. Aphthae in Behçet's syndrome.



311

Figure 311. Perianal ulceration in Behçet's syndrome.



312

Figure 312. Erythema nodosum in Behçet's syndrome.

BITES

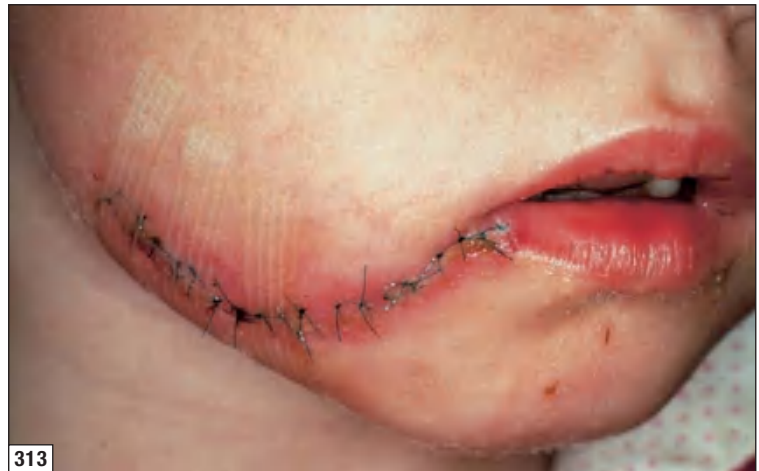Dogs occasionally and other animals or even humans rarely can inflict bites around the mouth (Fig. 313). Animal bites may become infected by unusual organisms.

Diagnosis

Diagnosis is clinical.

Management

Wound debridement and antimicrobials are indicated. Symptoms may be controlled with analgesics and topical anesthetics (benzylamine oral rinse or spray). A chlorhexidine mouthwash may also aid healing in older children.



313

Figure 313. Severe orofacial wound from a dog bite after repair.

BURNS

Burns (Figs 314–324) are most common after the ingestion of caustics by young children or after eating foods that are too hot, and are seen especially on the palate or tongue, for example, ‘pizza-palate’. Some patients attempt to relieve oral pain by holding an analgesic tablet at the site of pain. Aspirin has commonly produced burns. Cocaine use may also result in oral burns.

Cold injury is uncommon, but commonly follows cryosurgery. Actinic burns may develop on the lips of children, especially the lower lip, causing a red, swollen, chapped or ulcerated lesion. In addition, this sun exposure may trigger herpes labialis.

Electrical burns are also uncommon and are usually seen in preschool children who bite electric cord. Very rarely, burns are caused by natural products such as the houseplant *dieffenbachia*, or the enzyme bromelain in pineapple.

Diagnosis

Diagnosis is clinical.

Management

Simple burns can be controlled by topical coating agents, topical anesthetics and sodium bicarbonate mouthrinses. Symptoms may be controlled with benzydamine oral rinse or spray. A chlorhexidine mouthwash may also aid healing. Electrical burns may result in appreciable scarring and perioral constriction and require careful follow-up. Debridement, antibiotics and commissural appliances help to decrease serious cosmetic disfigurement and scarring.

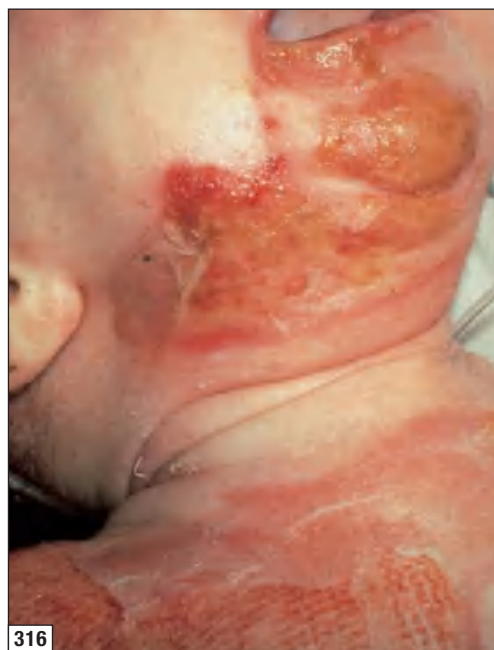
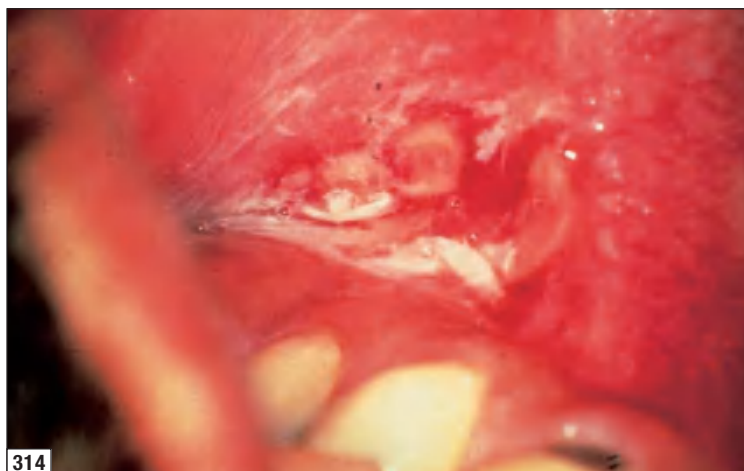
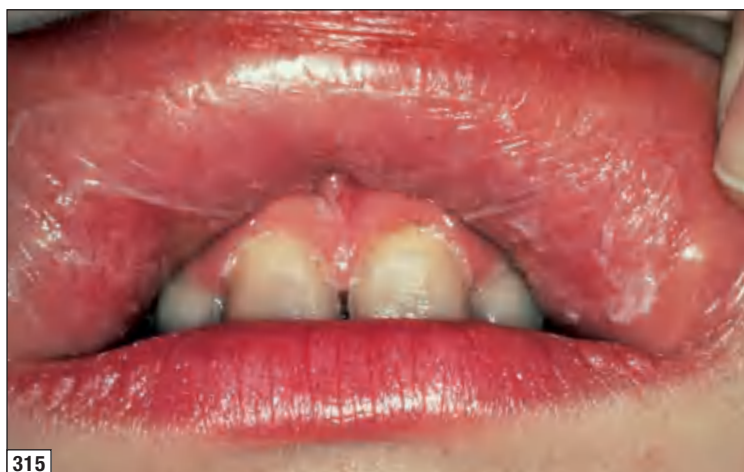Figure 316. Burns of the lips, premaxilla, chin, neck and thorax of a baby who had reached up onto a coffee table and pulled a pot of freshly made hot tea over himself.



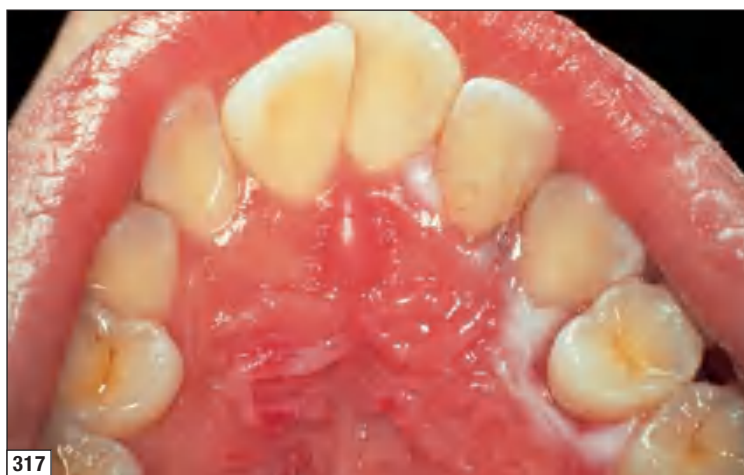314

Figure 314. Cotton roll burn of the maxillary labial sulcus.



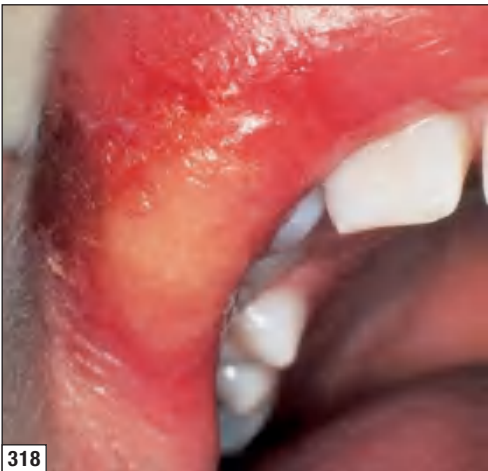315

Figure 315. A burn of the maxillary labial sulcus that appeared shortly after using lignocaine topical gel before infiltration anesthetic.



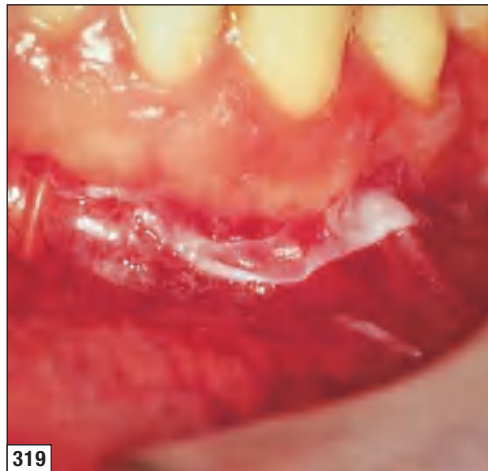
317

Figure 317. Burn of the palatal mucosa caused by dentine primer (orthophosphoric acid) that had leaked under a rubber dam.



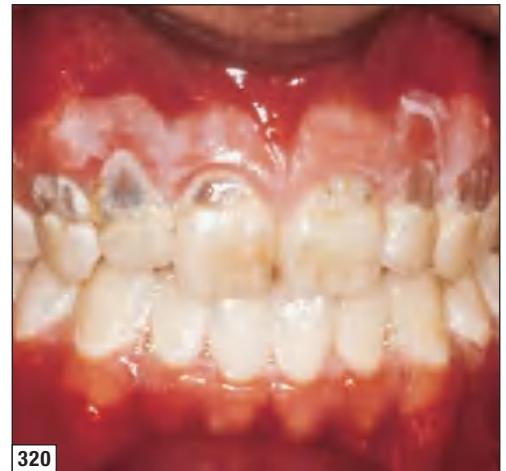318

Figure 318. A handpiece burn of the upper lip.



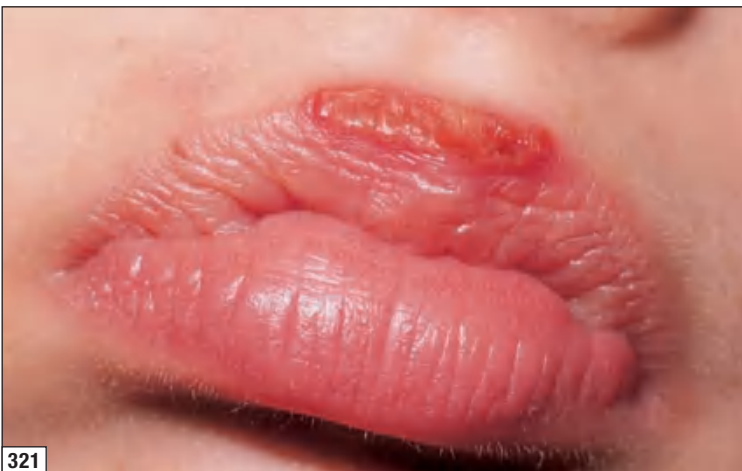319

Figure 319. Chemical burn from mouthwash use.



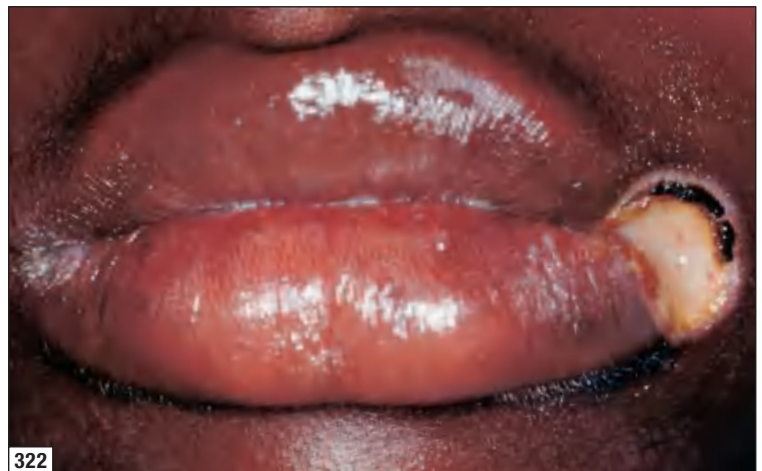320

Figure 320. Cocaine burns.



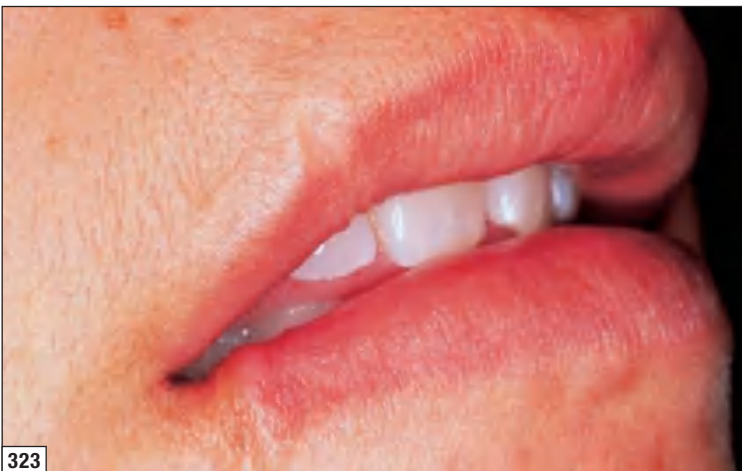321

Figure 321. Burn on upper lip.



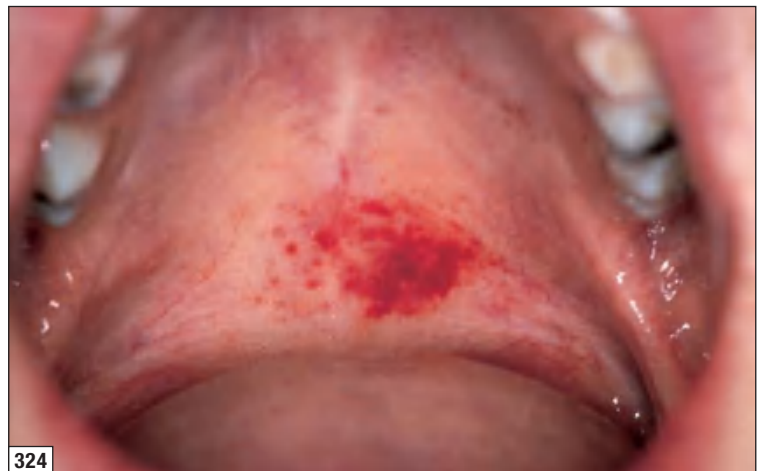322

Figure 322. Deep necrotic ulcer from electric burn involving the angle of the lips and adjacent skin in a black girl who was sucking on an electrical plug.



323

Figure 323. Fan-shaped scars are observed on the maxillary and mandibular lips from electric burns of this Hispanic adolescent girl. They were caused by sucking on an electrical cord when she was a toddler.



324

Figure 324. Petechiae after eating an ice lollipop.

CARCINOMA

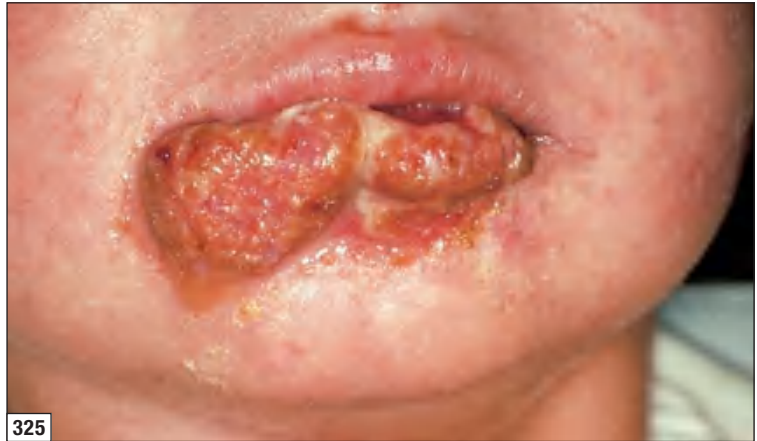Oral carcinoma (Fig. 325) is extremely rare in children. Labial carcinoma may be predisposed to by rare conditions such as xeroderma pigmentosum. Rare cases of nonsyndrome squamous cell carcinomas are diagnosed under the age of 20 every year. Most occur in adolescents and the posterior ventrolateral tongue is the most common site. A red and white patch or persistent ulcer are the most common clinical findings.

Diagnosis

Diagnosis is clinical, supported by imaging and biopsy.

Management

Management depends on the stage and extent of the disease, but surgery is recommended with or without nodal neck dissection and radiation therapy.



325

Figure 325. Carcinoma of the lip in a child.

CHAPPED LIPS

Chapping (Fig. 326) is a lip reaction with scaling, usually in response to cold or hot, dry winds. Acute sunburn can cause very similar changes. Mouthbreathing and use of lip balms with drying agents aggravate the condition.

The lips become sore, cracked and scaly and the child tends to lick the lips or to pick or chew at the scales, which may make the condition worse. The vermillion border of the lips exhibits dryness, scaling and fissuring, which may crack and bleed when the lips are manipulated. The lips frequently burn and appear swollen. In children who constantly suck on the lips, a perioral erythema and papules may accompany the chapped lips.

Diagnosis

Diagnosis is clinical.

Management

Interrupting the cycle of wetting and drying the lips and discontinuing the use of a medicated lip emollient that may act as a desiccant is necessary for lesion resolution. A protective moisturizing ointment helps to relieve the symptoms of dryness and tightness. An emollient such as petrolatum (petroleum jelly) or lanolin should be applied to the lips.

Fissured, red and swollen lips may benefit from short-term use of antimicrobial and anti-inflammatory agents. To decrease chronic lip sucking, a soft acrylic splint for coverage of the maxillary teeth may be a useful habit appliance for severe cases. Treatment options are given in Table 20.

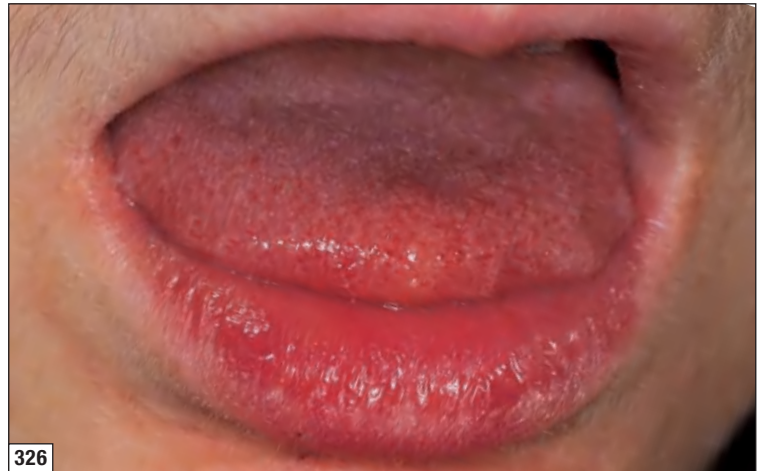

Figure 326. Chapped lips.

Table 20. Treatment options for chapped lips

Topical corticosteroid agents

Drug	Triamcinolone acetonide 0.1% ointment
Dispense	15 g tube
Directions for use	Apply thin layer to the affected area three times daily. Use for 5–7 days.
Pediatric significance	A + D Original ointment, anhydrous lanolin ointment, ChapStick Petroleum Jelly Plus have absorption base types with few sensitizers and may be used for maintenance. Other lip emollients with sunscreens may be introduced slowly after the lip lesions have resolved, but medicated formulas should be avoided altogether.

Drug	Aclovate (alclometasone dipropionate) ointment 0.05% (not in UK)
Dispense	15 g tube
Directions for use	Apply thin layer to the affected area three times daily. Use for 5–7 days.
Pediatric significance	Because this topical corticosteroid may be used on facial skin, it is a good alternative when there is extensive perioral involvement. For maintenance of the lips, see triamcinolone acetonide 0.1% ointment above.

Topical corticosteroid/antifungal agent

Drug	Nystatin/triamcinolone acetonide (USA: Mycolog II; UK, Nystadermal) ointment
Dispense	15 g tube
Directions for use	Apply a thin layer to the affected area three times daily. Use for 5–7 days.
Pediatric significance	This combination agent is a good choice when a secondary fungal infection is suspected. For maintenance of the lips, see triamcinolone acetonide 0.1% ointment above.

Topical antimicrobial agent

Drug	Mupirocin (Bactroban) 2% ointment
Dispense	15 g tube
Directions for use	Apply a thin layer to the affected area three times daily for 5 days.
Pediatric significance	This agent is appropriate for use when a secondary bacterial infection is suspected around the perioral skin, including multiple papules, pustules or crusted lesions. Prolonged use may result in fungal overgrowth.

CHEEK-CHEWING (MORSICATIO BUCCARUM)

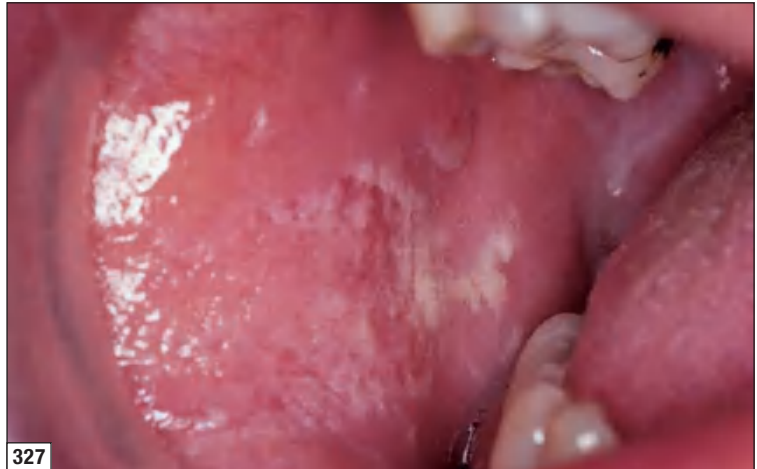Cheek or lip biting (Fig. 327) is often a neurotic trait. The mucosa is shredded with a shaggy white appearance similar to that of white sponge nevus (see p. 41), but restricted to areas close to the occlusal line. Lip-biting is a common habit, particularly in anxiety states, and may be associated with a few traumatic petechiae. Typically, the lower lip only is affected.

Diagnosis

Diagnosis is clinical.

Management

Reassurance is all that is required.

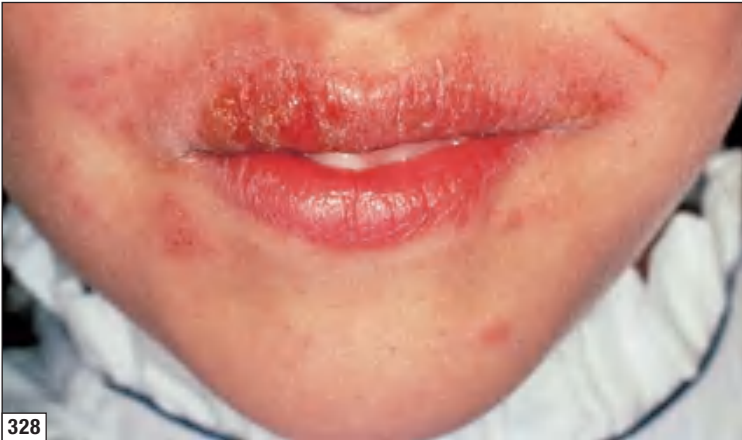

327

Figure 327. Cheek biting (morsicatio buccarum).

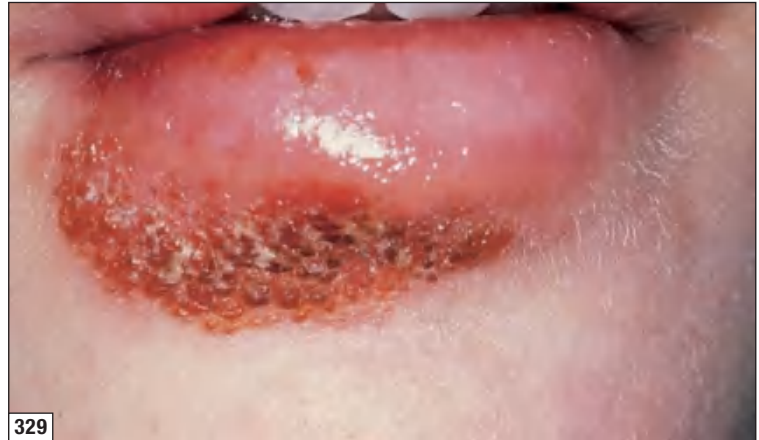CHEILITIS

Cheilitis (Figs 328–333) may be caused by various factors. Some cases are caused by excess sunlight exposure, others by drugs such as etretinate, or by chemical or other burns, or by allergies. Children may develop a habit of licking the lip and adjacent skin, leading to some erythematous circumoral lesions. Candidiasis may infect some of these lesions.



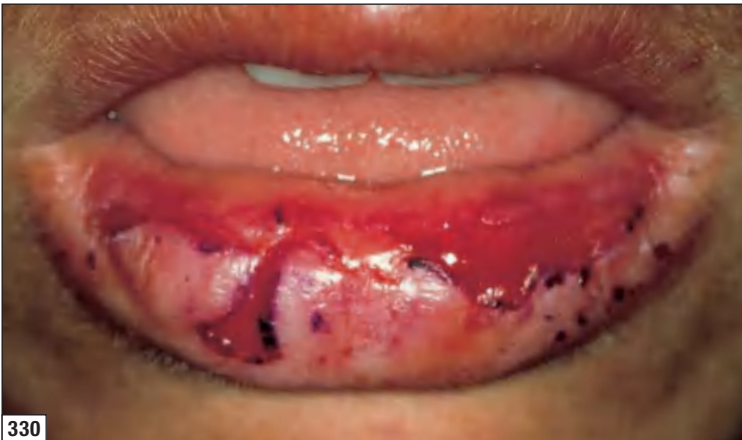328

Figure 328. Lip-licking cheilitis affecting the upper lip.



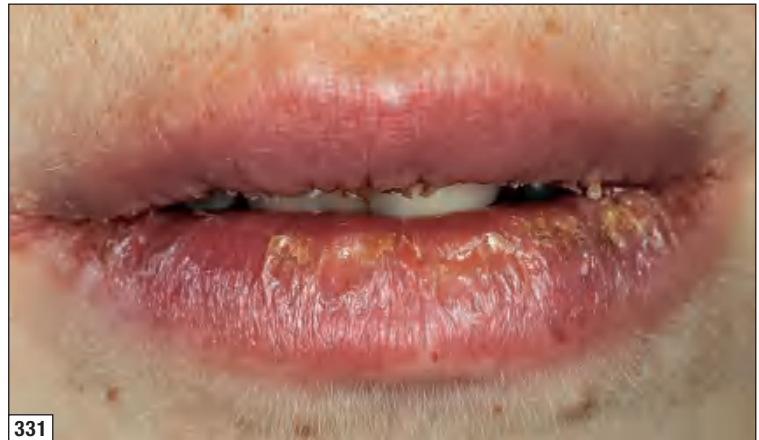329

Figure 329. Lip-licking cheilitis affecting the lower lip.



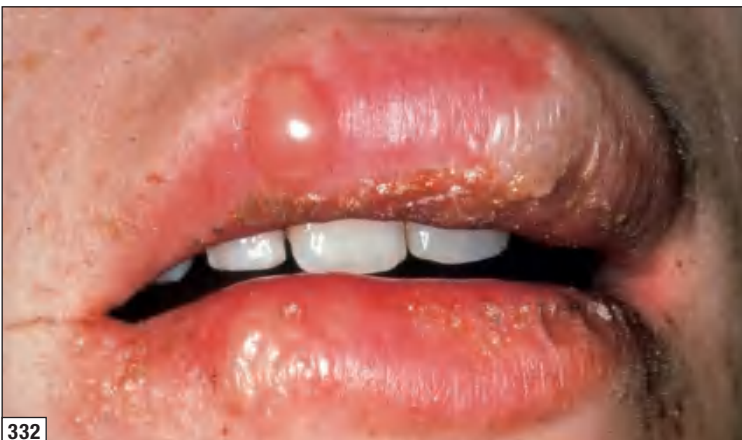330

Figure 330. Actinic cheilitis after excessive exposure to tropical sun.



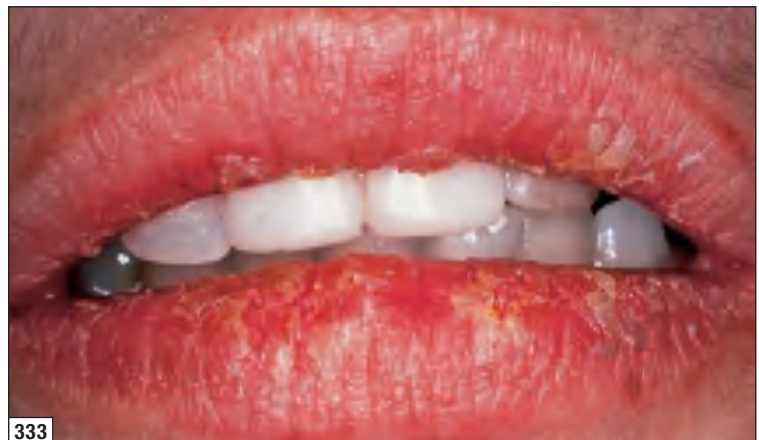331

Figure 331. Cheilitis.



332

Figure 332. Acute exacerbation of cheilitis granulomatosa with diffuse swelling of the lips, scaling and vesicles/pustules on the vermillion border. Pain is not generally a feature of this condition.



333

Figure 333. The appearance of the lips in patient in Figure 332 in a relatively quiescent phase of cheilitis granulomatosa. This is a chronic condition of unknown etiology, which may persist for many years.

CHORISTOMA

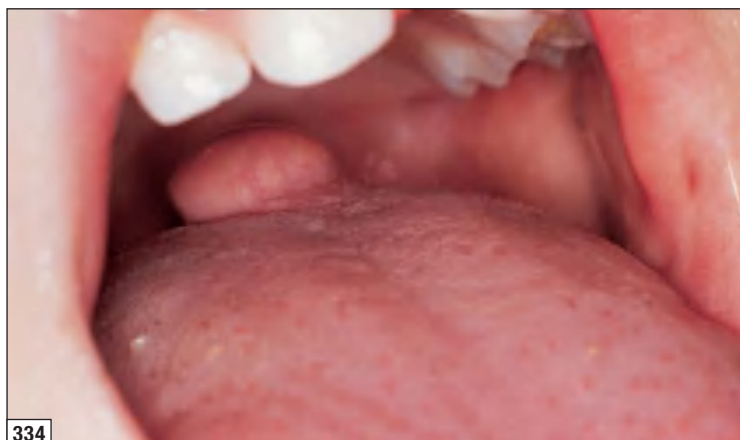Choristoma (Fig. 334) is a growth of normal tissue at an abnormal site with the majority developing on the tongue. These firm, smooth-surfaced nodules may contain a variety of tissue types, including, gastric, glial, osseous and cartilaginous tissue. Swallowing and gagging problems may occur when the enlargements are on the dorsal tongue.

Diagnosis

Diagnosis is clinical, supported by biopsy.

Management

Excision is the treatment of choice and recurrence is not expected.



334

Figure 334. Congenital lingual choristoma in a young girl. Commissural lip pits were also noted as an incidental finding.

CROHN'S DISEASE

Crohn's disease is a chronic inflammatory bowel disease of unknown etiology, affecting mainly the ileum. However, any part of the gastrointestinal tract can be involved including the mouth. The majority of patients with 'oral Crohn's disease' do not however, have identifiable gastrointestinal lesions. Noncaseating granulomas are seen in oral Crohn's disease, but similar cases are related to allergies such as to food constituents like cinnamon aldehyde – the term 'orofacial granulomatosis' (Figs 335–343) is then often used – or sarcoidosis. Swelling of the lips and angular stomatitis are common. Persistent irregular oral ulcers or classic aphthae are common features. Gingival swelling may be a feature and oral mucosal tags are seen in some patients. Folding of the oral mucosa may lead to a 'cobblestone' appearance.

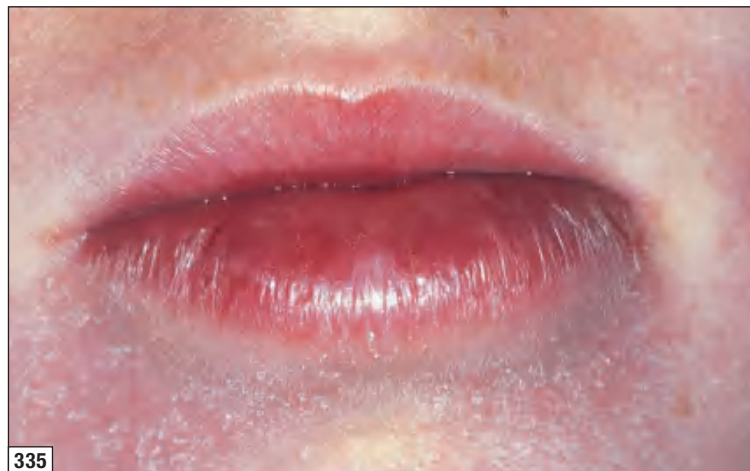Melkersson–Rosenthal syndrome, a related condition, is discussed on page 33.

Diagnosis

Diagnosis is clinical, supported by lesional biopsy, hematology, biochemistry and imaging and sometimes allergy testing. Sarcoidosis, orofacial granulomatosis and Melkersson–Rosenthal syndrome should be excluded.

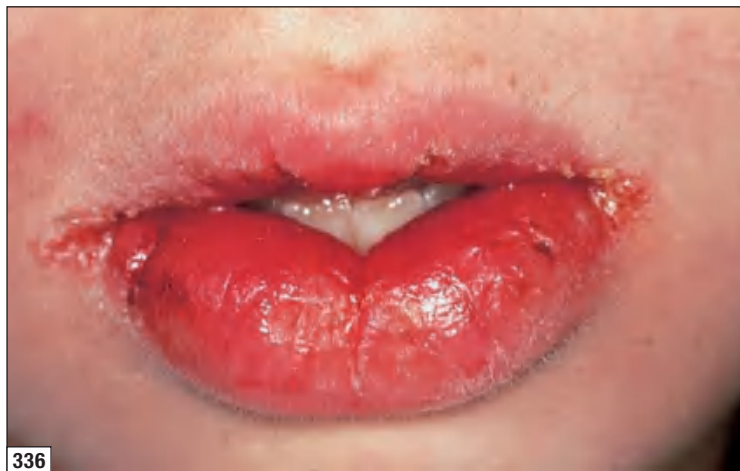Management

Oral hygiene must be improved and dietary exclusion may be needed. Symptoms may be controlled with topical anesthetics. A chlorhexidine mouthwash may also aid healing in older children. Crohn's disease responds best to sulfasalazine, but oral ulcers respond well to topical corticosteroids. Medical care is required.



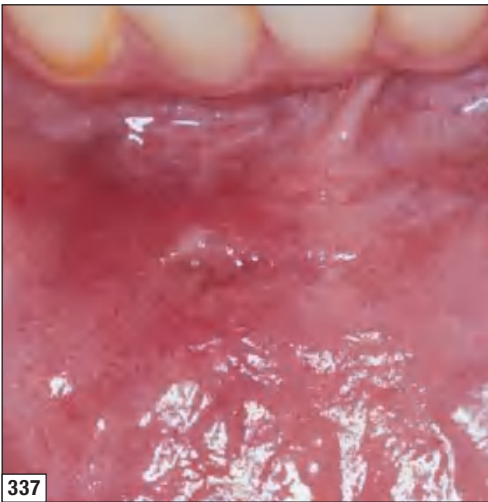335

Figure 335. Labial swelling in orofacial granulomatosis.

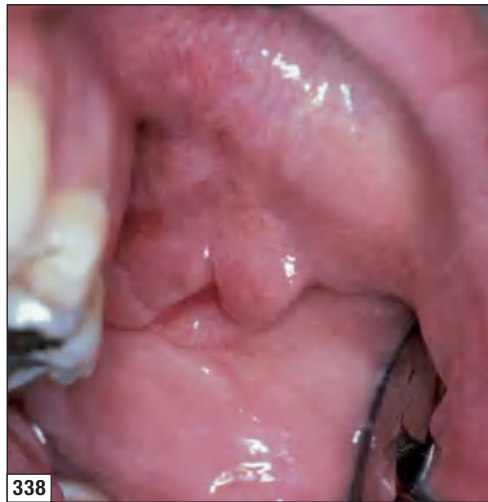

336

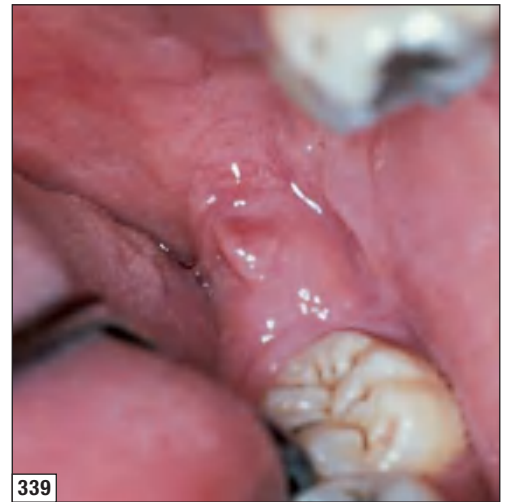Figure 336. Labial swelling, fissuring and angular stomatitis in orofacial granulomatosis.



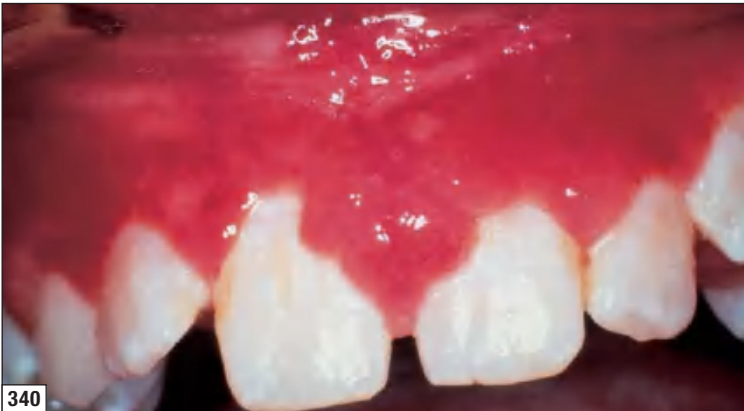337
Figure 337. Oral ulceration in orofacial granulomatosis.



338
Figure 338. Cobblestoning of the buccal mucosa in orofacial granulomatosis.



339
Figure 339. Mucosal tags in orofacial granulomatosis.



340
Figure 340. Gingival proliferative lesions in orofacial granulomatosis.

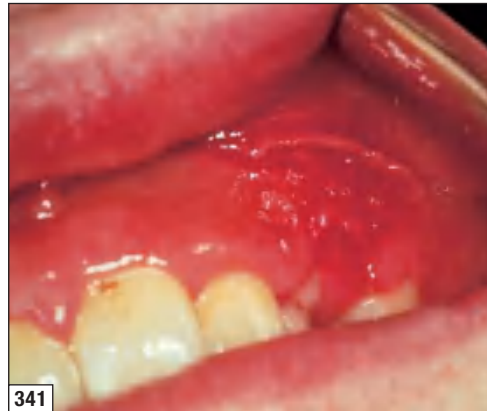
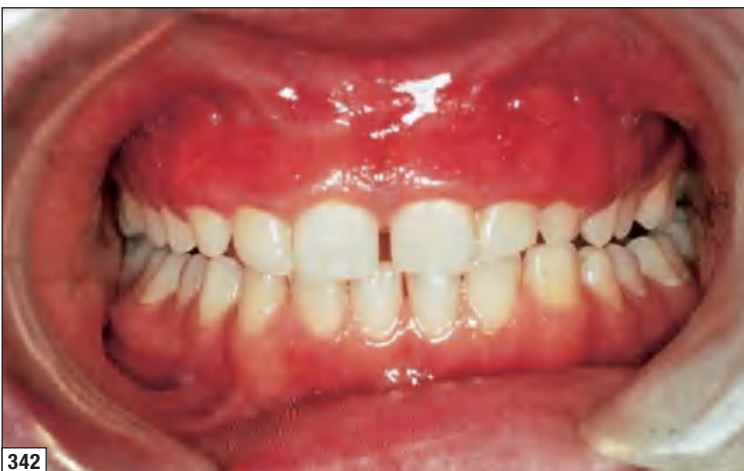
Figure 341. Gingival lesions in orofacial granulomatosis.



342
Figure 342. Gingival swelling in orofacial granulomatosis.

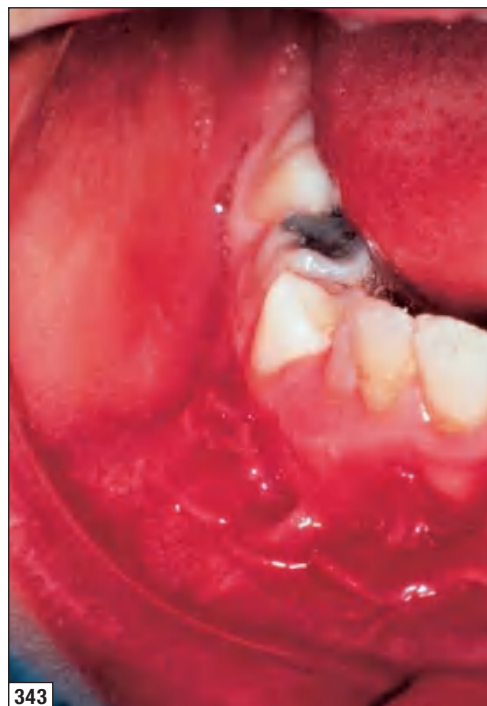

Figure 343. Gingival swelling and 'cobblestoning' of the oral mucosa of a child with orofacial granulomatosis.

DEEP MYCOSES

The deep mycoses (Fig. 344) are rare in children. Despite the fact that *Rhizopus*, *Mucor* and *Absidia* are ubiquitous fungi in decaying vegetation and some sugary foods, zygomycosis (phycomycosis, mucormycosis) is rare and seen almost exclusively in immunocompromised patients. Nasal and paranasal sinus zygomycosis is seen in poorly-controlled diabetics, and it may invade the orbit, frontal lobe, palate and elsewhere.

Aspergillosis infection with aspergillosis species, usually with *Aspergillus fumigatus*, but also *A. flavus* and *A. niger*, can present in several ways. The most serious is systemic aspergillosis or respiratory tract aspergillus infection in immunocompromised patients. In aspergillus sinusitis, there are normally noninvasive fungus balls, but infection of the antrum may rarely invade the palate, orbit or brain. It has been reported that antral aspergillosis can be precipitated by over-filling maxillary root canals with endodontic material containing zinc oxide and paraformaldehyde.

Other deep mycoses are seen mainly in the endemic areas, predominantly in the tropics, or in severely immunocompromised people.

Diagnosis

Diagnosis is clinical, supported by mycology and often biopsy and imaging.

Management

Systemic antimycotics are indicated. Medical care is required.

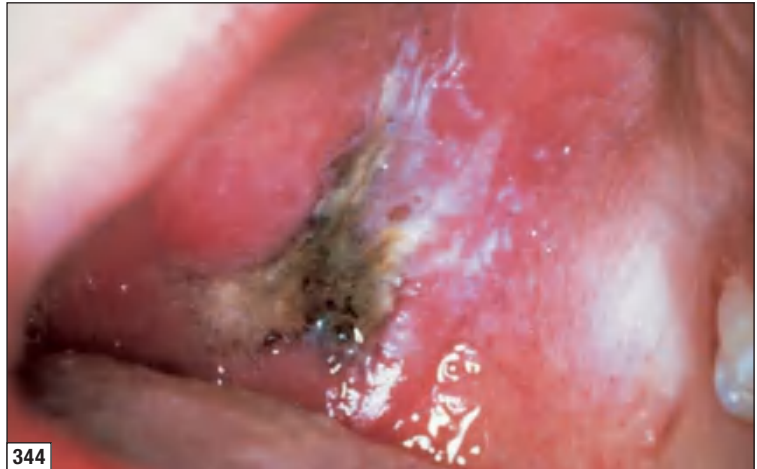

Figure 344. Deep mycosis in a leukemic patient.

ERYTHEMA MULTIFORME

Although the etiology of erythema multiforme (Figs 345–347) is unclear in most patients, in some this mucocutaneous disorder is precipitated by infections (e.g. herpes simplex or mycoplasma), drugs (e.g. sulfonamides, barbiturates, hydantoins, cephalosporins and others) or a range of other triggers where drugs are causal, the term toxic epidermal necrolysis is often used.

Most patients are males, typically adolescents or young adults, and there are periods of remission from the disease. The virtually pathognomonic feature of erythema multiforme is swollen, blood-stained or crusted lips.

Oral lesions progress through macules to blisters and ulceration and are typically most pronounced in the anterior parts of the mouth. Extensive oral ulceration may be seen.

Most patients have oral lesions only, but in some, other mucocutaneous sites are involved. Rashes of various types (hence 'erythema multiforme') are seen. The characteristic rash consists of 'target' or 'iris' lesions in which the central lesion has a surrounding ring of erythema.

Conjunctivitis, stomatitis and rash occur together in Stevens–Johnson syndrome (erythema multiforme exudativum). The ocular changes resemble those of mucous membrane pemphigoid: dry eyes and symblepharon may result. Balanitis, urethritis and vulval ulcers are typical genital lesions.

Diagnosis

Diagnosis is clinical. Biopsy may be necessary if there is doubt about the diagnosis or any possibility of pemphigus or pemphigoid.

Management

Oral hygiene must be improved. Symptoms may be controlled with coating agents and topical anesthetics (benzylamine oral rinse or spray.) A chlorhexidine mouthwash may also aid healing. The most appropriate treatment is not clear. Any known precipitants should be avoided. Systemic antiviral agents (aciclovir) may help prevent herpes simplex virus-induced erythema multiforme (see Herpes, p. 152). The place for systemic corticosteroids remains unclear, but often there is little alternative in Stevens–Johnson syndrome. Medical care is then required.

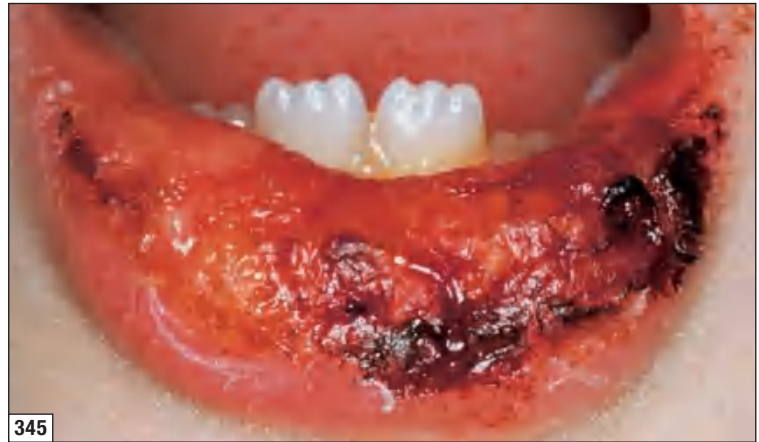

Figure 345. Labial swelling and bloodstained crusting in a young boy with oral erythema multiforme.

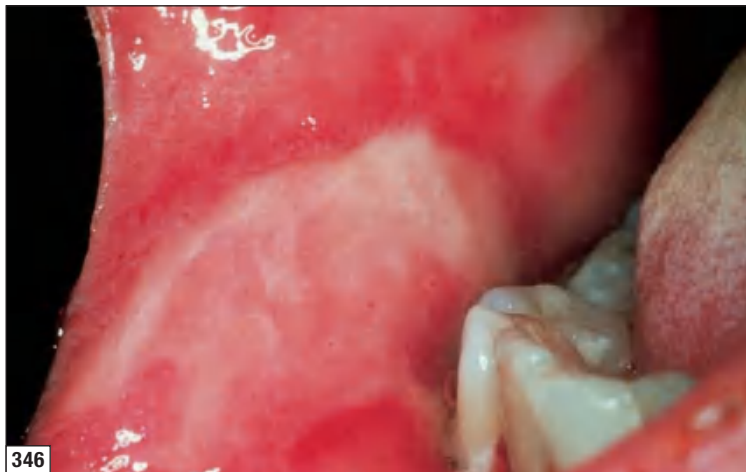


Figure 346. Oral erosions in erythema multiforme.

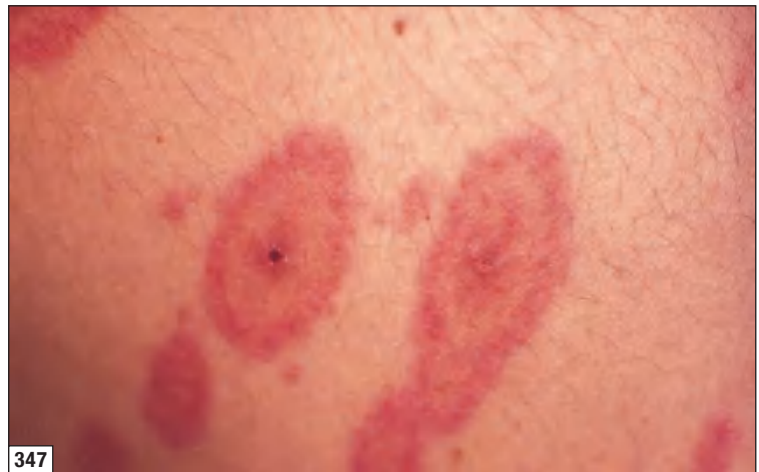

Figure 347. Typical target or iris rash of erythema multiforme.

EXFOLIATIVE CHEILITIS

Persistent scaling of the vermilion of the lips (exfoliative cheilitis; Fig 348) is seen mainly in adolescent or young adult females. Exfoliative cheilitis often starts in the center of the lower lip and spreads to involve the whole of the lower or of both lips. Lip scaling and crusting is more or less confined to the vermilion border, persisting in varying severity for months or years. There may be bizarre yellow hyperkeratotic or thick hemorrhagic crusts or sloughing of sheets of epithelium.

Many cases are thought to be factitious, caused by repeated self-induced trauma such as repetitive biting, picking, lip sucking, chewing or other manipulation of the lips. In some cases it starts with chapping or with atopic eczema, and developing into a habit tic. Exacerbations have been associated with stress and some have been shown to regress with psychotherapy and antianxiolytic or antidepressant treatment.

Diagnosis

Similar superficial scaling can be present in actinic cheilitis, contact cheilitis, glandular cheilitis, lupus erythematosus, *Candida* infections and HIV infection. There appears to be no consistent association with dermatological or systemic disease, though some cases are infected with *Candida* species and cases are seen in HIV disease, in which it is common as a result of xerostomia, candidiasis and protease inhibitors, especially indinavir.

Contact and actinic cheilitis in particular must also be carefully excluded and then biopsy is sometimes indicated.

Management

Some cases resolve spontaneously or with improved oral hygiene. Reassurance and topical corticosteroids may help others, but often it is refractory, even to topical fluorinated corticosteroids. Indeed, the peeling is sometimes accentuated by medications (see Chapped lips, p. 141).

When a factitious cause is suspected, a psychiatric consultation and care may be beneficial.

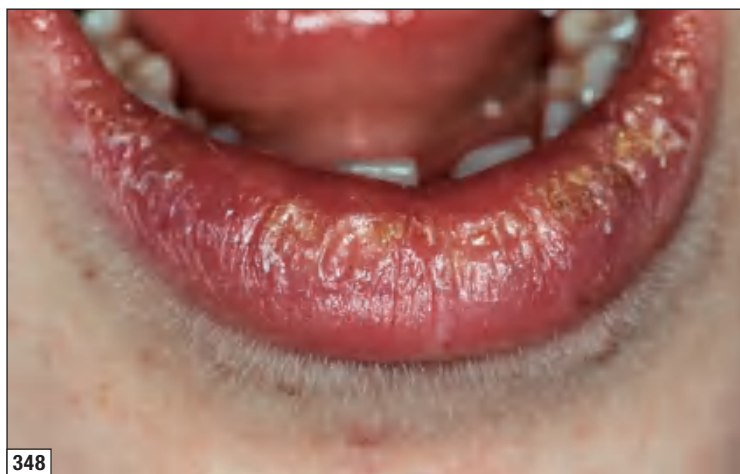

Figure 348. Exfoliative cheilitis.

FURRED TONGUE

The tongue is frequently coated in children (Figs 349, 350). Mouthbreathing, any febrile illness and poor oral hygiene may cause a furred or coated tongue, usually as a result of a coating of epithelial, food and microbial debris, particularly if they are:

- on a soft nonabrasive diet
- poor at oral hygiene or do not brush the tongue
- smokers
- ill
- dehydrated or have dry mouth
- using antimicrobials or chlorhexidine.

Black hairy tongue is an extreme example, which affects mainly the posterior dorsum of tongue. The filiform papillae are long and stained by accumulating debris.

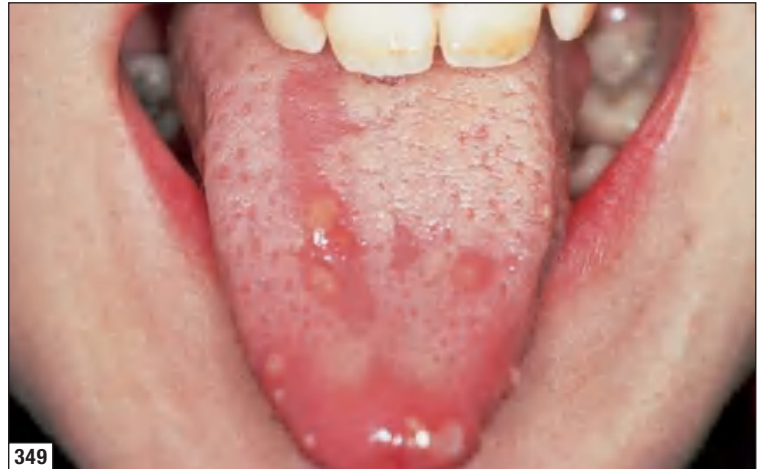Diagnosis

Diagnosis is clinical.

Management

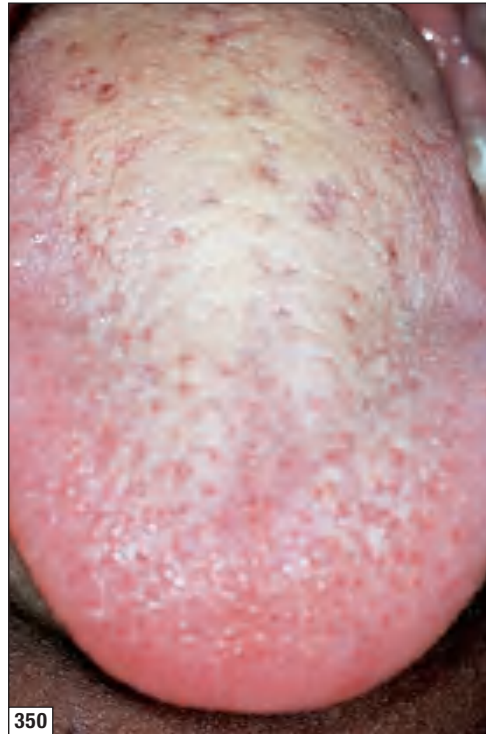The condition is improved by:

- increasing oral hygiene
- brushing the tongue
- using a tongue scraper
- increasing dietary fruit, and roughage (pineapple may help)
- using sodium bicarbonate mouthwashes.



349

Figure 349. Furred tongue in an ill child – in this case primary herpetic stomatitis (ulceration is also evident).



350

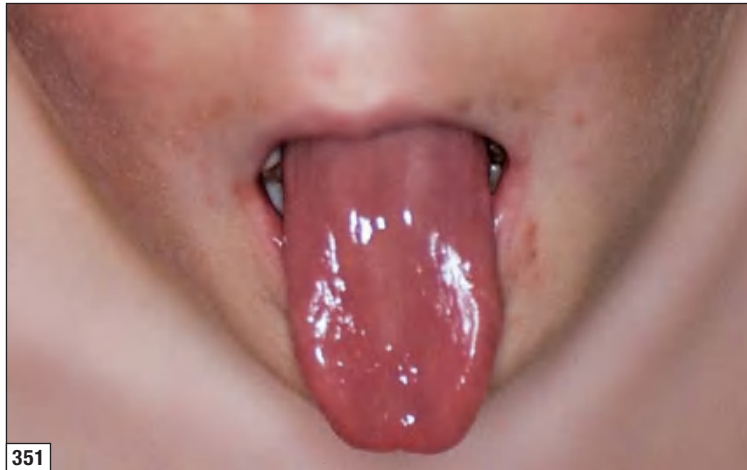Figure 350. Matted creamy white coating of the dorsal tongue was an incidental finding in this young black child.

GLUTEN-SENSITIVE ENTEROPATHY (CELIAC DISEASE)

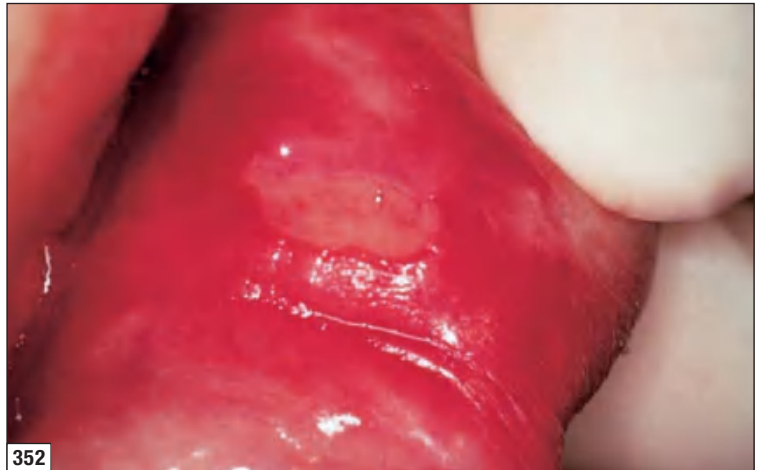Up to 3% of patients seen as outpatients with aphthae prove to have celiac disease (Figs 351, 352). Other oral manifestations include glossitis, angular stomatitis and dental hypoplasia.

Diagnosis

Diagnosis is clinical, supported by hematology, biochemistry and small bowel (jejunal) biopsy.



351
Figure 351. Glossitis in celiac disease.



352
Figure 352. Aphthous ulceration in celiac disease.

GRANULAR CELL TUMOR

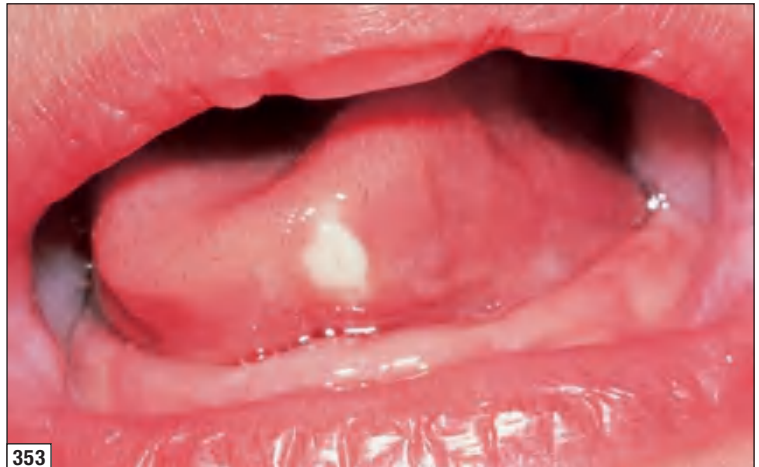Granular cell tumor is a benign soft tissue tumor (Fig. 353). It is rare in children and was previously referred to as a granular cell myoblastoma. This asymptomatic nodule is firm and infiltrative with a pink or yellowish-white surface. The tongue is the most common site of involvement.

Diagnosis

Diagnosis is clinical, supported by biopsy.

Management

Excision of the lesion is the treatment and it does not recur.



353
Figure 353. Granular cell tumor.

HAND, FOOT AND MOUTH DISEASE (VESICULAR STOMATITIS WITH EXANTHEM)

Hand, foot and mouth disease (Fig. 354) results from a Coxsackievirus infection. Small painful vesicles are surrounded by inflammatory haloes especially on the dorsum and lateral aspect of the fingers and toes. Coxsackie virus A16 is usually implicated, but A5, A7, A9 and A10 or viruses of the B9 group, or other enteroviruses, may be responsible.

The incubation period is up to 1 week. A rash is not always present or may affect more proximal parts of the limbs or buttocks. The vesicles usually heal spontaneously in about 1 week.

Oral lesions are nonspecific, usually affecting the tongue or buccal mucosa. Ulcers are shallow, painful and very small, surrounded by inflammatory haloes.

Reports of other systemic manifestations such as encephalitis are very rare, except in enterovirus 71 infection.

Diagnosis

Diagnosis is clinical.

Management

No specific antivirals are available. Oral hygiene must be improved. Symptoms may be controlled with coating agents or topical anesthetics (benzylamine oral rinse or spray). A chlorhexidine mouthwash may also aid healing in older children.

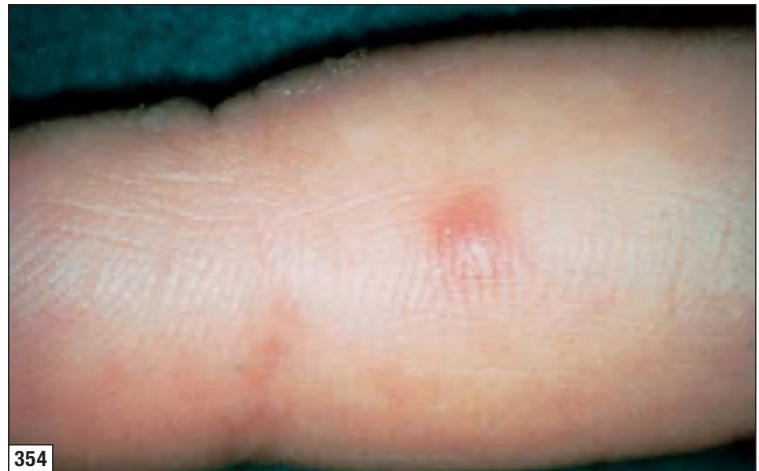

Figure 354. Vesicles in hand, foot and mouth disease.

HERPANGINA

Herpangina (Fig. 355) is usually caused by Coxsackieviruses A1-A6, A8, A10, A12 or A22, but similar syndromes can be caused by other viruses, especially Coxsackie B and echoviruses. Herpangina presents with fever, malaise, headache, and a sore throat caused by an ulcerating vesicular eruption in the oropharynx. Vesicles rupture to leave painful, shallow, round ulcers, mainly on the fauces and soft palate. Ulcers heal spontaneously in 7–10 days.

Lesions resembling Koplik's spots may be seen in echovirus 9 infections, along with a rash and aseptic meningitis.

Diagnosis

Diagnosis is clinical.

Management

No specific antiviral agents are available. Oral hygiene must be improved. Symptoms may be controlled with coating agents and topical anesthetics (benzylamine oral rinse or spray). A chlorhexidine mouthwash may also aid healing in older children.

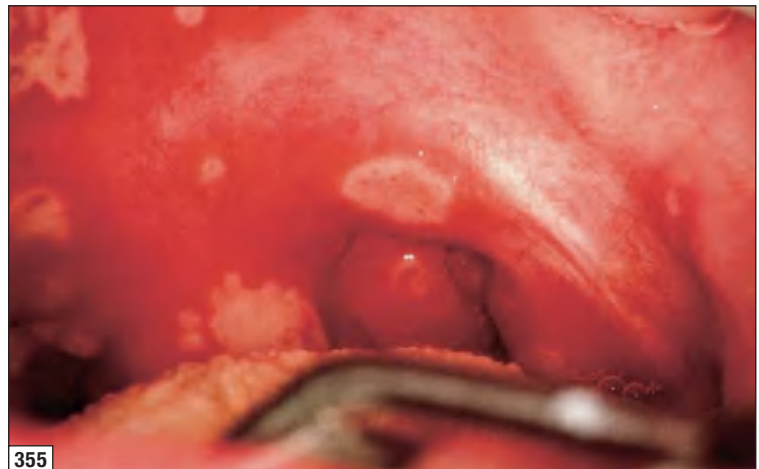


Figure 355. Palatal ulceration in herpangina.

HERPES SIMPLEX INFECTIONS

Primary infection

Herpetic stomatitis (Figs 356–361) is typically a childhood infection seen between the ages of 2–4 years after an incubation period of approximately 6–7 days. Gingival edema, erythema and ulceration are a prominent feature of primary infection, which is usually caused by herpes simplex virus-1 (HSV-1).

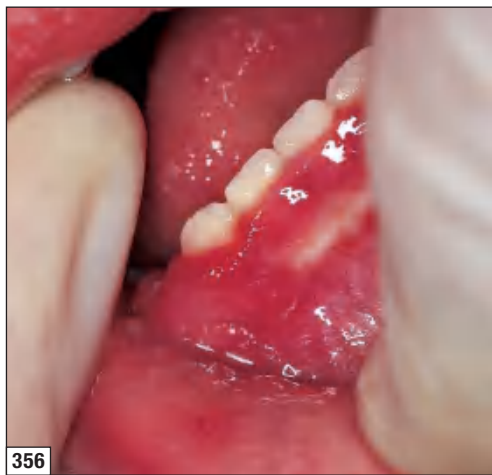

Figure 356. Gingival swelling and erythema in primary herpetic stomatitis.

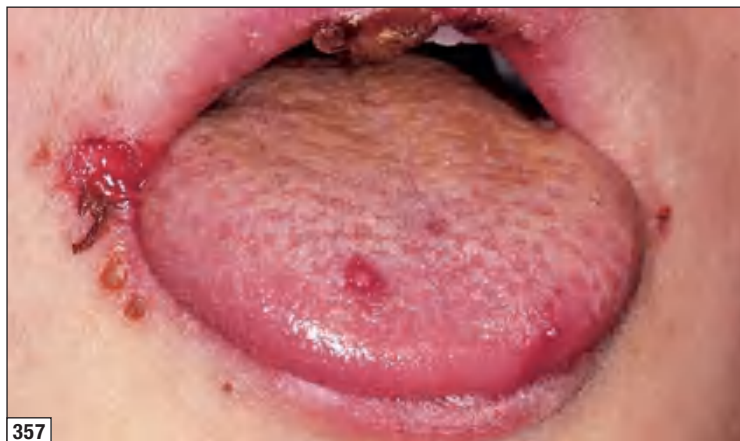

Figure 357. Ulcers on tongue, and skin lesions, in primary herpetic stomatitis.

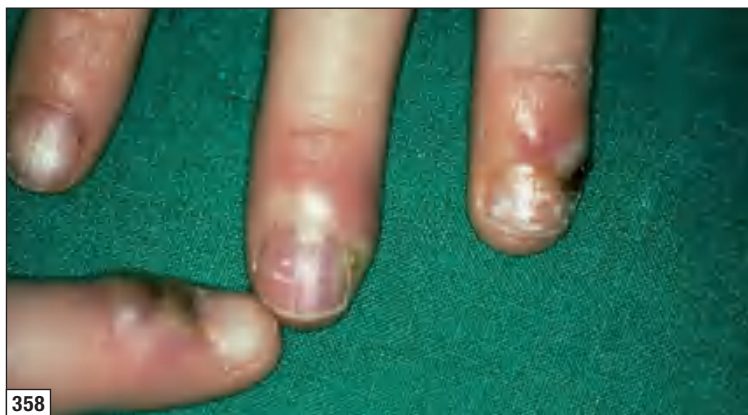

Figure 358. Lesions on skin resulting from contamination by infected saliva in primary herpetic stomatitis.

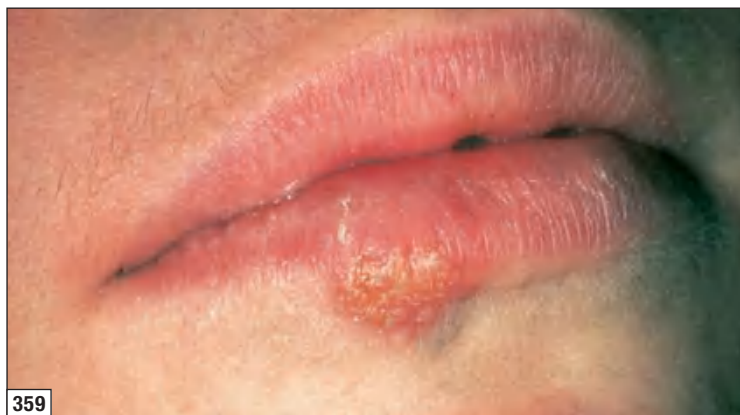

Figure 359. Herpes labialis at a typical site.

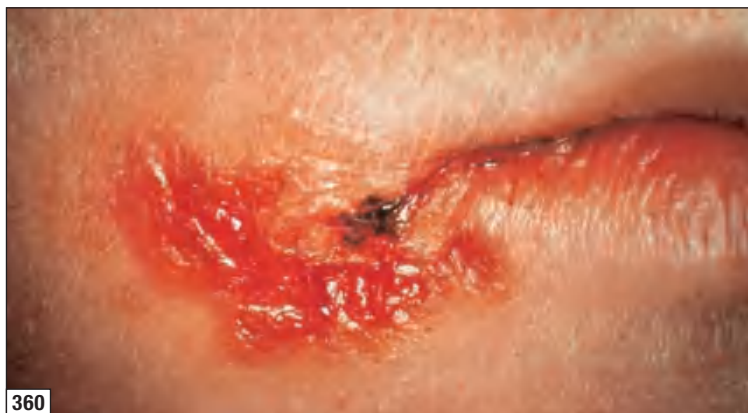

Figure 360. Herpes labialis at the right angle of the mouth. The vesicular lesions have burst to leave a scab that will heal without scarring.

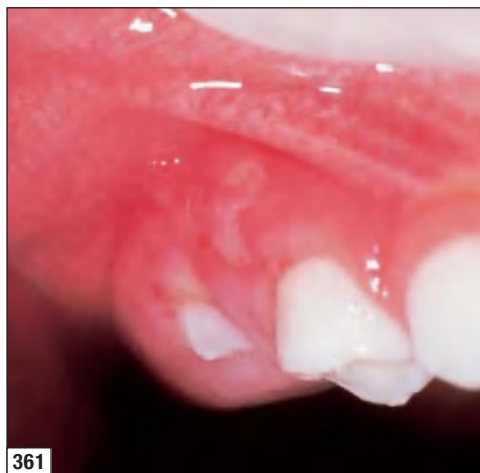

Figure 361. Secondary herpetic ulcers of the attached gingiva adjacent to an erupting maxillary primary second molar. Recalcitrant lesions may be seen in immunocompromised people.

361

The saliva is heavily infected with HSV, which can cause lip and skin lesions and is a source for cross-infection. Rare complications of HSV infection include erythema multiforme, encephalitis and mononeuropathies, including Bell's palsy. Herpetic stomatitis usually resolves in 7–14 days.

Diagnosis

Diagnosis is clinical, sometimes supported by microbiology or serology.

Management

Management of fever, nutritional intake, hydration and oral pain are the primary goals of therapy in the pediatric age group. Palliative management with topical anesthetics and coating agents are important for local pain control and to encourage fluid and nutritional intake. Oral

analgesics for control of pain, fever and muscle aches are recommended. Symptoms may be controlled with coating agents or topical anesthetics (benzydamine oral rinse or spray).

Systemic antiviral therapy may be indicated in severe cases or in immunocompromised children. Medical care is then required. Aciclovir is the first line therapy for primary HSV stomatitis unless there is antiviral resistance, in which event famciclovir or foscarnet are indicated. Oral hygiene must be improved. In order to decrease the risk of secondary bacterial infection, antimicrobial mouthrinses may be beneficial, especially when there is appreciable gingival involvement. A chlorhexidine mouthwash may be useful to aid healing in older children. Treatment options are given in Table 21.

Table 21 Treatment options for primary herpes simplex virus infection

Topical anesthetics and coating agents

Drug mixture Dispense Directions for use Pediatric significance	Diphenhydramine hydrochloride 12.5 mg/5 mL syrup and Maalox (aluminum and magnesium hydroxides) mouthrinse, mix in a 1:1 ratio 200 mL Rinse with 1–2 teaspoonfuls (5–10 mL) every 4 hours for 2 minutes; swish and spit or swish and swallow. Shake well before use. Store suspension at room temperature. It is stable for 60 days. For children who cannot rinse, the suspension can be swabbed inside the mouth with a Toothette or cotton-tipped applicator. If swallowed because of throat pain, the maximum amount is 4 mL/kg/day or 5 mg/kg/day of diphenhydramine. Because there are several diphenhydramine hydrochloride liquid formulas available, request one that is alcohol-free. Benadryl Dye-Free Allergy Liquid Medication has a bubble gum flavor that appeals to young children. Kaopectate or other magnesium aluminum hydroxide solution can be substituted for Maalox. Rinsing with chlorhexidine gluconate may be beneficial for managing gingivitis, once the oral ulcers have resolved.
Drug mixture Dispense Directions for use Pediatric significance	Diphenhydramine hydrochloride 12.5 mg/5 mL syrup/lidocaine (lignocaine) viscous 2%/Maalox mouthrinse; mix in ratio of 1:1:1 200 mL Rinse with 1–2 teaspoonfuls (5–10 mL) every 4 hours and spit out excess. Do not use 2% lidocaine hydrochloride viscous in children who cannot expectorate because of the potential for aspiration.
Drug Dispense Directions for use Pediatric significance	Sucralfate (USA: Carafate; UK: Antepsin) suspension 1 g/10 mL or 1 g/5 ml (Anlepsin) 200 mL Rinse with 1–2 teaspoonfuls (5–10 mL) 4 times a day and spit out excess. Store at room temperature. In children less than 6 years old, who cannot expectorate, limit the amount to 0.5 g four times a day in case the suspension is swallowed. Carafate is sweetened with glycerin and sorbitol and contains no alcohol.

Nutritional liquid supplement

Drug Dispense Directions for use Pediatric significance	PediaSure 237 mL (USA) 8–12 cans Drink one can four times/day. Serve cold. This liquid supplement is a nutritionally complete formula that is easy to swallow and comes in a number of flavors. In addition to this supplement, intake of fluids should be given on regular basis to prevent dehydration. Frozen popsicles/lollipops and Jell-O Pudding Pops help to soothe the mouth and provide some calories.
--	---

Table 21 Treatment options for primary herpes simplex virus infection (*continued*)**Topical antimicrobial oral rinse**

Drug	Peridex, PerioGard, Chlorohex 1200, generics (chlorhexidine gluconate 0.12%) or Corsodyl or Chlorohex 2000 (chlorhexidine gluconate 0.2%) oral rinse
Dispense	480 mL
Directions for use	Rinse with 15 mL for 30 seconds and expectorate. Use twice daily, after breakfast and before bed.
Pediatric significance	Because of the reversible tooth staining properties of chlorhexidine gluconate oral rinse, applying the medication with a cotton tipped applicator and placing it on the ulcer helps to minimize this side-effect. Tea and coffee increase this tooth-staining effect. Both Peridex and PerioGard contain 11.6% alcohol, and therefore parental supervision is important to prevent accidental ingestion. The oral rinse without alcohol is formulated at a 0.2% concentration to have a comparable antimicrobial effect. Most flavoring agents as well as the foaming agents in toothpaste will destroy the antimicrobial effect of chlorhexidine. All foamy residue from toothbrushing should be rinsed away before using this agent. A 30-minute period should elapse between toothpaste use and chlorhexidine rinse. Tooth staining, occasional minor irritation and mucosal sloughing and parotid swelling have been noted. Although commonly used, the clinical effectiveness and safety have not been established in children under the age of 18 years. Both Peridex and PerioGard contain 11.6% alcohol, which may be too irritating to use with extensive oral ulcers and erosions. It is best to prescribe this oral rinse when the majority of viral-induced lesions have resolved, but appreciable gingival inflammation persists, despite oral hygiene measures.

Systemic antiviral therapy

Drug	Aciclovir (Zovirax) 200 mg/5 mL suspension
Dispense	Appropriate mL (see below)
Directions for use	Take appropriate mL every 3 hours while awake or five times a day for 10 days.
Pediatric significance	The dosage for mucocutaneous HSV in this age group is 15 mg/kg, 5 times a day with the maximum dose of 80 mg/kg/day. It should be used with caution in children who have renal function impairment or dehydration. Children need to be well hydrated throughout therapy. Prolonged therapy may be required for immunocompromised patients. This banana-flavored suspension is sweetened with glycerin and sorbitol and contains no alcohol. It is a soothing preparation to swish and swallow, but there is no enhancement of the therapeutic effect as a result of the topical antiviral exposure.

Recurrences

HSV remains latent in the trigeminal ganglion, and reactivation (e.g. by fever, sunlight, trauma or immunosuppression) can produce herpes labialis. Up to one-quarter of the population have recurrent HSV infections. It presents as macules that rapidly becomes papular and vesicular, typically at the mucocutaneous junction of the lip. Lesions then become pustular, scab and heal without scarring. Herpes labialis may be severely destructive and widespread and recalcitrant in immunocompromised people.

Herpes simplex infection as a result of reactivation of latent HSV is uncommon intraorally, but may follow the trauma of a local anesthetic injection, eruption of a tooth, or restorative dentistry or may be seen in immunocompromised patients. Recurrent intraoral herpes in normal patients therefore tends to affect the hard palate or gingiva and heals within 1–2 weeks. Immunocompromised patients may develop chronic, often dendritic, ulcers frequently on the tongue. Clinical diagnosis tends to underestimate the frequency of these lesions. The ulcers can also affect any site in the mouth in this group of patients.

The lesions are characterized by the sudden onset of erythema, clustered vesicles and coalescing ulcers that are painful. Although a prodromal tingling and burning sensation develop before these lesions, this is

not a symptom that young children can easily identify. The vermilion border of the lip and perioral skin are the most common sites of involvement. Intraorally, these lesions have a marked predilection for the gingival and palatal mucosa. Healing is usually complete in 7–10 days and recurrences are variable. In some children, recurrent herpes simplex may be responsible for the discomfort associated with tooth eruption. Herpes simplex virus also underlies many cases of recurrent erythema multiforme (see p. 147).

Diagnosis

Diagnosis is clinical, sometimes supported by microbiology or serology.

Management

Prevention with sunscreens and wide rimmed hats and visors is the first line of management for herpes labialis, when exposure to sunlight is the triggering factor. Palliative management with topical anesthetics and protective coating agents are used to provide relief from itching and pain. Protective lip emollients or antiviral creams (penciclovir cream mainly) are recommended for recurrent herpes labialis. Antiviral therapy is indicated when recurrences are frequent or triggered by a known stimulus and if the child is immunosuppressed. Treatment options are given in Table 22.

Table 22. Treatment options for recurrent herpes simplex virus infection**Prevention**

Drug Water Babies Little Licks, SPF 30, PABA-free, Waterproof (OTC) (not in UK)
 Dispense 4.5 g tube
 Directions for use Apply to lips 1 hour before sun exposure and every hour thereafter.
 Pediatric significance For maximum protection, concurrent use of a sunscreen lotion with sun protection factor (SPF) 30 on the face and a wide-rimmed hat or visor will be most effective when excessive sunlight exposure is the triggering factor. There are several other lip balms that contain a SPF of 30 and the authors do not endorse any particular brand. Many of these lip balms contain several potential skin sensitizers that may result in chapped and cracked lips with chronic use (see Chapped lips, p. 141). Examples of other lip balms with SPF of 30 are: ChapStick Ultra Lip Protection Sunblock and Banana Boat Aloe Vera Lip Balm.

Drug USA: PRESUN for Kids (SPF 29) OTC; UK: Uvistat Ultrablock Cream (SPF30)
 Dispense 120 mL
 Directions for use Apply to sun exposed areas including the face, 1 hour before going outdoors and every hour thereafter.
 Pediatric significance Lotions with a SPF of 30 should be applied liberally on the face especially around the perioral region to prevent recurrences. Recent findings have shown that there is no appreciable advantage to using sunscreens with a SPF greater than 30. Do not use sunscreens on infants under 6 months of age. The authors do not endorse a particular product and several other sunscreens for children are included – USA: Bain de Soleil All Day for Kids, SPF 30, Waterproof; Hawaiian Tropic Baby Faces, SPF 35, Waterproof; Coppertone Kids Sunblock, SPF 30; Waterproof – Johnson's Baby Sunblock Extra Protection, SPF 30, Waterproof; Waterbabies by Coppertone, SPF 30, Waterproof; and Vaseline Intensive Care Baby Moisturizing, SPF 30+, Waterproof. UK: Sun E45, Sunblock lotion, Ambre Solaire, Total Sunblock Cream.

Topical anesthetic/analgesic medication

Drug Cepacol Viractin gel or cream (OTC) (not in UK)
 Dispense 0.25 oz tube
 Directions for use Apply to the affected lip or skin 3–4 times a day, beginning when symptoms first occur. Contains 2% tetracaine.
 Pediatric significance Applying a protective coating over the lip lesion decreases the risk that the child will manipulate the lesion and inoculate other sites or other individuals. The authors do not endorse a particular product; however, examples of other topical agents with the active agent are: Caladryl Cream for Kids 1% cream (pramoxine, 8% calamine, camphor): external use only; Zilactin-B Medicated Gel (10% benzocaine): internal and external use; and Oragel CoverMed Cream (1% dyclonine hydrochloride, 0.5% allantoin): external use only.

Topical antiviral medications

Drug Penciclovir (USA: Denavir; UK: Vectavir) cream 1%
 Dispense 2 g tube
 Directions for use Apply to the area every 2 hours for a period of 4 days, beginning when symptoms first occur.

Drug Aciclovir (Zovirax) ointment (USA), cream (UK) 5%
 Dispense 15 g tube (USA) 2g tube (UK)
 Directions for use Apply a thin layer to the area hourly at the onset of the symptoms for 7 days or when lesion resolves.
 Pediatric significance Topical antiviral agents may act as a protective emollient over the lesion, but, in general, they do not have appreciable clinical benefit for the healthy child. For maximum efficacy this topical antiviral should be applied at the earliest sign or symptom, which is often difficult to identify in the young child. The safety and effectiveness in children have not been established. Bactroban ointment 2% is effective if perioral cutaneous lesions become secondarily infected to promote healing and reduce the risk of scarring (see Perioral impetigo, p. 158)

Drug Abreva (docosanol) cream 10% (OTC) (USA)
 Dispense 2 g tube
 Directions for use Apply to the area 5 times a day until lip sore is healed, beginning when symptoms first occur. Rub in gently but completely and wash hands after applying cream.
 Pediatric significance Docosanol exerts a nonspecific antiviral action by blocking viral entry into a cell. It is effective against acyclovir-resistant HSV. Safety and effectiveness in children have not been established in children under the age of 12.

Table 22. Treatment options for recurrent herpes simplex virus infection (*continued*)**Systemic antiviral treatment**

Drug	Aciclovir (Zovirax) 200 mg capsules
Dispense	25 capsules
Directions for use	Take one capsule every 3 hours while awake, for 5 days
Pediatric significance	This medication is available in a 200 mg/5 mL suspension that is banana-flavored and does not contain sucrose or alcohol. The dosage for mucocutaneous HSV infection in this age group is 15 mg/kg, five times a day with the maximum dose of 80 mg/kg/day. It should be used with caution in children who have renal function impairment or dehydration. Oral aciclovir is indicated for immunocompromised children and it may be indicated for those children who have six or more episodes of recurrent HSV infection per year. In addition, long term prophylactic use of this drug may be beneficial for children who have HSV-associated erythema multiforme. It should be noted that there are limited studies evaluating the effectiveness of this drug in children and appropriate dosages for this age group are not available for the management of recurrent oral and labial HSV infection. The newer antiviral medications, Famvir (famciclovir) and Valtrex (valacyclovis), have improved bioavailability and a reduced dosing schedule, but the safety and efficacy of these drugs in children have not been established

HUMAN PAPILLOMAVIRUS INFECTIONS

Human papillomavirus infections (HPV) cause verruca vulgaris (common wart; Figs 362, 363), condyloma acuminatum (genital wart), papillomas (Figs 364, 365 or, rarely, focal epithelial hyperplasia (Heck's disease). Human papillomavirus lesions are increasingly common, especially as a complication of HIV disease, and immunosuppressed persons.

Warts are seen especially on the lips or tongue, condylomas on the tongue or fauces, Heck's disease in the anterior mouth and papillomas on the palate or gingiva.

Most warts occur on the skin, especially of the hands and knees. The lips, especially the vermillion and commissures, are frequently affected when finger warts are present, but may occur at other intraoral sites. They are characterized by white to tan, rough papules or nodules with a conical-to-papillary surface. Warts may be florid in immunocompromised children.

The condyloma acuminatum (genital wart) usually results from orogenital contact and appears as a cauliflower-like enlargement.

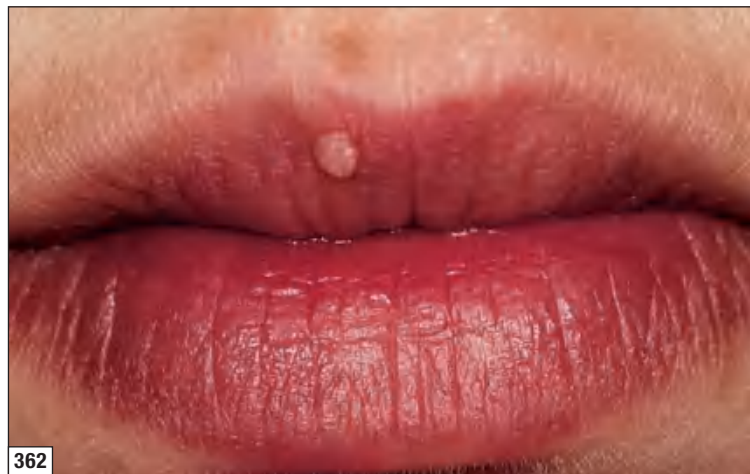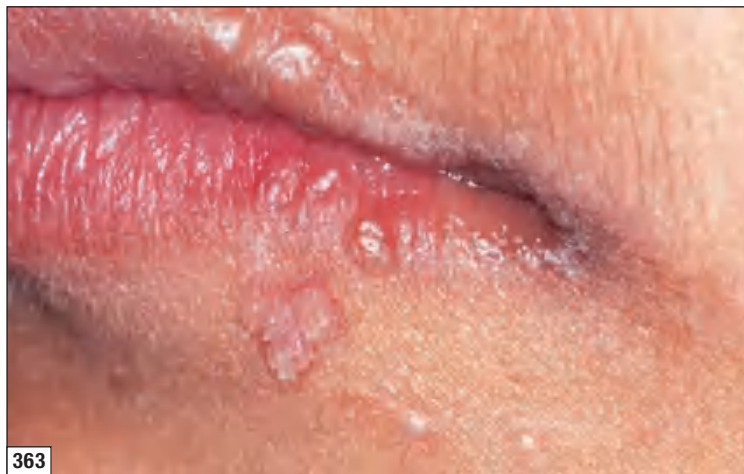The cauliflower-like appearance of a papilloma is obvious, but indistinguishable from a wart.

Diagnosis

Diagnosis is clinical, but biopsy is performed, especially if HPV typing is needed to rule out sexual abuse in a child.

Management

No specific antiviral agents are available. Surgical removal or treatment with podophyllin or interferon may be indicated. Excision of isolated oral lesions after treatment of cutaneous warts is recommended. Spontaneous resolution may occur with skin lesions, but is not typical for oral warts.

**Figure 362.** Wart on the lip.**Figure 363.** Multiple and clustered verrucae of the lip vermillion and perioral skin were noted in this Hispanic child.

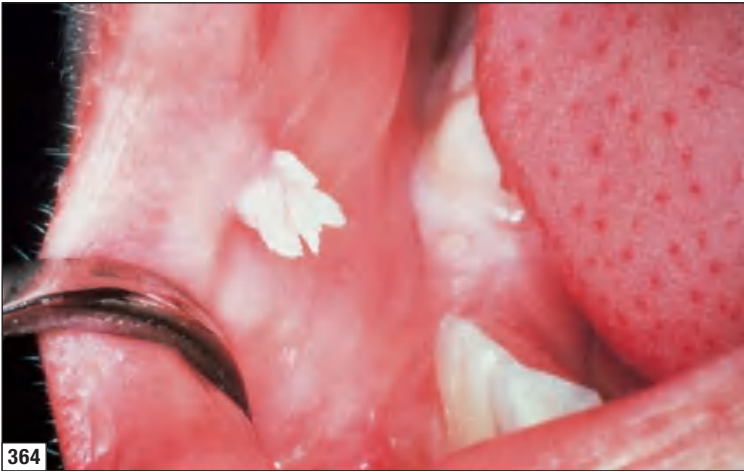

Figure 364. Papilloma of the oral mucosa just inside the right commissure.

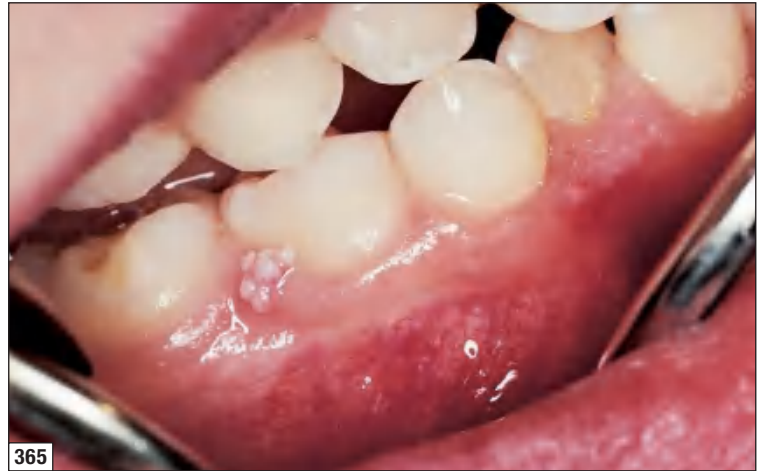

Figure 365. Gingival papilloma.

IATROGENIC INJURY

Hematomas may be produced by dental local anesthetic injections, especially regional blocks. They are usually inconsequential unless intramuscular, when they can cause trismus or become infected. Occasionally after tooth extraction blood may track through fascial planes of the neck to cause extensive bruising, even down to the chest wall. Iatrogenic oral ulceration (Fig. 366) can be produced by trauma, burns, or chemicals.

Diagnosis

Diagnosis is clinical.

Management

Reassurance is important. Symptoms may be controlled with analgesics and topical anesthetics (benzylamine oral rinse or spray). A chlorhexidine mouthwash may also aid healing. Systemic antimicrobials are indicated if infection is suspected.

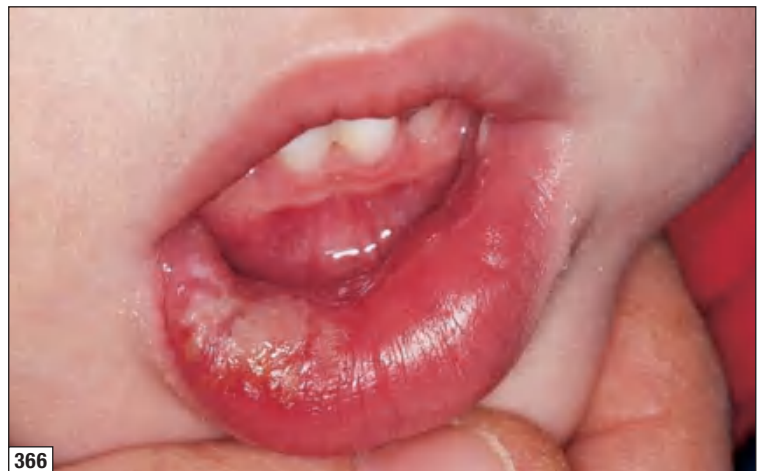

Figure 366. Ulcer from biting an anesthetised lower lip.

IMPETIGO

Impetigo (Fig. 367) is a common bacterial infection of the skin in children caused by *Staphylococcus aureus* and sometimes *Streptococcus pyogenes*, either alone or in combination. Multiple sticky golden-brown pruritic lesions are the classic features. Previous sites of trauma and insect bites, in addition to hot humid weather and poor hygiene, are all predisposing factors.

The face, including perioral skin, and extremities are the usual sites of involvement. The nonbullous form of the disease is the most common form of the disease, which may be treated by topical antimicrobial agents. The bullous form is more extensive and results in collapsed bullae covered by a golden crust. Cervical lymphadenopathy may be seen.

Diagnosis

Diagnosis is clinical, but microbiology may be required.

Management

Improved general hygiene is necessary to avoid spread. Topical antibiotic treatment that is effective against causative bacteria is the first line of treatment for the nonbullous form of the disease. Children who have widespread disease or the bullous form of impetigo require systemic antibiotics effective against both *S. pyogenes* and penicillin-resistant *S.*

aureus. Children should be referred to a physician for the management of more severe infections because serious complications, such as acute glomerulonephritis, may be a rare sequela. Treatment options are given in Table 23.

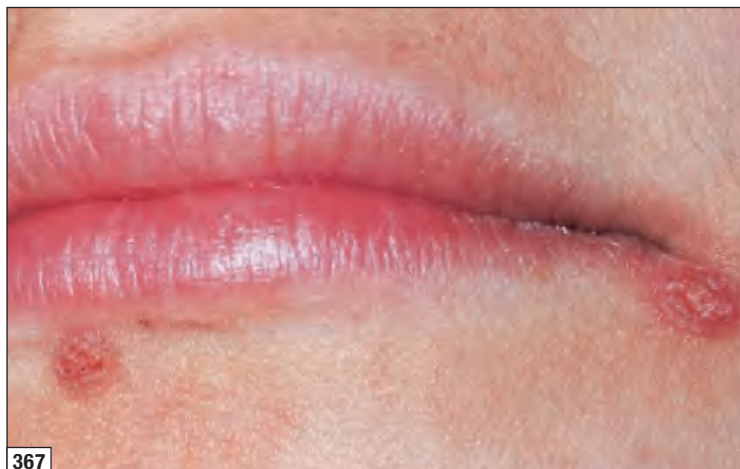

Figure 367. Perioral impetigo was misdiagnosed as angular cheilitis, which had not responded to both intraoral and extraoral topical antifungal agents.

Table 23. Treatment options for nonbullous impetigo

Topical antimicrobial agent

Drug	Mupirocin (Bactroban) 2% ointment
Dispense	15 g tube
Directions for use	Apply to affected area three times daily for 5 days.
Pediatric significance	This topical agent is often preferred to systemic antibiotics when lesions are localized because of the emergence of antibiotic drug resistance in children. Mupirocin applied to the nares twice each day for 10 days markedly reduces <i>S. aureus</i> carriage in the nose for as long as 1 year, which may be a source for recurrent infections. It is also effective for treating other perioral conditions such as folliculitis, minor wounds, burns, secondarily infected herpetic lesions and irritation on the skin from chronic lip sucking habits. Prolonged use may result in fungal overgrowth. Use systemic antimicrobial for widespread or bullous impetigo.
Drug	Fusidic acid (UK: Fucidin) 2 % cream
Dispense	15 g tube
Directions for use	Apply to affected area three times daily for 5 days.
Pediatric significance	Fusidic acid is active against staphylococci.

INFECTIOUS MONONUCLEOSIS (PAUL–BUNNELL POSITIVE GLANDULAR FEVER)

Infectious mononucleosis (Figs 368, 369) is caused by Epstein–Barr virus (EBV). More common in developed countries teenagers and young adults than in young children, the incubation of 30–50 days is followed by fever, sore throat and lymph node enlargement. Mouth ulcers may be seen together with faucial edema and tonsillar exudate. There is severe dysphagia and faucial edema, which rarely obstructs the airway.

Palatal petechiae, especially at the junction of the hard and soft palate, are almost pathognomonic of infectious mononucleosis, but can be seen in other infections such as HIV and rubella, and in noninfective causes of thrombocytopenia.

A feature that may suggest infectious mononucleosis is the occurrence of a rash if the patient is given ampicillin or amoxicillin (this may also be seen in lymphoid leukemias). A few patients develop a maculopapular rash even if not taking synthetic penicillins. The rash is often morbilliform and does not represent penicillin allergy.

Epstein–Barr virus may also cause persistent malaise, and has associations with Duncan’s disease (X-linked lymphoproliferative syndrome), Burkitt’s lymphoma and other neoplasms and hairy leukoplakia.

Diagnosis

Diagnosis is supported clinically by hematology and serology (Monospot or Paul–Bunnell tests).

Management

No specific antivirals are available though aciclovir may have some effect. Oral hygiene must be improved. Symptoms may be controlled with topical anesthetics (benzylamine oral rinse or spray). A chlorhexidine mouthwash may also aid healing.

KERATOSIS

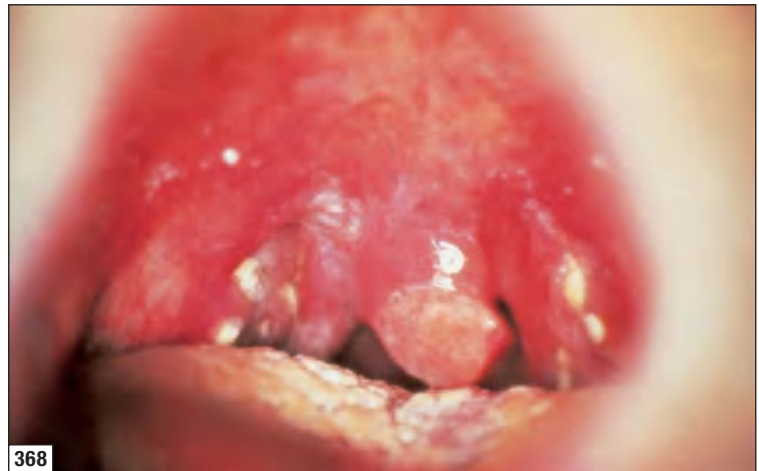Keratosis (Fig. 370) is an intraoral callus and consists of asymptomatic white adherent patches with a smooth or rough surface. It is located in areas of chronic irritation, usually adjacent to teeth. Improper toothbrushing, orthodontic appliances or a fractured tooth or restoration are common causes. Similar lesions may develop if a child chronically bites the cheek, lips or sides of the tongue and are referred to as cheek-biting keratosis. Tobacco or snuff use may induce keratosis.

Diagnosis

Diagnosis is clinical.

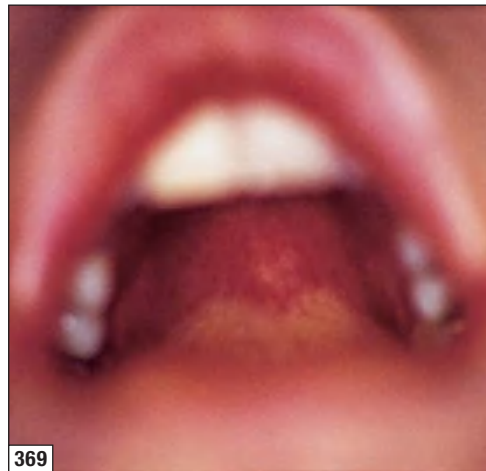Management

Reassurance about the condition is helpful. Identify and eliminate the source of the irritation and the lesion will resolve.



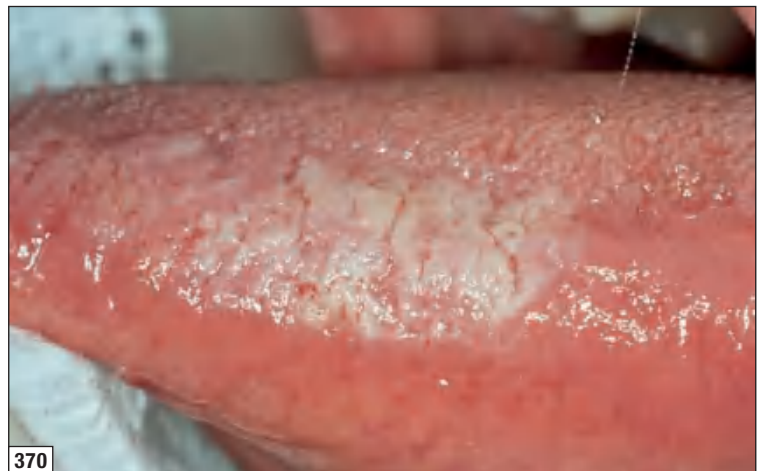368

Figure 368. Faucial edema, exudate and ulceration in infectious mononucleosis.



369

Figure 369. Infectious mononucleosis palatal petechiae.



370

Figure 370. Keratotic patch of lateral tongue from fractured tooth.

LANGERHANS CELL HISTIOCYTOSIS

Langerhans cell histiocytosis (LCH; Figs 371–374) is a group of disorders, formerly termed histiocytosis X, arising from Langerhans cells.

Letterer–Siwe disease is an acute disseminated and usually lethal form of LCH seen in children under the age of 3 years. There are bone lesions, mucocutaneous lesions, fever, lymphadenopathy and hepatosplenomegaly.

Hand–Schüller–Christian disease appears at 3–6 years of age with osteolytic jaw lesions and loosening of teeth (floating teeth), diabetes insipidus and exophthalmos.

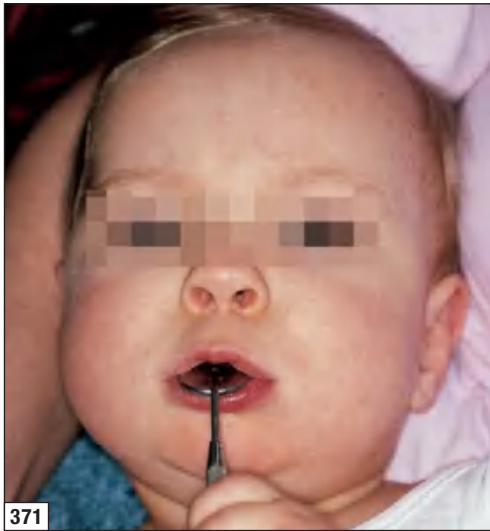Eosinophilic granuloma is a localized benign form of LCH typically seen in older patients and in which there are painless osteolytic bone lesions and sometimes mouth ulcers. The affected teeth may loosen.

Diagnosis

Diagnosis is clinical, supported by imaging and lesional biopsy.

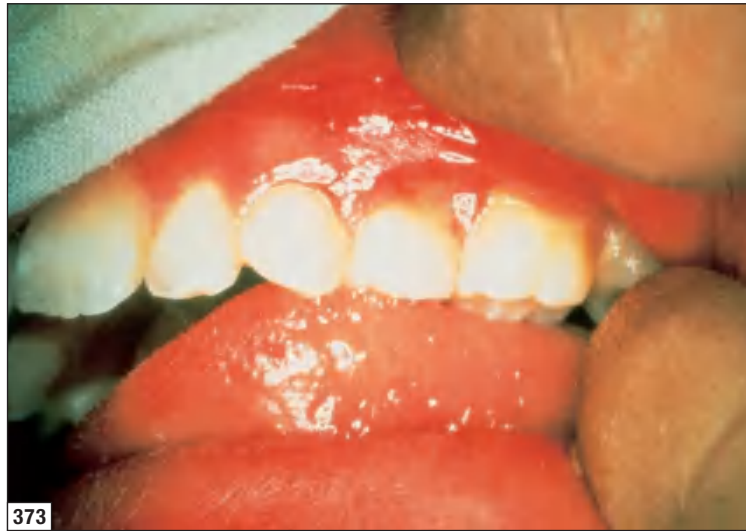Management

Medical care is required. Management depends on the type of LCH, and includes surgery, radiotherapy and chemotherapy.



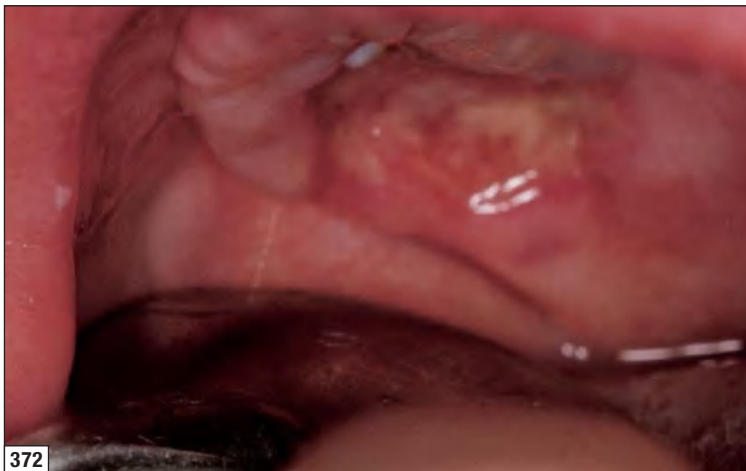371

Figure 371. Facial swelling in Langerhans cell histiocytosis.



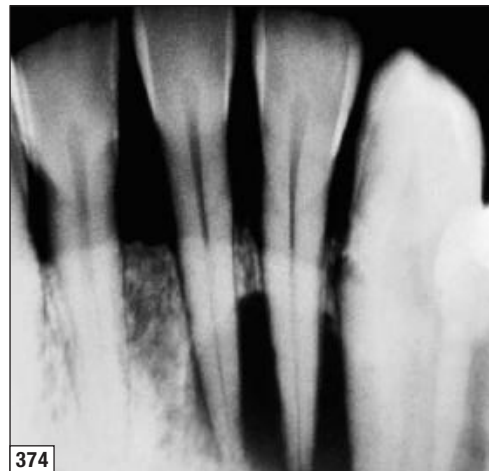373

Figure 373. Gingival ulceration in Langerhans cell histiocytosis.



372

Figure 372. Palatal swelling in Langerhans cell histiocytosis.



374

Figure 374. Radiolucent lesion in ('floating teeth') Langerhans cell histiocytosis.

LICHENOID LESIONS

Lichen planus (Figs 375–377) is rare in children. It is a mucocutaneous disorder characterized in some by oral white lesions and sometimes genital lesions and/or an itchy rash mainly on the wrists and ankles.

The etiology of oral lichen planus is unclear though there is a T lymphocyte attack on the stratified squamous epithelia. Usually no etiological factor is identifiable, but a minority of cases are related to:

- *Drugs* producing lichen-planus-like (lichenoid) lesions include anti-hypertensives, antidiabetics, gold salts, nonsteroidal anti-inflammatory agents, antimalarials and other drugs rarely used in children.
- *Reactions to materials*, particularly amalgam, stainless steel crowns and orthodontic appliances.
- *Graft versus host disease*.

Chronic active hepatitis and hepatitis C in southern Europe and Japan although there is a much lower prevalence of liver disease in lichen planus in the UK and in the USA.

The oral lesions are usually white and may be asymptomatic or may cause soreness, especially if erosive. Typically the lesions are bilateral and occur mainly on the posterior buccal (cheek) mucosa or tongue.

Presentations include:

- a network of raised white lines or striae (reticular pattern)
- white papules
- white plaques, simulating leukoplakia

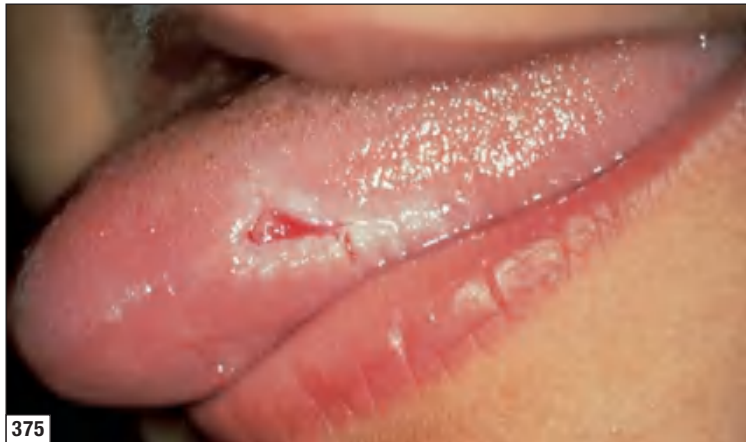

Figure 375. Lichen planus (erosive) on the tongue.

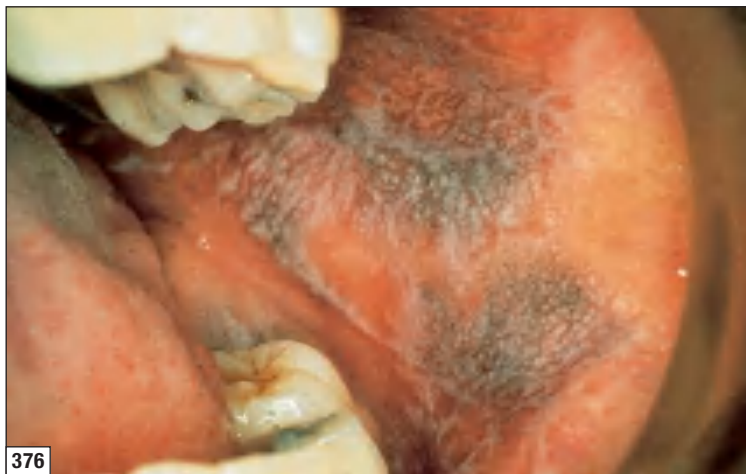

Figure 376. Lichen planus with pigmentary incontinence in the buccal mucosa of an Asian patient.

- erosions, which are less common, persistent, irregular and painful, with a yellowish slough.
- red atrophic areas.

Lichen planus is one of the most common causes of desquamative gingivitis and may also affect the:

- skin – with itchy (pruritic), purple, polygonal, papules (small raised rash) especially on the wrists
- genitals – with white or erosive lesions
- nails – ridging
- hair – scarring alopecia.

Lichenoid lesions resemble lichen planus, but may:

- be unilateral
- be associated with erosions
- resolve with discontinuation of the offending drug.

Diagnosis

The history and clinical appearance are usually highly indicative of the diagnosis, but lesional biopsy for histology and perilesional biopsy for immunostaining are often indicated, particularly to exclude:

- lupus erythematosus
- leukoplakia (keratosis)
- other rare childhood epithelial diseases.

Management

Systemic disease, drugs, or local possible predisposing factors should be excluded. If drugs are implicated, the physician should be consulted about possible changes in therapy. If amalgams might be implicated, it can be worth considering a trial, changing restorations lying adjacent to lesions for another restorative material. Alternatively, fabrication of a soft acrylic splint that covers the restorations or appliances for a short period of time may help to determine if the dental materials are a contributing factor. Patch testing may be a guide to this decision, but is not reliably predictive.

Symptomatic oral lichen planus may respond to topical corticosteroids usually the more potent agents (such as beclomethasone dipropionate, fluocinonide). Recalcitrant lesions can be managed with intralesional corticosteroids or topical ciclosporine. Systemic immunosuppressive agents, including corticosteroids, azathioprine, ciclosporine, hydroxychloroquine or dapsone or, rarely, vitamin A derivatives, or thalidomide are reserved for use in patients who have recalcitrant or widespread disease.

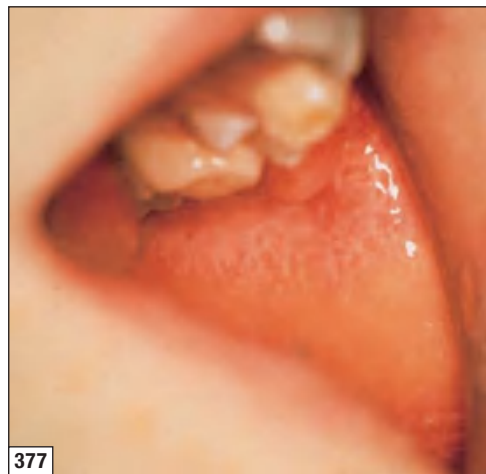

Figure 377. Lichen planus in a 10-year-old child.

LINGUAL PAPILLITIS

Transient lingual papillitis

Transient lingual papillitis (Fig. 378) represents a nonspecific inflammation of the fungiform papillae with a predilection for the anterior and lateral borders of the tongue. One or more papillae have a bright red or white surface and are very tender. Trauma, oral habits, food sensitivity and irritation from oral hygiene products may trigger this symptomatic condition. Most cases resolve as suddenly as they appear.

Diagnosis

Diagnosis is clinical.

Management

If possible identify the cause to prevent recurrences. Topical anesthetics or coating agents are recommended for pain relief, but topical corticosteroids may be needed for more severe cases.

Foliate papillitis.

The size and shape of the foliate papillae on the posterolateral margins of the tongue are variable. These papillae occasionally swell and sometimes become sore if irritated mechanically or if there is an upper respiratory infection (foliate papillitis) (see Figure 26).

Diagnosis

Diagnosis is clinical.

Management

Reassurance only is required.

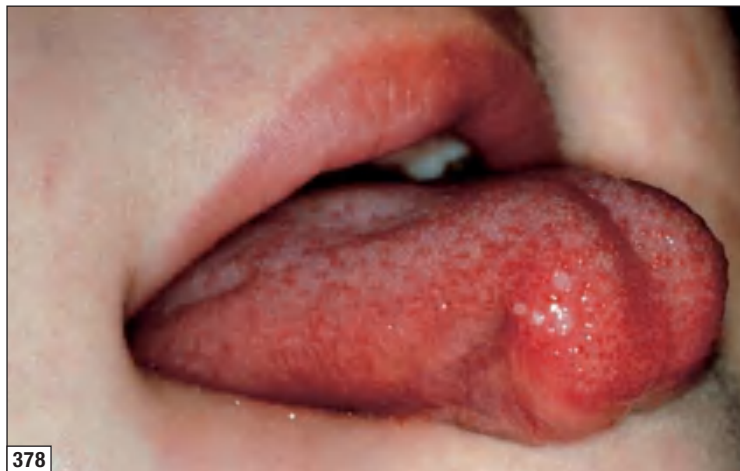

Figure 378. This child complained periodically about a tender tongue as a result of transient lingual papillitis on the lateral border.

LIP FISSURES

Lip fissures (Fig. 379) are uncommon. Most are seen in males, typically median in the lower lip and chronic, causing discomfort and may bleed from time to time. A hereditary predisposition for weakness in the first branchial arch fusion seems to exist.

Lip fissures are common in Down syndrome and the lips may also crack in this way if swollen (e.g. in cheilitis granulomatosa, oral Crohn's disease). Otherwise the etiology may be obscure, although sun, wind, cold weather and smoking are thought to predispose. A lip fissure may develop in the lip when a patient, typically a child, is mouthbreathing. Contrary to the clinical impression that fissures are seen mainly in the lower lip there is a higher prevalence in the upper lip.

Diagnosis

The diagnosis is clinical.

Management

Predisposing factors should be managed. Bland creams may help the lesion heal spontaneously. Otherwise, low potency topical corticosteroid creams, 0.5% balsam of Peru, salicylic acid, and topical antimicrobials (3% aureomycin, 2% mupirocin or sulfonamides) seem less effective than excision or cryosurgery. Laser ablation is also effective.

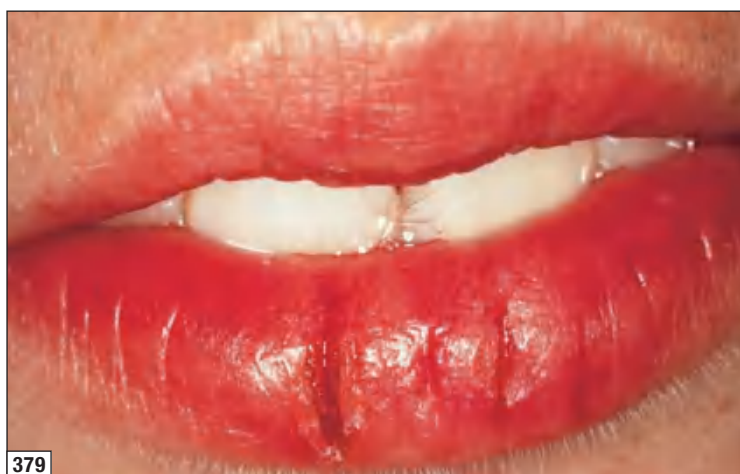

Figure 379. Lip fissure.

LUPUS ERYTHEMATOSUS

Discoid lupus erythematosus (DLE; Fig. 380) is a chronic and recurrent disorder primarily affecting the skin and characterized by sharply circumscribed macules and plaques displaying erythema, follicular plugging, scales, telangiectasia, and atrophy. Lesions are most frequent on the malar prominences, bridge of the nose, scalp and external auditory canals, and may persist or recur for years. Mucous membrane involvement may be prominent, especially in the mouth, where lesions mimic lichen planus.

Diagnosis

Because the cutaneous lesions of DLE and systemic lupus erythematosus may be identical, a patient presenting with typical discoid lesions must be evaluated to determine whether systemic involvement is present. Although DLE is usually limited to the skin, up to 10% of patients eventually develop varying degrees of systemic involvement; however, usually this is not severe and may only be indicated by a positive antinuclear antibody test. Leukopenia and mild, transitory systemic manifestations (e.g. arthralgias) are common.

Diagnostic studies should include biopsy from the active margin of a lesion, full blood picture, erythrocyte sedimentation rate (or plasma viscosity), antinuclear factors and renal function studies. Antibodies against double-stranded DNA are almost invariably absent in DLE.

Management

Topical corticosteroids are the main treatment used. Antimalarials (e.g. hydroxychloroquine 100 to 200 mg/day) are very useful. In resistant cases, higher dosages or combinations (e.g. hydroxychloroquine 200mg/day plus quinacrine 50–100 mg/day) may be required. Liberal use of sunscreen products helps to prevent exacerbations of the skin lesions.

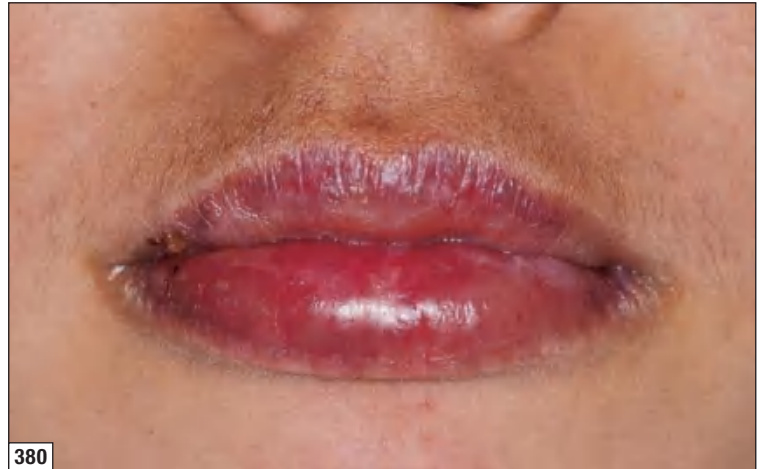

Figure 380. Lupus erythematosus of the lips.

LYMPHOEPITHELIAL CYST

Lymphoepithelial cyst (Fig. 381) is an uncommon lesion and presents as a yellowish-white nodule that occasionally enlarges and drains. The cystic contents vary from cheesy thick material to creamy white and fluid-like, resembling purulent exudate. The floor of the mouth and posterior tongue are the most common sites, but they may be found wherever there is oral lymphoid tissue.

Diagnosis

Diagnosis is clinical, supported by biopsy.

Management

Reassurance is all that is required. Excision is recommended, if symptomatic or if another more serious condition cannot be excluded.

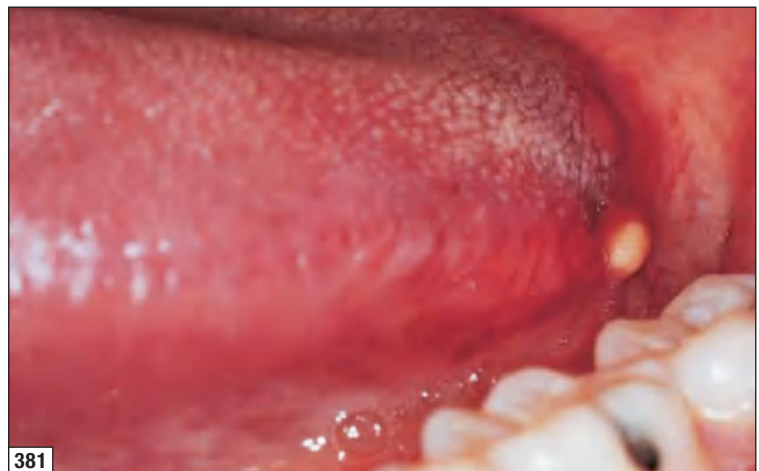

Figure 381. Lymphoepithelial cyst of the posterior lateral border of the tongue. Persistent tenderness of the tongue following an upper respiratory infection was the chief complaint of this adolescent.

LYMPHOMA

African Burkitt's lymphoma (Fig. 382) is associated with Epstein–Barr virus (EBV) and typically affects children before the age of 8–13 years. The jaws, particularly the mandible, are common sites of presentation. Massive swelling, which ulcerates in the mouth, may be seen. Radiographically, the teeth may appear to be 'floating in air'.

The association of non-African Burkitt's lymphoma (Figs 383–385) with EBV is less common and the disease occurs less frequently than the African form. The disease may cause oral pain, paresthesia or increasing tooth mobility. The jaws are less frequently involved in this type of Burkitt's lymphoma. Discrete radiolucencies in the lower molar region, destruction of lamina dura and widening of the periodontal space may be seen on imaging.

Other lymphomas are rare in children, but with the increased incidence of HIV disease, are becoming more common.

Diagnosis

Diagnosis is clinical, supported by hematology, imaging and lesional, lymph node and bone marrow biopsy.

Management

Medical care is required. Chemotherapy and often radiotherapy are indicated.

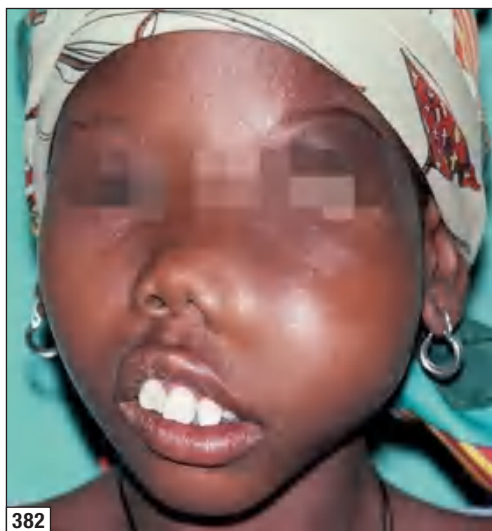

Figure 382. African Burkitt's lymphoma showing maxillary involvement.

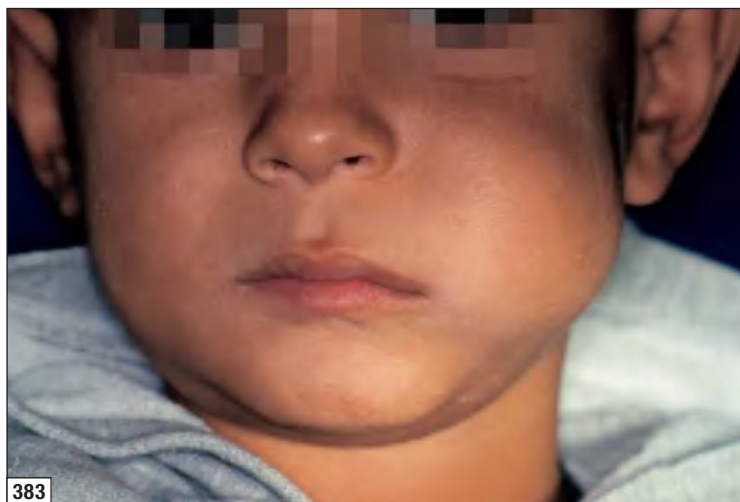
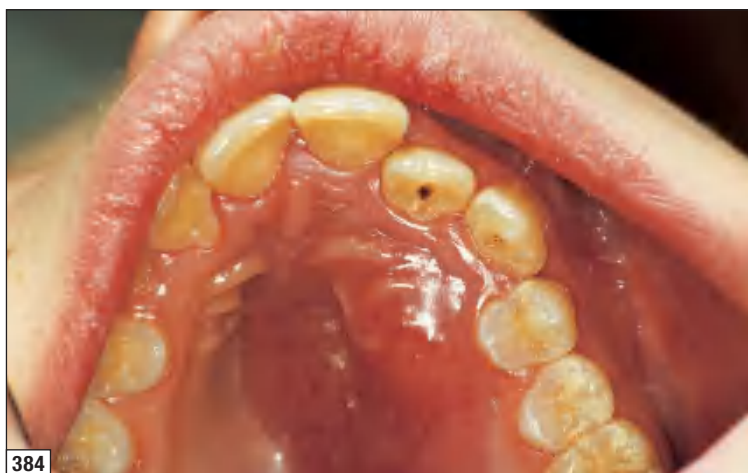
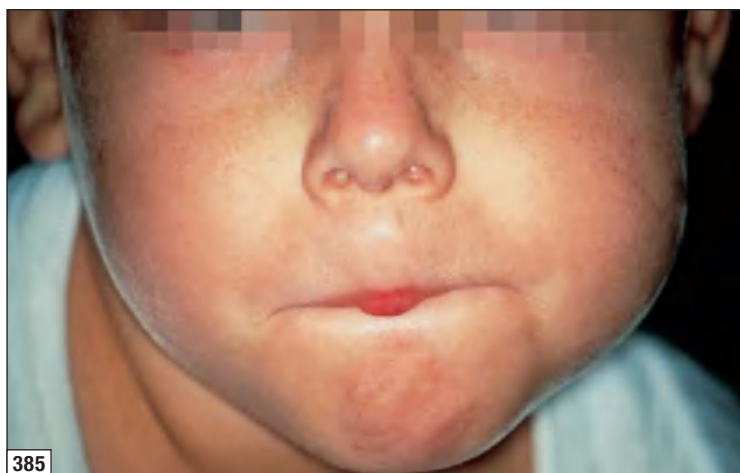Figure 383. African Burkitt's lymphoma showing maxillary involvement.



Figures 384, 385. Non-African Burkitt's lymphoma mimicking a dental abscess.



MACROGLOSSIA AND MICROGLOSSIA

The tongue varies enormously in size, but is particularly large if inflamed or edematous in angioedema, if infiltrated such as by hemangioma, lymphangioma or various deposits, or in some conditions such as Down syndrome. The main causes of macroglossia and microglossia in childhood are listed in Table 24.

Diagnosis

Diagnosis is clinical, supported by genetics, biochemistry and lesional biopsy, if needed.

Management

Reassurance is the only treatment necessary in most cases. If a tumor is causing the condition, then surgical resection may be indicated. If marked malocclusion develops then orthodontic treatment and recontouring of the tongue may be necessary. Medical management is needed for endocrine disease.

Table 24. Main causes of macroglossia and microglossia in childhood

Macroglossia

Angioedema
Amyloidosis
Angiomas (hemangiomas, lymphangiomas)
Beckwith–Wiedemann syndrome
Cretinism (congenital hypothyroidism)
Down syndrome
Mucopolysaccharidoses

Microglossia

Aglossia–adactylia syndrome
Möbius' syndrome

MEASLES (RUBEOLA)

Measles (Figs 386, 387) is an acute contagious infection with a paramyxovirus. The incubation period of 7–10 days is followed by fever, rhinitis, cough, conjunctivitis (coryza) and then a red maculopapular rash, which appears initially on the forehead and behind the ears, and spreads over the whole body.

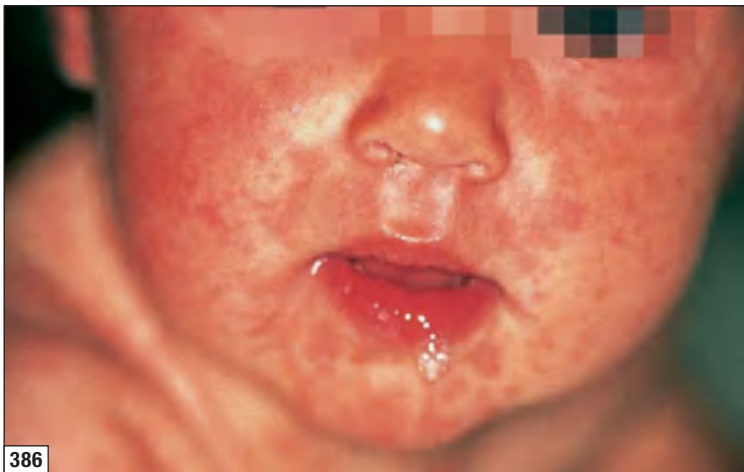Koplik's spots – small, whitish, necrotic lesions, said to resemble grains of salt – are found in the buccal mucosa and occasionally involve the conjunctiva or genitalia, preceding the measles rash by 1–2 days (Fig. 387).

Diagnosis

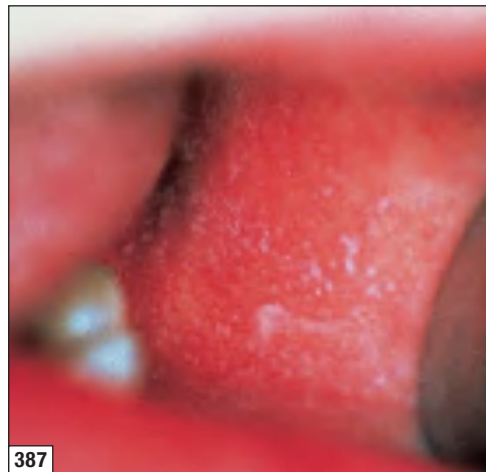Diagnosis is clinical.

Management

Medical care is required.



386



387

Figures 386, 387. Measles.

MEDIAN RHOMBOID GLOSSITIS (CENTRAL PAPPILARY ATROPHY)

Median rhomboid glossitis (Fig. 388) is a red depapillated rhomboidal area in the center of the tongue dorsum, now believed to be associated with candidosis. Formerly thought to be caused by persistence of the tuberculum impar it is predisposed to by:

- smoking
- appliance-wearing
- corticosteroid sprays and inhalers
- HIV infection.

Diagnosis

Diagnosis is clinical, supported occasionally by lesional biopsy. Biopsy may show pseudoepitheliomatous hyperplasia, but the condition is not potentially malignant.

Management

Median rhomboid glossitis may respond to antifungals and to the cessation of smoking.

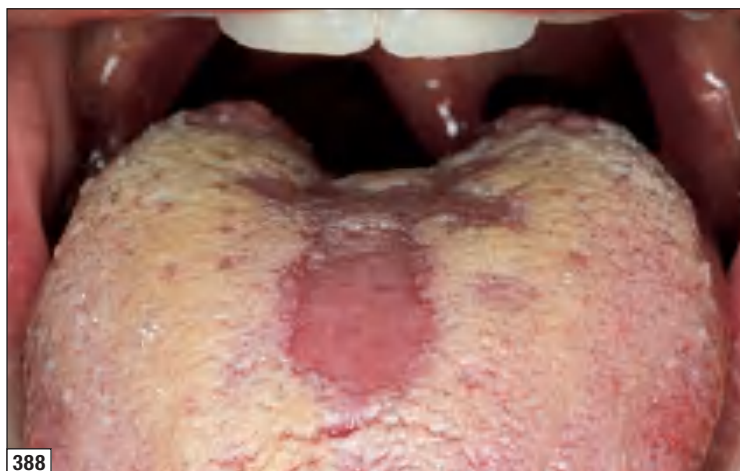

Figure 388. Median rhomboid glossitis.

MELANOTIC MACULE

Although uncommon, the melanotic macule (Figs 389, 390) is the most frequently diagnosed pigmented lesion in whites and is similar to the cutaneous freckle. The lip vermilion, buccal mucosa and gingiva are the most common sites of occurrence. Typically, it is a solitary tan, gray or brown macule that is oval and has a smooth, uniformly pigmented surface.

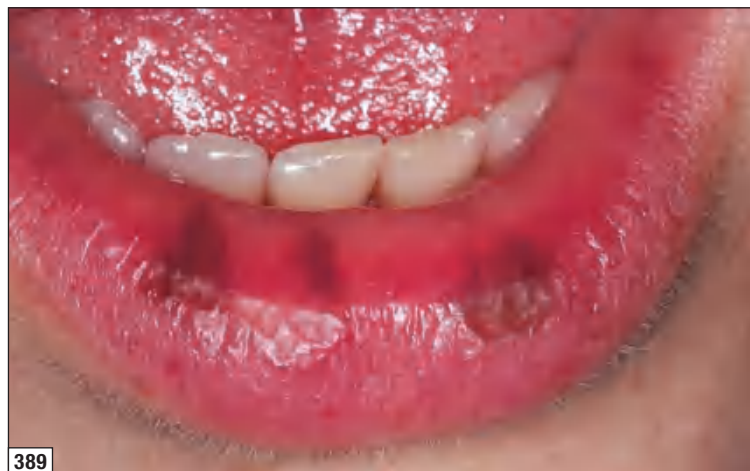

Figure 389. Melanotic macules.

Diagnosis

Diagnosis is clinical, supported by lesional biopsy.

Management

Excision biopsy is recommended if there is a cosmetic concern or if a melanocytic nevus or more sinister lesion cannot be excluded.

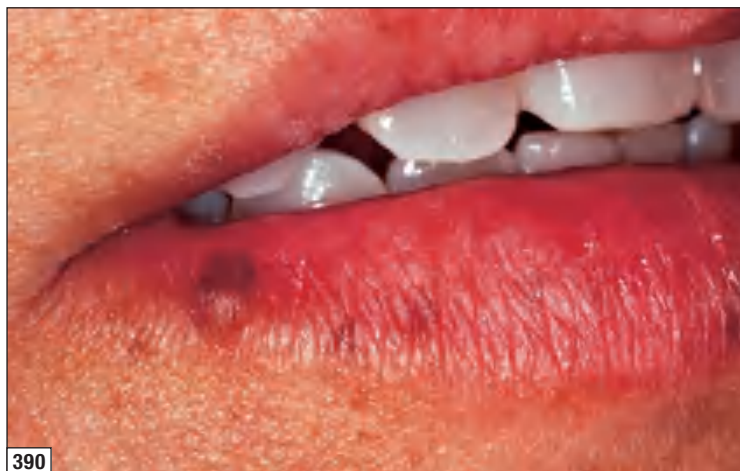

Figure 390. This adolescent female with excessive sun exposure was concerned about the increased freckling of the lips. The raised pigmented lesion represented an intradermal nevus, whereas the tiny flat areas of pigmentation are consistent with labial melanotic macules and ephelides.

MELANOCYTIC NEVUS

The melanocytic nevus (Fig. 390) is a common lesion that may be either congenital or acquired. Although the head and neck region is a common site of occurrence, the intraoral melanocytic nevus is seen infrequently. It appears as a solitary circumscribed gray, brown or black macule or nodule on the hard palate, gingiva or in the buccal mucosa. Occasionally, they may be nonpigmented and resemble a fibroma.

Diagnosis

Diagnosis is clinical, supported by lesional biopsy.

Management

Excision biopsy is recommended because of the very low potential risk for development of a melanoma from a pre-existing lesion.

MOLLUSCUM CONTAGIOSUM

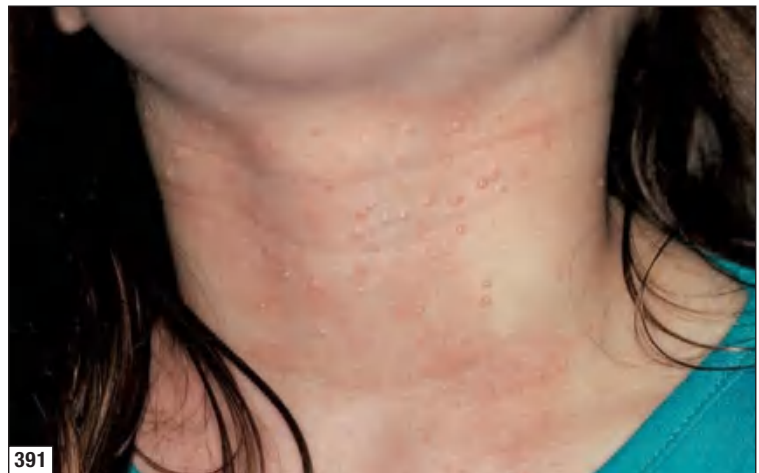Molluscum contagiosum (Figs 391, 392) is a pox virus infection producing characteristic umbilicated nontender papules, typically on the skin of male children. Oral lesions are very rare, except on the lip vermillion, whereas facial lesions are more common. Florid cases are seen in children who have HIV disease.

Diagnosis

Diagnosis is clinical.

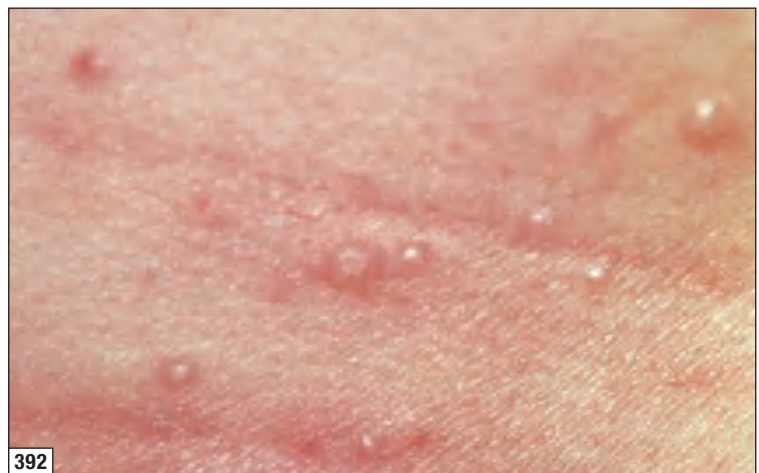Management

Management involves excision, cryotherapy or cauterization with chromic acid. Spontaneous resolution may occur.



391

Figure 391. Molluscum contagiosum on the neck.



392

Figure 392. Molluscum contagiosum showing umbilicated papules.

OROFACIAL GRANULOMATOSIS

Orofacial granulomatosis (OFG; Fig. 393) is an uncommon, chronic swelling of the lip as a result of granulomatous inflammation. The cause is unknown, but there may be adverse reactions to various food additives such as cinnamic aldehyde, butylated hydroxyanisole or dodecyl gallate (in margarine) or menthol (in peppermint oil), although these reactions are not always relevant.

The onset is usually in young adult life and has no gender or racial predilection. Labial swelling occurs in about 75% and facial swelling in 50% of patients. The earliest manifestation is sudden diffuse or occasionally nodular nontender swellings of the lip or face, involving in decreasing order of frequency, the upper lip, the lower lip and one or both cheeks. Less commonly the forehead, the eyelids or one side of the scalp may be involved. The attacks are sometimes accompanied by fever and mild constitutional symptoms, including headache and even visual disturbance. Lingual, palatal, gingival and buccal involvement may also occur. At the first episode the edema typically subsides completely in hours or days, but after recurrent attacks the swelling may persist, and slowly increases in degree. The swelling eventually becomes permanent. There may be splitting of the lips and angular stomatitis. Recurrences can range from days to years, but once chronicity is established, the enlarged lip appears cracked and fissured with reddish brown discoloration and scaling. The fissured lip becomes painful. It eventually acquires the consistency of firm rubber. After some years, the swelling may very slowly regress.

Ulcers classically involve the buccal sulcus, where they appear as linear ulcers, often with granulomatous masses flanking them. Mucosal lesions also include thickening and folding of the mucosa to produce a 'cobblestone' type of appearance and mucosal tags. Purple granulomatous enlargements may appear on the gingiva.

Noncaseating granulomas and lymphedema may be seen on biopsy, but the granulomas tend to be sparse and deep and close to the muscle. It is unclear where in the spectrum of Crohn's disease/sarcoidosis/allergy/infection these lesions (and related conditions such as Melkersson–Rosenthal syndrome (p. 33) and granulomatous cheilitis) lie.

Diagnosis

The many causes of edema of the lips make the diagnosis one based on exclusion, on clinical signs and on histological examination. Biopsy of the swollen lip or facial tissues is indicated, but during the early stages shows only lymphedema and perivascular lymphocytic infiltration. However, although the histological changes are not always conspicuous or specific in many cases of OFG. In some cases of long duration, the infiltrate becomes more dense and pleomorphic and small focal granulomas are formed, indistinguishable from those of Crohn's disease or sarcoidosis. In some cases, small granulomas occur in the lymphatic walls.

Investigation of the gastrointestinal tract (endoscopy, radiography and biopsy) is mandatory to exclude Crohn's disease. Investigations such as chest radiography, serum angiotensin converting enzyme and a gallium scan may be required to exclude sarcoidosis.

Patch tests may be indicated to exclude reactions to various food-stuffs or additives.

Management

Reactions to dietary components should be sought and possible provoking substances/antigens avoided. Elimination diets may be warranted in some patients who have orofacial granulomatosis. Conservative management has included intralesional corticosteroid injections, nonsteroidal anti-inflammatory agents, antibiotics, antimalarials and mast cell stabilizers.

Clofazimine appears to help, in a dose of 50 mg twice daily for 10 days, then twice weekly for 4 months. Clofazimine appears to be most effective during the early stages and works by clearing granulomas. Metronidazole may also produce a resolution of granulomatous cheilitis.

Intralesional corticosteroid injections may reduce the swelling. An injection of up to 5 ml triamcinolone (10 mg/ml) into the lips after local analgesia may be effective. The injections may have to be repeated every 4–6 months once a response plateau has been reached. Systemic corticosteroids are rarely indicated, but may help if there is an associated facial palsy.

Azathioprine, dapsone, sulfapyridine or salazopyrine may be helpful.

Other therapies that have occasionally been helpful include penicillin, metronidazole, minocycline, erythromycin and ketotifen.

Surgery and irradiation have also been used. Surgery alone is relatively unsuccessful and the best results are from reduction cheiloplasty with intralesional triamcinolone and systemic tetracycline. The steroid injections must be given periodically after the surgery or there may be an exaggerated recurrence.

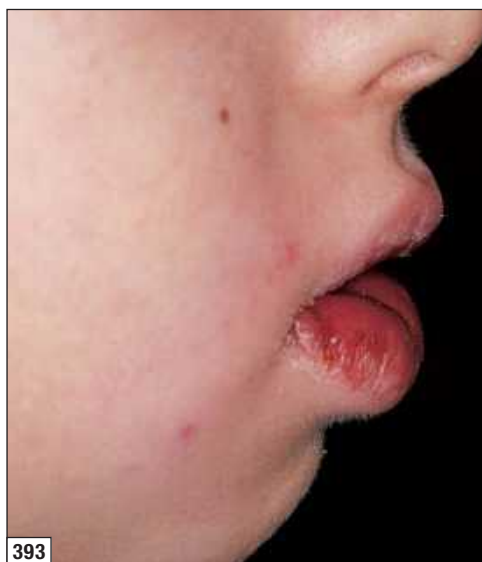

Figure 393. Orofacial granulomatosis.

PAPILLARY HYPERPLASIA

Papillary hyperplasia is a reactive lesion of the hard palate consisting of multiple pink or red papules or nodules that are asymptomatic. It is often associated with a concurrent candidal infection. In children this lesion is seen under palatal coverage orthodontic appliances or temporary partial appliances to replace missing teeth. Occasionally this condition is observed in children who are mouthbreathers with a narrow palate.

Diagnosis

Diagnosis is clinical, occasionally supported by microbiology.

Management

Treatment involves managing the superimposed candidal infection with antifungal agents, including the removable appliance. Surgical palatal tissue recontouring may be necessary. Oral hygiene must be improved.

PEMPHIGUS VULGARIS

Pemphigus (Figs 394, 395) is rare in children, but may present with oral erosions, lesions in other mucosae or skin blisters. Pemphigus is an autoimmune disease with antibodies directed against desmoglein in the glycoprotein coat of epidermal and mucosal cells, which separate, forming thin-rooted blisters. The blisters quickly rupture and persist as painful erosions. Mouth lesions are an early and prominent feature. The mouth lesions may be similar to other forms of oral ulceration. Untreated pemphigus progresses remorselessly and may be fatal. Even with treatment, morbidity is severe.

Diagnosis

Diagnosis is clinical, supported by perilesional biopsy and direct immunofluorescence of the biopsy specimen and indirect immunofluorescence of patient blood.

Management

Medical care is required. Systemic corticosteroids are typically required. Oral hygiene must be improved. Symptoms may be controlled with topical anesthetics (benzylamine oral rinse or spray). A chlorhexidine mouthwash and topical corticosteroids may also aid healing.

PERIODIC FEVER, APHTHOUS STOMATITIS, PHARYNGITIS AND CERVICAL ADENITIS SYNDROME (PFAPA)

Periodic fever is an idiopathic condition that may occur with tonsillitis. It resolves spontaneously and long-term sequelae are rare. Corticosteroids are highly effective symptomatically; tonsillectomy and cimetidine treatment have been effective in a few patients with this syndrome (see Aphthae, p. 132).

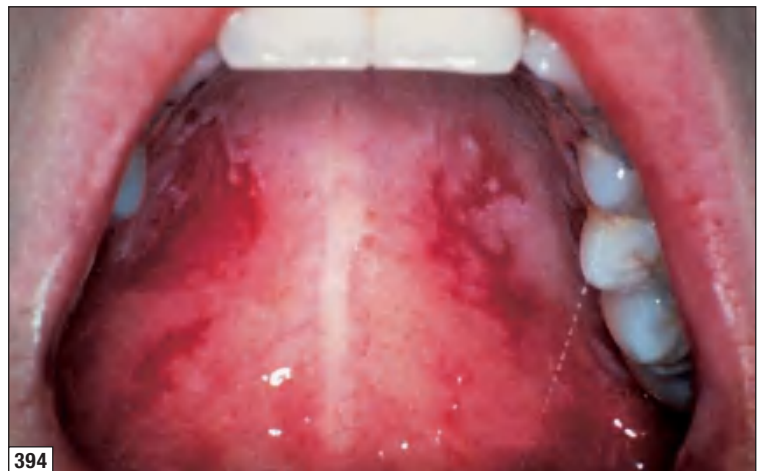


Figure 394. Pemphigus affecting the palate of a teenager.

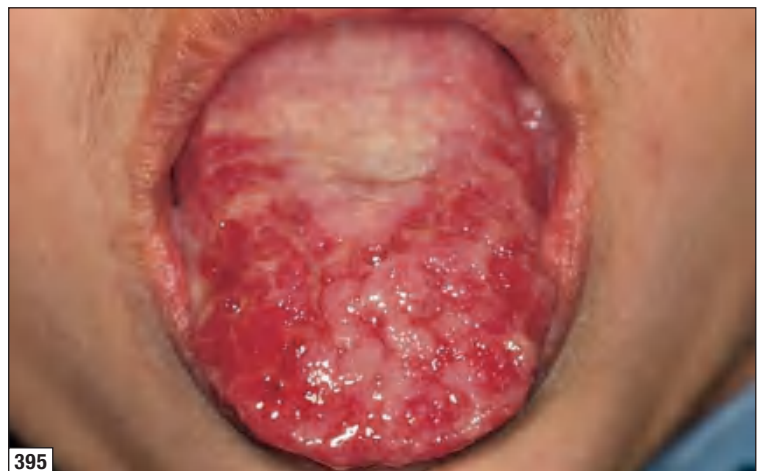

Figure 395. Pemphigus.

PYOSTOMATITIS VEGETANS

Oral lesions termed pyostomatitis vegetans (Fig. 396) are deep fissures, pustules and papillary projections. Less than 50 cases have been recorded and most patients have had ulcerative colitis or Crohn's disease.

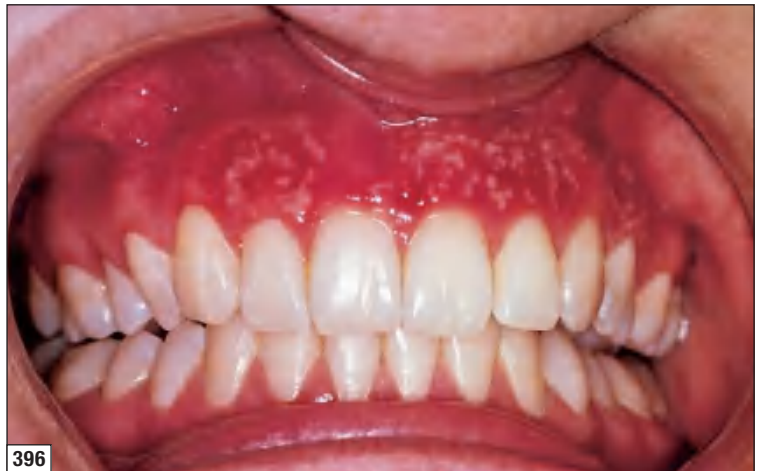Reported oral lesions in ulcerative colitis include aphthae, chronic oral ulcers and pyostomatitis vegetans. The course of these lesions tends to follow that of the bowel disease.

Diagnosis

Diagnosis is clinical, supported by hematology, imaging and lesional biopsy.

Management

Medical care is required. Oral hygiene must be improved. Symptoms may be controlled with topical anesthetics (benzylamine oral rinse or spray). A chlorhexidine mouthwash and topical corticosteroids may also aid healing.



396

Figure 396. Pyostomatitis vegetans in an adolescent with ulcerative colitis.

SCLERODERMA

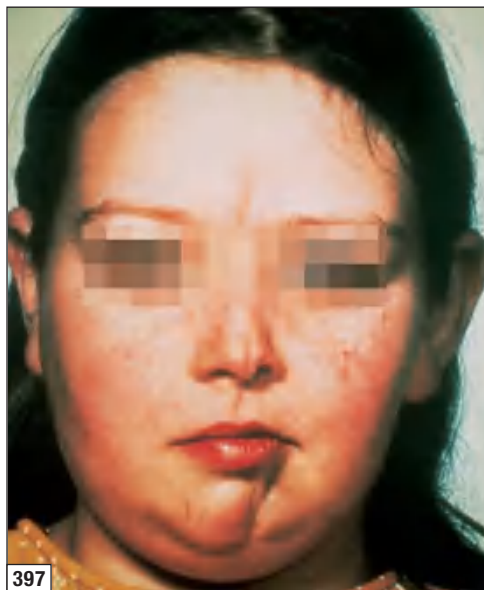Scleroderma (systemic sclerosis; Fig. 397) is rare in children, but localized scleroderma (morphea) may occasionally affect the face and lips (en coup de sabre) and may extend intraorally. In contrast to classical scleroderma, there is no widening of the periodontal ligament.

Diagnosis

Diagnosis is clinical, supported by serology (antinuclear antibodies, Scl-70 and anticentromere antibodies).

Management

Medical or surgical care is required for severe cases.



397

Figure 397. Scleroderma. En coup de sabre.

SELF-MUTILATION

Minor, subconsciously self-induced oral lesions are common, the typical examples being bruxism and cheek-biting (*morsicatio buccarum*). Other lesions may be self-inflicted when the oral mucosa is anesthetized, such as after a local anesthetic (Fig. 366) or surgery to the trigeminal nerve.

Serious deliberate self-inflicted lesions in the mouth are considerably less common than on the skin. This may be a result of an underlying need or desire for attention in patients who are emotionally disturbed or with learning disability. Although serious psychiatric disease is uncommon in children, occasional patients have later committed suicide.

The most common type of self-inflicted oral injuries reported in the past has been so-called self-extraction of teeth. Soft-tissue lesions can be produced, however, typically by picking at the gingivae with the fingernails. A diagnosis of self-inflicted injury may be difficult. It should be suspected when the lesions are:

- unlike those of any recognized disease
- of bizarre configuration with sharp outlines and in an otherwise healthy mouth
- in sites accessible to the patient.

In addition the patient may show signs that suggest emotional disturbance or may be known to be undergoing psychiatric treatment. Factitious or artefactual lesions are seen in some patients who are disturbed or with learning disability, Lesch–Nyhan syndrome (congenital hyperuricemia (Fig. 398)), Gilles de la Tourette's syndrome (tic, coprolalia and copropraxia), Munchausen syndrome, where there is sensory loss in the area and where there is congenital indifference to pain, as in familial dysautonomia (Riley–Day syndrome).

Patients with epilepsy often suffer repeated orofacial trauma causing soft tissue lacerations and scarring, and damage to teeth and/or jaws.

Diagnosis

Diagnosis is clinical. Nonaccidental injury must always be excluded.

Management

Oral hygiene must be improved. Symptoms may be controlled with coating agents or topical anesthetics (benzylamine oral rinse or spray). A chlorhexidine mouthwash may also aid healing. Medical and psychiatric care are often required.

SYPHILIS

Oral lesions of acquired syphilis (Fig. 399) are rare in children and are more common in adolescents. The primary chancre may affect the lip, tongue or palate. Lesions of secondary syphilis (mucous patches and snail track ulcers) can affect any intraoral site.

Diagnosis

Diagnosis is clinical, supported by serology and occasionally lesional biopsy.

Management

Medical care is required. Systemic antimicrobials are indicated.

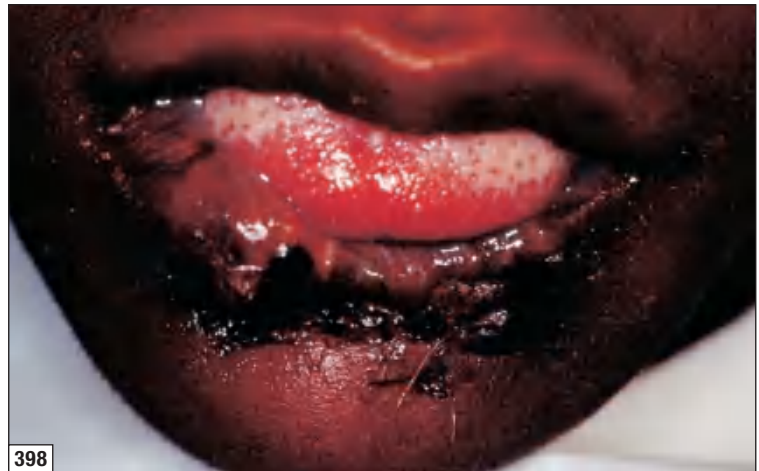

Figure 398. Chronic chewing of the lower lip resulted in severe disfigurement in this black child with Lesch–Nyhan syndrome.

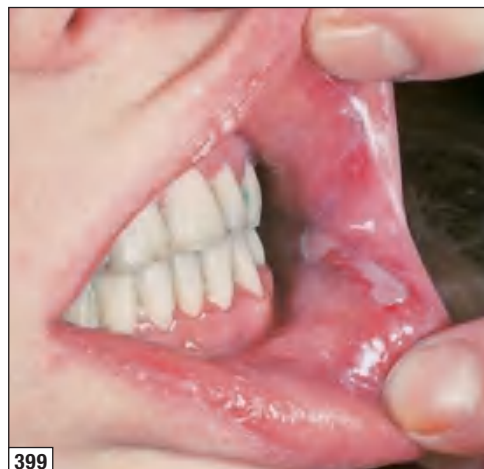

Figure 399. Mucous patches in secondary syphilis (gloves would be worn!)

TRAUMATIC ULCERS

Neonates occasionally develop an ulcer in the palate (Bednar's ulcer), which is thought may be caused by trauma, especially from forceful sucking from the nipple of the nursing bottle, breast or pacifier. Traumatic ulcers are common in children, usually caused by accidental biting, hard foods, appliances or after dental treatment or other trauma (Figs 400–403). In child abuse (nonaccidental injury), ulceration of the upper labial frenum may follow a traumatic frenal tear. Bruised and swollen lips, lacerated frenae and even fractured or subluxed teeth or fractured mandible can be features of child abuse.

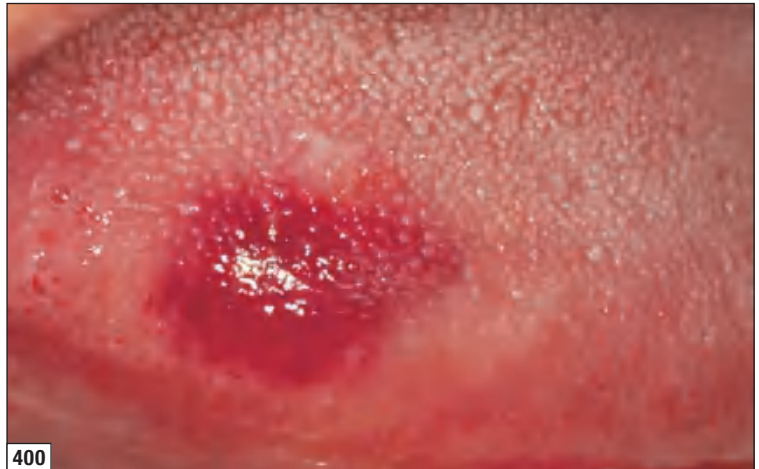The lingual frenum may be traumatized by repeated rubbing over the lower incisor teeth in children who have recurrent bouts of coughing as in whooping cough. Riga–Fede disease is caused by the repeated rubbing of the ventral tongue over the incisors in sucking infants. It is also seen in children who have neuromuscular disorders with prominent tongue thrusting habits.

Diagnosis

Diagnosis is clinical

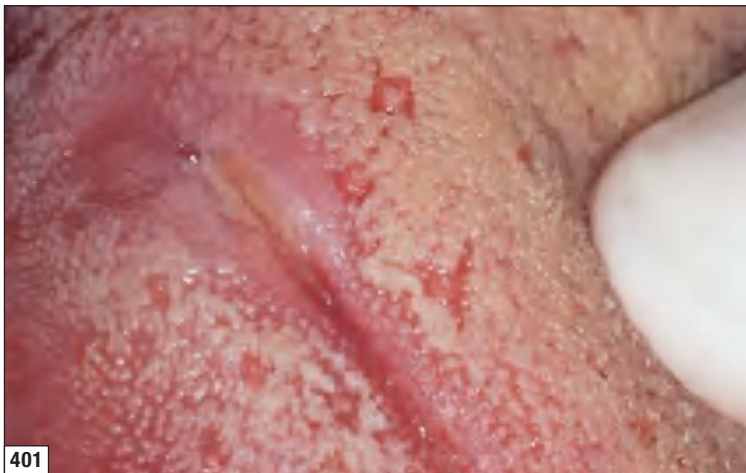Management

Oral hygiene must be improved. Symptoms may be controlled with coating agents or topical anesthetics (benzylamine oral rinse or spray). A chlorhexidine mouthwash may also aid healing.



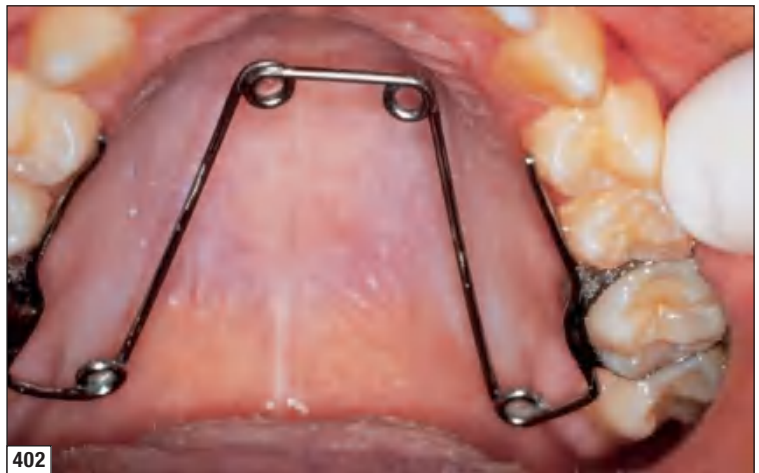
400

Figure 400. Hematoma of the lateral tongue following a traumatic insult during a soccer game.



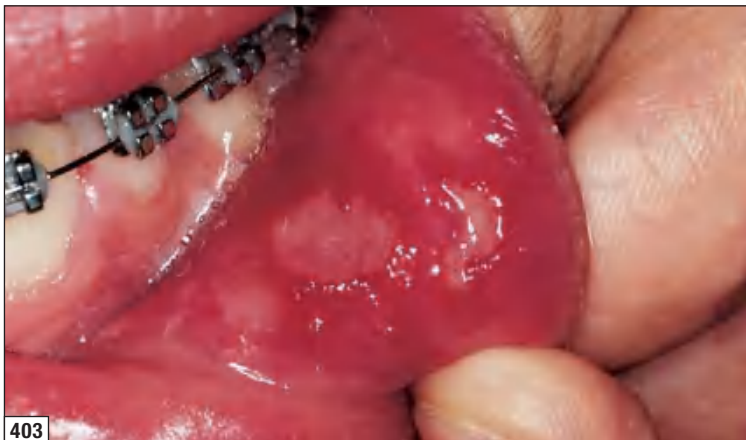401

Figure 401. A palatal expander orthodontic appliance caused a linear ulcer on the dorsal tongue, which was painful. Although the indentation from the appliance was obvious, retraction of the narrow slit was required to visualize the deep ulcer.



402

Figure 402. The responsible appliance used for the patient shown in Figure 401.



403

Figure 403. Oral ulceration caused by trauma from an orthodontic appliance.

VARICELLA-ZOSTER VIRUS INFECTIONS

Varicella (chickenpox; Figs 404–407) is a highly contagious infection caused by the varicella-zoster virus (VZV). After an incubation period of 2–3 weeks, a variably dense rash appears, concentrated mainly on the trunk and head and neck (i.e. centripetal). The typical rash goes through macular, papular, vesicular and pustular stages before crusting. The rash crops in waves over 2–4 days, so lesions at different stages are typically seen.

The oral mucosa is commonly involved, but there may be isolated lesions only. Vesicles appear, especially in the palate, and then rupture to produce painful round or ovoid ulcers with an inflammatory halo.

Maxillary or mandibular zoster (Fig. 408) is rare in childhood, but may then be associated with pain and unilateral ulceration with an ipsi-

lateral rash, and later occasionally with ipsilateral dental hypoplasia. Zoster is seen in a child mainly when the mother has suffered chickenpox during pregnancy, or the child had chickenpox in infancy, or the child is immunocompromised.

Diagnosis

Diagnosis is clinical, supported occasionally by serology or viral studies.

Management

Oral hygiene must be improved. Symptoms may be controlled with topical anesthetics (benzylamine oral rinse or spray). A chlorhexidine mouthwash may also aid healing.

Medical care is required. Antiviral treatment (aciclovir) may be indicated for healthy and immunocompromised patients. Vaccination is available for the prevention of this infection.

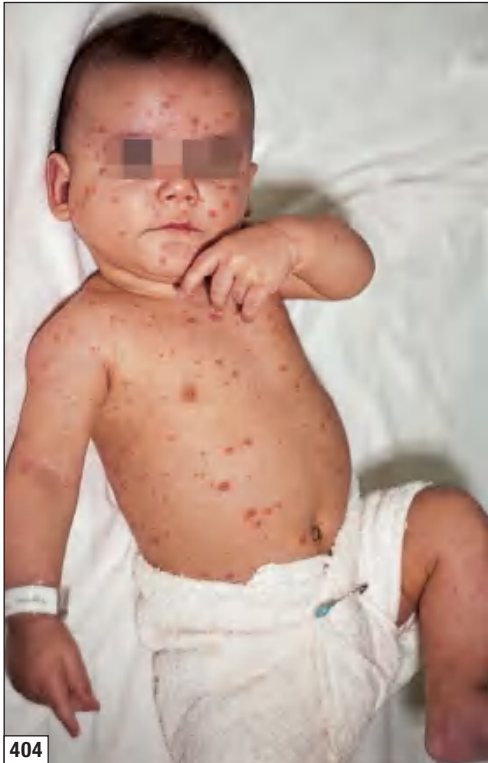

Figure 404. Chickenpox: the rash is typically centripetal – on the trunk and face mainly.

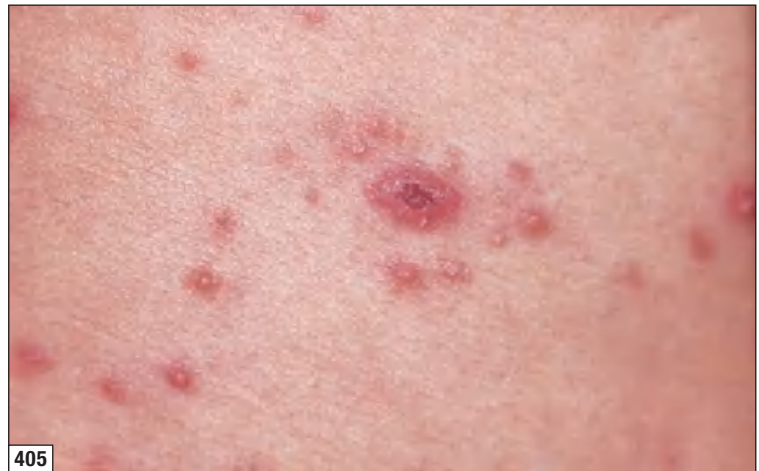
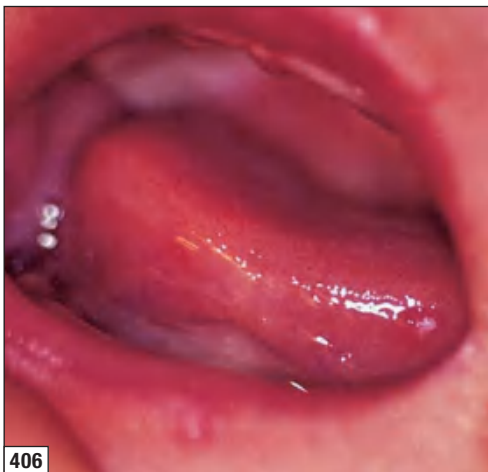
Figure 405. Chickenpox rash evolves from macules to papules, vesicles and pustules before crusting.



Figures 406, 407. Oral vesiculation in chickenpox.

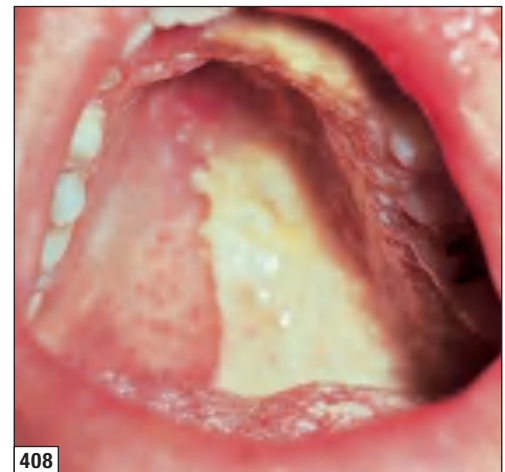
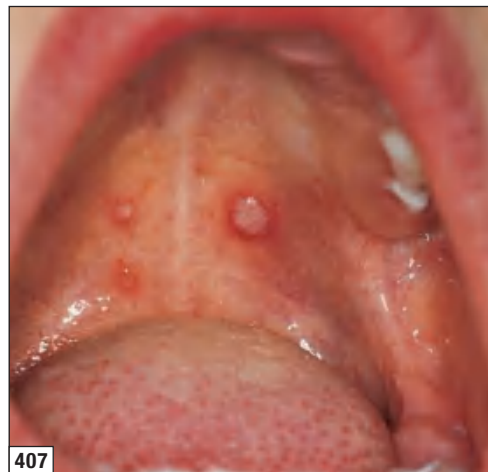
Figure 408. Herpes zoster caused by reactivation of latent varicella-zoster virus during bone marrow transplantation.

7

Acquired salivary gland disorders

Although acute viral sialadenitis, which presents with salivary gland pain and swelling, is mainly a childhood infection, other salivary gland disorders are rare in children.

COMMON COMPLAINTS

Dry mouth

Few children complain of a dry mouth: most have more than adequate saliva. Indeed, hypersalivation is more common. The main causes of dry mouth (Table 25) are iatrogenic, either from drugs (those with anticholinergic or sympathomimetic activity), irradiation of the salivary glands or graft versus host disease. Dehydration, as in diabetes mellitus, is an occasional cause. Rarely there is salivary gland agenesis (Fig. 409) or disease of glands, such as Sjögren's syndrome, sarcoidosis or HIV disease.

Table 25. Main causes of dry mouth in childhood

Iatrogenic

Anticholinergics

Atropine and analogues
Antihistamines
Tricyclic antidepressants
Antiemetics, phenothiazines

Sympathomimetics

Ephedrine and other decongestants
Bronchodilators
Amphetamines and appetite suppressants

Cytotoxic drugs

Opioids
Anti-HIV drugs
Didanosine, protease inhibitors

Radiotherapy or use of ¹³¹iodine

Graft versus host disease

Dehydration

Diabetes mellitus
Diarrhea and vomiting

Organic disease of glands

Juvenile Sjögren's syndrome
Sarcoidosis
Ectodermal dysplasia
Cystic fibrosis
Aplasia
Infections – HIV, hepatitis C virus, HTLV-1

Psychogenic

Anxiety states
Depression
Hypochondriasis

Diagnosis

In patients complaining of a dry mouth, xerostomia cannot always be objectively confirmed; there is *not* always reduced salivary flow or a salivary disorder. In true xerostomia, the dry mucosa may become tacky and the lips adhere one to another. There may be a lack of salivary pooling in the floor of the mouth, or the saliva may appear scanty or frothy. Saliva may not be expressible from the salivary ducts. An examining dental mirror may often stick to the oral mucosa.

Other investigations may be indicated, including serology and other tests for systemic disease, and salivary function studies, which include the following.

Salivary flow rates (sialometry)

Salivary flow rate estimation is:

- a sensitive indicator of salivary gland dysfunction
- nonspecific.

Salivary biopsy

Minor salivary glands are usually biopsied. The glands selected are those in the lower labial mucosa (labial gland biopsy), because they are simply biopsied through a small incision inside the labial mucosa with few adverse effects except occasional minor hypoesthesia.

Sialography

Sialography, in which radiopaque dye is introduced into the salivary duct, may be of value if there is duct obstruction or dilatation, but carries the risks of:

- discomfort
- infection.

Salivary scintiscanning

Salivary scintiscanning with technetium pertechnetate correlates both with salivary flow rate and labial gland histopathological changes and offers the additional advantage that all major salivary glands are examined noninvasively, simultaneously and if necessary, continuously.

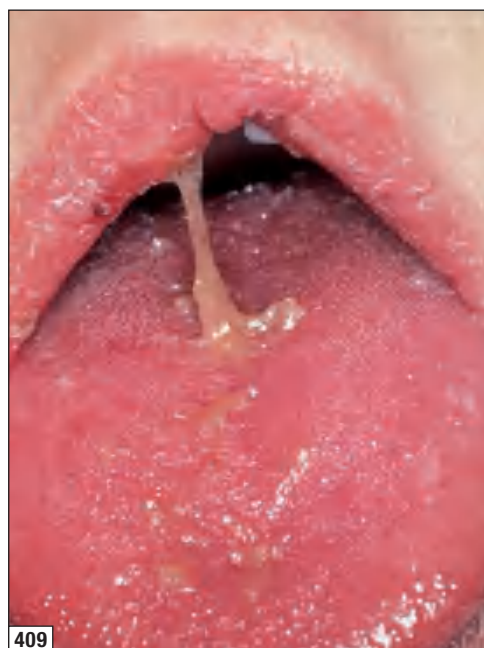

Figure 409. Xerostomia in a 4-year-old child as a result of complete agenesis of the major salivary glands. The dry mucosa is very tacky with strands of thick mucoid saliva. Agenesis was confirmed by a technetium pertechnetate radionuclide scan.

However, it is:

- not always available
- expensive
- associated with a small radiation hazard.

Ultrasound

Ultrasound is useful mainly where a neoplasm is suspected.

Sialochemistry

Sialochemistry (studies of constituents of saliva) is of limited clinical value.

Management

Any underlying cause should, if possible, be rectified. The lips may need protection with petroleum jelly. It is also wise for the patient to avoid dry foods such as biscuits and anything that may produce xerostomia, such as:

- drugs (e.g. antihistamines)
 - smoking.
- Salivation may be stimulated by using:
- chewing gums (containing xylitol or sorbitol, not sucrose)
 - diabetic sweets.

Salivary substitutes may help symptomatically. Various are available including (Table 26):

- water
- methylcellulose
- mucin.

Dental caries

Dietary control of sucrose intake, and the daily use of fluorides (1% sodium fluoride gels or 0.4% stannous fluoride gels) are essential to control dental caries. Regular dental checks are required.

Table 26. Saliva substitutes

Main constituent	UK	USA
Sodium carboxymethyl cellulose	Glandosane (Fresenius)	Glandosque (Bradley)
Sodium carboxymethyl cellulose	Luborant (Antigen)	Entertainers Secret (KLI Corp)
Gel, lactoperoxidase, glucose oxidase	Oral Balance (Laclede)	Oral Balance (Laclede)
Mucin	Saliva orthana (Nycomed)	—
Sodium carboxymethyl cellulose	Salivace (Penn)	Salivart Synthetic Salvia (Gebauer)
Sodium carboxymethyl cellulose	Saliveze (Wyvern)	Xerolube (Colgate oral)

Candidosis

Candidosis is managed as described above (Table 17). Appliances should be soaked in sodium hypochlorite solution or chlorhexidine for 20 minutes. An antifungal such as miconazole gel or amphotericin or nystatin ointment should be spread on the fitting surface washed appliance before reinsertion.

Bacterial sialadenitis

Acute sialadenitis needs treating with a penicillinase-resistant antibiotic such as flucloxacillin or clindamycin.

Salivary swelling

Most salivary swellings in children are caused by mumps sialadenitis, but recurrent parotitis, salivary duct obstruction, HIV infection, Sjögren's syndrome, sialosis and neoplasms are important causes to be excluded. The causes of swelling of the salivary glands are summarized in Table 27.

Table 27. Main causes of salivary gland swelling in childhood

Local

Inflammatory (ascending bacterial sialadenitis)
Duct obstruction (usually by a calculus)
Neoplasms (various)

Systemic

Inflammatory

Mumps
Recurrent parotitis
HIV infection
Hepatitis C virus infection
Sjögren's and sicca syndrome
Sarcoidosis
Actinomycosis

Others

Eating disorders
Mikulicz's disease (lymphoepithelial lesion and syndrome)

Drugs

Chlorhexidine and others

Sialosis

Deposits

Diagnosis

Submandibular swellings are usually readily detectable clinically, but in an overweight person parotid swelling can be difficult to confirm. A useful guide to whether the patient has parotid enlargement is to observe the outward deflection of the ear lobe, which is seen in true parotid swelling. Diagnosis is mainly clinical, but investigations such as serology for mumps or HIV antibodies, autoantibodies (SS-A [Ro] and SS-B [La]), liver function tests or needle or open biopsy may be indicated.

Management

Treatment is of the underlying cause.

Sialorrhea (hypersalivation, ptyalism)

Infants frequently drool; this is normal, especially when 'teething'. Sialorrhea is more common and drooling is seen more frequently in children who have learning disability or poor control of the orofacial muscles, or where there are inflammatory oral lesions. In many cases the complaint relates not so much to excessive saliva production, but by an inability to swallow saliva as a result of muscular incoordination, lip incompetence, neurological disorders, pharyngeal obstruction or reduced swallowing rate (Table 28).

Diagnosis

Diagnosis is clinical; estimation of salivary flow may be indicated.

Management

Treatment is of the underlying cause.

Atropinics, although theoretically useful to control sialorrhea, are rarely of practical value because of side-effects, but propantheline bromide, or transdermal scopolamine (hyoscine) may be effective. Antihistamines are sometimes used.

Surgical operations have been devised to reroute the submandibular gland duct to open posteriorly.

Table 28. Causes of sialorrhea

Painful lesions or foreign bodies in the mouth

Drugs

Anticholinesterases

Clozapine

Cocaine

Iodides

Bromides

Ammonium bicarbonate

Ethyl chloride

Dimercaprol

Ketamine

Ethionamide

Digitalis

Benzodiazepines rarely

Heavy metal toxicity rarely (lead poisoning)

Pharyngeal or esophageal obstruction

Poor neuromuscular coordination

Cerebral palsy

Facial palsy

Bulbar palsy

Pseudobulbar palsy

Learning disability

Other physical disability

Psychogenic

Episodic idiopathic paroxysmal sialorrhea

MUCOCELE

Mucoceleles (Figs 410–412) are dome-shaped, fluctuant, bluish, nontender, submucosal swellings with normal overlying mucosa. Most mucoceleles are caused by saliva extravasating into the lamina propria from a damaged salivary duct (extravasation mucoceleles) and are seen in the lower labial and ventral lingual mucosa. Occasional mucoceleles are retention cysts such as mucoceleles arising from the sublingual gland, which because of their resemblance to a frog's belly, are termed ranulas. Rarely, a ranula extends through the mylohyoid muscle – a plunging ranula (Fig. 413).

A few mucoceleles arise within the epithelium and such *superficial mucoceleles* appear as small vesicles that ulcerate when ruptured.

Diagnosis

Diagnosis is clinical and biopsy.

Management

Removal surgically or by cryotherapy is the most common treatment.

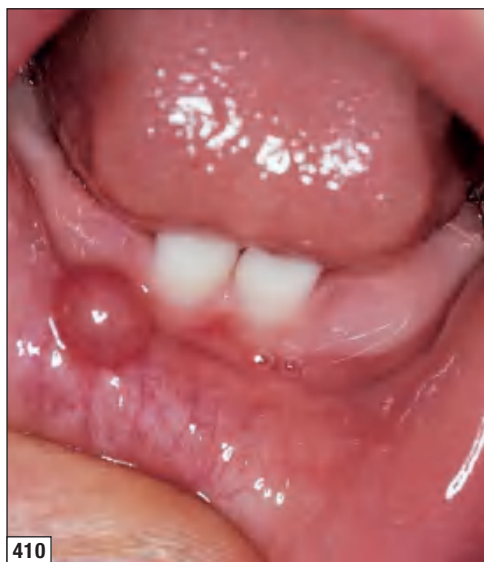

Figure 410. Mucocele in a common site, the lower lip.

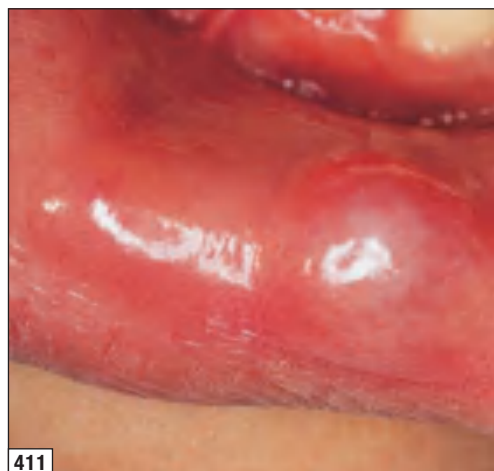

Figure 411. Mucocele of the lower labial mucosa with a smooth translucent surface.

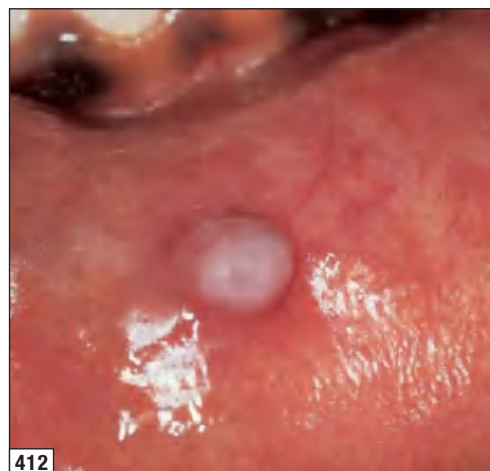

Figure 412. Mucocele of the lower labial mucosa with a keratinized surface as a result of repeated sucking on the nodule.

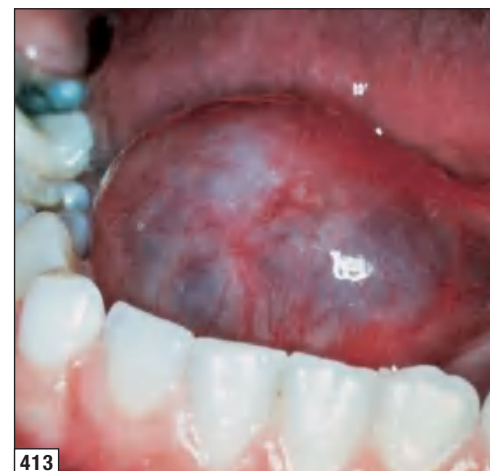

Figure 413. A ranula of the right sublingual gland with the classical bluish translucent appearance said to resemble the belly of a frog.

SIALOLITHIASIS

Salivary calculi (sialoliths) are uncommon in children. They usually affect the submandibular duct, are sometimes asymptomatic, but may present with pain in and swelling of the gland – particularly around mealtimes. Calculi are usually yellow or white and can sometimes be seen in the duct or may be palpable.

Stones are even less common in the parotid gland and less often radiopaque. Obstruction of any gland can also be caused by mucus plugs, strictures or the edema associated with ulceration of the duct papilla. Rarely, salivary obstruction has other etiologies.

Diagnosis

Diagnosis is clinical, supported by imaging. Not all are radiopaque, so radiographic imaging is not always helpful.

Management

Surgery.

MUMPS

Mumps (Figs 414, 415) is an acute infection with the paramyxovirus paramyxo virus and predominantly affects the major salivary glands.

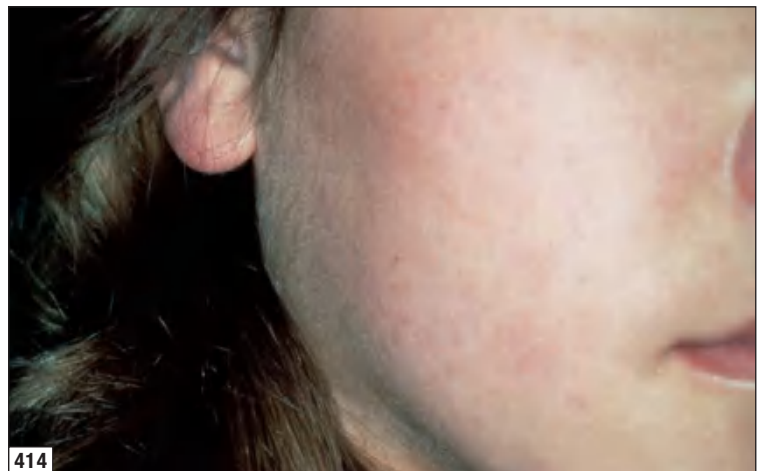The incubation period of 2–3 weeks is followed by fever, malaise and sialadenitis, which can affect not only mainly the parotids, but also the submandibular glands. The most obvious intraoral feature is swelling and redness at the duct orifice of the affected gland (papillitis). There is tender swelling with trismus. This may be unilateral, but is more frequently bilateral. Pancreatitis, oophoritis and orchitis are less common features. Infection with coxsackievirus, echovirus, HIV and other viruses occasionally cause similar features.

Diagnosis

Diagnosis is clinical, supported occasionally by serology, biochemistry (raised serum amylase) or viral studies.

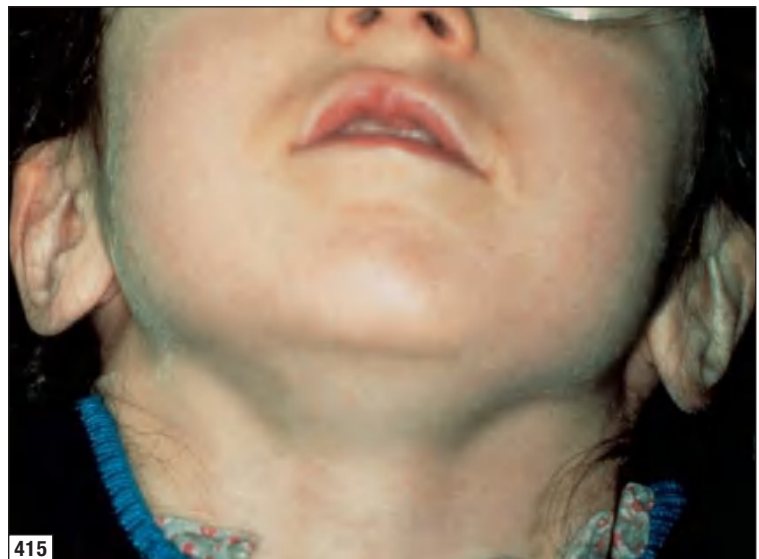Management

There are no specific antivirals available. Supportive care only is available. Vaccines are available for prevention.



414

Figure 414. Mumps parotitis.



415

Figure 415. Mumps bilateral parotitis and left submandibular sialadenitis.

SUPPURATIVE SIALADENITIS

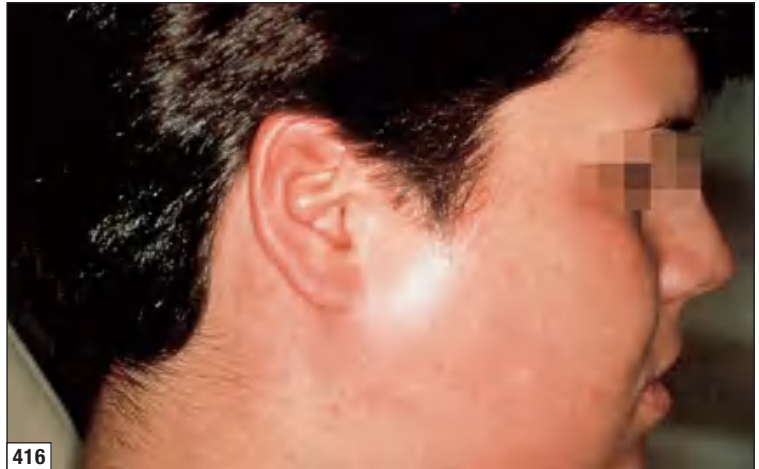Xerostomia and obstructive sialadenitis predispose to suppurative sialadenitis (Fig. 416). It is usually unilateral and presents with fever, pain and a swollen and tender parotid gland. A common causal organism is a penicillinase-producing *Staphylococcus aureus*.

Diagnosis

Diagnosis is clinical, supported by microbiology and imaging.

Management

Suppurative sialadenitis usually responds to antibiotics: clindamycin or a penicillinase resistant agent such as flucloxacillin are indicated. Surgical drainage is infrequently needed.



416

Figure 416. Suppurative parotitis showing a tense erythematous swelling.

RECURRENT SIALADENITIS

Recurrent parotitis (Fig. 417) is an idiopathic parotid swelling that may be seen in otherwise healthy children. Most cases appear related to congenital duct anomalies, but an association with an IgG subclass deficiency has been recorded.

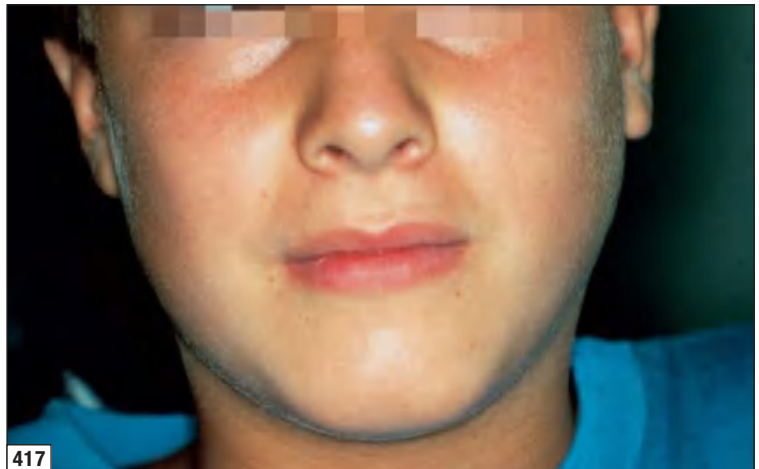The swelling is usually unilateral, but may occur simultaneously or alternately on the contralateral side. There is little pain, and the salivary swelling lasts 2–3 weeks with spontaneous regression.

Diagnosis

Diagnosis is clinical, supported occasionally by, imaging, serology or viral studies.

Management

No specific treatment is available or required. Usually the condition resolves after puberty, but antimicrobials are often given.



417

Figure 417. Recurrent parotitis.

SALIVARY NEOPLASMS

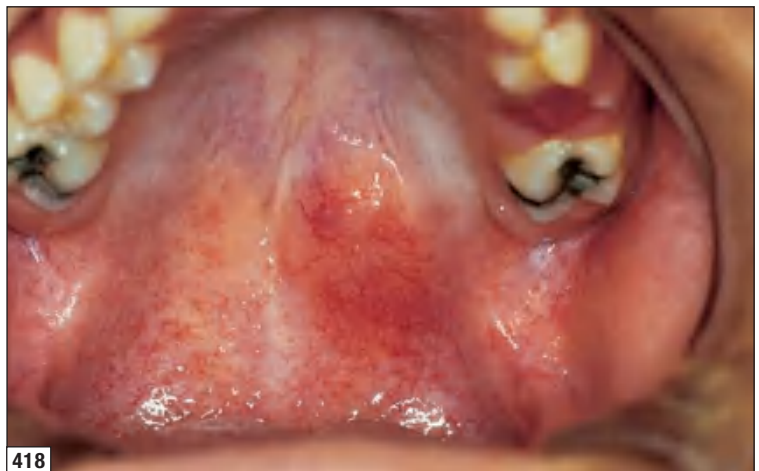Salivary neoplasms are rare in children, but usually involve the parotid gland and most are pleomorphic adenomas. Most malignant salivary neoplasms are mucoepidermoid carcinomas.

Diagnosis

Diagnosis is clinical, supported by imaging and biopsy.

Management

Management involves surgery.



418

Figure 418. Pleomorphic adenoma of the palatal glands in a 12-year-old child.

8

Acquired musculoskeletal disorders

Children rarely acquire musculoskeletal disorders.

ACTINOMYCOSIS

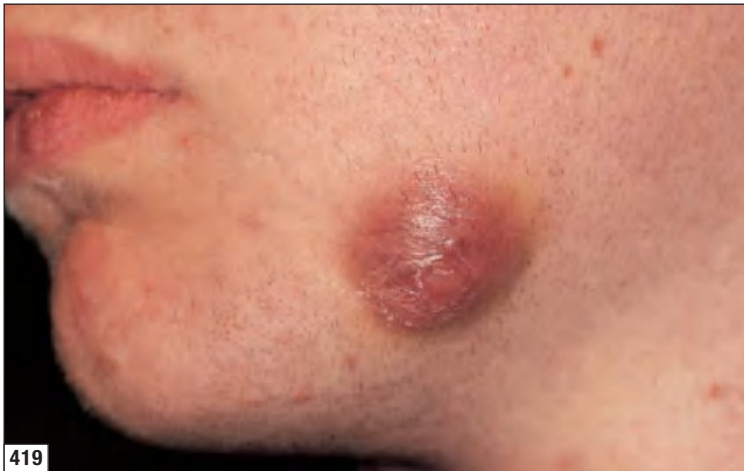Actinomycosis (Figs 419, 420), though not a bone infection, is included here because it commonly follows trauma involving bone. Rare in children, it is typically seen over the mandibular region, presenting as a dusky red persistent swelling that may discharge pus through multiple sinuses.

Diagnosis

Diagnosis is clinical supported by imaging and microbiology.

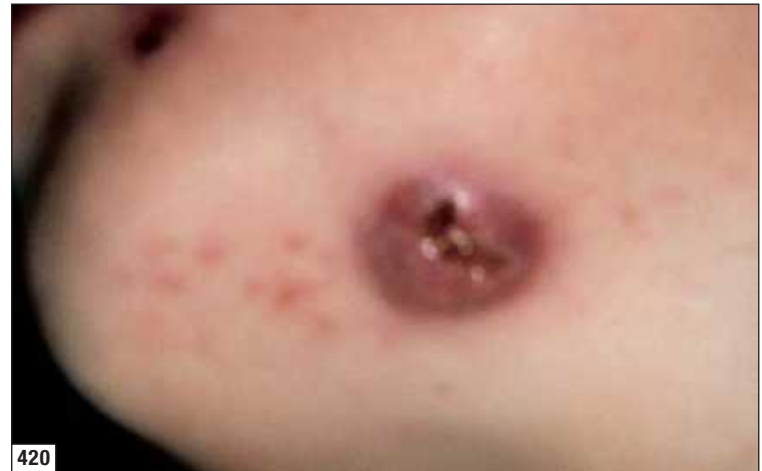Management

Surgery and antibiotics, usually penicillin for at least 6 weeks.



419

Figure 419. Actinomycosis showing the typical dusky purplish appearance at a common site.



420

Figure 420. Actinomycosis.

FIBROUS DYSPLASIA (SEE ALSO CHERUBISM)

Fibrous dysplasia (Figs 421–424) is an uncommon benign fibro-osseous lesion of unknown etiology, but presumably with a genetic element. The swelling is painless and typically stops growing at the time of skeletal maturity. Four subgroups of fibrous dysplasia have been described:

- *monostotic* (involvement of one bone) the most common
- *polyostotic*
- *polyostotic fibrous dysplasia of Albright's syndrome* (McCune–Albright syndrome) – the association of polyostotic fibrous dysplasia with cutaneous hyperpigmentation, precocious puberty and occasionally other endocrine disorders (Fig. 425)
- *craniofacial fibrous dysplasia* (a form confined to the craniofacial complex).

Diagnosis

Diagnosis is clinical supported by imaging, biochemistry and biopsy. The typical appearance on imaging is of a 'ground glass' pattern. Bone scan using technetium diphosphonate shows increased uptake of radionuclide in fibrous dysplasia.

Management

Surgical recontouring of the craniofacial lesions is recommended for improved function and cosmetics. Surgery is delayed until after puberty.

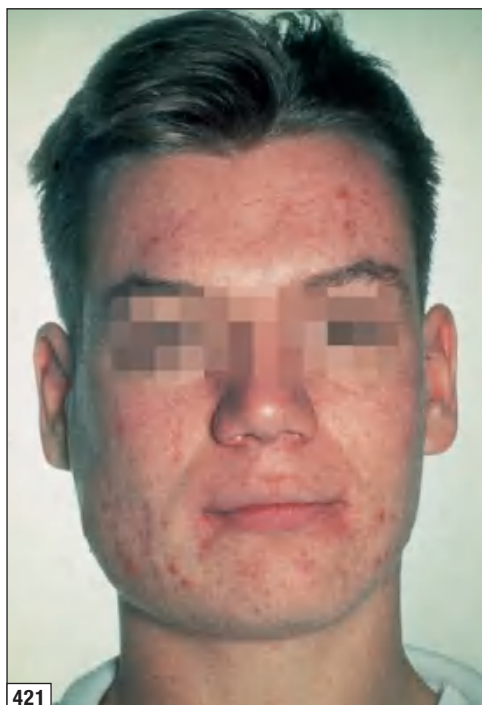

Figure 421. Fibrous dysplasia affecting the right side of the mandible in a teenager.

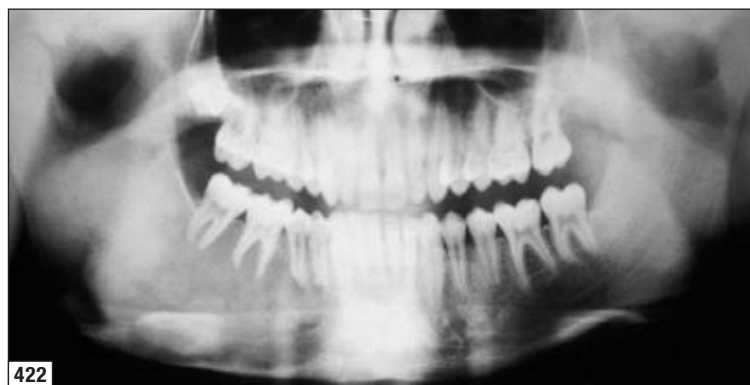

Figure 422. There is marked asymmetry with bony expansion on the affected side in the patient shown in Figure 423. The radiograph shows the typical 'ground glass' appearance replacing normal trabecular architecture. The roots of the teeth are unaffected by the bony changes.

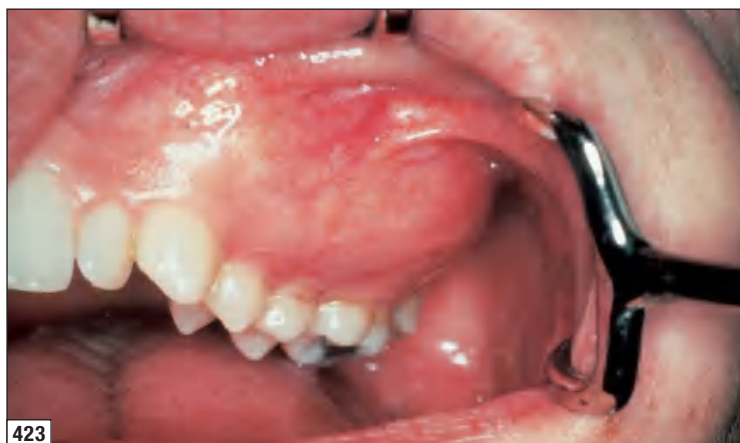

Figure 423. Typical maxillary alveolar expansion in fibrous dysplasia.

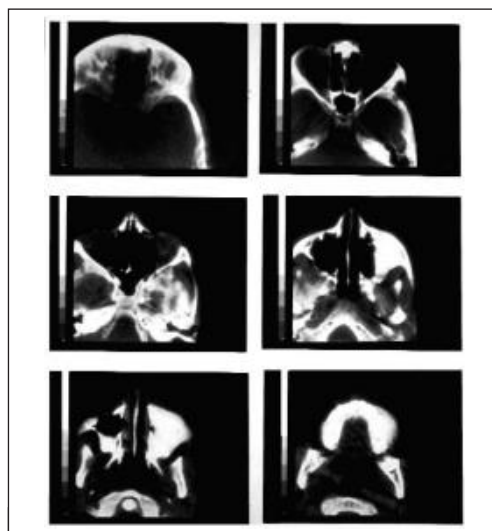


Figure 424. Fibrous dysplasia demonstrated on a computed tomogram.

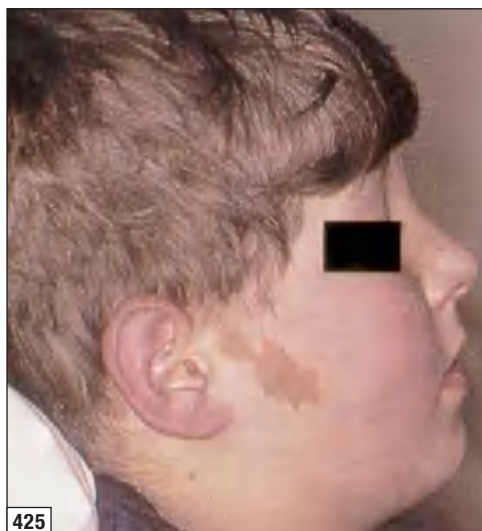

Figure 425. Skin hyperpigmentation in Albright's syndrome.

MASSETERIC HYPERTROPHY

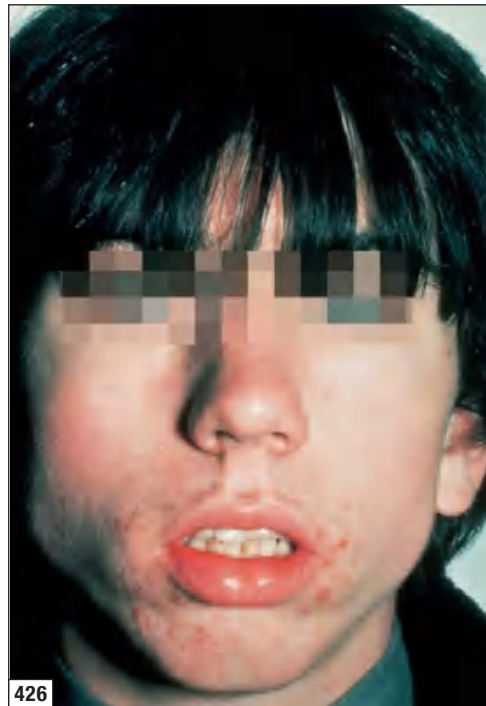The masseter muscle hypertrophies (Figs 426, 427), especially where there are parafunctional habits such as jaw-clenching or bruxism. It is therefore commonly seen in cerebral palsy and learning disability, and Rett's syndrome but some cases appear to be familial. There is unilateral or bilateral masseteric enlargement and sometimes a little tenderness in the affected muscle. Occasionally the hypertrophied muscle obstructs the parotid duct.

Diagnosis

Diagnosis is clinical, supported by imaging and biopsy.

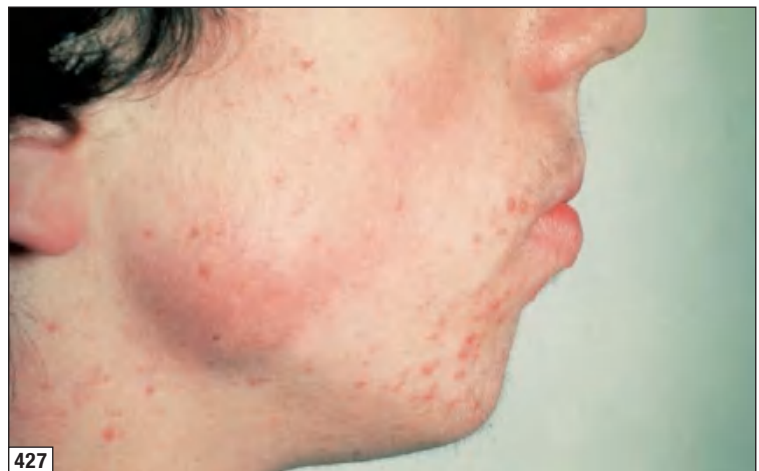Management

Treatment of the parafunctional habit may be indicated.



Figures 426, 427.

Bilateral masseteric hypertrophy.



ODONTOGENIC CYSTS AND TUMORS

Odontogenic cysts and tumors are rare in children with the exception of odontomes. Periapical cyst is the most common lesion in this group for adults, but is infrequently observed in children. Dentigerous cysts, odontogenic keratocysts and occasionally unicystic ameloblastomas are seen in children and adolescents and most often occur in the posterior mandible. Tumors that have a predilection for children include the adenomatoid odontogenic tumor, which is usually found in the maxillary canine region, and the ameloblastic fibroma and ameloblastic fibro-odontoma, which occur in the posterior mandibular region. The conventional ameloblastoma (Figs 428, 429) is rarely diagnosed in children and is the most aggressive of the benign odontogenic tumors.

Diagnosis

Diagnosis is clinical, supported by imaging and biopsy.

Management

Management involves surgery.

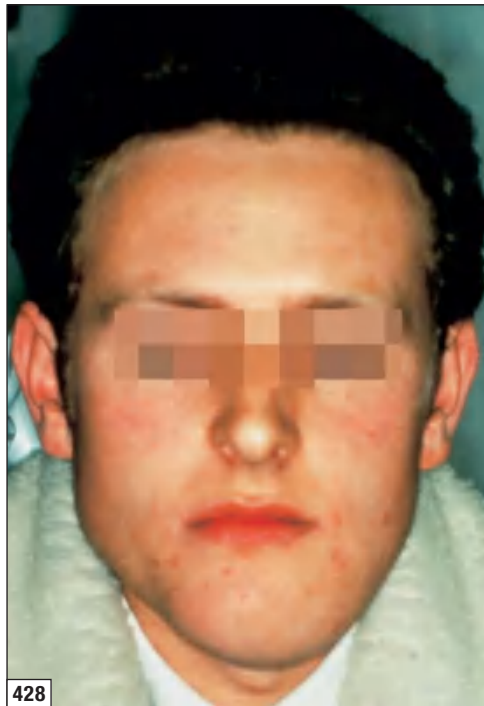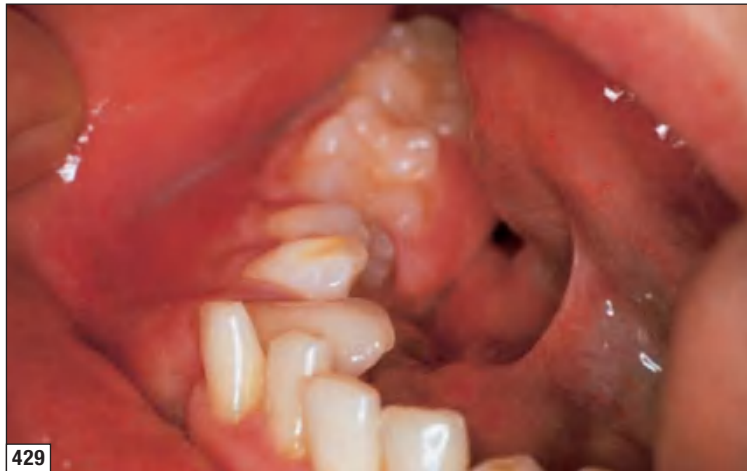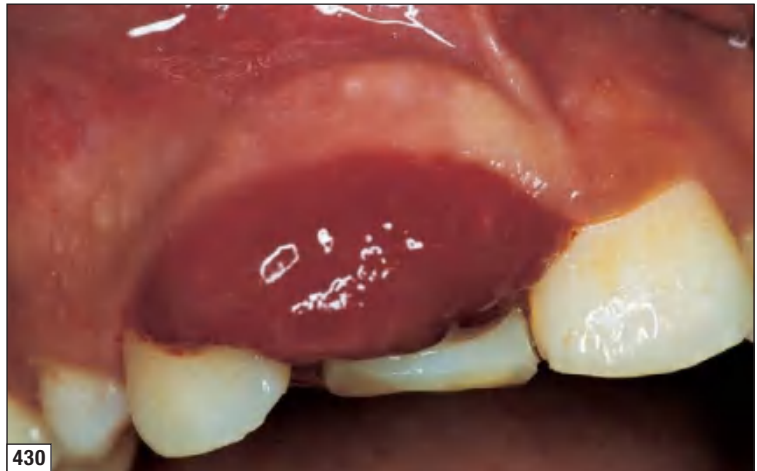


Figure 428
Ameloblastoma in
right mandible.



429

Figure 429. Ameloblastoma in the patient in Figure 428 showing tooth displacement and expansion.



430

Figure 430. Adenomatoid odontogenic tumor.

OSTEOMYELITIS

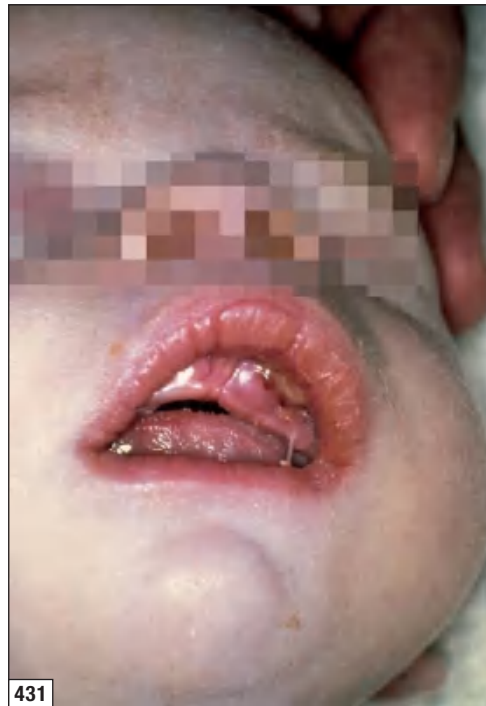Neonates are occasionally afflicted by *Staphylococcus aureus* causing a maxillary osteomyelitis (Figs 431, 432). In older children, Garré's osteomyelitis of the jaws, also known as chronic osteomyelitis with proliferative periostitis, is the most common form of osteomyelitis. It is an exuberant response of the periosteum to a low-grade infection, usually from a nonvital mandibular molar. The prominent bony expansion is alarming because it develops rapidly and can cause marked facial distortion. Appreciable pain is not a common finding.

Diagnosis

Diagnosis is clinical, supported by imaging, microbiology and biopsy.

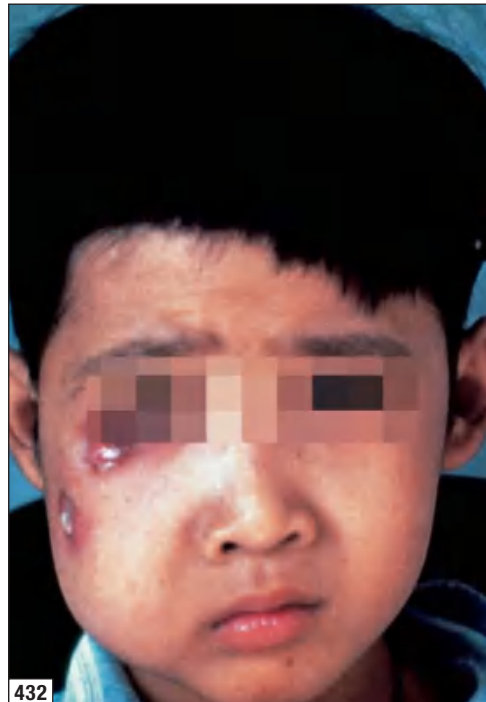Management

Antibiotics plus endodontic treatment or extraction if there is a nonvital tooth, and occasionally surgery. An underlying immune defect should be excluded.



431

Figure 431. Maxillary osteomyelitis in a neonate.



432

Figure 432. Osteomyelitis in a malnourished patient.

TEMPOROMANDIBULAR JOINT DISORDERS

Temporomandibular joint pain-dysfunction syndrome (myofascial pain-dysfunction syndrome, facial arthromyalgia)

Temporomandibular joint (TMJ) pain-dysfunction is common in adolescent and young adult women and rare in children. Symptoms are highly variable, but include:

- recurrent clicking in the TMJ at any point of jaw movement
- crepitus especially with lateral movements
- periods of limitation of jaw movement, but rarely severe trismus
- variable jaw deviation or locking
- pain in the TMJ and surrounding muscles, which may be tender to palpation – pain appears to be related to muscle spasm and ischemia.

Patients who have a night-time clenching or grinding habit (bruxism) may awake with joint pain, which abates during the day. The symptoms of individuals who clench or grind during working hours tends to worsen towards evening and there is sometimes a psychogenic basis.

Different etiological factors that have been implicated include:

- muscle overactivity (e.g. bruxism, clenching)
- TMJ disruption after trauma
- psychiatric history (e.g. anxiety, stressful life events).

Precipitating factors may include

- wide mouth opening
- local trauma
- nail biting
- gum chewing
- emotional upset.

There is rarely, however, one specific etiology – a combination of factors is often contributory. Occlusal factors do not in general appear especially important.

Diagnosis

Diagnosis is clinical. Radiographic changes are uncommon and arthrography and magnetic resonance imaging are seldom indicated.

Management

Most patients recover spontaneously and therefore reassurance and conservative measures are preferred and include:

- rest
- remedial jaw exercises to minimize abnormal habits
- soft diet
- analgesics.

If these are insufficient, it can be helpful to give a periarticular injection of local analgesic to break the cycle leading to muscle spasm or use:

- plastic splints on the occlusal surfaces (occlusal splints) to reduce joint loading
- heat
- ultrasound
- anxiolytic agents
- antidepressants.

A small minority of patients fail to respond to the above measures and require local corticosteroid or sclerosant therapy, local nerve destruction, or, usually as a last resort, TMJ surgery.

Growth disorders

Impaired mandibular growth may be associated with generalized growth disorders or where there is damage to the condylar growth center – typically by infection or irradiation. Generalized growth disorders such as acromegaly may lead to increased condylar growth, and prognathism. Less well defined are the causes of facial hemihyperplasia.

Diagnosis

Diagnosis is clinical, supported by imaging.

Management

Management involves surgery.

Pyogenic arthritis

Pyogenic arthritis of the TMJ is rare, but may follow a penetrating injury, result from contiguous infection or be hematogenous (e.g. gonococcal). Infection of the TMJ may result in ankylosis and impaired mandibular growth.

Diagnosis

Diagnosis is clinical, supported by imaging, serology, biochemistry and biopsy.

Management

Management involves antibiotics.

Rheumatoid arthritis

Rheumatoid arthritis is a chronic relapsing inflammatory arthritis that usually affects many diarthrodial joints and is characterized by morning stiffness of the joints, which in advanced disease become severely deformed. Osteoporosis, flattening of the mandibular condyle, marginal irregularities and limited movement may be seen. There may be restricted oral opening. Juvenile rheumatoid arthritis (Fig. 433) – 20% of which is Still's syndrome, with systemic disease – may also interfere with mandibular growth and cause ankylosis.

Diagnosis

Diagnosis is clinical, supported by imaging, serology and biochemistry.

Management

Management involves analgesics.

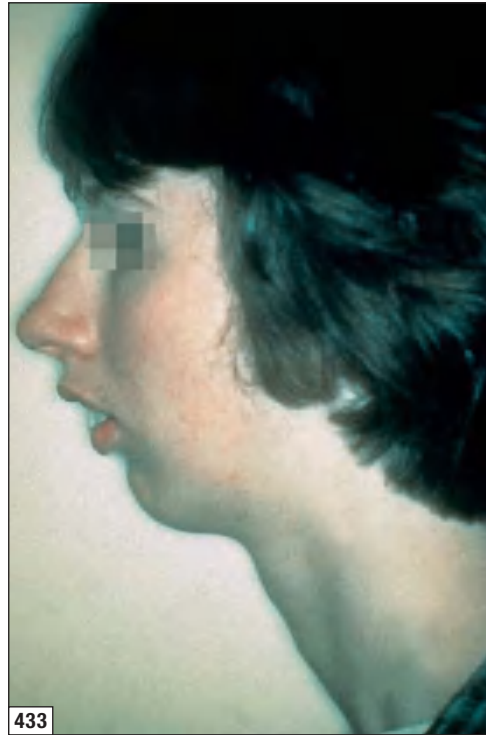

Figure 433. Juvenile rheumatoid arthritis has affected the temporomandibular joint and resulted in impaired mandibular growth, and therefore severe retrognathia.

Subluxation

Some patients are able to sublux their TMJ deliberately. Subluxation is especially liable to occur in hypermobility syndromes such as Ehlers–Danlos syndrome.

Diagnosis

Diagnosis is clinical, supported by imaging.

Management

Management involves the avoidance of behaviour that causes the problem and, as a last resort, surgery.

9

Pain and neurological disorders

Most orofacial pain is of odontogenic origin.

CAUSES OF OROFACIAL PAIN

A differential diagnosis of orofacial pain is given in Table 29.

Local causes

Most orofacial pain in children is related to dental causes, but a wide range of conditions can be responsible, particularly local causes such as:

- odontogenic causes, mainly a consequence of caries
- temporomandibular pain dysfunction
- paranasal sinus and nasopharynx disease.

Paranasal sinus and nasopharynx disease

In acute sinusitis:

- There has usually been a preceding cold followed by local pain and tenderness (but not swelling).
- There is radioopacity of the affected sinuses, sometimes with an obvious fluid level.
- Pain may be aggravated by changing the position of the head.

With maxillary sinusitis, pain may be felt in related upper molars, which may be tender to percussion. The pain of ethmoidal or sphenoidal sinusitis is deep in the root of the nose.

Tumors in the sinuses are rare in children, but can also cause orofacial pain by infiltrating branches of the trigeminal nerve.

Salivary gland disorders

In children, the most common cause of salivary pain is sialadenitis.

Pain from salivary glands from blockage of a salivary duct by calculus or mucus plug is rare, but:

- is localized
- may be quite severe
- may be intensified by increased saliva production such as before and with meals.

The affected gland may be swollen and tender to palpation. Mouth opening may aggravate the pain, and therefore there may be some trismus.

Referred pain

Eyes

Disorders of refraction, retrobulbar neuritis or rarely glaucoma can cause pain, which may radiate to the orbit or frontal region.

Ears

Middle ear disease may cause headaches.

Neck

Neck pain, usually from cervical spondylosis, occasionally causes pain referred to the face.

Table 29. Differential diagnosis of orofacial pain

	Dental	Periodontal	Mucosal	Salivary glands	Neurologic	Vascular	TMJ pain dysfunction	Psychogenic
Site	Mouth, ear, jaws, cheek	Tooth	Mucosa	Area of gland	Nerve distribution	Orbit or upper face	Temple, ear, jaws, teeth	Diffuse, deep, sometimes across midline
Local-ization	Poor, diffuse, radiating, does not cross midline	Good	Usually good	Usually good	Good	Usually good	Poor, but usually unilateral	Poor
Duration	Seconds to days	Hours to days	Hours to days	Hours to days	Seconds	Minutes to hours	Weeks to years	Weeks to years
Character	Intermittent, sharp, paroxysmal	Steady, boring	Burning or sharp	Drawing, pulling	Lancinating, paroxysmal	Throbbing, deep	Dull, continuous	Dull, boring continuous
Precipit-ating factors	Hot and cold	Chewing	Sour and spicy foods	Eating	Touch	Alcohol	Yawning, chewing	Stress, fatigue
Associated signs	Caries, exposed dentine	Abscess	Erosions or ulcers	Salivary gland swelling	None usually	Lacrimation, injected eye, nasal discharge	Click in TMJ, trismus	None
Etiological factors	Caries, trauma, gingival recession	Acute periodontitis	Varied	Saliva retention, infection	Idiopathic, multiple sclerosis	Vasomotor	Stress, parafunction	Depression
Treatment	Cracked tooth, restoration, endodontics	Endodontics or extraction	According to cause	Drainage, antibiotics	Carbamazepine, nerve block, cryoanalgesia, neurosurgery	Sumatriptan	Antidepressants, other treatments	Antidepressants

Neurological disorders (e.g. trigeminal neuralgia)

Similar features are seen in multiple sclerosis, some cerebral disorders and the rare Shortlasting, Unilateral, Neuralgiform headache attacks with Conjunctival injection and Tearing (SUNCT syndrome). Similar severe orofacial pain can result from cerebrovascular disease, multiple sclerosis, infections such as HIV infection or neoplasms. Physical signs such as facial sensory or motor impairment may then be present.

Frey's syndrome

Frey's syndrome (auriculotemporal syndrome, gustatory sweating) is a paroxysmal burning pain, usually in the temporal area of in front of the ear, associated with flushing and sweating on eating. Frey's syndrome may follow damage to the auriculotemporal nerve after surgery around the parotid region.

Diagnosis

Starch-iodine test.

Management

20% aluminium chloride hexahydrate, solution applied to area.

Herpetic and postherpetic neuralgia

Herpetic and postherpetic neuralgia persists after herpes zoster (shingles) and is a continuous burning pain, but it is rare in children.

Diagnosis

The history is usually indicative.

Management

Systemic aciclovir (acyclovir), famciclovir or valciclovir used during an attack of zoster can markedly reduce the prevalence of postherpetic neuralgia.

Vascular disorders (e.g. migraine)

Migraine and migrainous neuralgia can cause orofacial pain, but though uncommon in children may be seen in adolescents. Sick cell disease may produce bone and other infarcts resulting in pain. Recent evidence also suggests that chronic neuralgia may occasionally be related to thrombosis/hypofibrinolysis causing small areas of jaw ischemia and necrosis; this has been termed *neuralgia-inducing cavitation necrosis*.

Migraine

Migraine is a severe headache associated with nausea and sometimes photophobia, probably related to arterial dilatation, seen mainly in females. The attacks often affect the whole head or one side and may be precipitated by:

- alcohol
- various tyramine-containing foods such as ripe bananas or chocolate
- contraceptive pill
- stress.

Classic migraine has the following features:

- recurrent severe unilateral headache (hemicrania) lasting hours or days
- preceding warning symptoms (an aura) of visual, sensory, motor or speech disturbances
- visual phenomena of zig-zag colored lights (fortification spectra) or transient visual defects
- photophobia

- nausea or vomiting.

The number, frequency and intensity of attacks usually diminish with increasing age and spontaneous remissions are not uncommon.

Diagnosis

Diagnosis is clinical.

Management

Ergotamine or sumatriptan given early may abort an attack, but should only be prescribed by a physician, because they can produce serious adverse reactions. In acute attacks aspirin or paracetamol/acetaminophen may give some relief and generally patients prefer to lie in a quiet, dark room.

Migrainous neuralgia (cluster headache)

Migrainous neuralgia (cluster headache) is a retro-orbital pain occurring mainly at nights, mainly in adolescent and young adult males. Migrainous neuralgia is related to vascular changes, and is often:

- precipitated by alcohol
- localized around the eye
- unilateral
- characterized by attacks that last less than 1 hour and commence and often terminate suddenly
- responsible for awakening the patient at night or in the early hours of the morning (2–3 a.m.)
- burning and 'boring' in character
- associated on the affected side with the profuse watering of the eye and congestion of the conjunctiva and nasal discharge and obstruction.

Diagnosis

Diagnosis is clinical.

Management

Alcohol should be avoided. Indomethacin at night may help prevent attacks, as may calcium channel blockers. Attacks of migrainous neuralgia are managed, by the physician, with oxygen inhalations, or ergotamine or sumatriptan.

Psychogenic orofacial pain

Psychogenic orofacial pain is an ill-defined group of disorders which include:

- temporomandibular pain-dysfunction
- burning mouth syndrome (oral dysaesthesia, glossopyrosis, glossodynia).

Burning mouth syndrome is common in individuals past middle age and is rare in children. It is characterized by a persistent burning sensation in the tongue, usually bilaterally. Discomfort is sometimes relieved by eating and drinking, in contrast to the pain from ulcerative lesions, which is typically aggravated by eating.

Diagnosis

Diagnosis is clinical supported by imaging and biochemistry. Organic causes of discomfort, such as erythema migrans, lichen planus, a deficiency glossitis (related to deficiency of iron, folate or vitamin B₁₂), xerostomia, diabetes mellitus or candidosis must be excluded, but these are only occasional causes. More frequently there is an underlying depression, monosymptomatic hypochondriasis or anxiety.

Management

Reassurance and occasionally psychiatric consultation or antidepressants are therefore indicated.

Atypical facial pain

Atypical facial pain is often:

- a dull boring or burning type
- of ill-defined location.

Most patients:

- are female
- have constant chronic discomfort or pain
- rarely use analgesics
- sleep undisturbed by pain
- have consulted several clinicians
- have no objective signs
- have recent adverse life events
- have multiple psychogenic-related complaints.
- have negative investigations.

Diagnosis

It is important to exclude organic disease clinically and by investigations including imaging.

Management

Attempts at relieving pain by restorative treatment, endodontia or exodontia are usually unsuccessful. Over 50% of such patients are depressed or hypochondriacal, and some respond to anti-depressants. Those who will respond invariably do so early in treatment, but many refuse medication or psychiatric help.

Atypical odontalgia presents with pain and hypersensitive teeth typically indistinguishable from pulpitis or periodontitis, but without detectable pathology. Probably a variant of atypical facial pain, it should be treated similarly.

FACIAL PALSY

Lower motor neurone (LMN) paralysis of the facial (VII) cranial nerve in a child or adolescent is usually a result of Bell's palsy, mainly caused by herpes simplex virus.

Other causes (Table 30) may include:

- head injury (Figs 434, 435)
- surgical damage to the facial nerve
- tumors
- diabetes mellitus
- sickle cell disease
- infections with HIV, *Borrelia burgdorferi* (Lyme disease) or other microorganisms.

Occasionally, a temporary facial palsy follows the administration of an inferior alveolar local analgesic if the anesthetic solution tracks through the parotid gland to reach the facial nerve.

Table 30. Causes of facial palsy

Upper motor neurone lesion

Cerebrovascular event, including infarction as a result of sickle cell disease
Trauma
Tumor
Infection
Multiple sclerosis

Lower motor neurone lesion

Systemic infection
Bell's palsy (herpes simplex virus usually)
Varicella-zoster virus infection
Lyme disease
HIV infection
Middle ear disease
Otitis media
Cholesteatoma
Lesion of skull base
Fracture
Infection
Parotid lesion
Tumor
Trauma to branch of facial nerve

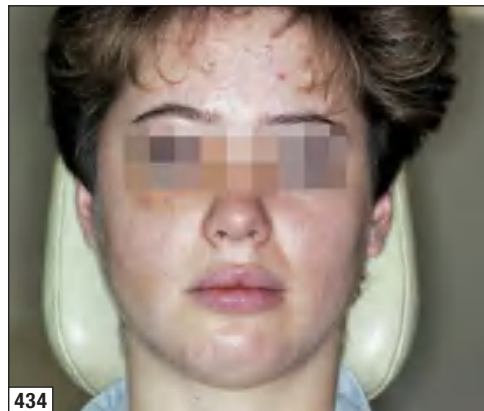

Figure 434. Facial palsy resulting from a basal skull fracture on the right side in a road accident.



Figure 435. There is residual periorbital hematoma on the right side, as well as the palsy in the patient in Figure 434.

The neurones to the upper face receive bilateral upper motor neurone (UMN) innervation. Upper motor neurone facial palsy is usually caused by damage in the middle capsule of the brain such as in a cerebrovascular event. Damage therefore extends to other areas including motor neurones, but extrapyramidal influences can still act on the face (e.g. on laughing) because of the bilateral cortical representation. An UMN lesion therefore, is characterized by unilateral facial palsy, with some sparing of the frontalis and orbicularis oculi muscles, the face may still move with emotional responses (because of extrapyramidal influences) and there may also be a paresis of the ipsilateral arm or arm and leg or some aphasia.

In contrast, lower motor neurone (LMN) facial palsy is characterized by total unilateral paralysis of all muscles of facial expression for voluntary and emotional responses, but no hemiparesis because the facial nerve neurones supplying the lower face receive upper motor neurones only for the contralateral motor cortex.

Diagnosis

In facial palsy:

- facial weakness is demonstrated by asking the patient to close the eyes against resistance, raise the eyebrows, raise the lips to show the teeth, try to whistle
- the forehead is unfurrowed
- the patient is unable to close the ipsilateral eye
- the eye on attempted closure rolls upward (Bell's sign)
- tears overflow onto the cheek (epiphora).
- the nasolabial fold is obliterated
- the ipsilateral corner of mouth droops.

The following investigations are indicated:

- full neurological examination, looking particularly for signs suggesting a central lesion, such as hemiparesis, tremor, loss of balance, involvement of the V, VI or VIII cranial nerves (test for loss of hearing or taste)
- aural examination for discharge and other signs of middle ear disease
- blood pressure measurement (to exclude hypertension)
- fasting blood sugar levels (to exclude diabetes mellitus)
- Lyme disease (tick-borne infection with *Borrelia burgdorferi*) may need to be excluded by serology
- HIV may need to be considered
- sickle cell test in appropriate groups.

Management

Management is of the underlying condition.

High-dose systemic corticosteroids and often aciclovir are indicated as emergency care for Bell's palsy.

SENSORY LOSS

Normal facial sensation is important to protect the skin, oral mucosa and especially cornea from damage. Facial sensory awareness may be:

- completely lost (anesthesia)
- partially lost (hypoesthesia).

The term paresthesia does not mean loss of sensation; rather it means abnormal sensation. Facial sensory loss is caused mainly by extracranial lesions of the trigeminal nerve. Rarely there are congenital disorders

such as 'congenital indifference to pain' and Riley-Day syndrome, which may present with anesthesia (Fig. 436).

Lesions of a sensory branch of the trigeminal nerve may cause anesthesia or hypoesthesia in the distribution of the affected branch. Facial sensory loss may lead to corneal, facial or oral ulceration.

Extracranial causes of sensory loss

Extracranial causes of facial sensory loss include damage to the trigeminal nerve from:

- trauma
- osteomyelitis
- malignant disease.

The mandibular division or its nerve branches is most commonly traumatized by inferior alveolar local analgesic injections, fractures or surgery (particularly osteotomies or surgical extraction of lower third molars). The lingual nerve may be damaged, especially during removal of lower third molars, particularly when the lingual split technique is used. Labial anesthesia or hypoesthesia may follow labial gland biopsy or removal of a mucocele from the lower lip.

Intracranial causes of sensory loss

Serious intracranial causes of sensory loss are uncommon in children, but include:

- multiple sclerosis
- brain tumors
- syringobulbia
- sarcoidosis
- infections (e.g. HIV infection).

Because other cranial nerves are anatomically close, there may be associated neurological deficits. With posterior fossa lesions for example, there may be cerebellar features such as ataxia. With middle cranial fossa lesions, there may be associated neurological deficits affecting cranial nerve VI.

Benign trigeminal neuropathy is a transient sensory loss of unknown etiology, in one or more divisions of the trigeminal nerve. The neuropathy seldom appears until the second decade and the corneal reflex is retained.

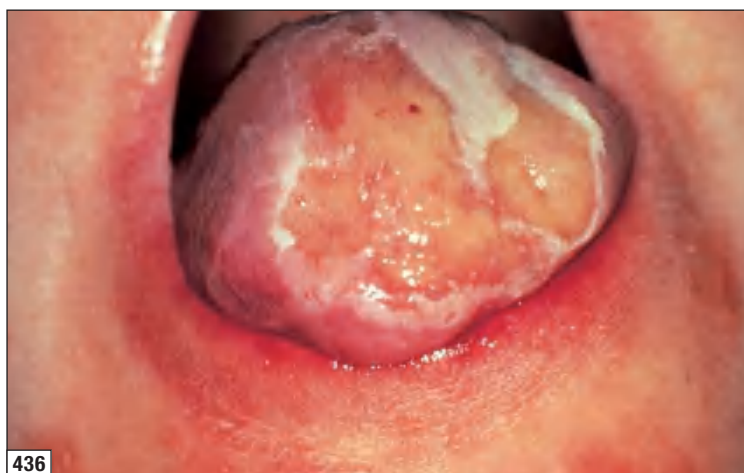

Figure 436. Erosion and scarring of the tip and dorsal surface of the tongue in a 3-year-old child with congenital insensitivity to pain. The tongue had been chewed between the upper and lower teeth. There was no intellectual impairment.

Psychogenic causes such as hysteria, and hyperventilation syndrome may underlie some causes of facial anesthesia.

Organic causes include diabetes mellitus and connective tissue disorder.

Diagnosis

In view of the potential seriousness of facial sensory loss, care should be taken to exclude local causes and a full neurological assessment must be undertaken. It is important to test all areas in patients complaining of facial sensory loss, but particularly the corneal reflex. Lesions involving the ophthalmic division cause corneal anesthesia, which is tested by gently touching the cornea with a wisp of cotton wool twisted to a point. Normally, this procedure causes a blink, but if the cornea is anesthetic (or if there is facial palsy), no blink follows, provided that the patient does not actually see the cotton wool. Progressive lesions affecting the sensory part of the trigeminal nerve

initially result in a diminishing response to pinprick of the skin and, then, complete anesthesia. Later there may be corneal, facial or oral ulceration. As, in the case of posterior or middle cranial fossa lesions, other cranial nerves are anatomically close, so there may be associated neurological deficits.

If the patient complains of complete facial or hemifacial anesthesia, but the corneal reflex is retained or there is apparent anesthesia over the angle of the mandible (an area not innervated by the trigeminal nerve), then the symptoms are probably functional (nonorganic).

Management.

If the cornea is anesthetic, a protective eye pad should be worn and a tarsorrhaphy (an operation to unite the upper and lower eyelids) may be indicated because the protective corneal reflex is lost and the cornea may be traumatized.

10

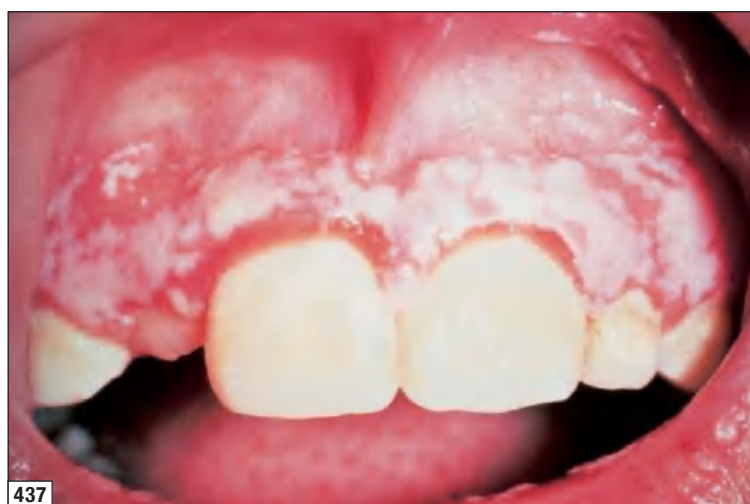Orofacial lesions in
major medical conditions

Orofacial lesions can be seen in many medical and surgical conditions, but this chapter highlights those most commonly seen in pediatric dental practice. These are mainly seen in immunocompromised patients or those with hemato-oncological problems. Oral diseases tend to be more frequent where there is:

- poor oral hygiene
- malnutrition
- tobacco use.

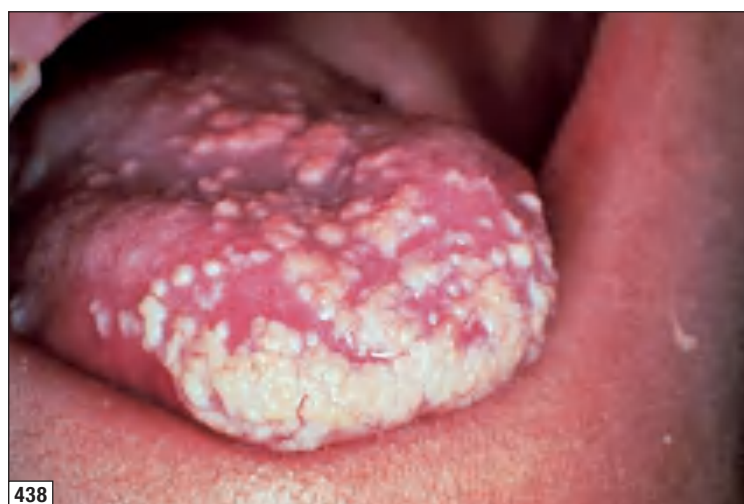ACQUIRED IMMUNE DEFICIENCY SYNDROME (AIDS, HIV-RELATED DISEASE)

Infection with HIV may cause an initial glandular fever-like illness, but may be asymptomatic. The incubation period until HIV disease (Figs 437–446) appears may extend over 5 or more years. The definition of AIDS has changed over the years, and is now applied when the T lymphocyte count (specifically the CD4 count) is below 200/ml or when certain conditions are present, such as oropharyngeal candidosis, hairy leukoplakia, or Kaposi's sarcoma. Oral lesions in HIV infection and AIDS are most likely to appear when the CD4 cell count is very low and are often controlled, at least temporarily, by anti-retroviral treatment.



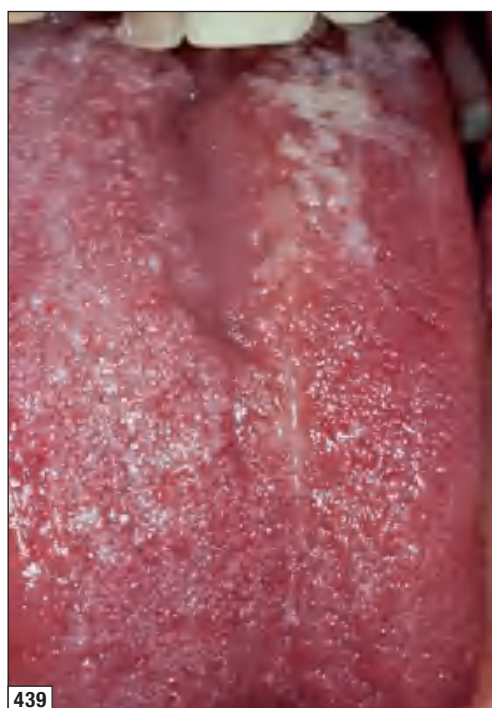437

Figure 437. Oral candidosis in HIV disease showing typical lesions of thrush.

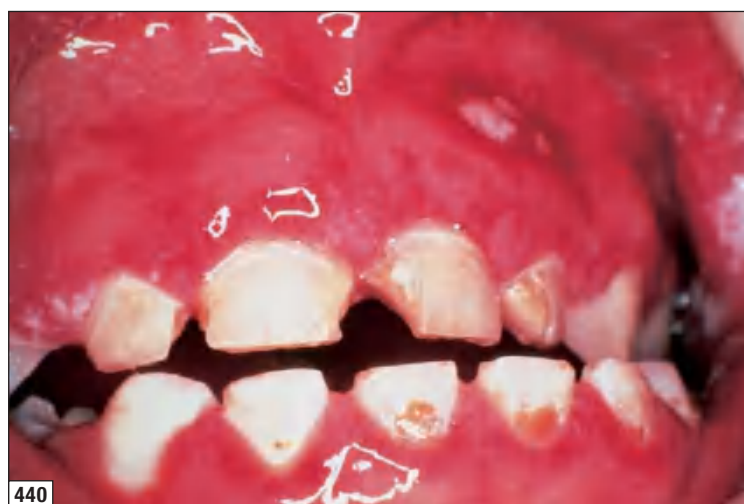

438

Figure 439. Median rhomboid glossitis in a young HIV-positive Hispanic child. Note that both the erythematous and pseudomembranous forms of candidosis are found on the dorsal tongue.

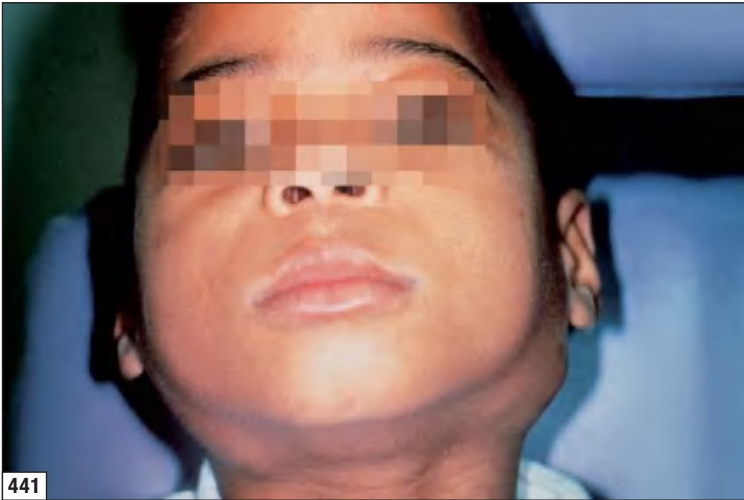

439



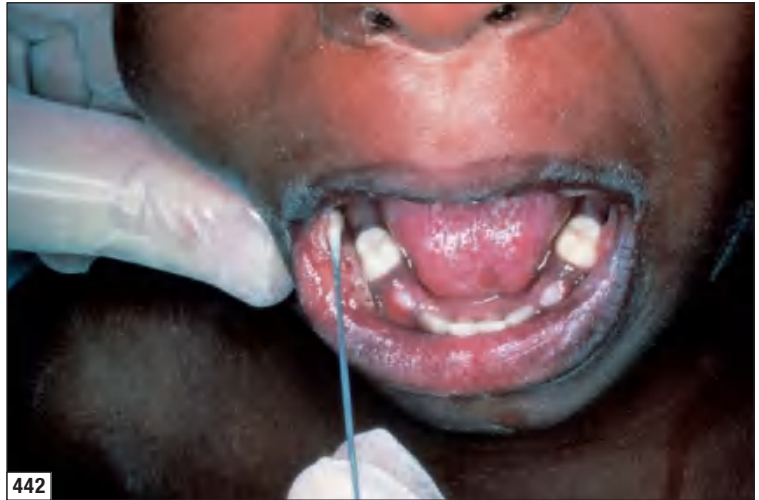440

Figure 440. Oral erythematous candidosis and extensive caries in HIV disease.



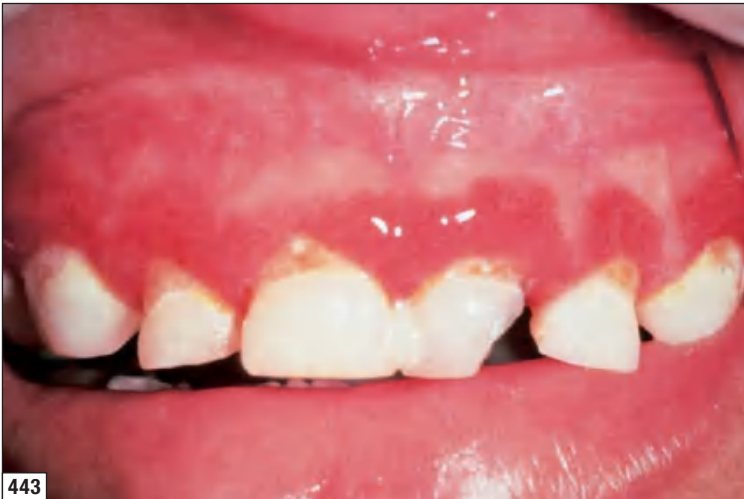441

Figure 441. HIV salivary gland disease affecting predominantly the parotid glands.

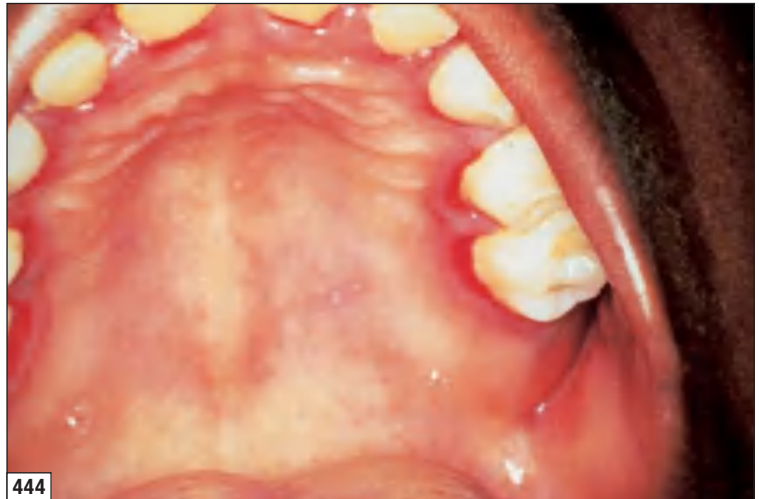

442

Figure 442. Intraoral herpetic ulceration in the buccal mucosa in a patient with AIDS who also has oral candidosis.

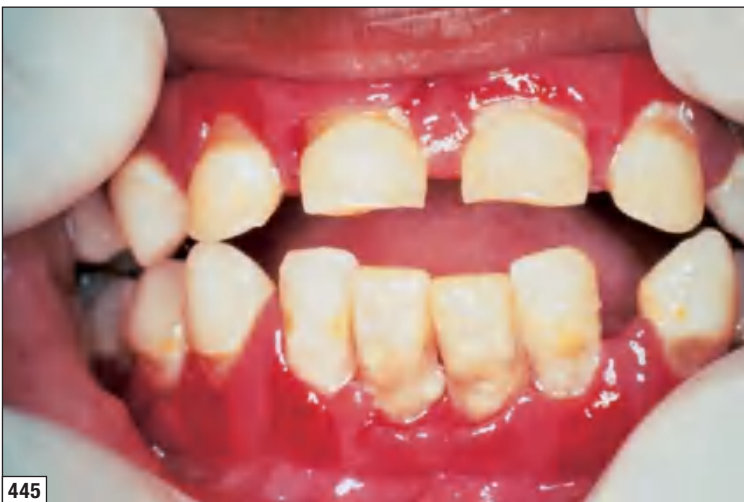

443

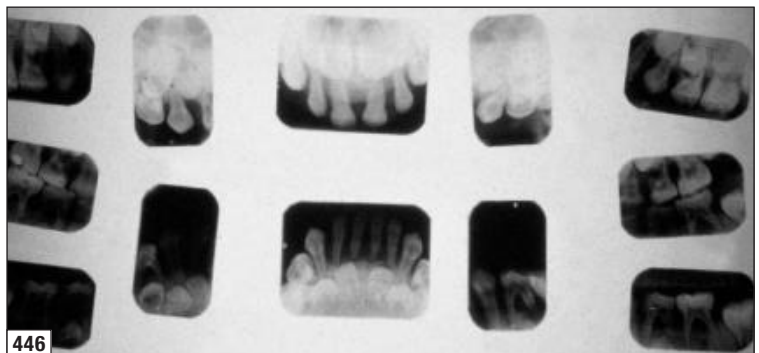

444

Figure 444. HIV gingivitis showing linear erythematous band at the gingival margin and good oral hygiene.



445



446

Figure 446. HIV periodontitis: radiographs showing alveolar bone loss.

Oral features are now classified as commonly associated with HIV infection, less commonly associated or strongly associated with HIV infection but rare in children (Table 31).

Oral candidosis (p. 128), especially thrush and erythematous candidosis, is probably the most common oral lesion and is seen in over 60% of patients, often as an early manifestation. It may be a predictor of other opportunistic infections and of esophageal thrush. Other types of oral candidosis may be seen, including angular stomatitis. Xerostomia may predispose to candidosis and also to dental caries. There is an increase, in HIV infection and AIDS, in antifungal resistance, in non-albicans species, such as *Candida krusei*, and new species such as *C. dubliniensis* and *C. inconspicua*.

Hairy leukoplakia of the tongue is uncommon; it is not known to be premalignant, but it is a predictor of disease progression. The leukoplakia may be corrugated (or 'hairy') and usually affects the lateral margins of the tongue. Flat white lesions may be seen on the tongue in about one-third of cases. It is:

- associated with Epstein–Barr virus (EBV)
- seen on the tongue lateral margins
- a white lesion not removable by wiping
- of no known malignant potential
- a predictor of bad prognosis

Treatment is not often required, but it resolves with aciclovir or anti-retroviral agents.

Recurrent viral infection may cause oral ulcers. Herpes simplex may cause labial or intraoral lesions in AIDS, presenting as chronic ulcers. Cytomegalovirus may also cause ulcers. Other oral viral infections include human papillomavirus (HPV) infections and, in particular, perioral verrucae.

Kaposi's sarcoma is rarely a feature of childhood AIDS, being associated with human herpesvirus-8 (HHV-8), mainly transmitted sexually. Typically it:

- occurs on the palate or maxillary gingivae
- presents as red, blue or purple macules, which progress to papules, nodules or ulcers
- is associated with human herpesvirus-8
- responds poorly to irradiation
- responds transiently to chemotherapy.

Oral lesions are often managed with intralesional vinblastine or systemic chemotherapy if there are extraoral lesions.

Lymphomas are rare, but typically:

- non-Hodgkin's lymphomas
- in the maxillary gingivae/fauces
- part of widespread disease
- associated with EBV
- resistant to therapy.

Table 31. Lesions associated with HIV infection in children. From Ramos-Gomez FJ, Flaitz C, Catapano P et al. Classification, diagnostic criteria, and treatment recommendations for orofacial manifestations in HIV-infected pediatric patients. *J Clin Pediatr Dent* 1999;23:85–96.

Group 1. Lesions commonly associated with pediatric HIV infection

- Candidosis, pseudomembranous, erythematous, angular cheilitis
- Linear gingival erythema
- Herpes simplex infection
- Parotid enlargement
- Recurrent aphthous ulcers

Group 2. Lesions less commonly associated with pediatric HIV infection

- Bacterial infections
- Periodontal disease
- Seborrheic dermatitis (perioral)
- Viral infections (cytomegalovirus, human papillomavirus, varicella–zoster virus, molluscum contagiosum)
- Xerostomia

Group 3. Lesions strongly associated with HIV infection, but rare in children

- Neoplasms: Kaposi's sarcoma and non-Hodgkin's lymphoma
- Hairy leukoplakia
- Tuberculosis-related ulcers

Chemotherapy is required.

Aphthous-type ulcers, especially of the major type, may appear in HIV disease. Granulocyte colony stimulating factor or thalidomide can be helpful in HIV-related aphthous-like ulceration when topical steroids are ineffective.

Other infections may be seen. Mouth ulcers are also occasionally caused by opportunistic pathogens such as mycobacteria and rarely by histoplasma or cryptococcus.

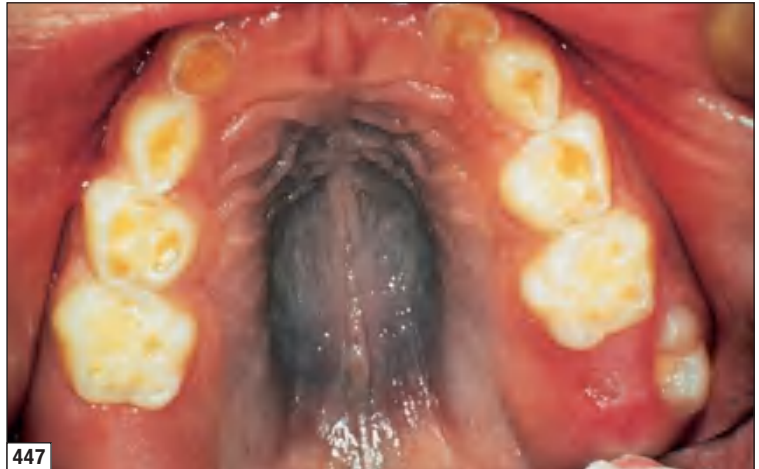
Ulcerative gingivitis, and destructive periodontitis appear to be features of HIV infection. HIV *Parotitis* is relatively common in children who have AIDS, but of unknown etiology.

Other oral or perioral lesions in HIV infection include cervical lymph node enlargement, petechiae and cranial neuropathies.

APLASTIC ANEMIA

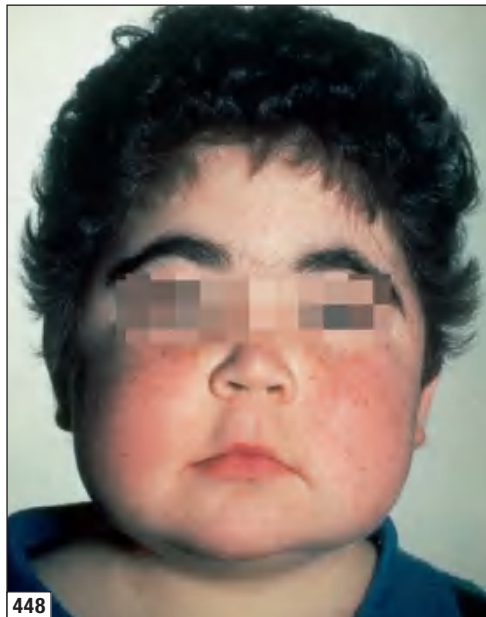Clinical features of aplastic anemia (Figs 447–449) depend on the predominant cell type affected and therefore there may be features of:

- thrombocytopenia – spontaneous purpuric or ecchymotic hemorrhages of the skin and mucous membrane
- leukopenia, (particularly neutropenia) leading to decreased resistance to infection and manifesting as severe oral ulceration, often associated with opportunistic organisms – typically there is, as in agranulocytosis, only a minimal red inflammatory halo around the ulcers
- anemia
- a combination of these features (pancytopenia).



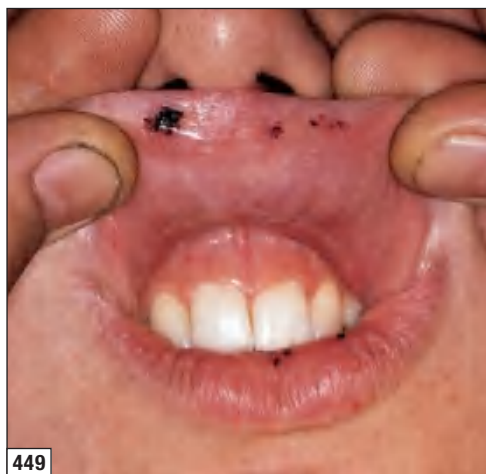447

Figure 447. The palatal bruising in this patient with aplastic anemia and thrombocytopenia occurred after sucking confectionery.



448

Figures 448. Systemic corticosteroid therapy for the patient in Figure 447 has resulted in hirsutism and a rounding of the facial features – so called 'moon face'.



449

Figure 449. Oral purpura in aplastic anemia. Similar lesions are not infrequently seen because of trauma in healthy persons.

BONE MARROW TRANSPLANTATION

Bone marrow transplantation (Figs 450–452) is often the treatment for aplastic anemia, leukemia and other disorders. Oral complications are common and can be a major cause of morbidity. The underlying disease, chemo- or radio-therapy and graft versus host disease (GVHD) may result in:

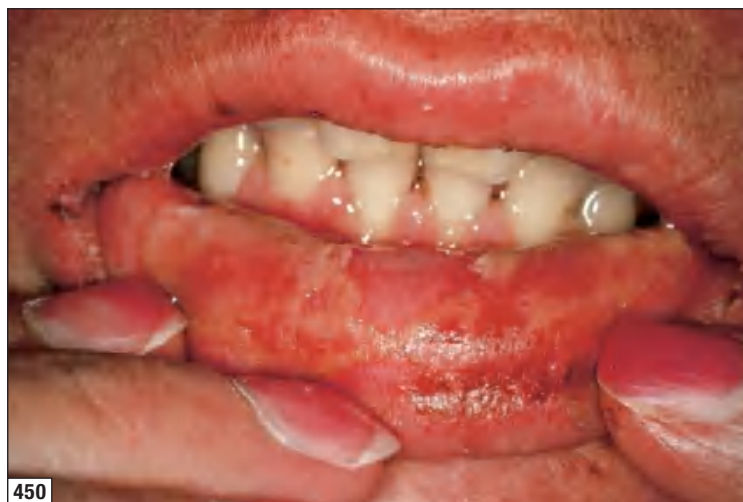- mucositis
- infections
- bleeding
- xerostomia
- loss of taste.

The oral manifestations of *acute* GVHD consist of painful mucosal desquamation and ulceration and/or cheilitis, and lichenoid plaques or striae. Small white lesions affect the buccal and lingual mucosa early on, but clear by day 14. Erythema and ulceration are most pronounced at 7–11 days after BMT, and may be associated with obvious infection. The ventrum of the tongue, buccal and labial mucosa and gingiva may be affected by ulceration or mucositis.

Candidosis, herpes simplex stomatitis and occasionally herpes zoster are the most common oral opportunistic infections.

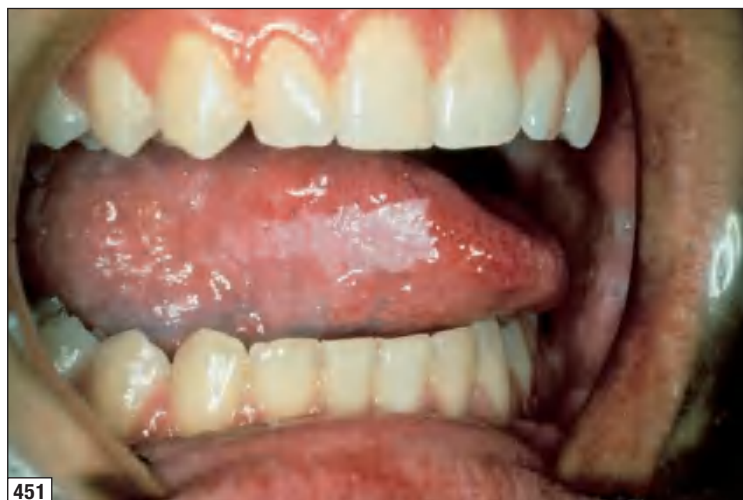Gingival bleeding and oral purpura are potential complications.

The oral lesions in *chronic* GVHD are coincident with skin lesions, and include generalized mucosal erythema, lichenoid lesions, mainly in the buccal mucosa, and/or sclerodermatous reactions with xerostomia and depressed salivary IgA levels in the minor gland. Xerostomia is most important in the first 14 days after transplantation and is a consequence of drug treatment, irradiation and/or GVHD. Xerostomia predisposes to caries.



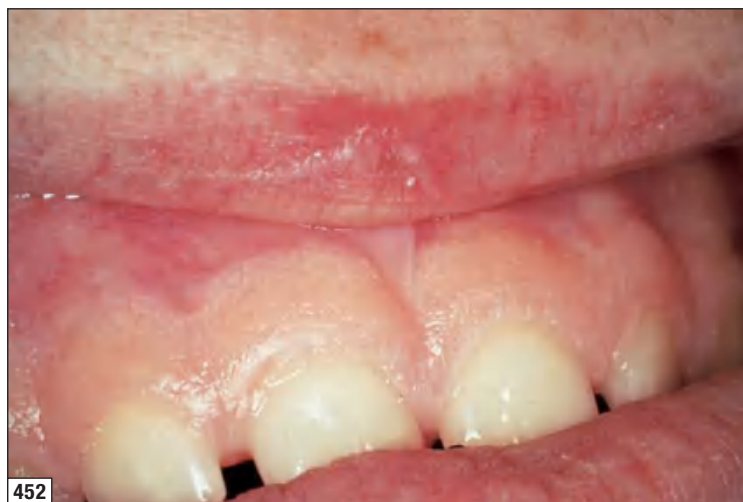450

Figures 450, 451. Labial ulceration and mucositis in bone marrow transplantation.



451

Figure 451. Lichenoid mucositis in chronic GVHD.

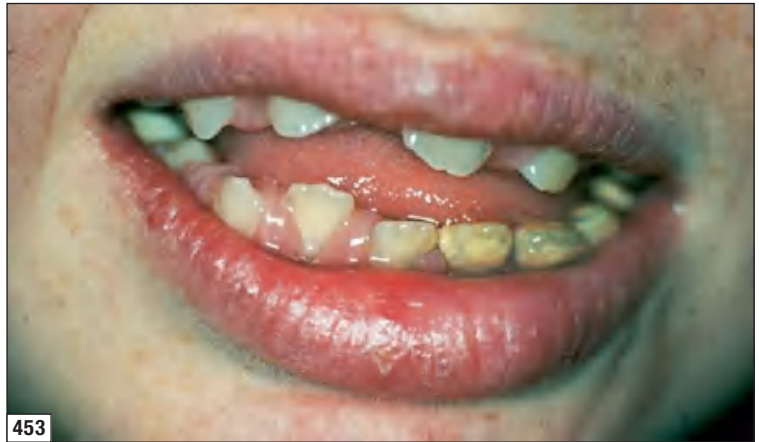

452

Figure 452. Ciclosporin-induced gingival hyperplasia in a bone marrow transplant recipient.

CEREBRAL PALSY

There are no oral changes specific to cerebral palsy (Fig. 453), but there may be bruxism, malocclusion, and oral disease as a consequence of plaque accumulation (inflammatory periodontal disease) and high sugar intake (caries).



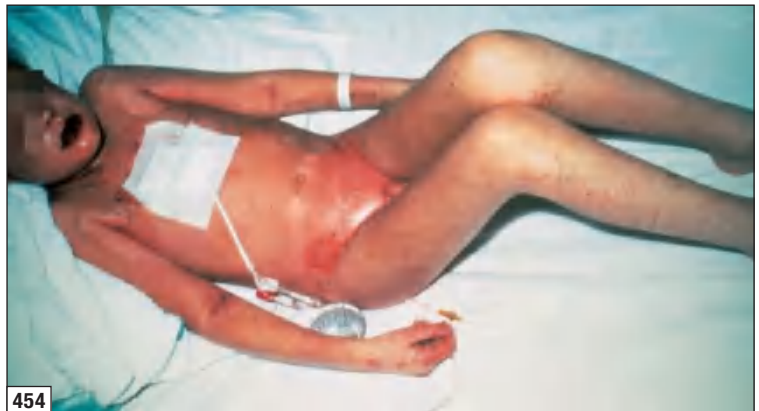453

Figure 453. Cerebral palsy, showing calculus on left mandibular teeth, and phenytoin-induced gingival hyperplasia.

CHEMOTHERAPY

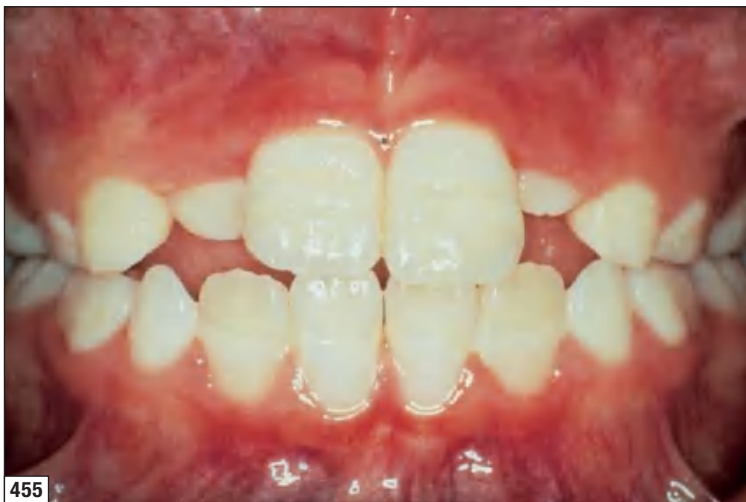Chemotherapy can have immediate and long-term oral effects (Figs 454–462). The immediate effects of chemotherapy include hemorrhagic, infective and ulcerative oral complications. These typically resolve once chemotherapy is finished.

Long-term effects of chemotherapy, however, are recorded in the teeth that were mineralizing when treatment was given and include crown abnormalities (hypoplasia, microdontia or taurodontism) and root anomalies (shortened, constricted, tapered or thinned). Teeth may also fail to develop and there may be craniofacial maldevelopment.



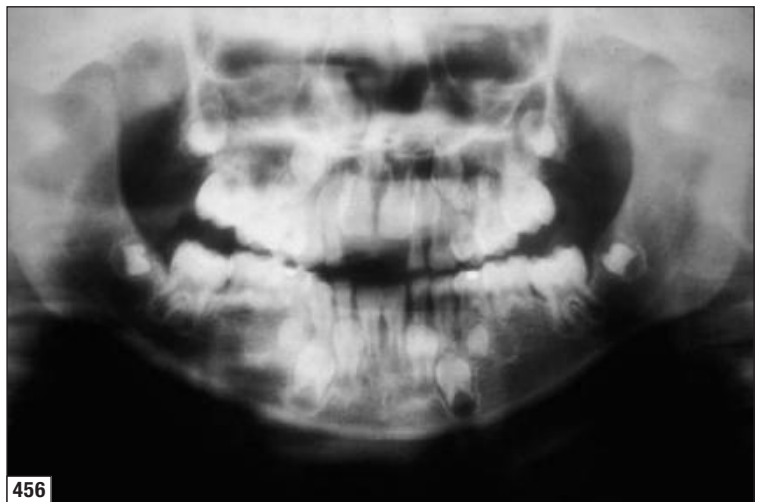454

Figure 454. Fulminant septicemia of oral origin in a child undergoing chemotherapy.



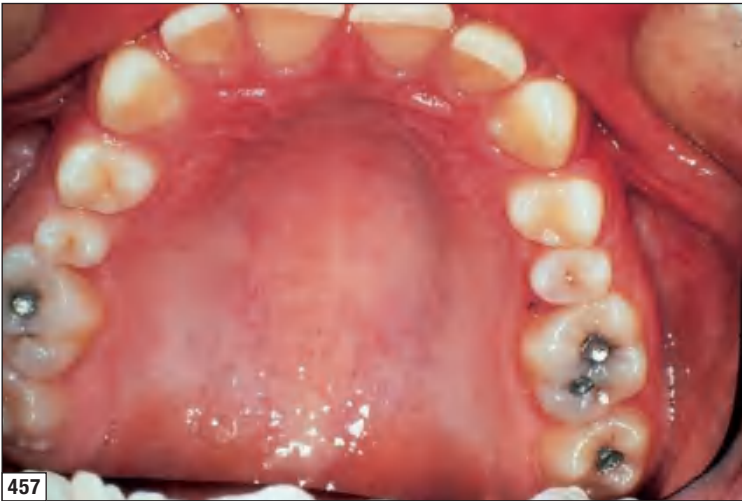455

Figure 455. Mild enamel hypoplasia in a child who received chemotherapy from 2–4.5 years of age for acute lymphoblastic leukemia.



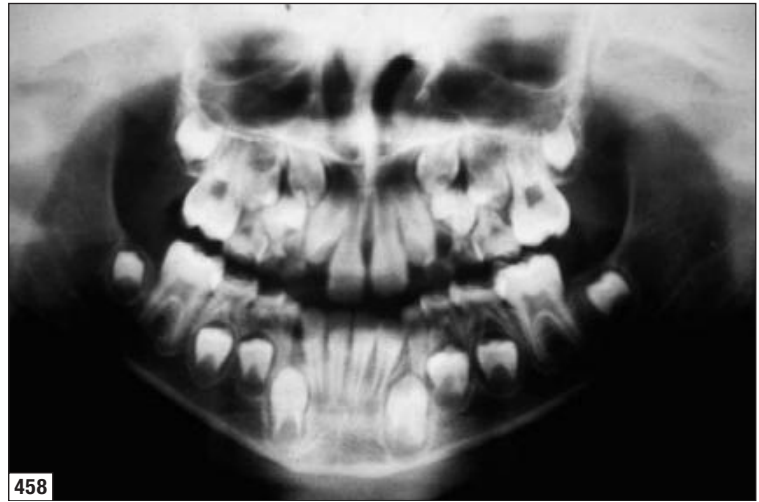456

Figure 456. Microdontia of developing second permanent molars. Chemotherapy was given from 1–3 years of age for an embryonal yolk sac tumor.



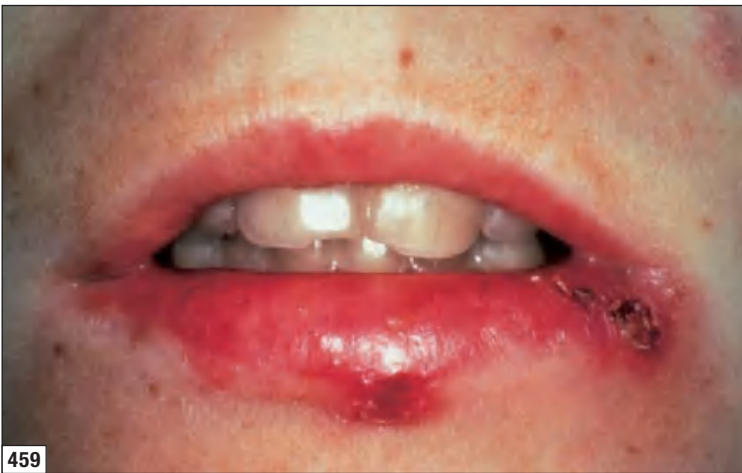457

Figure 457. Erupted microdontic maxillary second premolars. This patient received chemotherapy for 2.5 years, which commenced at age 1.5 years for acute lymphoblastic leukemia.



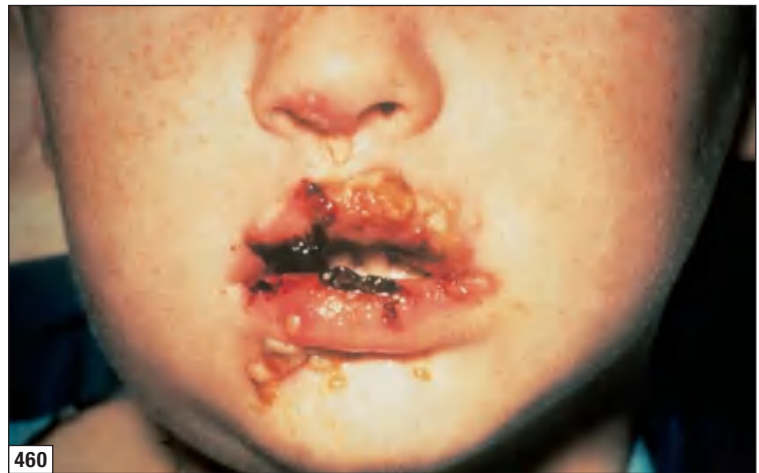458

Figure 458. Microdontic second permanent molars and taurodontic first permanent molars in a child who received chemotherapy for 2.5 years, which commenced at age 2 years for acute lymphoblastic leukemia.



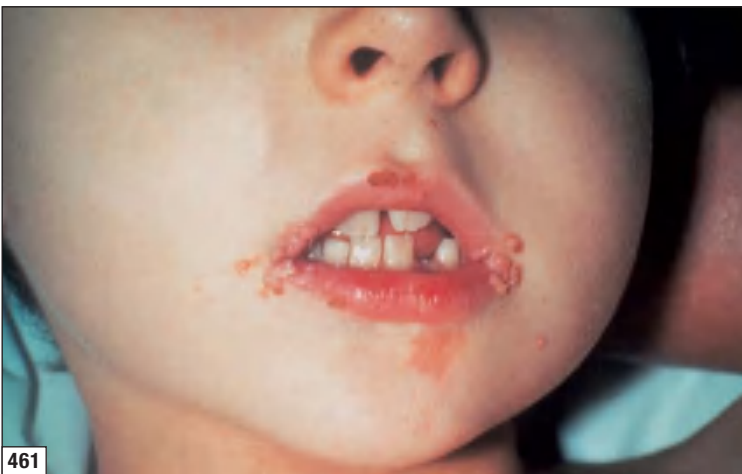459

Figure 459. Herpes virus infection in children undergoing chemotherapy.



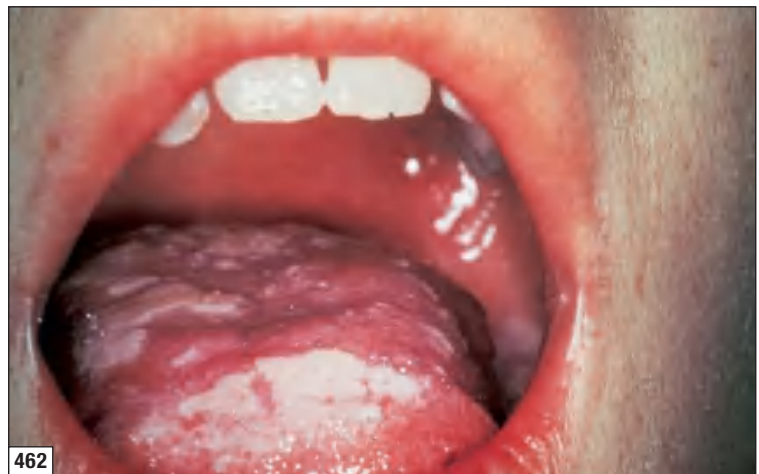460

Figure 460. Herpes virus infection in children undergoing chemotherapy.



461

Figure 461. Papilloma virus infection in a child undergoing chemotherapy.



462

Figure 462. Candidosis (thrush) in a child undergoing chemotherapy.

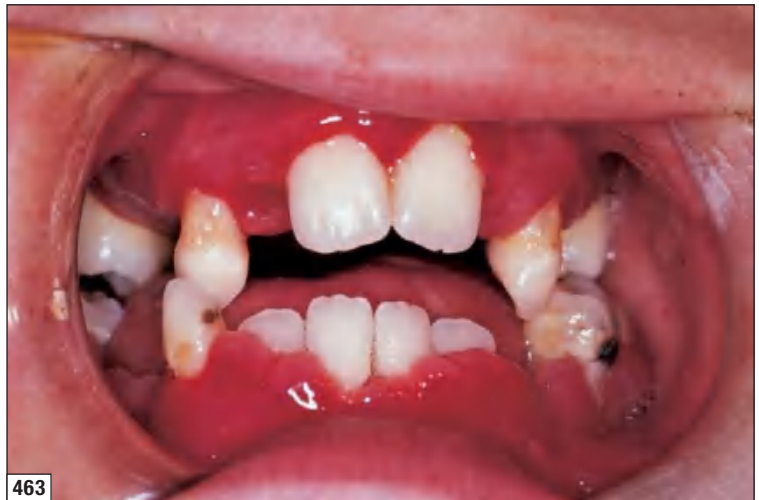CONGENITAL IMMUNODEFICIENCIES

Cyclic neutropenia

Cyclic neutropenia (Figs 463–466) results in a drop in polymorphonuclear neutrophil count, and sometimes other leukocytes, about every 21 days. Destructive periodontal disease, recurrent ulcerative gingivitis and recurrent mouth ulcers are frequent manifestations.

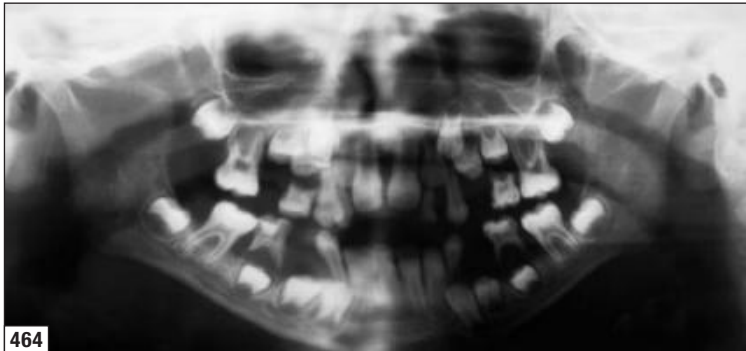Chronic granulomatous disease

Chronic granulomatous disease is predominantly an X-linked granulocyte defect in which neutrophils and monocytes are defective at killing catalase-positive microorganisms and presents typically with cervical lymph node enlargement (Fig. 467) and suppuration. Recurrent infections in early childhood may result in enamel hypoplasia and there is also a predisposition to oral ulceration and periodontal destruction.



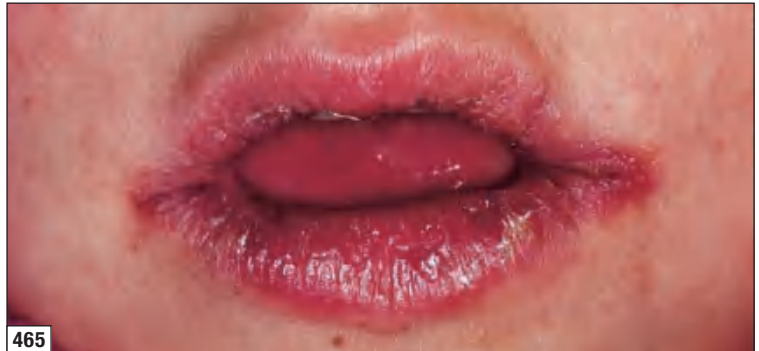463

Figure 463. Periodontal disease in cyclic neutropenia.



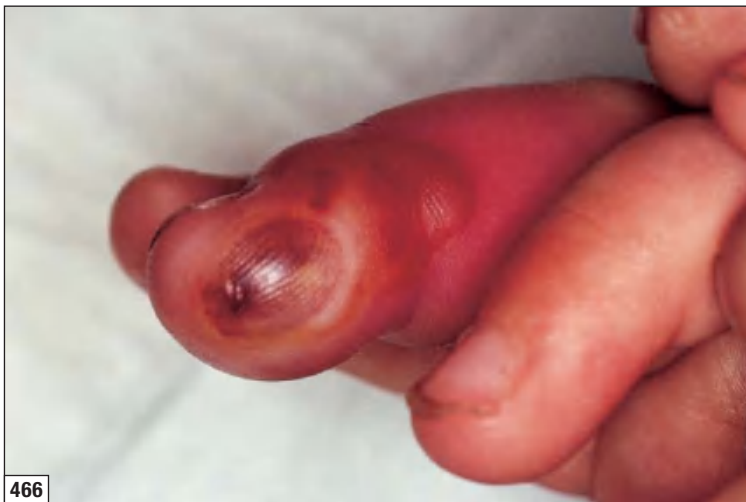464

Figure 464. Radiograph showing periodontal disease in cyclic neutropenia.



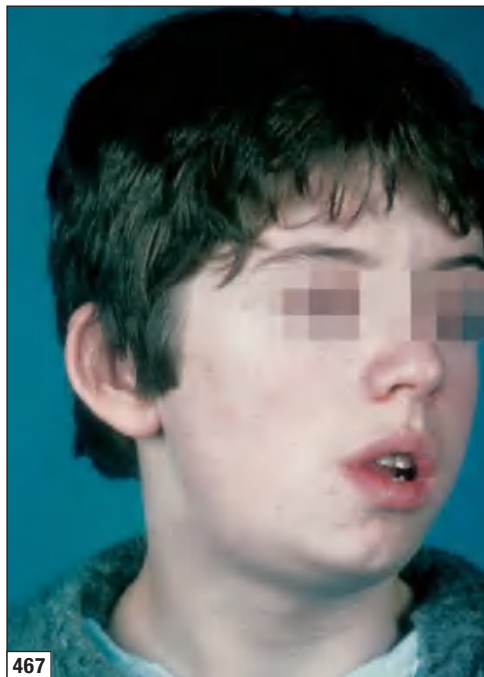465

Figure 465. Angular stomatitis in cyclic neutropenia.



466

Figure 465. Skin infections in cyclic neutropenia.



467

Figure 467. Submandibular lymphadenitis in chronic granulomatous disease.

T cell immune defects

Many primary immune defects are known, but some are barely compatible with life: DiGeorge syndrome for example, has additional profound defects such as cardiovascular defects as well as T cell immunodeficiencies. An early and prominent feature in cell-mediated (T cell) immune defects is chronic oral candidosis, which may present as thrush and/or angular stomatitis (Fig. 468). There is also a predisposition to recurrent lesions of herpes simplex (Fig. 469) and varicella-zoster virus. Neutrophil defects in particular, predispose to mouth ulcers and accelerated periodontitis. Severe infections in the neonate can disturb odontogenesis, causing enamel hypoplasia. In the past, tetracycline treatment caused tooth discoloration.

Acatalsia

Acatalsia is a rare neutrophil defect seen mainly in Japan, Korea, Israel and Switzerland and may manifest with gangrene.

Selective IgA deficiency

Selective IgA deficiency is the most common primary (genetically determined) immune defect. Some patients are healthy, but others, particularly those who also lack IgG₂, suffer recurrent respiratory infection, autoimmune disorders and atopy. Many have mouth ulcers, and there may be a reduced protection against dental caries.

Bruton's syndrome (sex-linked panhypogammaglobulinemia)

Bruton's syndrome affects males almost exclusively and presents mainly with recurrent pyogenic respiratory infections and may predispose to mouth ulcers.

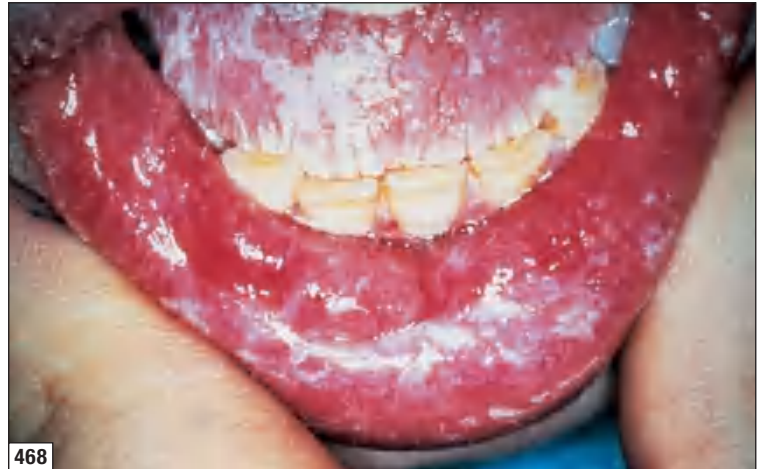

Figure 468. Oral candidosis (thrush) in a congenital T cell immune defect.

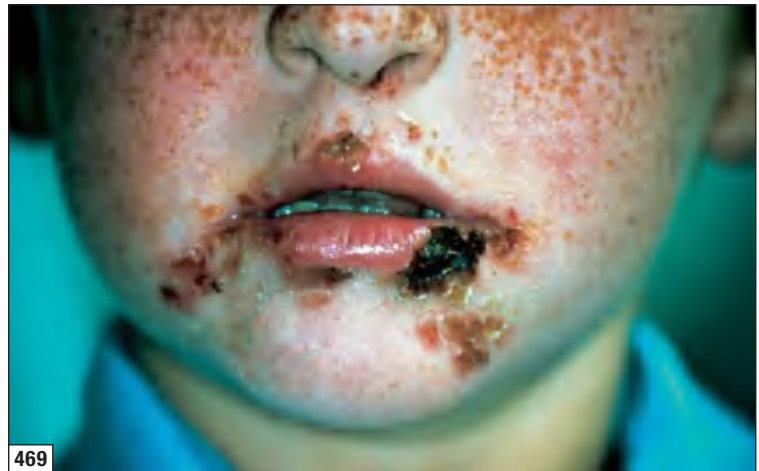

Figure 469. Severe herpes labialis in a child with a congenital T lymphocyte defect.

Chronic mucocutaneous candidosis

Chronic mucocutaneous candidosis (Figs 470–473) is a heterogeneous group of syndromes characterized by cutaneous, oral and other mucosal candidosis, usually from early life. In CMC, candidosis involves both skin and nails in varying severity. The oral lesions include white plaques, which eventually become widespread, thick and adherent and the tongue fissured. *Candida albicans* is the usual cause, but *C. tropicalis*, *C. parapsilosis*, *C. guilliermondii* and *C. krusei* may also be implicated, and the organism frequently becomes resistant to antifungals.

Type 1 CMC has a familial pattern, an early onset and may be associated with iron deficiency anemia and postcricoid webs.

Type 2 CMC includes granulomas, chronic oral candidosis, and candidosis sometimes affecting the larynx and eyes.

Type 3 CMC (candidosis–endocrinopathy syndrome) also includes hypoparathyroidism (with dental defects) and often hypoadrenocorticism, hypothyroidism and diabetes mellitus. Acute candidosis is discussed on p. 128.

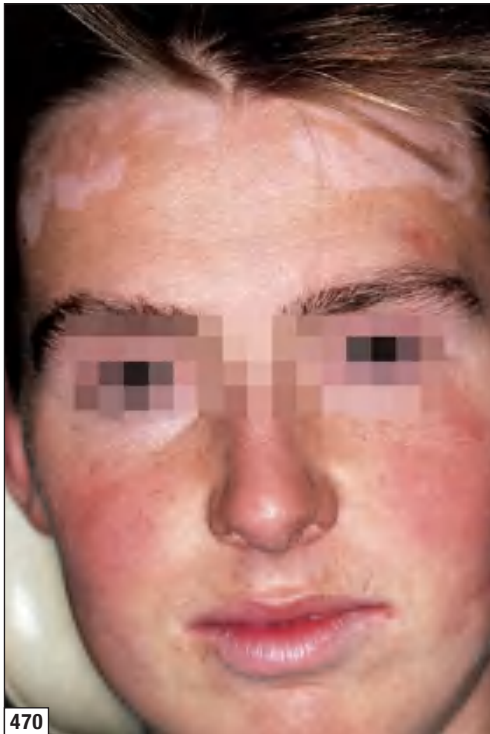

Figure 470. Hyperpigmentation as a result of Addison's hypoadrenocorticism and vitiligo in a boy with candidosis–endocrinopathy syndrome.

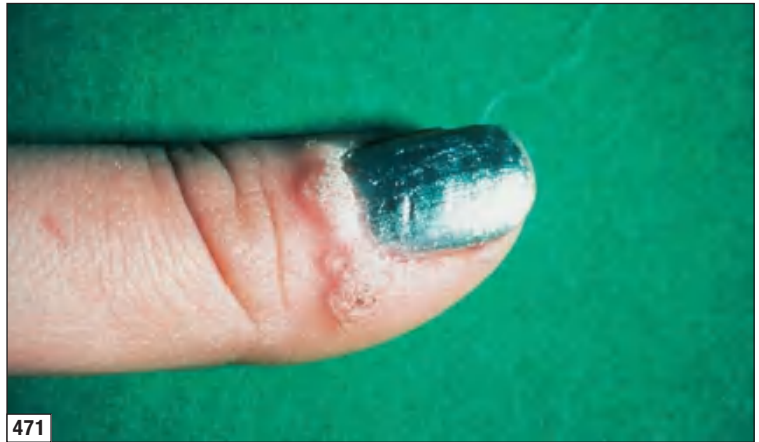

Figure 471. Nail involvement is common in chronic mucocutaneous candidosis.

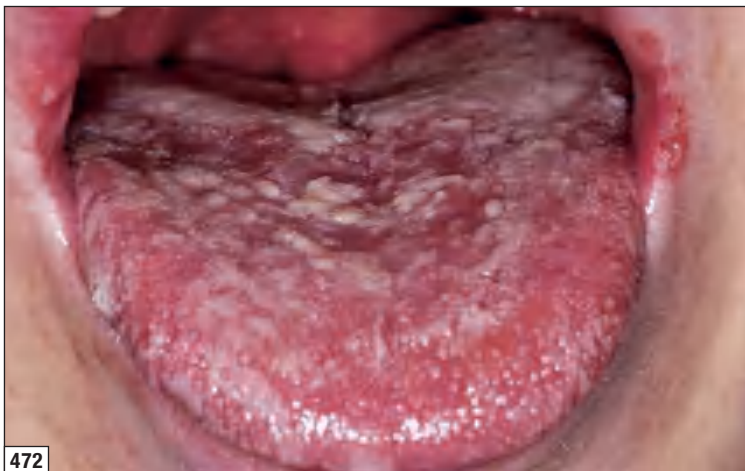

Figure 472. Chronic oral candidosis in chronic mucocutaneous candidosis.

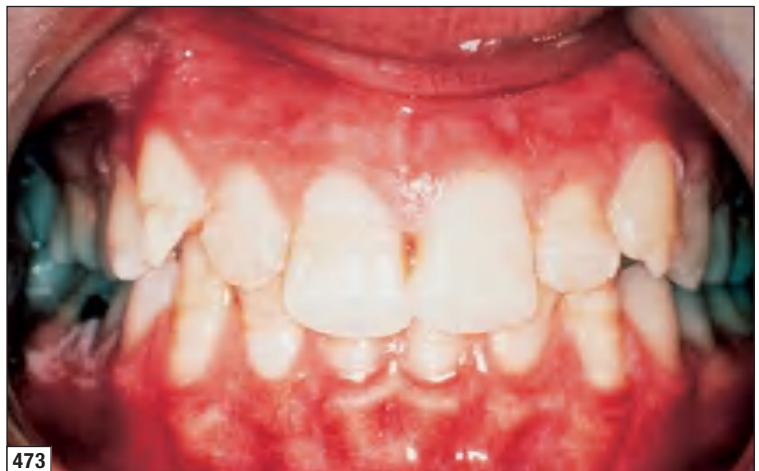

Figure 473. Chronological hypoplasia of the anterior teeth in chronic mucocutaneous candidosis.

Wiskott–Aldrich syndrome

Wiskott–Aldrich syndrome (Fig. 474) is a rare complex immune deficiency syndrome with thrombocytopenia and eczema. It is associated with oral petechiae, oral ulceration, premature tooth loss and/or large pulp chambers.

Severe combined immunodeficiency

Severe combined immunodeficiency (SCID; Fig. 475) is a rare primary immunodeficiency with an overall frequency estimated to be 1 in 75000 live births. It represents a group of diseases characterized by deficient T and B cell function with resulting susceptibility to infection (viral, fungal, protozoal and bacterial) and secondary failure to thrive. SCID syndromes are caused by multiple gene defects.

Treatment of SCID is by bone marrow transplantation after a conditioning regimen of high-dose chemotherapy. Although the duration of this chemotherapy is not as long as conventional anticancer regimens there is the same risk of dental side-effects – hypodontia, microdontia, hypoplasia, taurodontism, shortening and thinning of roots.

CYSTIC FIBROSIS

Cystic fibrosis (Figs 476, 477) is the commonest cause of chronic suppurative lung disease of children in the developed world. It is an autosomal recessive condition with a frequency of 1 in 2000 births that affects many exocrine and mucus-secreting glands. The primary abnormality involves defective cell membrane transport, and thus sweat glands, salivary glands and pancreas produce abnormal secretions resulting in duct obstruction. Salivary glands may swell and there may be xerostomia.

A defect in ciliary mechanism leads to recurrent chest infections, chronic productive cough, halitosis, chest deformity, finger clubbing and poor growth. Central cyanosis is often present. Because of the recurrent chest infections requiring many courses of antibiotics and the development of resistance, the use of tetracyclines may be unavoidable. The teeth may then be affected by tetracycline staining.

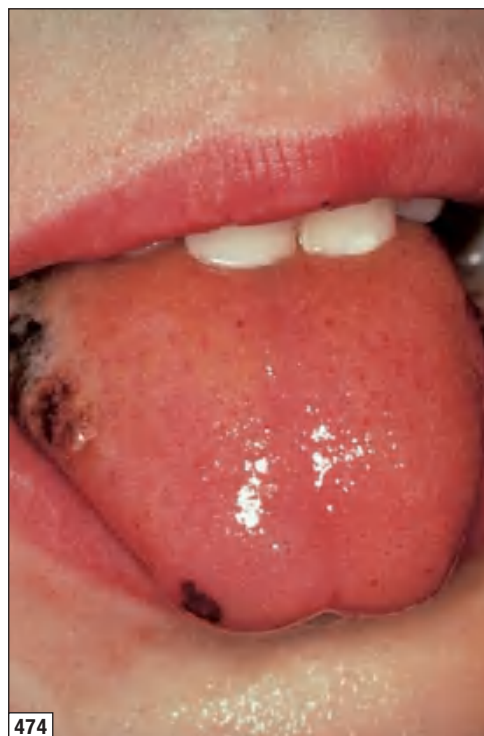

Figure 474. Oral purpura in the Wiskott–Aldrich syndrome.

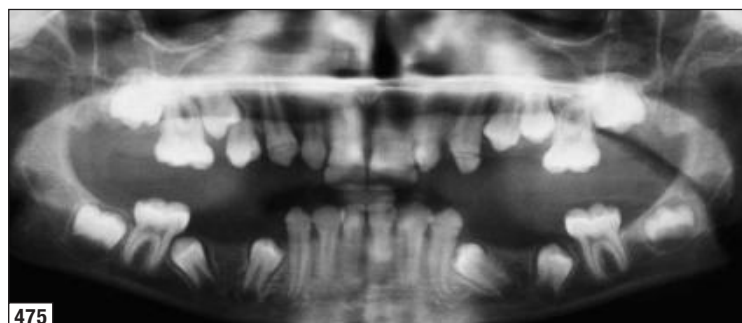

Figure 475. Severe combined immunodeficiency.

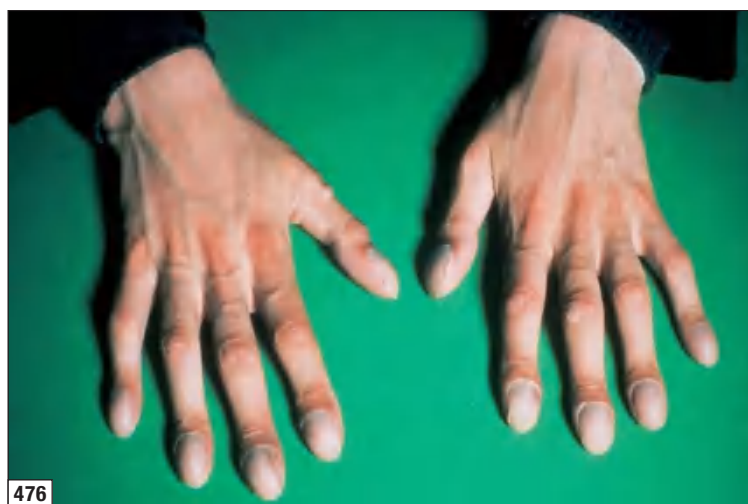

Figure 476. The hands of a patient with cystic fibrosis demonstrating cyanosis and finger clubbing.

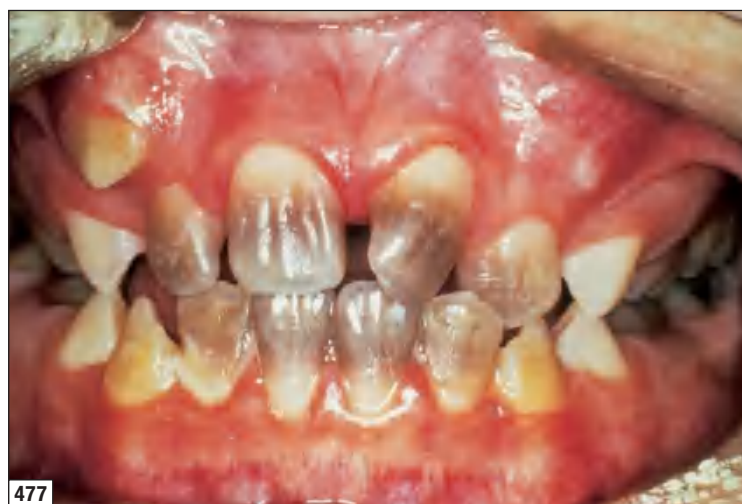

Figure 477. The teeth of the patient with cystic fibrosis demonstrating tetracycline staining.

DOWN SYNDROME

Down syndrome (Figs 478–481) is a trisomic chromosome anomaly usually involving chromosome 21, in most instances affecting children of elderly mothers. There is a typical mongoloid appearance. Brachycephaly and short stature are prominent features, there are anomalies of many organs, and virtually all patients have learning disability. A fairly characteristic, though not pathognomonic feature is the presence of white spots (Brushfield's spots) around the iris. Other characteristic features are a single palmar crease (simian crease) and clinodactyly of the fifth finger.

Patients with Down syndrome have multiple immune defects, and blepharitis, keratitis and upper respiratory infections are common, as are systemic infections, such as viral hepatitis.

Cheilitis and cracking of the lips may be seen, possibly because of mouthbreathing. Macroglossia and fissured tongue are also common and the midface is often hypoplastic with palatal anomalies.

Over-retained primary teeth are much more of a problem than premature loss of teeth. Early loss of teeth can be a feature, not only because of poor oral hygiene in many patients, but also because the teeth have short roots and there may be rapidly destructive periodontal disease. Cleft lip and palate are more prevalent in Down syndrome than in the general population.

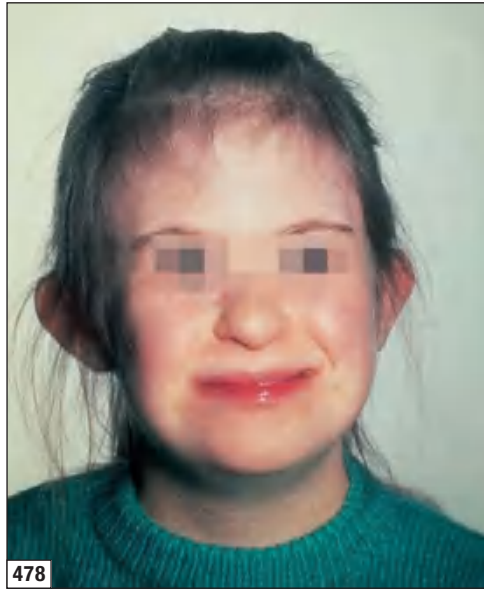


Figure 478–481. Down syndrome.

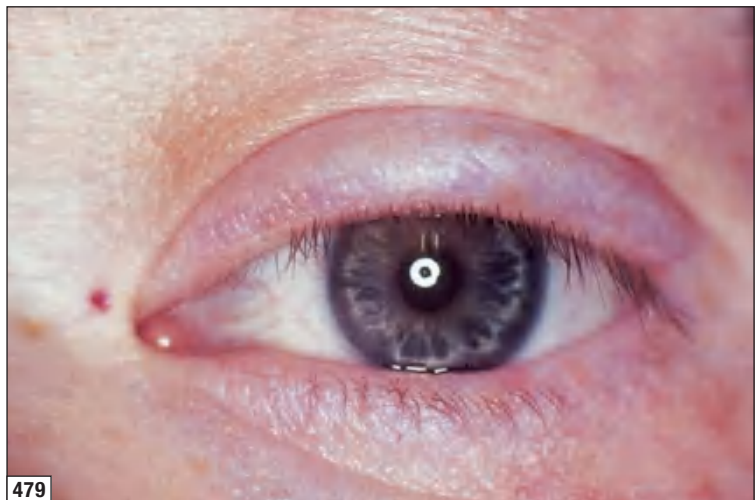

Figure 479. Brushfield spots in the iris are fairly characteristic of Down syndrome.

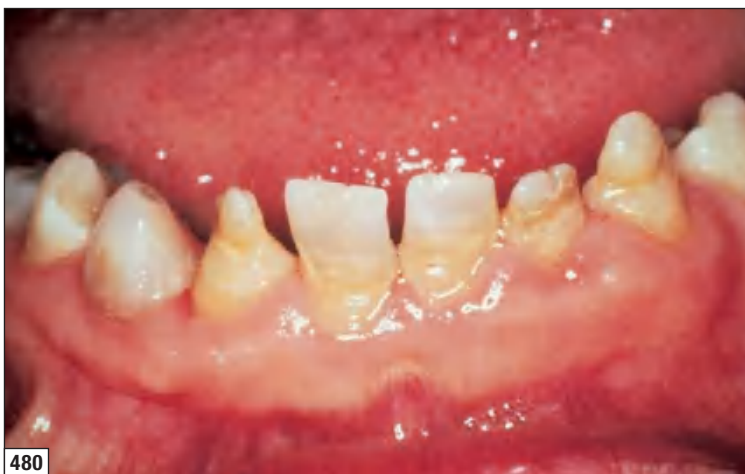

Figure 480. Hypoplasia of teeth is often associated with Down syndrome.

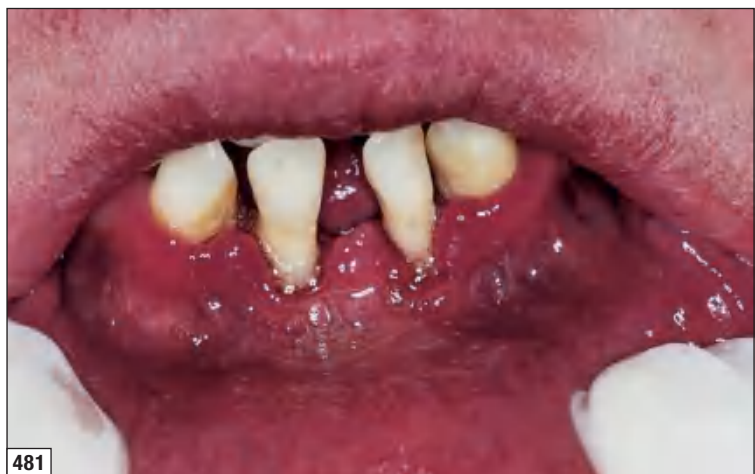

Figure 481. Aggressive periodontitis associated with Down syndrome.

FALLOT'S TETRALOGY

About 10% of all congenital heart defects and 66% of all cyanotic congenital heart defects are a result of Fallot's tetralogy. The condition involves ventricular septal defect, pulmonary stenosis, right ventricular hypertrophy and dextroposition of the aorta. There is marked right to left shunting of blood – resulting in central cyanosis – which can be clearly seen in the lips and tongue.

HEMOPHILIAS

Any breach of mucosa in hemophilia, especially tooth extraction, can lead to persistent bleeding (Fig. 482), which is occasionally fatal. One danger is that hemorrhage into the fascial spaces, particularly from surgery in the lower molar region, can track into the neck and mediastinum and constrict the airway. Hemorrhage after extraction can be controlled with factor replacement, use of antifibrinolytics such as tranexamic acid, and desmopressin.

Tooth eruption and exfoliation of primary teeth are usually uneventful, but occasionally there can be a small bleed into the follicle. Spontaneous gingival hemorrhage, oral petechiae and ecchymoses are rare.

HIV infection and viral hepatitis have occurred in patients given blood transfusions or blood products before appropriate exclusion of high-risk or HIV-positive donors. This is no longer a major problem and with recombinant products available, heat treatment of blood products and factors is not used.

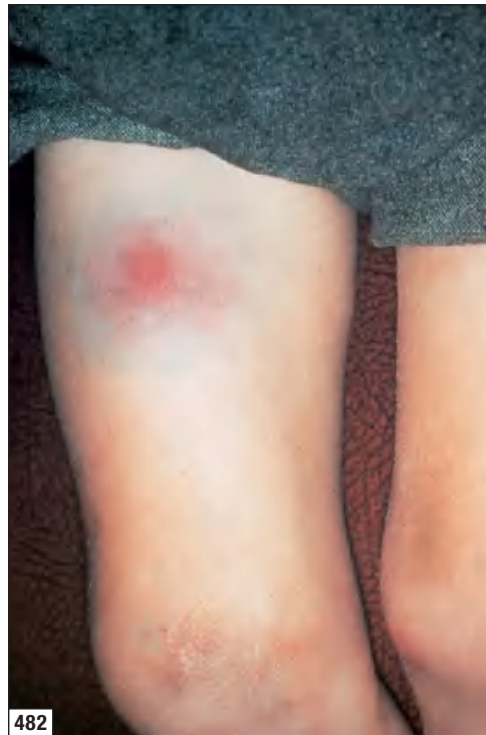

Figure 482. A large hematoma of the right thigh as a result of persistent bleeding into the muscle in hemophilia A.

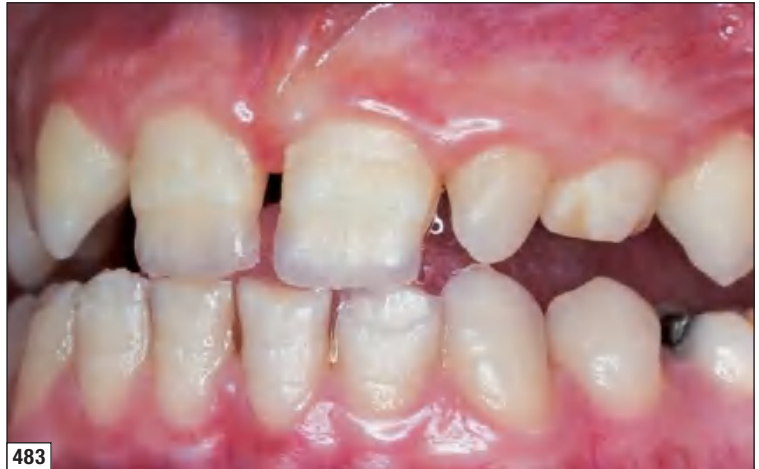482

HYPOPARATHYROIDISM

Congenital hypoparathyroidism may be associated with severe hypoplasia of the teeth, shortened roots and retarded eruption (Fig. 483). Congenital hypoparathyroidism is also a feature in rare patients with candidosis–endocrinopathy syndrome and DiGeorge syndrome, who also have chronic mucocutaneous candidosis.

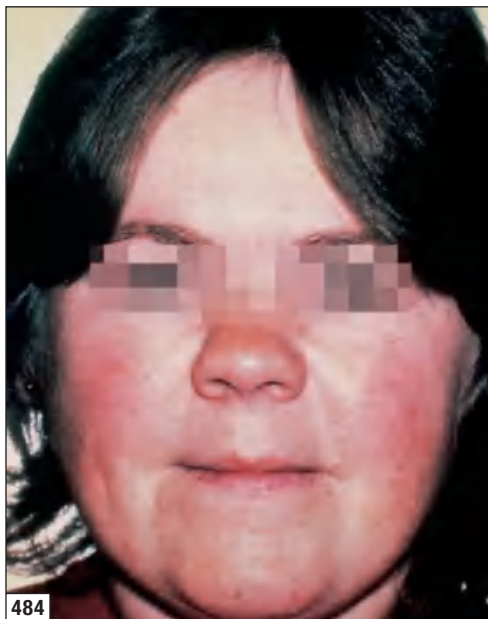Acquired hypoparathyroidism produces facial tetany (Chvostek’s sign), but no other oral manifestations.

Pseudohypoparathyroidism (Figs 484–488) is associated with elfin facies, short stature, short metatarsals and metacarpals, calcified basal ganglia and enamel hypoplasia. Parathyroid hormone is secreted, but the end-organs are unresponsive and there is also an association with other endocrine disorders, particularly hypothyroidism.



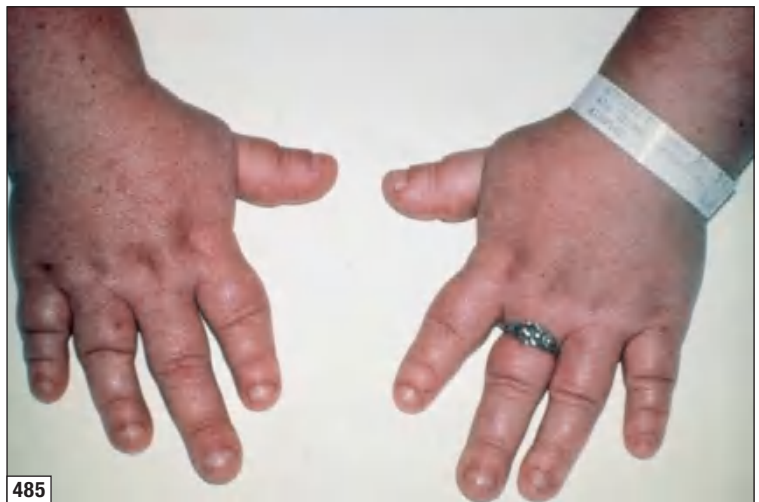483

Figure 483. Enamel hypoplasia in congenital hypoparathyroidism.



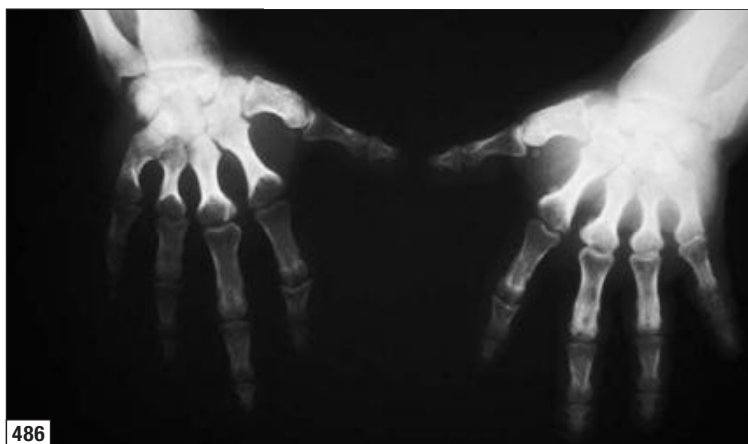484

Figure 484. The characteristic somatic features of round 'elfin facies' and short stocky neck in pseudohypoparathyroidism.



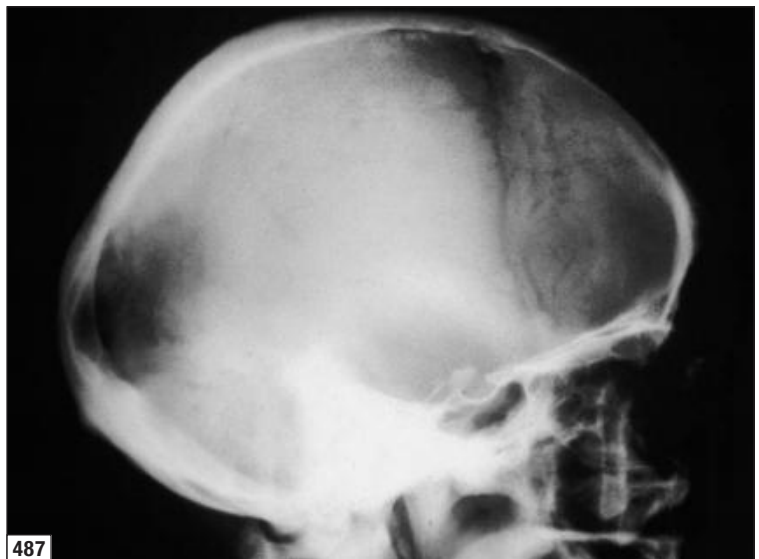
485

Figure 485. Pseudohypoparathyroidism. The small dumpy hands of the patient in Figure 484.



486

Figure 486. Pseudohypoparathyroidism. The radiographs of the patient in Figure 484 reveal shortening of all metacarpals and distal phalanges.



487

Figure 487. Pseudohypoparathyroidism. The lateral skull of the same patient in Figure 484 showing calcification within the basal ganglia.

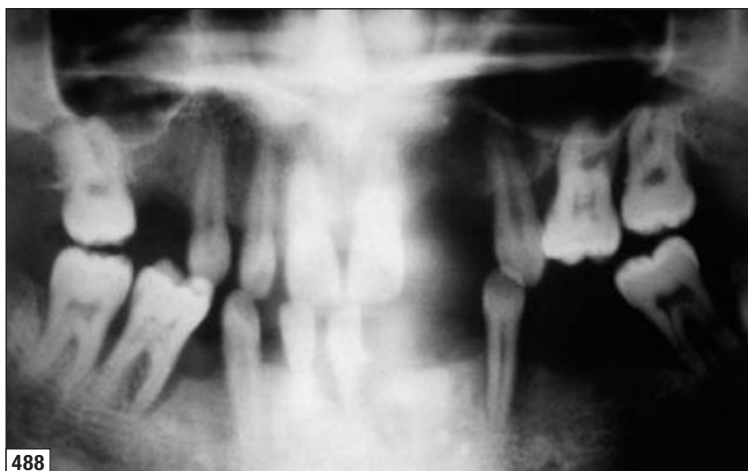

Figure 488. Pseudohypoparathyroidism. A panoramic view of the same patient in Figure 484 showing a decimated teenage dentition with pulp stones in the upper left and lower right first permanent molars.

IMMUNOSUPPRESSED PATIENTS

The most common orofacial lesions in immunosuppressed children are:

- candidosis
- herpes viral infections.
- Others include:
 - ulcers
 - periodontal disease
 - malignant neoplasms.

Candidosis (see p. 128)

Thrush and erythematous candidosis are common and often seen early. Factors that can increase the liability to candidosis include:

- xerostomia
- smoking
- corticosteroids
- antibiotics
- cytotoxic chemotherapy
- irradiation
- malnutrition.

Thrush presents as creamy white plaques that can be wiped off to leave a red base. Red persistent lesions are now termed erythematous candidosis and are especially noticeable on the palate and tongue.

Diagnosis

Diagnosis is mainly clinical.

Management

Candidosis is managed by:

- avoiding smoking
- treating predisposing causes (e.g. xerostomia)
- improving oral hygiene – chlorhexidine has some anticandidal activity

- antifungals, the choice depending on the severity and extent of disease, medical contraindications and other complications of the immunocompromising condition.

Herpes viral infections

Herpesviruses, especially herpes simplex virus (HSV) can cause herpes labialis or oral or perioral ulcers. Cytomegalovirus (CMV) may cause oral ulceration in patients with disseminated infection.

Hairy leukoplakia, a common, corrugated (or ‘hairy’) white lesion caused by Epstein–Barr virus (EBV), is usually seen in HIV infection and AIDS, but may be seen in any immunocompromising state. EBV can cause lymphomas.

Diagnosis

Diagnosis is clinical supported by viral studies – immunostaining and DNA studies.

Management

Aciclovir is the main antiviral active against HSV. Ganciclovir is needed for CMV infections.

Mouth ulcers

Ulcers in immunocompromised persons may be related to:

- aphthous-type ulcers (p. 132)
- infections – herpesviruses, mycoses (especially histoplasmosis or cryptococcosis), mycobacteria or syphilis, protozoa (e.g. leishmaniasis)
- malignant neoplasms
- drugs (e.g. cytotoxics or antiretroviral agents).

Diagnosis

Diagnosis can be difficult and biopsy with microbial studies may be needed.

Management

Specific therapies are often indicated. Chlorhexidine and topical analgesics can be helpful local treatments.

Gingival and periodontal disease

Necrotizing ulcerative gingivitis and periodontitis:

- occur disproportionately to the level of oral hygiene
- can be painful
- cause rapid alveolar bone loss.

Diagnosis

Diagnosis is clinical.

Management

Improved oral hygiene, debridement, chlorhexidine and sometimes metronidazole are needed.

Malignant neoplasms

Immunocompromising conditions may predispose to oral:

- leukoplakia
- carcinoma
- Kaposi’s sarcoma (KS)
- lymphomas.

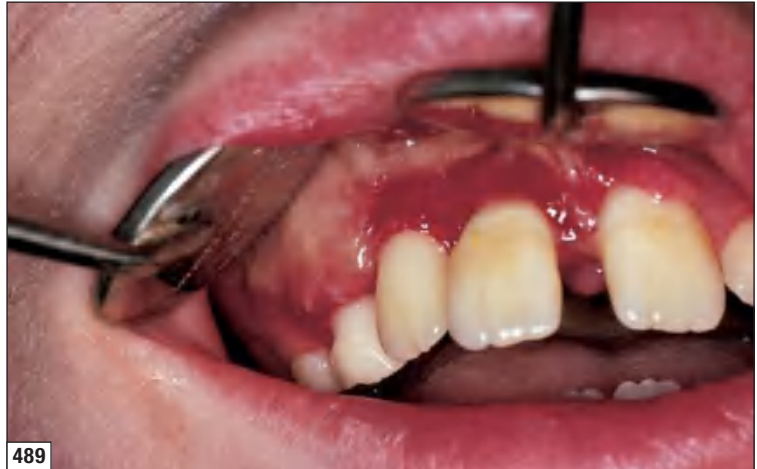LEUKEMIAS

Leukemia (Figs 489–493) results in the replacement of blood platelets, leukocytes and erythrocytes by malignant leukocytes. This causes:

- Thrombocytopenia – which leads to spontaneous gingival hemorrhage and oral purpura (Figs 489, 490), particularly where there is trauma. Chemotherapy may aggravate the bleeding tendency. Gingival hemorrhage can be so profuse as to dissuade the patient from oral hygiene, but this simply aggravates the problem as the gingivae then become inflamed, more hyperemic and bleed more profusely.
- Leukocyte dysfunction – which predisposes to infections and ulcers – some viral, bacterial or fungal infections, some nonspecific and some associated with cytotoxic therapy. Microbial infections – mainly fungal and viral – are common in the mouth and can be an appreciable problem for leukemic patients. Candidosis is extremely common, whereas aspergillosis and zygomycosis are rare. Recurrent herpes labialis is common in leukemic patients; recurrent intraoral herpes simplex is also common. The lesions can be extensive and, because of the thrombocytopenia, there is often bleeding into the lesion. Simple odontogenic infections can spread widely and be difficult to control. Nonodontogenic oral infections are also common in leukemic patients and can involve a range of

bacteria including *Staphylococcus aureus*, *Pseudomonas aeruginosa*, *Klebsiella pneumoniae*, *Staphylococcus epidermidis*, *Escherichia coli* and enterococci.

Leukemic deposits in the gingiva occasionally cause gingival swelling, a feature especially of myelomonocytic leukemia.



489
Figure 489. Gingival purpura in acute lymphoblastic leukemia.

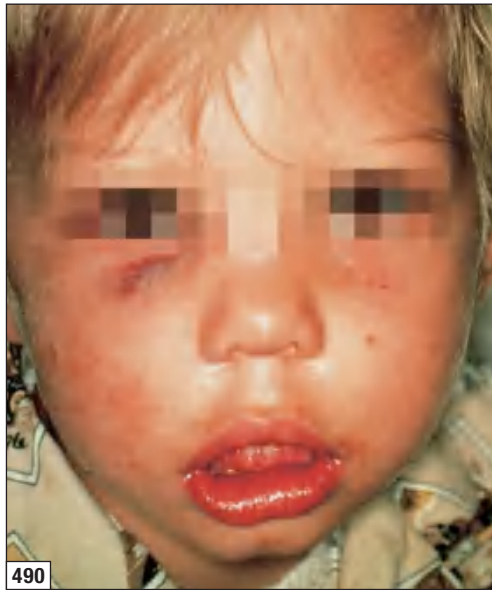
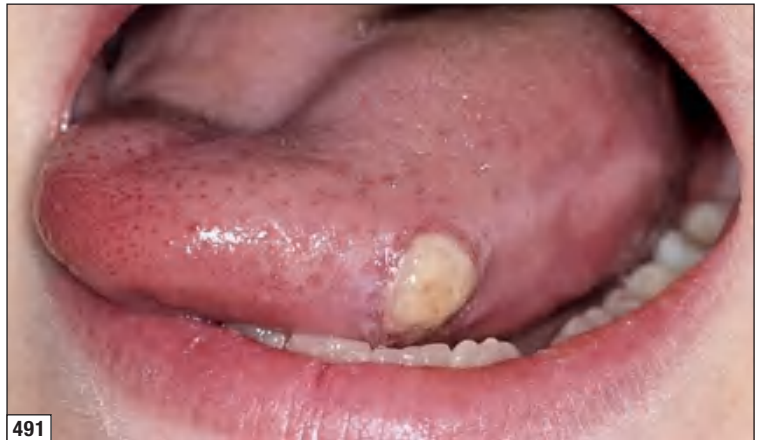
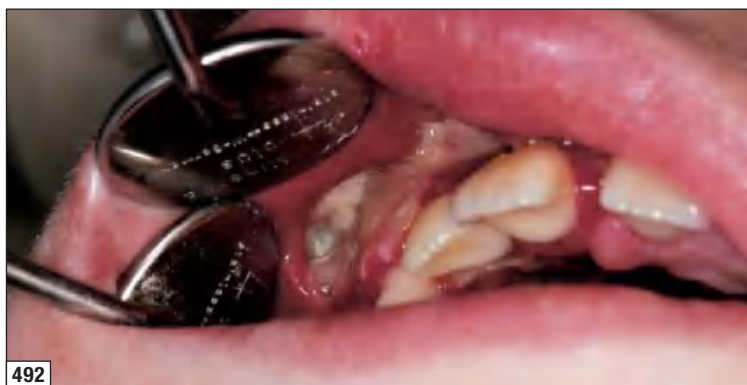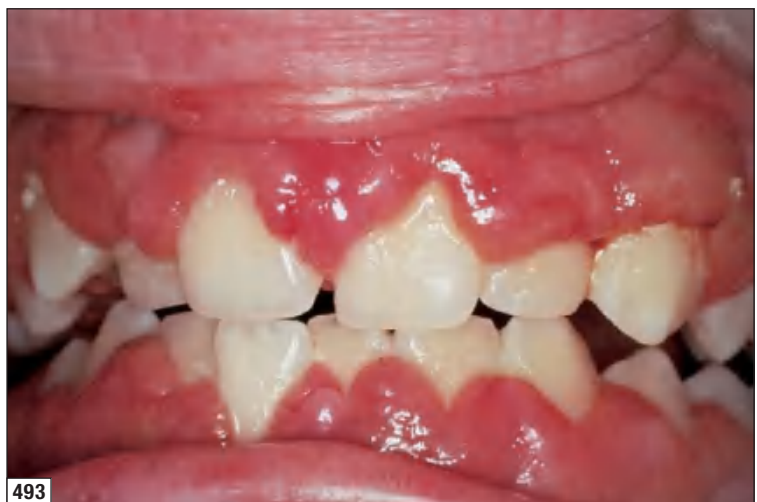Figure 490. Purpura in leukemia.



491
Figure 491. Leukemic infiltrate.



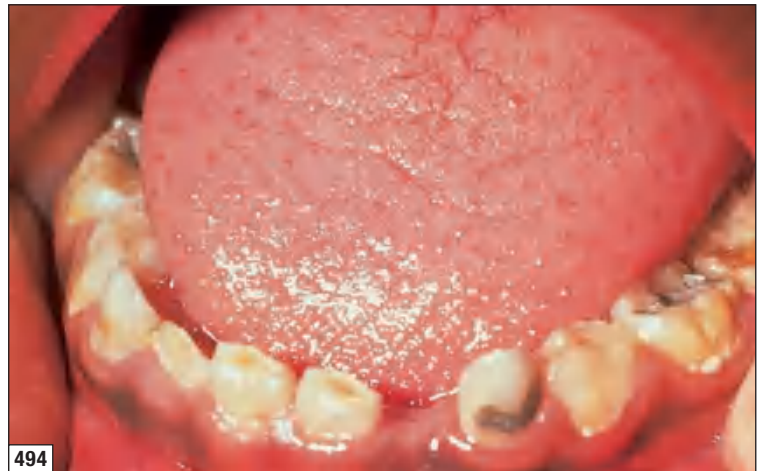492
Figure 492. Oral ulceration in acute lymphoblastic leukemia.



493
Figure 493. Gingival swelling in myelomonocytic leukemia.

LEARNING DISABILITY

There are no oral changes specific to learning disability (Fig. 494), but there may be bruxism, malocclusion and oral disease as a consequence of plaque accumulation (inflammatory periodontal disease) and high sugar intake (caries).



494

Figure 494. Learning disability showing dental neglect and calculus.

MALNUTRITION

Ulcers, glossitis and angular stomatitis (cheilitis) are the main oral features (see p. 223).

RADIOTHERAPY

Irradiation involving the orofacial region almost invariably leads to complications (Figs 494–502), though the severity is often related to the dose of radiotherapy used, and these include:

- mucositis
- xerostomia
- loss of taste.

Infections, (caries, candidosis, acute sialadenitis), and dental hypersensitivity are mainly secondary to reduced salivary function.

More serious, but less common, and seen mainly where the jaws are irradiated, are:

- osteoradionecrosis, osteomyelitis and trismus secondary to endarteritis of the small arteries in bone and muscle
- craniofacial, tooth and root maldevelopment producing results similar to those seen in patients on chemotherapy.

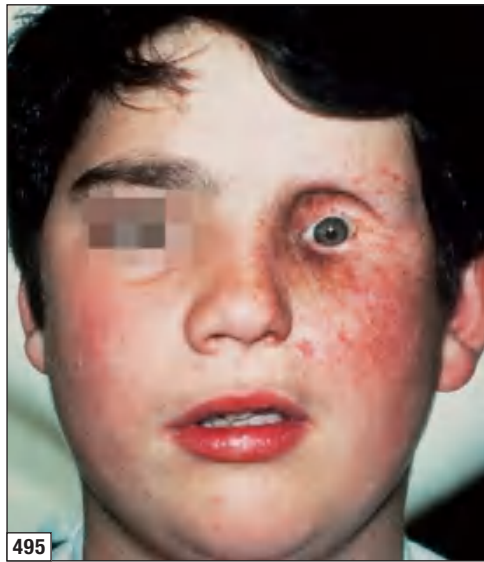

Figure 495. Rhabdomyosarcoma of the orbital muscles of the left eye was treated by enucleation and radiotherapy. This has resulted in telangiectasia of the skin of the left side of the eye and cheek and left infraorbital and maxillary hypoplasia.

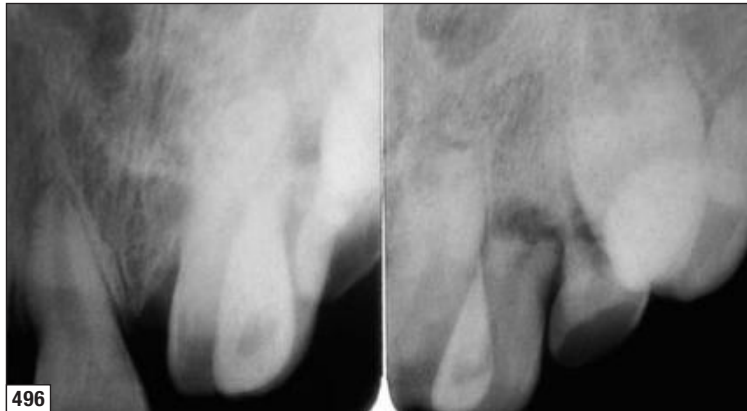

Figure 496. Rhabdomyosarcoma. Intraoral radiograph of the left anterior maxillary teeth of the patient in Figure 495. There has been cessation of root growth of the permanent lateral incisor and canine as a result of radiotherapy.

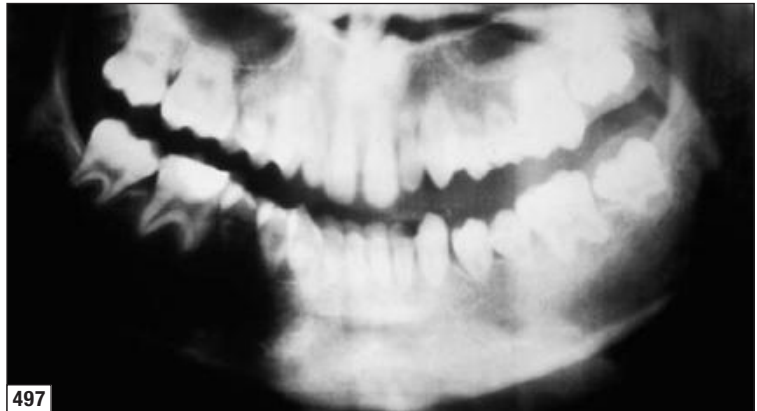

Figure 497. Rhabdomyosarcoma. This patient received external beam X-irradiation treatment to a sarcoma of the left parotid gland at 5 years of age. There has been partial cessation of root growth and premature apical closure in all the permanent teeth. Despite this all the permanent teeth have erupted into their correct occlusal position by the age of 11 years.

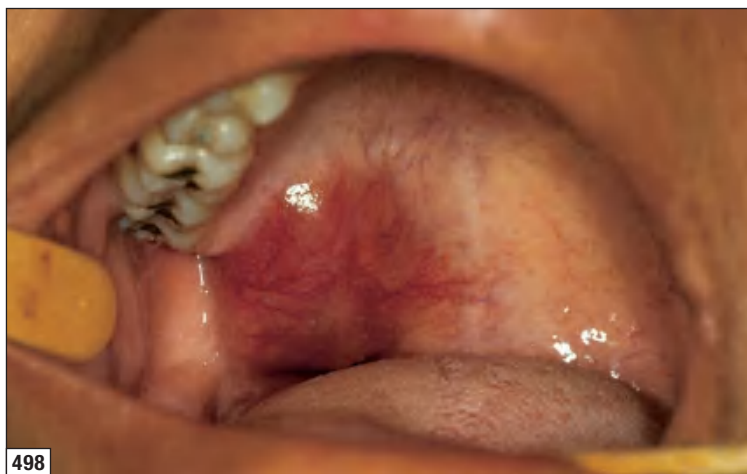

Figure 498. Rhabdomyosarcoma – palatal swelling.

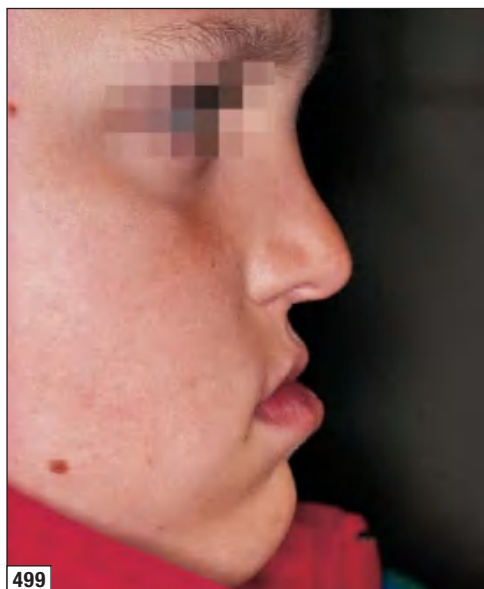
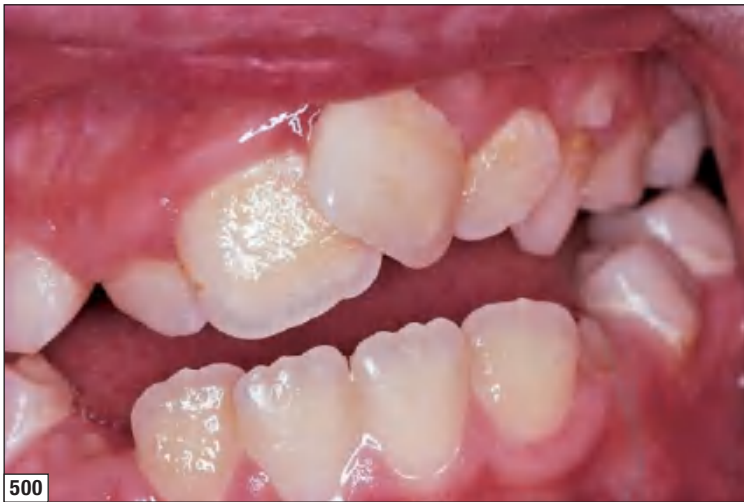
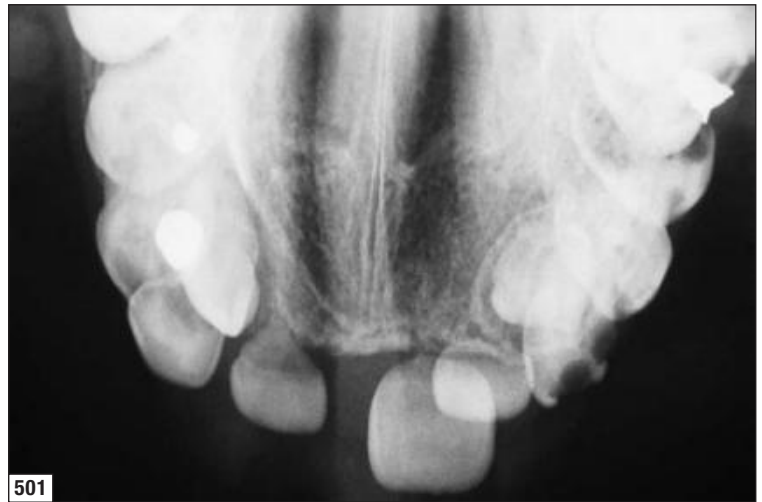
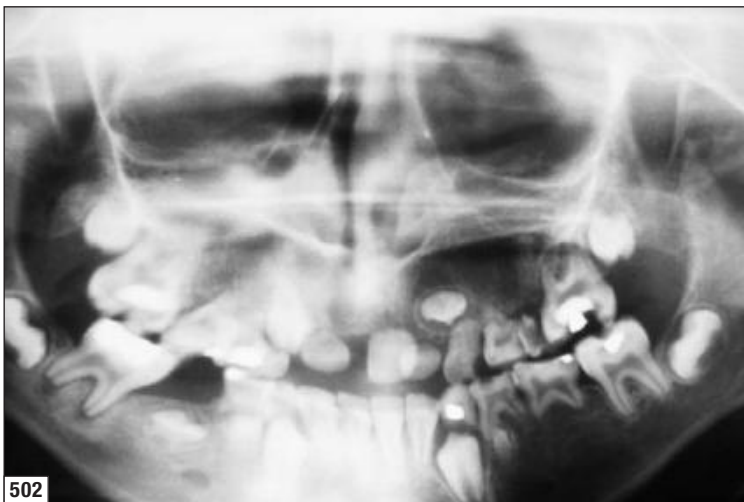Figure 499. Rhabdomyosarcoma; effect of radiotherapy on facial development.



500



501



502

Figures 500–502. Rhabdomyosarcoma – effect of radiotherapy on dental development.

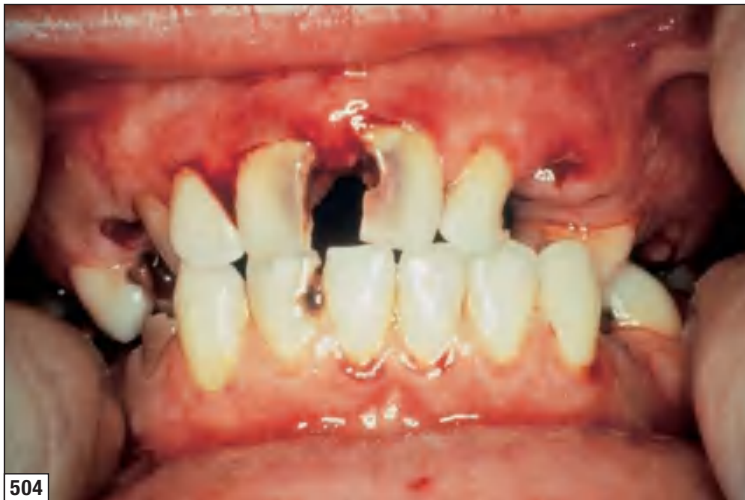SOLID ORGAN TRANSPLANTATION

The chronic immunosuppression needed following organ transplantation predisposes to candidosis, herpesvirus, human papillomavirus and other infections. Some patients develop white lesions (keratoses) or hairy leukoplakia. Occasional malignant tumors have resulted including Kaposi's sarcoma, lymphomas and carcinomas. Ciclosporin may induce gingival hyperplasia.

THROMBOCYTOPATHY

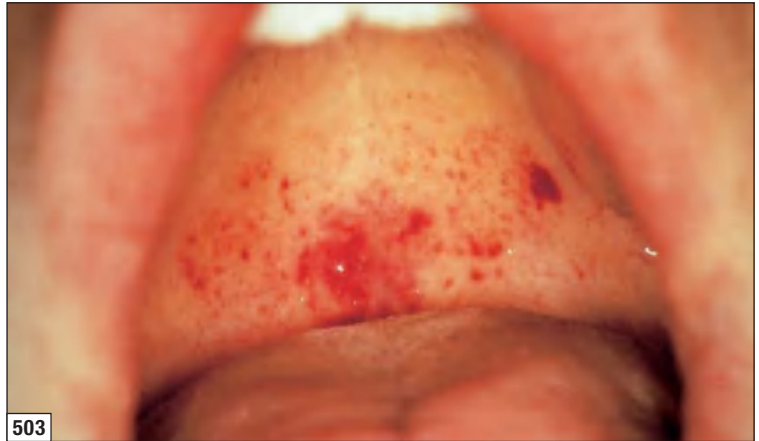Spontaneous gingival bleeding is often an early feature in platelet deficiencies or defects (Figs 503–505). Post-extraction bleeding may be a problem.

Oral petechiae and ecchymoses appear mainly at sites of trauma, but can be spontaneous. Petechiae appear therefore, mainly in the buccal mucosa, on the lateral margin of the tongue, and at the junction of hard and soft palates.



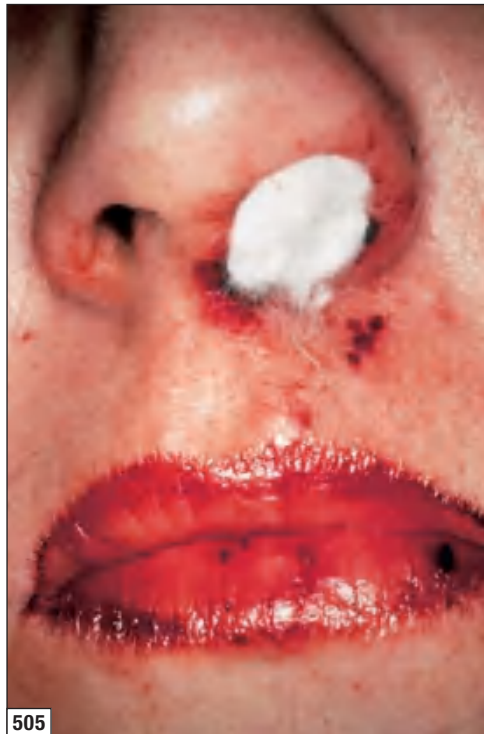504

Figure 504. Spontaneous gingival bleeding and epistaxis in a teenage patient with idiopathic thrombocytopenic purpura who has a neglected dentition.



503

Figure 503. Oral petechiae in thrombocytopenia.



505

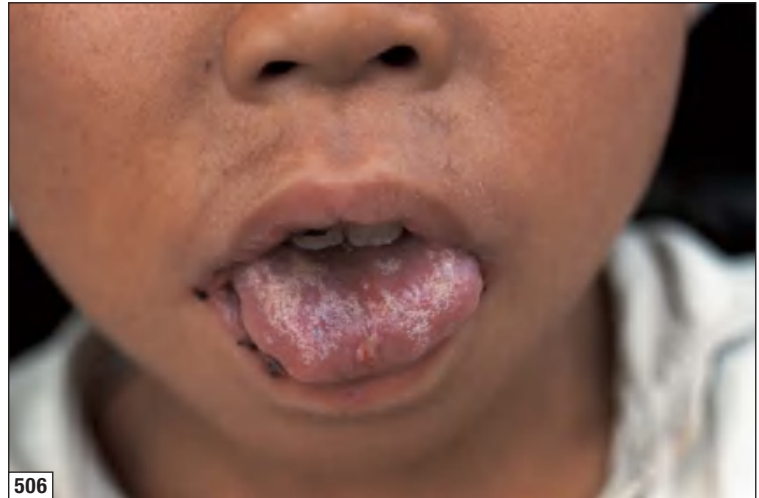Figure 505. Petechiae are visible in the patient in Figure 504, on the skin below the left nares, the lower lip and the chin.

VON WILLEBRAND'S DISEASE

Spontaneous gingival bleeding, oral purpura and post-extraction bleeding may be seen in von Willebrand's disease.

VITAMIN DEFICIENCIES

Deficiencies of hematinics (iron, vitamin B or folic acid) can manifest with glossitis, angular stomatitis and candidosis, and mouth ulcers. Such deficiencies are seen particularly in malnutrition (Fig. 506).



506

Figure 506. Tongue in pellagra showing ulceration.

Iron deficiency

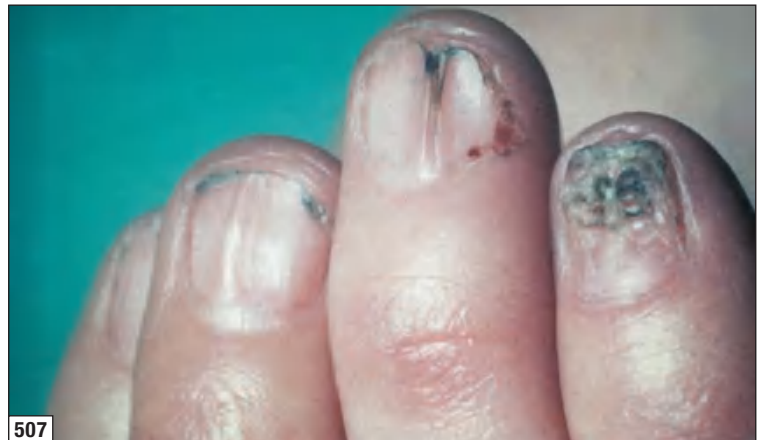The most common cause of iron deficiency (Figs 507, 508) in developed countries is dietary deficiency, or chronic hemorrhage, though this is rare in children. When bone marrow iron stores are depleted, there is a stage of iron deficiency without anemia (sideropenia) and before red cell changes and pallor are evident. Angular stomatitis, ulcers and sore mouth are oral manifestations, which may be seen in the pre-anemic stage as well as in anemia. Clinically obvious lesions are not always demonstrable, though the mouth is sore.

Vitamin B deficiency

Vitamin B deficiency is rare in children. In developed countries, vitamin B₁₂ deficiency is rarely dietary in origin except in vegans, but is usually a result of pernicious anemia, or gastric or small intestinal disease. It may cause a sore mouth, sometimes with atrophic glossitis, which presents as a depapillated and smooth tongue. Red lines or red patches on the ventrum of the tongue (Moeller's glossitis), are fairly typical of early vitamin B₁₂ deficiency. Clinically obvious lesions are not always demonstrable, though the mouth is sore. Oral ulcers and angular stomatitis are also common features. Angular stomatitis is seen particularly in vitamin B₁₂ and riboflavin deficiency.

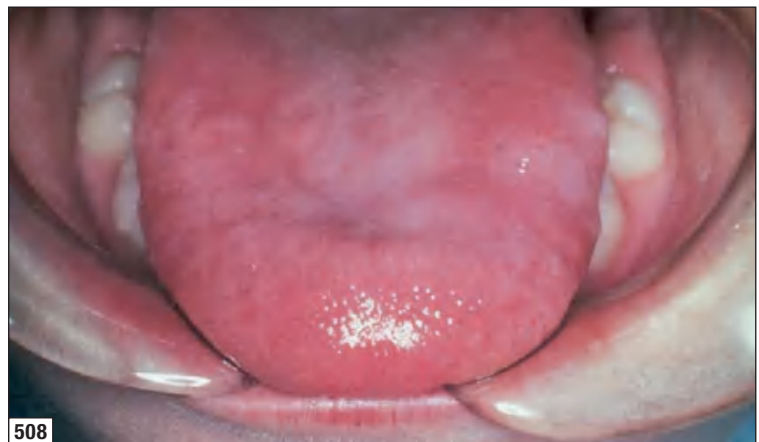Folic acid deficiency

Folic acid deficiency may be dietary. Angular stomatitis, ulcers and sore mouth are oral manifestations, which may be seen in the pre-anemic stage as well as in anemia. Clinically obvious lesions are not always demonstrable though the mouth is sore.



507

Figure 507. Iron deficiency in a 10-year-old child. Koilonychia is the term given to nail changes first evidenced by brittleness and dryness, later by flattening and thinning, and finally by concavity (spoon-shape). In addition there is a chronic fungal infection of the nailbed of the index finger.



508

Figure 508. Chronic atrophic glossitis in the same child as in Figure 507. There is some atrophy of the papillae and mucous membrane giving the tongue a smooth glazed appearance. The atrophy begins at the edges and later affects the whole tongue. As a result the tongue appears moist and exceptionally clean.

FURTHER READING

- Alamoudi N, Farsi N, Salako NO, Feteih R. Temporomandibular disorders among school children. *J Clin Pediatr Dent* **22**(4): 323–8, 1998.
- American Academy of Periodontology. Position Paper: Periodontal diseases of children and adolescents. *J Periodontol* **67**:57–62, 1996.
- Cameron A, Widmer R. *Handbook of Paediatric Dentistry*. St Louis, Mosby, 1997.
- Delaney JE, Keels MA. Pediatric oral pathology. Soft tissue and periodontal conditions. *Pediatr Clin North Am* **47**(5): 1125–47, 2000.
- Feder HM. Cimetidine treatment for periodic fever associated with aphthous stomatitis, pharyngitis and cervical adenitis. *Pediatr Infect Dis J* **11**:318–21, 1992.
- Field E, Brookes V, Tyldesley W. Recurrent aphthous ulcerations in children – a review. *Int J Pediatr Dent* **2**:1–10, 1992.
- Flaitz C, Hicks MJ. Oral candidiasis in children with immune suppression: Clinical appearances and therapeutic considerations. *ASDC J Dent Child* **66**:161–6, 1999.
- Flaitz CM, Baker KA. Treatment approaches to common symptomatic oral lesions in children. *Dent Clin North Am* **44**:671–696, 2000.
- Flaitz CM, Coleman GC. Differential diagnosis of oral enlargements in children. *Pediatr Dent* **17**:294–304, 1995.
- Flaitz CM. Differential diagnosis of oral mucosal lesions in children and adolescents. *Advances in Dermatology* **16**:39–79, 2000.
- Flaitz CM. Oral pathologic conditions and soft tissue anomalies. In Pinkham JR, Casamassimo PS, Fields HW, McTigue DJ, Nowak AJ (eds). *Pediatric Dentistry: Infancy Through Adolescence*, 3rd edition. Philadelphia, WB Saunders, 1999.
- Flanagan MA, Barasch A, Koenigsberg SR, Fine D, Houpt M. Prevalence of oral soft tissue lesions in HIV-infected minority children treated with highly active antiretroviral therapies. *Pediatr Dent* **22**(4): 287–91, 2000.
- Gorlin RJ, Cohen Jr MM, Levin LS. *Syndromes of the Head and Neck*. 3rd edition. Oxford, Oxford University Press, 1990.
- Hall RK. *Pediatric Orofacial Medicine and Pathology*. London, Chapman & Hall Medical, 1994.
- Hernandez-Sampelayo T. Fluconazole versus ketoconazole in the treatment of oropharyngeal candidiasis in HIV-infected children. Multicentre Study Group. *Eur J Clin Microbiol Infect Dis* **13**:340–4, 1994.
- Kimberlin D, Powell D, Prober C, et al. Administration of oral acyclovir suppressive therapy after neonatal simplex virus disease limited to the skin, eyes, and mouth: Results of a phase I/II trial. *Pediatr Infect Dis J* **15**:247–54, 1996.
- Kozinetz CA, Carter AB, Simon C, Hicks MJ, Rossmann SN, Flaitz CM, Cron SG, Kline MW. Oral manifestations of pediatric vertical HIV infection. *AIDS Patient Care* **14**(2): 89–94, 2000.
- Lopes MA, Goncalves M, Di Hipolito Junior O, de Almeida OP. Congenital lower lip pits: case report and review of literature. *J Clin Pediatr Dent* **23**(3): 275–7, 1999.
- Majorana A, Schubert MM, Porta F, Ugazio AG, Sapelli PL. Oral complications of pediatric hematopoietic cell transplantation: diagnosis and management. *Support Care Cancer* **8**(5): 353–65, 2000.
- McNamara CM, O'Riordan BC, Blake M, Sandy JR. Cleidocranial dysplasia: radiological appearances on dental panoramic radiography. *Dentomaxillofac Radiol* **28**(2):89–97, 1999.
- Orvidas LJ, Kasperbauer JL. Pediatric lymphangiomas of the head and neck. *Ann Otol Rhinol Laryngol* **109**(4): 411–21, 2000.
- Pinkham JR, Casamassimo PS, Fields Jr HW, McTigue DJ, Nowak A (eds). *Pediatric Dentistry: Infancy Through Adolescence*. 3rd edition. Philadelphia, WB Saunders Co, 1999.
- Ramos-Gomez FJ, Flaitz C, Catapano P, Murray P, Milnes AR, Dorenbaum A. Classification, diagnostic criteria, and treatment recommendations for orofacial manifestations in HIV-infected pediatric patients. *J Clin Pediatr Dent* 1999;23:85–95.
- Rosenberg SW, Arm RN (eds) *Clinician's Guide to Treatment of Common Oral Conditions*. American Academy of Oral Medicine, 1997.
- Scully C, Bagan JV, Eisen D, Porter S, Rogers RS. *Dermatology of the Lips*. Oxford, Isis Medical Media, 2000.
- Scully C, Epstein JB, Wiesenfeld J. *Oxford Handbook of Dental Patient Care*. Oxford, Oxford University Press, 1998.
- Scully C, Flint S, Porter SR. *Oral Diseases*. London, Martin Dunitz, 1996.
- Scully C, Cawson RA. *Medical Problems in Dentistry*. 1st edition. Bristol, London and Boston, P.S.G. Wright, 1982.
- Scully C. *Handbook of Oral Disease; Diagnosis and Management*. London, Martin Dunitz, 1999.
- Takekoto CK, Hodding HH, Kraus D. *Pediatric Dosage Handbook*. Washington, DC, American Pharmaceutical Association, 2000.
- USP-DI: Drug Information for the Health Care Professional*, Volume 1. Rockville, MD, USP, 1999.
- Wake M, Hesketh K, Allen M. Parent beliefs about infant teething: a survey of Australian parents. *J Paediatr Child Health* **35**(5):446–9, 1999.
- Welbury RR (ed) *Paediatric Dentistry*. 2nd Edition. Oxford, Oxford University Press, 2001.
- White AK. Salivary gland disease in infancy and childhood: non-malignant lesions. *J Otolaryngol* **21**(6): 422–8, 1992.

i ndex

A

Abrasion (teeth) 75
Abscesses
 lateral periodontal 119
 migratory, of buccal sulcus 113
 periapical 78–79
Acatasia 211
Accessory nerve 12
Acquired disorders
 gingival disease 105–122
 mucosal 123–174
 musculoskeletal 183–192
 periodontal disease 105–122
 salivary gland 175–182
 teeth 71–104
Acquired hypoparathyroidism 216
Acquired immune deficiency syndrome (AIDS) 203–205
 candidosis 203, 205
 hairy leukoplakia 205
 herpetic ulceration 204
 HIV gingivitis 204
 lesion groupings 205
 lymphomas 205
 median rhomboid glossitis 203
 molluscum contagiosum 167
 periodontitis 204
 salivary gland disease 204
 viral infections 205
Acrocephalosyndactyly 45
Actinic cheilitis 143
Actinomycosis 185
Addison's disease 210
Adenoma, pleomorphic 182
Adenoma sebaceum 54
Adenomatoid odontogenic tumors 188
African Burkitt's lymphoma 164
Albright's syndrome 186
Allergens 131
Allergy type 1 hypersensitivity response 131
Alveolar bone 8, 10
Alveolar expansion, fibrous dysplasia 186
Amalgams
 amalgam tattoos 130
 lichen planus 161

Ameloblastoma 188
Amelogenesis imperfecta 18 *see also* Enamel formation
Amoxicillin staining 87
Anemia, aplastic 206
Anesthesia (sensory loss) 198
Anesthetics
 herpes simplex infection 153, 155
 iatrogenic injuries 157
 topical 133
Angioedema 131
 allergic 29, 131
 hereditary 29
Angiofibromas 54–55
Angiomatosis, encephalofacial 33
Angular cheilitis 131, 210
Angular stomatitis 131, 210
Ankyloglossia (tongue tie) 19
Ankylosis 76
Antifungal agents
 ointments and creams 129–130
 systemic 129
 topical 128, 129, 141
Anti-inflammatory paste 134
Antimicrobial agents, topical
 chapped lips 141
 nonbullous impetigo 158
Antimicrobial oral rinses 129
 aphthae treatment 133
 herpes simplex infection 154
Antiplatelet dentifrices 107
Antiplatelet mouthwashes 107
Antiviral therapy 155–156
 herpes simplex virus infections 153, 154, 155–156
Apert's syndrome 45
Aphthae 132–135 *see also* Ulcers
 Behçet's syndrome (disease) 136
 celiac disease 150
 herpetiform 132
 HIV disease 205
 immunosuppressed patients 217
 major 132
 minor 132
 recurrent 132–135
 treatment options 133–135
Aphthous stomatitis

 in periodic fever syndrome 169
 recurrent 132–135
Aplastic anemia 206
Appliances
 malocclusion treatment 97
 traumatic ulcers 172
Arthritis
 pyogenic 190
 rheumatoid 191
 temporomandibular joints 190–191
Arthromyalgia, facial 190
'Ash leaf' depigmentation 54
Aspergillosis 146
Attrition, dental 76
Autoimmune disease 169
Avulsion, teeth 101

B

Bacterial sialadenitis 178, 182
Basal cell nevi, multiple 58
Bednar's ulcer 172
Behavioral disorders
 bruxism 37, 171
 cheek-chewing 142
 gingival trauma 121
 Rett syndrome 37
 self-mutilation 171
Behçet's syndrome (disease) 136
Bell's palsy 197
Benign migratory glossitis 24–25
Bifid uvula 20
Bile pigment staining, of teeth 95
Biliary atresia, intrinsic staining of teeth 95
Biopsy, salivary 177
Birthmarks 28
Bite (occlusion) 96
 anterior open 96
Bites (dog) 137
Black staining, teeth 87
Bleeding
 gingival 108, 222
 tooth extraction in hemophilia 215
Bloch-Sulzberger disease 59
Bone 10
 disorders

cleidocranial dysplasia 46–47
 hypophosphatasia 30
 tori 10
 Bone marrow transplantation 207
 Bourneville–Pringle disease 54
 Braces *see* Appliances
 Brandywine dentinogenesis imperfecta 22
 Brown staining, teeth 87
 Bruising *see also* Trauma
 aplastic anemia 206
 child abuse 102, 103
 thrombocytopenia 222
 Brushfield's spots 214
 Bruton's syndrome 211
 Bruxism 171
 Rett syndrome 37
 Buccal mucosa *see* Mucosa
 Buccal sulcus, migratory abscess 113
 Bulimia, dental erosion 84
 Bullae
 bullous impetigo 158
 epidermolysis bullosa 53
 Burkitt's lymphoma (African) 164
 Burning mouth syndrome 196
 Burns 138–139
 child abuse 103
 types of injury 138

C

C1-esterase inhibitor deficiency 29
 Calcification, cerebral 54–55
 Calcium channel blockers 116
 Calculus 107
 control 107
 learning disability association 219
 salivary 181
 Cancer *see* Malignancy; Tumors
 Cancrum oris 113
 Candidosis (candidiasis)
 acute 128–130
 AIDS 203, 205
 chronic mucocutaneous (CMC) 212
 following chemotherapy 209
 immunosuppressed patients 217
 papillary hyperplasia 169
 salivary gland disorders 178
 T-cell immune defects 211
 treatment options 128, 129–130
 Candidosis-endocrinopathy syndrome 212
 Carabelli, cusp 5
 Carcinoma *see also* Malignancy
 mucoepidermoid 182
 oral 140
 Caries *see* Dental caries
 Carney syndrome 45
 Celiac disease 150
 Cell rests of Malassez 78
 Central papillary atrophy 166
 Cerebral calcification, epiloia 54
 Cerebral gigantism 68
 Cerebral palsy 208

Chapped lips 141
 Cheek-biting 142
 Cheek-biting keratosis 159
 Cheek-chewing 142
 Cheilitis 143
 actinic 143
 angular 131, 210
 Down syndrome 214
 exfoliative 148
 lip-licking 143
 Cheilitis granulomatosa 143
 Cheilosis 131
 Chemotherapy 208–209
 enamel hypoplasia 82, 208
 hypodontia association 91
 Cherubism 19
 Chickenpox 173
 Child abuse 102–103
 traumatic ulcers 172
 Chondroectodermal dysplasia 46
 Choristoma 144
 Chronic granulomatous disease 210
 Chronic mucocutaneous candidosis (CMC) 212
 Chvostek's sign 216
 Ciclosporin, gingival hyperplasia due to 116, 207
 Circumvallate papillae 9
 Clefing disorders (cleft lip/palate) 20, 36
 Cleidocranial dysplasia (dysostosis) 46–47
 Clofazimine 168
 Cluster headache 196
 Cobblestoning 145
 Cocaine burns 139
 Coffin-Lowry syndrome 48
 Cold injury 138, 139
 Collagen disorders
 Ehlers–Danlos syndrome 52
 epidermolysis bullosa 53
 osteogenesis imperfecta 64
 Commissural lip pits 31
 Complement activation 29
 Complex odontome 98
 Condyloma acuminatum 156
 Congenital and hereditary disorders
 lesser orofacial involvement 43–70
 prominent orofacial involvement 15–42
 Congenital epulis 21
 Congenital heart defects 215
 Congenital hypoparathyroidism 216
 Congenital immunodeficiencies 210–213
 Congenital insensitivity to pain 198
 Congenital lingual choristoma 144
 Conjunctivitis, ligneous 33
 Connation 81, 99
 Corticosteroid treatment
 adverse effects 206
 mouthwashes, for aphthae 135
 systemic, for aphthae 135
 topical
 for aphthae 134
 chapped lips 141
 Cotton roll burn 138
 Cowden's syndrome 48

Coxsackievirus infections 151
 Cranial nerves 12–13 *see also* Innervation;
individual nerves
 Craniocarpotarsal dysplasia 40
 Craniofacial dysostosis 49
 Craniofacial fibrous dysplasia 186
 Crohn's disease 144–145
 pyostomatitis vegetans 170
 Crouzon's syndrome 49
 Crowded teeth 96–97
 Cusps
 cusp of Carabelli 5
 palatal, prominent 99
 prominent 99
 talon cusp 88, 99
 Cyanosis 213
 Cyclic neutropenia 210
 Cyclosporin (ciclosporin), gingival hyperplasia
 116, 207
 Cystic fibrosis 213
 Cysts
 dentigerous 85
 eruption 85, 130
 gingival/palatal, of the newborn 27
 lymphoepithelial 163
 odontogenic 188
 periapical 186
 Cytomegalovirus (CMV) infection 217

D

Decalcification, teeth 77
 Deciduous teeth *see* Primary dentition
 Delayed eruption, of teeth 73
 Dens evaginatus 98
 Dens in dente 98
 Dens invaginatus 98
 Dental caries 77–79
 diet 77–78
 'nursing' 78
 prevention 78
 salivary gland disorders 178
 sequelae 78
 vaccines 78
 Dental neglect 219
 Dental pain 78 *see also* Pain
 Dental plaque *see* Plaque, dental
 Dentigerous cyst 85
 Dentinal pain 78
 Dentine
 defects 75
 hereditary opalescent 22
 Dentine dysplasia type II 21
 Dentinogenesis imperfecta 22–23, 64
 Dentition *see also* Teeth
 mixed 3, 74
 permanent *see* Permanent dentition
 primary *see* Primary dentition
 Depigmentation 54
 Diabetes mellitus 131
 Diet
 dental caries 77–78

reactions to, orofacial granulomatosis 168
 tooth attrition 76
 tooth erosion 84
 DiGeorge syndrome 211
 Digital anomalies, Apert's syndrome 45
 Dilaceration 80
 Dilated odontome 98
 Discoid lupus erythematosus (DLE) 163
 Discoloration, teeth
 causes 74–75
 extrinsic staining 87
 idiopathic discoloration 94–95
 intrinsic staining 94–95, 213
 Dog bites 137
 Double teeth 81
 Down syndrome 214
 lip fissures 162
 Drooling 179
 Drug allergens, angioedema 131
 Drug-induced disorders/reactions
 angioedema 131
 gingival hyperplasia due to ciclosporin
 116, 207
 lichen planus 161
 Dry mouth 77, 177–178 *see also* Salivary glands
 causes 177
 Dyskeratosis congenita 49
 Dysostosis
 cleidocranial 46–47
 craniofacial 49

E

Ears, referred pain 195
 Ectodermal dysplasia 50–51, 74
 hypohidrotic with hypothyroidism 50
 incontinentia pigmenti 59
 salivary gland hypoplasia 50
 Ectopic eruption, teeth 74
 Edema
 facial *see* Facial edema
 facial 159
 infectious mononucleosis 159
 Ehlers–Danlos syndrome 52
 Electrical burns 138, 139
 Ellis–van Creveld syndrome 46
 Emphysema, surgical 103
 Enamel abnormalities 75
 after chemotherapy 208
 after radiotherapy 82–83
 hypoplasia *see* Enamel hypoplasia
 Morquio's syndrome 61
 pitting in fluorosis 94
 Sjögren–Larsson syndrome 67
 Enamel cleft 82
 Enamel formation 3
 inherited disorders 18
 Enamel hypoplasia 82–83 *see also* Enamel
 abnormalities
 chronological 83
 hypoparathyroidism 216
 pitting 55

 radiotherapy effect 82
 Encephalofacial angiomatosis 33
 En coup de sabre 170
 Eosinophilic granuloma 160
 Ephelides, labial 166
 Epidermolysis bullosa 53
 Epiloia 54–55
 Epiphyseal abnormalities 69
 Epistaxis, thrombocytopathy 222
 Epstein–Barr virus 217
 African Burkitt's lymphoma 164
 infectious mononucleosis 159
 Epstein's pearls 27
 Epulis
 congenital 21
 fibrous (fibroepithelial polyps) 108, 118
 giant cell 119
 Erosion, dental 84
 Erosive lichen planus 161
 Eruption, teeth *see* Teeth, eruption
 Eruption cysts 85, 130
 Erythema migrans 24–25
 treatment options 25
 Erythema multiforme 147
 Erythema multiforme exudativum 147
 Erythema nodosum 136
 Evaginated odontome 98
 Exfoliative cheilitis 148
 External resorption, teeth 86
 Extraction, tooth 215
 Extrinsic staining, teeth 87
 Eyes, referred pain 195

F

Facial arthromyalgia 190 *see also* Pain
 Facial development, radiotherapy effect 220
 Facial edema
 Langerhans cell histiocytosis 160
 Melkersson–Rosenthal syndrome 33
 periapical abscess 79
 Facial features
 Apert's syndrome 45
 corticosteroid treatment effect 206
 Down syndrome 214
 ectodermal dysplasia 50
 fibrous dysplasia 186
 Goldenhar's syndrome 57
 Hurler's syndrome 60
 masseteric hypertrophy 187
 Prader–Willi syndrome 65
 pseudohypoparathyroidism 216–217
 Rubenstein–Taybi syndrome 66
 Soto's syndrome 68
 trichorhinopharyngeal syndrome type I 69
 William's syndrome 70
 Facial hypoplasia 57
 Facial nerve 13
 Facial pain *see* Pain
 Facial palsy 197–198
 Fallot's tetralogy 215
 Familial white folded gingivostomatosis 41

Facial edema 159
 Fetor oris 108–110
 Fibroepithelial polyps 108, 118
 Fibroma
 giant cell 118
 irritation (fibroepithelial polyps) 108, 118
 subungual 55
 Fibromatoses, gingival 27
 Fibrous dysplasia 186
 Fibrous epulis (fibroepithelial polyps) 108, 118
 Filiform papillae 9
 Finger clubbing 213
 Fissured tongue 24, 25
 Floating teeth 160
 Flossing 107
 Fluoride 94
 protection against dental caries 78
 Fluorosis 94
 Focal dermal hypoplasia 26
 Focal epithelial hyperplasia 26
 Foliate papillae 9
 papillitis 162
 Folic acid deficiency 223
 Fordyce granules (spots) 7
 Foreign bodies, nasal cavity 110
 Fractured teeth 101 *see also* Trauma
 Fragile X syndrome 55
 Fragilitas ossium 64
 Frey's syndrome 196
 Frontal bossing 47
 Fungal infections *see also* Candidosis
 systemic 146
 Fungiform papillae 9
 Furred tongue 149

G

Gardner's syndrome 56
 Gargoylism 60
 Geographic tongue 24–25
 Germination (double teeth) 81
 Ghost teeth 34
 Giant cell epulis 119
 Giant cell fibroma 118
 Giant cell granuloma 119
 Gigantism, cerebral 68
 Gilles de la Tourette's syndrome 171
 Gingivae 8
 Gingival bleeding 108, 222
 Gingival cysts of the newborn 27
 Gingival disease
 acquired 105–122
 immunosuppressed patients 217
 Gingival enlargement 108, 109
 drug-induced 116
 systemic causes 108
 Gingival fibromatoses 27
 Gingival fibrous plaques 55
 Gingival hyperplasia
 ciclosporin-induced 116, 207
 phenytoin-induced 208
 Gingival lesions *see also* Ulcerative gingivitis

- orofacial granulomatosis 145
 plasminogen deficiency 37
 red lesions 108
 white lesions 108
 Gingival lumps
 fibroepithelial polyps 108, 118
 malignancy 108
 pyogenic granuloma 108
 Gingival mucosa 8
 Gingival overgrowth, drug-induced 116
 Gingival papilloma 157
 Gingival pigmentation 108
 Gingival red lesions 108
 Gingival swellings 108 *see also* Gingival enlargement; Gingival lumps
 herpetic stomatitis 152
 leukemias 218
 orofacial granulomatosis 145
 Gingival trauma 121
 Gingival ulcers 108
 Langerhans cell histiocytosis 160
 self-induced 121
 Gingival white lesions 108
 Gingivitis 108
 acute necrotizing ulcerative 111–112
 acute ulcerative 152
 chronic hyperplastic 114
 chronic marginal 115
 HIV 204
 inflammatory 107
 Sjögren–larsson syndrome 67
 ulcerative *see* Ulcerative gingivitis
 Gingivostomatosis, familial white folded 41
 Glandular fever 159
 Glossitis
 AIDS 203
 benign migratory 24–25
 celiac disease 150
 chronic atrophic 223
 median rhomboid 166, 203
 Moeller's 223
 pellagra 223
 vitamin B deficiency 223
 Glossopharyngeal nerve 12
 Gluten-sensitive enteropathy 150
 Goldenhar's syndrome 57
 Goltz syndrome 26
 Gorlin–Goltz syndrome 58
 Gorlin's syndrome 58
 Graft *versus* host disease
 lichen planus 161
 orofacial lesions 207
 Granular cell tumor 150
 Granuloma 78
 eosinophilic 160
 giant cell 119
 noncaseating 144, 168
 pyogenic 108, 117
 Granulomatosis
 Crohn's disease 144–145
 orofacial 168
 Granulomatous disease, chronic 210
 Green staining, teeth 87
 Grinding habits, teeth 76
 Growth disorders 190
 GVHD *see* Graft *versus* host disease
- ## H
- Haim–Munk syndrome 35
 Hairy leukoplakia 217
 AIDS 205
 Halitosis 108–110
 Hamartomas 28
 Cowden's syndrome 48
 lymphangioma 32
 odontomes 98
 Hand, foot and mouth disease 151
 Hand–Schuller–Christian disease 160
 HANE 29
 Headaches 196
 Healthy mouth 1–14
 Heck's disease 26
 Hemangiomas 28
 Sturge–Weber syndrome 38
 Hematomas
 eruption 85
 hemophilia 215
 traumatic ulcers 172
 Hemolytic disease of newborn 94
 Hemophilias 215
 Hepatitis, chronic active 161
 Hepatitis C 161
 Hereditary opalescent dentine 22
 Herpangina 151
 Herpes labialis 152, 154
 leukemias 218
 T-cell immune defects 211
 Herpes simplex infections 152–156
 after chemotherapy 209
 AIDS herpetic ulceration 204
 Bell's palsy 197
 herpes labialis *see* Herpes labialis
 herpetic/postherpetic neuralgia 196
 herpetic stomatitis 149, 152
 immunocompromised patients 154, 204, 217
 primary infection 152–153
 recurrences 154
 prevention 155
 skin lesions 152
 treatment options 153–154, 155–156
 Herpes virus infections, immunosuppressed patients 217
 Herpes zoster 173
 Herpetic stomatitis 149, 152
 Herpetic ulceration, in AIDS 198
 Histiocytosis X (Langerhans cell histiocytosis) 160
 HIV-related disease *see* Acquired immune deficiency syndrome (AIDS)
 HPV *see* Human papillomavirus infections
 HSV *see* Herpes simplex infections
 Human papillomavirus infections 156–157
 after chemotherapy 209
 focal epithelial hyperplasia 26
 Hurler's syndrome 60
 Hutchinson's incisors 39
 Hypercalcaemia–supravulvar aortic stenosis syndrome 70
 Hyperdontia 74, 88–89 *see also* Supernumerary teeth
 Hyperelasticity 52
 Hyperkeratosis 35
 Hyperpigmentation
 Albright's syndrome 186
 candidosis–endocrinopathy syndrome 212
 mucosal lesions 126–127
 skin 186
 Hyperplastic gingivitis, chronic 114
 Hyperplastic pulpitis 90
 Hypersalivation 179
 Hypertelorism
 cleidocranial dysplasia 47
 Crouzon's syndrome 49
 Hypocalcified amelogenesis imperfecta 18
 Hypodontia 74, 90–91
 chondroectodermal dysplasia 46
 congenital absence of teeth 91
 ectodermal dysplasia 50, 51
 incontinentia pigmenti 59
 oral-facial-digital syndrome 35
 traumatic 91
 trichorhinopharyngeal syndrome type I 69
 Hypoesthesia 198
 Hypoglossal nerve 12–13
 Hypomaturation amelogenesis imperfecta 18
 Hypoparathyroidism 216–217
 Hypophosphatasia 30
 Hypoplastic amelogenesis imperfecta 18
 Hypothyroidism 50
- ## I
- Iatrogenic injury 157 *see also* Trauma
 traumatic ulcers 172
 Icterus gravis neonatorum 94
 Idiopathic discoloration 94–95
 Idiopathic thrombocytopenic purpura 222
 IgA deficiency, selective 211
 Imbricated teeth 96
 Immunocompromised patients *see also* Acquired immune deficiency syndrome (AIDS)
 congenital immunodeficiencies 210–213
 herpes simplex virus infections 154, 204, 217
 immunosuppression 217, 221
 mycoses 146
 varicella–zoster virus infections 173
 Immunomodulating agents 135
 Impacted teeth 92
 Impetigo 158
 Incontinentia pigmenti 59
 Infectious mononucleosis 159
 Inflammatory gingivitis 107
 Inflammatory periodontal disease 107
 Inflammatory resorption 86

Innervation 11–13 *see also individual nerves*
 motor supply 12–13, 197–198
 taste 11
 teeth 4
 trigeminal nerve 11
 Internal resorption 86, 93
 Intrauterine infections 82
 Intrinsic staining, teeth 94–95, 213 *see also*
 Discoloration
 porphyria 94
 Invaginated odontome 98
 Iron deficiency 223
 Irritation fibroma (fibroepithelial polyps) 108,
 118

J

Jaundice, intrinsic staining 94, 95
 Jaw bones 10
 Joint hypermobility 52
 Juvenile periodontitis 120
 Juvenile rheumatoid arthritis 191

K

Kabuki make-up syndrome 59
 Kaposi's sarcoma 205
 Keratocysts 58
 odontogenic 58
 Keratosis 159
 cheek-biting 159
 Kernicterus 94, 95
 Koilonychia 223
 Koplik's spots 165

L

Laband syndrome 27
 Labia *see* Lips
 Labial frenum abnormalities 17
 Langerhans cell histiocytosis 160
 Learning disability 219
 Lesch–Nyhan syndrome 171
 Letterer–Siwe disease 160
 Leukemia 218
 acute lymphoblastic 209, 218
 myelomonocytic 218
 Leukocyte dysfunction 218
 Leukoedema 6
 Leukoplakia (oral) 49
 Lichenoid lesions 161
 graft *versus* host disease 207
 Lichen planus 161
 Ligneous conjunctivitis 37
 Lingual nerve, sensory loss 198
 Lingual papillitis 162
 Lingual thyroid 31
 Lining mucosa 6
 Lip-licking cheilitis 143
 Lips
 biting 142

burns 139
 carcinoma 140
 chapped 141
 cheilitis 143
 cleft 20, 36
 cracking, Down syndrome 214
 Crohn's disease 144
 fissures 162
 fragile X syndrome 55
 gingivae 8
 hemangiomas 28
 lip pits 31, 39
 lupus erythematosus 163
 Melkersson–Rosenthal syndrome 33
 mucocele 179
 sucking 141
 swelling in erythema multiforme 147
 ulceration 207
 warts 156
 Liver disease, intrinsic staining of teeth 95
 Local pain 195
 Lower motor neuron lesions 13, 197–198
 Lupus erythematosus 163
 Lymphadenitis, submandibular 210
 Lymphangioma 32
 Lymphedema 168
 Lymphoepithelial cyst 163
 Lymphomas 164
 in AIDS 205

M

Macrodonia 75, 96
 Macroglossia 165
 Macules, melanotic 166
 Malassez, cell rests 78
 Malignancy *see also* Tumors
 gingival lumps 108
 immunosuppressed patients 217
 Kaposi's sarcoma and HIV 205
 lymphoma 164, 205
 mucoepidermoid carcinoma 182
 oral carcinoma 140
 salivary neoplasms 182
 Malnutrition 219
 osteomyelitis 189
 Malocclusion 96–97
 gingival damage 121
 Prader–Willi syndrome 65
 Mandibular division, trigeminal nerve 11
 Mandibular growth, impairment 190
 Mandibular labial gingivae 8
 Mandibular protrusion 97
 Mandibular retrusion 97
 Mandibular swellings 19
 Marginal gingivitis, chronic 115
 Martin–Bell syndrome 55
 Masseteric hypertrophy 187
 Masticatory mucosa 8
 Materia alba 107
 Maxillary division, trigeminal nerve 11
 Maxillary labial gingivae 8
 Maxillary protrusion 97
 McCune–Albright syndrome 186
 Measles 165
 Median rhomboid glossitis 166, 203
 Medical conditions, orofacial lesions 201–223
 Melanocytic nevus 167
 Melanotic macule 166
 Melkersson–Rosenthal syndrome 33
 Mesiodens *see* Supernumerary teeth
 Metabolic bone diseases 30
 Microdonia 75
 chemotherapy association 208, 209
 hypodontia association 90
 Microglossia 165
 Microstomia 40
 Migraine 196
 Migrainous neuralgia 196
 Mikulicz's aphthae 132
 Milk teeth *see* Primary dentition
 Mineralization, dentition 4
 MiRAS 132
 Mixed dentition 3, 74
 Moeller's glossitis 223
 Mohr syndrome 35
 Molluscum contagiosum 167
 Moniliasis 128–130 *see also* Candidosis
 Monostotic fibrous dysplasia 186
 Moon's molars 39
 Morquio's syndrome 61
 Morsicatio buccarum 142
 Motor innervation 12–13
 motor neuron lesions 13, 197–198
 Mouth ulcers *see* Aphthae; Ulcers
 Mouthwashes 107
 antimicrobial 133
 chemical burns 139
 Mucocele 180
 Mucopolysaccharidoses 60–61
 Mucosa, oral 6–9
 cobblestoning 145
 hemangiomas 28
 masticatory 8
 papilloma 157
 racial pigmentation 6
 specialized 9
 Mucosal disorders
 acquired 123–174
 lumps 125–127
 swellings *see* Mucosal swellings
 Mucosal lesions 125
 pigmented 126
 red lesions 126
 syphilis 171
 ulcers 127
 white lesions 127
 Mucosal neuromas 62
 Mucosal swellings 125–127
 investigations 125–126
 Melkersson–Rosenthal syndrome 33
 Mucosal tags 145
 Mucositis, lichenoid 206
 Mulberry molars 39
 Multilocular radiolucencies 19

Multiple endocrine neoplasia syndrome type III (MEN) 62
 Multiple hamatoma and neoplasia syndrome 48
 Multiple mucosal neuroma syndrome type IIB 62
 Mumps 181
 Munchausen syndrome 171
 Muscles 10
 Musculoskeletal disorders, acquired 183–192
 Mycoses
 candidosis *see* Candidosis
 deep 146
 Myoblastoma, granular cell 150
 Myofascial pain-dysfunction syndrome 190
 Myxomas, Carney syndrome 45

N

Nail abnormalities
 chondroectodermal dysplasia 46
 chronic mucocutaneous candidosis 212
 dyskeratosis congenita 49
 iron deficiency 223
 Nasopharynx disease 195
 Natal teeth 34
 Neck, referred pain 195
 Necrotizing ulcerative gingivitis, acute 111–112
 Neuralgia
 herpetic and postherpetic 196
 migrainous 196
 trigeminal 196
 Neuralgia-inducing cavitation necrosis 196
 Neurofibromatosis type I 70
 Neurological assessment 199
 Neurological disorders 193–200
 motor loss 197–198
 orofacial pain 196
 sensory loss 198–199
 Neuromas, mucosal 62
 Neutropenia, cyclic 210
 Nevi
 Gorlin's syndrome 58
 intra-dermal 166
 melanocytic 167
 white sponge nevus 41
 Nevoid basal cell carcinoma syndrome 58
 Noma 113
 Nonaccidental injury *see* Child abuse
 Non-African Burkitt's lymphoma 164
 Nonbullous impetigo 158
 Noonan's syndrome 63
 Normal mouth and variants 1–14
 Nursing caries 78 *see also* Dental caries
 Nutritional liquid supplements 153

O

Occlusion (bite) 96
 Oculoauriculovertbral dysplasia 57
 Odontodysplasia 34
 Odontogenesis imperfecta 34

Odontogenic cysts 188
 Odontogenic keratocysts 58
 Odontogenic tumors 188
 Odontomes 98
 Operculum, inflammation 113
 Oral allergy syndrome 131
 Oral-facial-digital syndrome (OFD) 35
 Oral malodor 108–110
 Orofacial granulomatosis 168
 Crohn's disease 144–145
 Orofacial lesions, in systemic medical conditions 201–223
 Orofacial pain 193–200
 Osteogenesis imperfecta 64
 Osteoma 56
 Osteomyelitis 189
 Otopalatodigital syndrome 66

P

Pain 193–200
 atypical facial 196
 control 133
 dental 78
 orofacial
 causes 195–197
 differential diagnosis 195
 referred 195
 Palatal abnormalities
 burns 138
 cleft palate 20, 36
 erosion 84
 Soto's syndrome 68
 whistling face syndrome 40
 Palatal bruising 206
 Palatal cusps 99
 Palatal cysts of the newborn 27
 Palatal gingivae 8
 Palatal glands, pleomorphic adenoma 182
 Palatal swellings
 Langerhans cell histiocytosis 160
 rhabdomyosarcoma 220
 Palate
 cleft 20, 36
 normal 8
 Papillae 9
 Papillary atrophy 166
 Papillary hyperplasia 9, 169
 Papillitis 9, 162
 foliate 162
 lingual 162
 Papilloma, gingival 157
 Papillomavirus *see* Human papillomavirus infections
 Papillon-Lefèvre syndrome 35
 Papules
 Cowden's syndrome 48
 molluscum contagiosum 167
 Papyraceous scarring 52
 Paramyxoviruses
 measles 165
 mumps 181
 Paranasal sinus disease 195
 Paresthesia 198
 Parotitis 181
 HIV 205
 recurrent 182
 Paul-Bunnell positive glandular fever 159
 PAX genes 90
 Peg-shaped teeth 91
 Pellagra 223
 Pemphigus vulgaris 169
 Periadenitis mucosa necrotica recurrens (PMNR) 132
 Perianal ulceration 136
 Periapical abscesses 78–79
 Pericoronitis, acute 113
 Periodic fever, aphthous stomatitis, pharyngitis and cervical adenitis (PFAPA) syndrome 169
 Periodontal abscess 119
 Periodontal disease
 acquired 105–122
 cyclic neutropenia 210
 immunosuppressed patients 217
 inflammatory 107
 Papillon-Lefèvre syndrome 35
 Periodontitis
 chronic 119
 Down syndrome 214
 early-onset 110, 120
 HIV 204, 205
 prepubertal/juvenile 120
 rapidly advancing 110
 Periodontosis 120
 Perleche 131
 Permanent dentition 4 *see also* Teeth
 damage 75
 eruption times 4, 73
 Patau's syndrome 36
 Petechiae 139
 erythema multiforme 147
 infectious mononucleosis 159
 thrombocytopeny 222
 varicella-zoster virus infections 173
 Peutz-Jeghers syndrome 64
 PFAPA syndrome 169
 Phenytoin-induced gingival hyperplasia 116, 208
 Pierre Robin syndrome 36
 Pigmentary incontinence, lichen planus 161
 Pigmentation *see also* Hyperpigmentation
 depigmentation 54
 gingival 108
 oral 126
 racial 6, 108
 Pinch marks 103
 Pink spot 93
 Pit and fissure sealants 78
 'Pizza-palate' 138
 Plaque, dental 77–78, 107
 chronic marginal gingivitis 115
 halitosis 108
 Plasminogen deficiency 37
 Platelet deficiencies 222
 Plugged tonsillar crypts 109
 Polyostotic fibrous dysplasia 186

Polyps
 fibroepithelial 108, 118
 pulp 90
 Porphyria 94
 Pox virus infection 167
 Prader–Willi syndrome 65
 Prepubertal periodontitis 120
 Primary dentition 3 *see also* Teeth
 eruption times 4
 retention in cleidocranial dysplasia 47
 Pseudohypoparathyroidism 216–217
 Psychogenic disorders
 orofacial pain 195, 196–197
 sensory loss 199
 temporomandibular joint pain-dysfunction syndrome 190
 Ptyalism 179
 Pulp
 abnormal morphology 21
 polyps 90
 Pulpitis 78
 hyperplastic 90
 Purpura
 aplastic anemia 206
 leukemias 218
 Wiskott–Aldrich syndrome 213
 Pyogenic arthritis 190
 Pyogenic granuloma 108, 117
 Pyostomatitis vegetans 170

R

Racial traits/disorders
 focal epithelial hyperplasia 26
 pigmentation 6, 108
 taurodontism 100
 Radiolucencies
 cherubism 19
 Hurler's syndrome 60
 Langerhans cell histiocytosis 160
 Radiotherapy 220–221
 enamel hypoplasia 82
 Ranula 180
 Rashes *see* Petechiae
 Recurrent aphthous stomatitis (RAS) 132–135
 Red lesions, mucosal 126
 Referred pain 195
 Replanting teeth 101
 Resorption
 external 86
 internal 86, 93
 Retrocuspid papilla 9
 Rett syndrome 37
 Rhabdomyosarcoma 220–221
 Rheumatoid arthritis 191
 Rhomboid glossitis, median 166, 203
 Rickets, vitamin D resistant 40
 Riga–Fede disease 172
 Riley–Day syndrome 171, 198
 Robin syndrome (sequence) 36
 Rubenstein–Taybi syndrome 66
 Rubeola 165
 Russell's sign 84

S

Saliva 10
 flow rates 177
 herpes simplex infection 153
 hypersalivation 179
 substitutes 178
 Salivary glands 10
 acquired disorders 175–182
 agenesis 177
 AIDS 204
 biopsy 177
 calculi 181
 hypoplasia 50
 investigations 177–178
 neoplasms 182
 orofacial pain 195
 secretions 10
 swelling 178–179
 Salivary scintiscanning 177–178
 Sarcoidosis 144
 Scarring
 epidermolysis bullosa 53
 papyraceous 52
 Scintiscanning, salivary 177–178
 Scleroderma 170
 Scrotal tongue 24, 25
 Sebaceous glands 7
 Selective IgA deficiency 211
 Self-mutilation 171 *see also* Behavioral disorders
 Sensory loss 198–199
 extracranial causes 198
 intracranial causes 198–199
 Septicemia of oral origin 208
 Severe combined immunodeficiency (SCID) 213
 Sex-linked panhypopimmunoglobulinemia 211
 Shortlasting, Unilateral, Neuralgiform
 headache attacks with Conjunctival
 injection and Tearing (SUNCT)
 syndrome 196
 Sialadenitis 195
 recurrent 182
 suppurative 178, 182
 Sialochemistry 178
 Sialography 177
 Sialolithiasis 181
 Sialometry 177
 Sialorrhea 179
 Sinuses, tumors 195
 Sinusitis, acute 195
 Sjögren–Larsson syndrome 67
 Skeletal deformities
 cystic fibrosis 213
 Morquio's syndrome 61
 pseudohypoparathyroidism 216–217
 rhabdomyosarcoma radiotherapy 220–221
 Skin hyperpigmentation, Albright's
 syndrome 186
 Skin infections 210
 Skin lesions
 Cowden's syndrome 48
 hemangiomas 28, 38
 herpes simplex infections 152
 Solid organ transplantation 221
 Soto's syndrome 68
 Speaking, innervation for 12
 Specialized mucosa 9
 Spirochetes 111–112
 Staining of teeth *see* Discoloration
Staphylococcus aureus 182, 189
 Stevens–Johnson syndrome 147
 Stickler syndrome 33
 Stigmata 39
 Still's syndrome 191
 Stomatitis
 angular 131, 210
 herpetic 149, 152
 recurrent aphthous (RAS) 132–135
 vesicular stomatitis with exanthem 151
 Sturge–Weber syndrome 38
 Subgingival calculus 107
 Sublingual gland, ranula 180
 Subluxation, temporomandibular joints 191
 Sulcus terminalis 9
 Supernumerary teeth 74, 88–89, 89
 cleidocranial dysplasia 47
 inverted 89
 Suppurative sialadenitis 178, 182
 Supragingival calculus 107
 Surgical emphysema 103
 Sutton's ulcers 132
 Swallowing, innervation for 12
 Swellings
 gingival *see* Gingival swellings
 lips, in erythema multiforme 147
 mandibular 19
 mucosal *see* Mucosal swellings
 palatal *see* Palatal swellings
 salivary glands 178–179
 Syphilis 171
 congenital 39
 Systemic sclerosis 170

T

Tags, mucosal, orofacial granulomatosis 145
 Talon cusp 88, 99
 Tartar 107
 Taste 11
 Taste buds 11
 Taste fibers 11
 Tattoos, intraoral 130
 Taurodontism 100
 T-cell immune defects 211
 Teeth 3–5 *see also* Dentition
 abrasion 75
 acquired disorders 71–104
 ankylosis 76
 attrition 76
 caries *see* Dental caries
 color variations 74–75
see also Discoloration
 conical 50
 decalcification 77
 development 3–5, 74, 90

germination 81
 dilaceration 78
 discoloration *see* Discoloration, teeth
 early loss 73
 Down syndrome 214
 ectopic eruption 74
 erosion 84
 eruption
 failure 89
 hematoma 85
 eruption times 4, 5
 delayed, causes 73
 normal 73
 variations 5, 73
 extraction, bleeding in hemophiliacs 215
 extrinsic staining 87
 hypoplasia 210, 214
 impacted 92
 innervation 4
 see also Innervation
 mottling 94
 natal 34
 number variations 74
 see also Hyperdontia; Hypodontia
 premature apical closure 52
 replanting 101
 resorption 86
 restoration (filling) 78
 self-extraction 171
 size and shape variations 74–75
 structural variation 74–75, 81
 supernumerary *see* Supernumerary teeth
 transposition 100
 Teething 5
 hypersalivation 179
 Telangiectasia 220
 Temporomandibular joint pain–dysfunction
 syndrome 190, 195
 Temporomandibular joints 10
 disorders 190–191
 subluxation 191
 Tetracyclines, intrinsic staining 94, 95, 213
 Thrombocytopathy 222
 Thrombocytopenia 218
 Thrush 128–130 *see also* Candidosis
 Thyroid, lingual 31
 TMJs *see* Temporomandibular joints
 Tongue
 anatomy 9
 fissured 24, 25
 furred 149
 geographic 24–25
 hemangiomas 28
 hematoma 172
 keratosis 159
 lichen planus 161
 lymphangioma involvement 31
 macroglossia 165
 microglossia 165
 multiple mucosal neuromas 62
 pellagra 223
 pigmented fungiform papillae 6
 plicated 25
 scrotal 24, 25

Tongue tie (ankyloglossia) 19
 Tonsillar crypts, plugged 109
 Tonsils, lingual 9
 Tooth *see* Teeth
 Toothbrushing 107
 abrasion 75
 dental caries prevention 78
 Tooth germ 3
 Toothpaste, fluoride 78
 Torus mandibularis 10
 Torus palatinus 10
 Transient lingual papillitis 162
 Transplantation
 bone marrow 207
 organ 221
 Transposition, teeth 100
 Trauma *see also* Child abuse
 actinomycosis 185
 avulsed teeth 101
 child abuse 102–103
 dilaceration due to 80
 dog bites 137
 enamel hypoplasia 82–83
 fractured teeth 101
 gingival and periodontal damage 121
 iatrogenic injury 157
 self-mutilation 171
 traumatic hypodontia 91
 traumatic ulcers 172
Treponema pallidum 39
 Trichorhinopharyngeal syndrome type I 69
 Trigeminal nerve 11
 divisions 11
 sensory loss 198
 trigeminal neuralgia 196
 Trigeminal neuropathy, benign 198
 Tubercles, prominent 99
 Tuberos sclerosus 54–55
 Tumors *see also* Malignancy
 granular cell tumors 150
 odontogenic 188
 sinuses 195
 Turner tooth 83

U
 Ulcerative colitis 170 *see also* Crohn's disease
 Ulcerative gingivitis
 acute necrotizing 111–112
 in AIDS 205
 Langerhans cell histiocytosis 160
 Ulcers 127
 aphthous *see* Aphthae
 Bednar's 172
 causes 127
 gingival *see* Gingival ulcers
 herpangina 151
 herpetic stomatitis 152
 herpetiform 132
 iatrogenic injuries 157
 immunosuppressed patients 217
 infectious mononucleosis 159
 leukemias 218
 mucosal 127

 necrotic, from electrical burns 139
 orofacial granulomatosis 145, 168
 pellagra 223
 traumatic 172
 Ultrasound 178
 Upper motor neuron lesions 13, 197–198
 Uvula, bifid 20

V

Vaccines, dental caries 78
 Vagus nerve 12
 Van der Woude's syndrome 39
 Varicella–zoster virus infections 173
 Vascular disorders, orofacial pain 196
 Verruca vulgaris 156
 Vesicles
 hand, foot and mouth disease 151
 varicella–zoster virus infections 173
 Vesicular stomatitis with exanthem 151
 Vestibular mucosa 8
 Vincent's disease 111–112
 Vitamin B deficiency 223
 Vitamin deficiencies 223
 Vitamin D resistant rickets 40
 Vitiligo 210
 Volatile sulfide compounds (VSC) 108–109
 Von Recklinghausen neurofibromatosis (NF
 type I) 70
 Von Willebrand's disease 222
 VZV infections 173

W

Waldeyer's oropharyngeal ring 9
 Warts, lips 156
 Whistling face syndrome 40
 White lesions, mucosal 127
 White patches on teeth 94, 95
 White sponge nevus 41
 Williams syndrome 70
 Wisdom teeth, impaction 92
 Wiskott–Aldrich syndrome 213

X

Xeroderma pigmentosum 140
 Xerodermia 50
 Xerostomia *see* Dry mouth

Y

Yellow/orange staining, teeth 87

Z

Zygomatic nerve 11
 Zygomycosis 146